

Paradoxical association between dyspepsia and autoimmune chronic atrophic gastritis: Insights into mechanisms, pathophysiology, and treatment options

Roberta Elisa Rossi, Alessandra Elvevi, Valentina Sciola, Francesco Vito Mandarino, Silvio Danese, Pietro Invernizzi, Sara Massironi

Specialty type: Gastroenterology and hepatology

Provenance and peer review: Invited article; Externally peer reviewed.

Peer-review model: Single blind

Peer-review report's scientific quality classification

Grade A (Excellent): 0
Grade B (Very good): B, B
Grade C (Good): C, C
Grade D (Fair): 0
Grade E (Poor): 0

P-Reviewer: Baryshnikova NV, Russia; Cheng H, China; Huang YQ, China; Jia J, China

Received: March 21, 2023

Peer-review started: March 21, 2023

First decision: April 12, 2023

Revised: April 23, 2023

Accepted: May 6, 2023

Article in press: May 6, 2023

Published online: June 21, 2023



Roberta Elisa Rossi, Gastroenterology and Endoscopy Unit, IRCCS Humanitas Research Hospital, Rozzano 20089, Milan, Italy

Alessandra Elvevi, Pietro Invernizzi, Sara Massironi, Gastroenterology Unit, Fondazione IRCCS San Gerardo dei Tintori, Monza 20900, Italy and Department of Medicine and Surgery, University of Milano-Bicocca, Monza 20900, Italy

Valentina Sciola, Gastroenterology and Endoscopy Unit, Fondazione IRCCS Ca' Granda Ospedale Maggiore Policlinico, Milano 20100, Italy

Francesco Vito Mandarino, Silvio Danese, Department of Gastroenterology and Endoscopy, IRCCS Ospedale San Raffaele, Milan 20132, Italy

Silvio Danese, School of Medicine, Vita-Salute San Raffaele University, Milan 20132, Italy

Corresponding author: Sara Massironi, MD, PhD, Chief Physician, Doctor, Medical Assistant, Research Scientist, Division of Gastroenterology, Fondazione IRCCS San Gerardo dei Tintori, Via Pergolesi, 33, Monza 20900, Italy. sara.massironi@libero.it

Abstract

BACKGROUND

Autoimmune gastritis (AIG) is a progressive, chronic, immune-mediated inflammatory disease characterized by the destruction of gastric parietal cells leading to hypo/anacidity and loss of intrinsic factor. Gastrointestinal symptoms such as dyspepsia and early satiety are very common, being second in terms of frequency only to anemia, which is the most typical feature of AIG.

AIM

To address both well-established and more innovative information and knowledge about this challenging disorder.

METHODS

An extensive bibliographical search was performed in PubMed to identify guidelines and primary literature (retrospective and prospective studies, systematic reviews, case series) published in the last 10 years.

RESULTS

A total of 125 records were reviewed and 80 were defined as fulfilling the criteria.

CONCLUSION

AIG can cause a range of clinical manifestations, including dyspepsia. The pathophysiology of dyspepsia in AIG is complex and involves changes in acid secretion, gastric motility, hormone signaling, and gut microbiota, among other factors. Managing dyspeptic symptoms of AIG is challenging and there are no specific therapies targeting dyspepsia in AIG. While proton pump inhibitors are commonly used to treat dyspepsia and gastroesophageal reflux disease, they may not be appropriate for AIG. Prokinetic agents, antidepressant drugs, and non-pharmacological treatments may be of help, even if not adequately evidence-based supported. A multidisciplinary approach for the management of dyspepsia in AIG is recommended, and further research is needed to develop and validate more effective therapies for dyspepsia.

Key Words: Dyspepsia; Dyspeptic symptoms; Gastro-intestinal symptoms; Autoimmune gastritis; Chronic autoimmune atrophic gastritis; Treatment

©The Author(s) 2023. Published by Baishideng Publishing Group Inc. All rights reserved.

Core Tip: The management of dyspepsia in patients with autoimmune gastritis (AIG), a chronic, immune-mediated disease, remains a challenge, as it can overlap with functional dyspepsia and gastroesophageal reflux disease. Currently, there are no specific therapies. A tailored treatment approach based on a better understanding of putative pathogenic mechanisms underlying symptoms is needed. Prokinetic agents, antidepressant drugs, and non-pharmacological treatments may be helpful, although not adequately evidence-based supported. As a future perspective, targeting dyspepsia in AIG based on changes in the microbiota and advanced endoscopic techniques to treat severe dyspeptic symptoms might be an area of ongoing research.

Citation: Rossi RE, Elvevi A, Sciola V, Mandarino FV, Danese S, Invernizzi P, Massironi S. Paradoxical association between dyspepsia and autoimmune chronic atrophic gastritis: Insights into mechanisms, pathophysiology, and treatment options. *World J Gastroenterol* 2023; 29(23): 3733-3747

URL: <https://www.wjgnet.com/1007-9327/full/v29/i23/3733.htm>

DOI: <https://dx.doi.org/10.3748/wjg.v29.i23.3733>

INTRODUCTION

Autoimmune gastritis (AIG) is an immune-mediated disease targeting the H⁺/K⁺ ATPase proton pump in the parietal cells, which are responsible for the secretion of gastric acid and intrinsic factor[1]. The pathogenesis of AIG involves the activation of both T and B lymphocytes, which infiltrate the gastric mucosa and destroy the parietal cells[1-5], leading to hypochloridria and vitamin B12 deficiency.

Symptoms of AIG can be nonspecific, with patients presenting with no or vague symptoms, including postprandial fullness, early satiation, abdominal pain, bloating[6], as well as epigastric pain. Therefore, the diagnosis of AIG can be challenging, as many of these symptoms overlap with other digestive disorders, mainly functional dyspepsia (FD) and gastroesophageal reflux disease (GERD). This overlap in clinical symptoms and characteristics can pose diagnostic challenges between AIG and FD, which share some common characteristics, including clinical symptoms, as well as a higher prevalence among women. Moreover, some patients may present with atypical symptoms, such as fatigue, joint pain, or skin rashes, which can further overlap with functional symptoms. Distinguishing between AIG and GERD can be even more challenging. While the pathophysiological mechanisms underlying GERD and AIG are different, they can present with similar abdominal symptoms, such as epigastric pain, heartburn, and nausea, which may pose diagnostic challenges, particularly in patients with atypical symptoms.

The pathophysiological mechanisms underlying clinical symptoms in AIG are poorly understood.

Appropriate evaluation, including endoscopy, is therefore required to differentiate these entities; indeed, based on the Rome Global Epidemiology Study, the diagnosis of FD requires the absence of organic, systemic, or metabolic disease upon routine investigation, including endoscopy[7,8].

It is therefore important to understand the different pathogenesis of symptoms in AIG, GERD, and FD, as the management of these conditions can be very different. This is particularly important when prescribing empirically proton pump inhibitors (PPIs) based therapies, which are often considered to be

the first-line therapy for GERD and are often used to manage symptoms of FD. Conversely, in AIG, a condition of hypochlorhydria, PPI therapy could further reduce acid secretion, stimulate gastrin hypersecretion, and further induce enterochromaffin-like (ECL) cell hyperplasia. As a result, the use of PPIs in patients with AIG is generally not indicated.

Therefore, accurate diagnosis and differentiation between these conditions are crucial to avoid inappropriate or potentially harmful management strategies. Understanding the pathophysiology of each condition can also guide the choice of appropriate treatments, including lifestyle modifications, dietary changes, and medication management.

In this review, we will discuss the putative pathogenic mechanisms underlying symptom generation in AIG, their clinical implications, and the current management strategies for this complex and multifaceted disease.

MATERIALS AND METHODS

An extensive bibliographical search was performed in PubMed to identify guidelines and primary literature (retrospective and prospective studies, systematic reviews, case series) published in the last 10 years, using both medical subject heading terms and free-language keywords: Dyspepsia; dyspeptic symptoms; gastro-intestinal symptoms; chronic autoimmune atrophic gastritis; diagnosis; treatment. The reference lists from the studies returned by the electronic search were manually searched to identify further relevant reports. The reference lists from all available review articles, primary studies, and proceedings of major meetings were also considered. Articles published as abstracts were included, whereas non-English language papers were excluded.

RESULTS

A total of 125 records were reviewed and 80 were defined as fulfilling the criteria for final consideration. [Figure 1](#) presents the flow chart showing the process of study selection.

DISCUSSION

Dyspepsia in autoimmune gastritis: clinical manifestations and pathophysiological mechanisms

The spectrum of clinical manifestations in AIG is wide but often nonspecific[9,10]. Classical manifestations of AIG include pernicious anemia due to vitamin B12 deficiency, which can cause fatigue, weakness, and shortness of breath. Other hematological anomalies comprise micro/normocytic anemia due to the coexistence of iron deficiency anemia[9,11]. Neurological symptoms such as tingling, numbness, or weakness in the limbs, are due to vitamin B12 deficiency and are characterized by neuronal damage with peripheral neuropathy, myelopathy, and autonomic dysfunction[12,13]. Furthermore, psychiatric alterations have been reported such as depression, cognitive impairment, and psychosis[14,15]. As AIG is often associated with other autoimmune conditions, patients may also present with symptoms related to those conditions, such as joint pain, skin rashes, or thyroid dysfunction[16]. Also, the impaired absorption of other vitamins, such as 25-OH-vitamin D, or micronutrients, such as calcium, due to gastric hypo- or achlorhydria, has been hypothesized to be a predisposing factor also for the development of osteoporosis which can be a possible further extra gastrointestinal (GI) manifestation in AIG patients[17-19].

However, these manifestations usually characterize severe or long-standing disease.

In the early stages of AIG, patients may not present with these specific symptoms, and the patients may begin to experience non-specific GI symptoms such as upper abdominal discomfort, bloating, and nausea[11]. Focusing on GI symptoms, even if AIG is generally regarded as a silent disease, some recent studies highlight a not negligible percentage of patients who report upper GI discomfort mainly characterized by dyspeptic and/or GERD symptoms[20] and as in FD, dyspeptic symptoms may manifest as postprandial distress syndrome (PDS) with early satiation and/or postprandial fullness or as epigastric pain syndrome (EPS).

Indeed, according to both data from literature and real-life clinical practice, dyspepsia is frequently reported by AIG patients, which represents a challenge for their proper management.

In the cross-sectional study by Carabotti *et al*[21], more than half of the patients affected by AIG (56.7%, 215 out of 397) reported GI symptoms with a prevalence of upper GI symptoms (69.8%) including dyspepsia (71.2%), described as postprandial fullness, early satiety and/or epigastric pain, GERD related symptoms (7.2%) such as heartburn and/or regurgitation, overlap dyspepsia-GERD symptoms (17.2%) and nausea and vomiting (3.8%). Moreover, 15.8% of the patients enrolled in this study also reported lower irritable bowel syndrome (IBS) -like GI symptoms with overlapping of upper and lower GI symptoms in 14.4% of the patients ([Figure 2](#)).

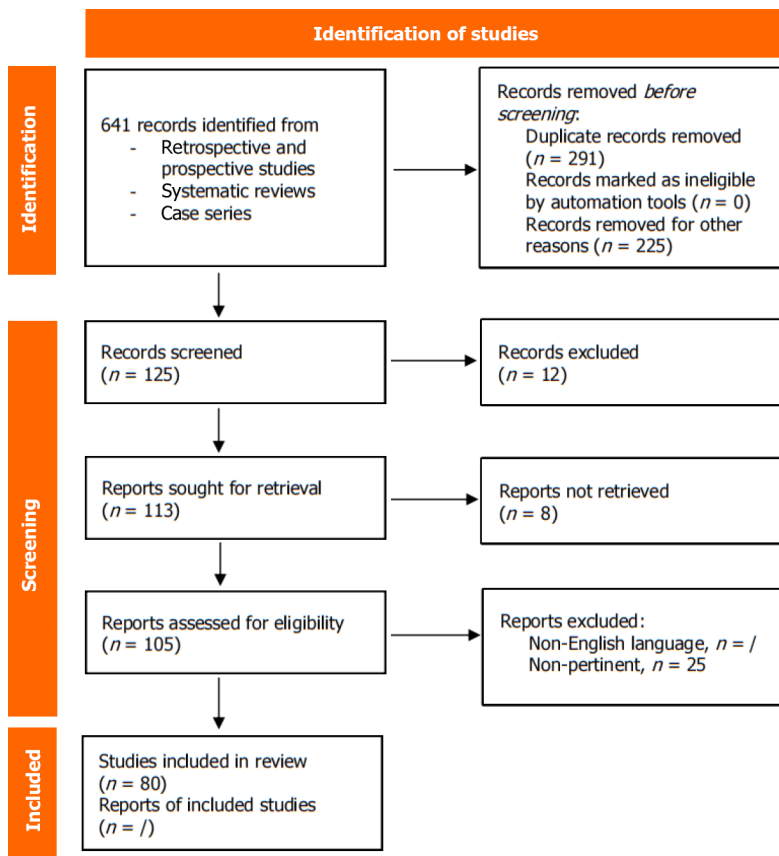


Figure 1 Flow chart showing the process of study selection.

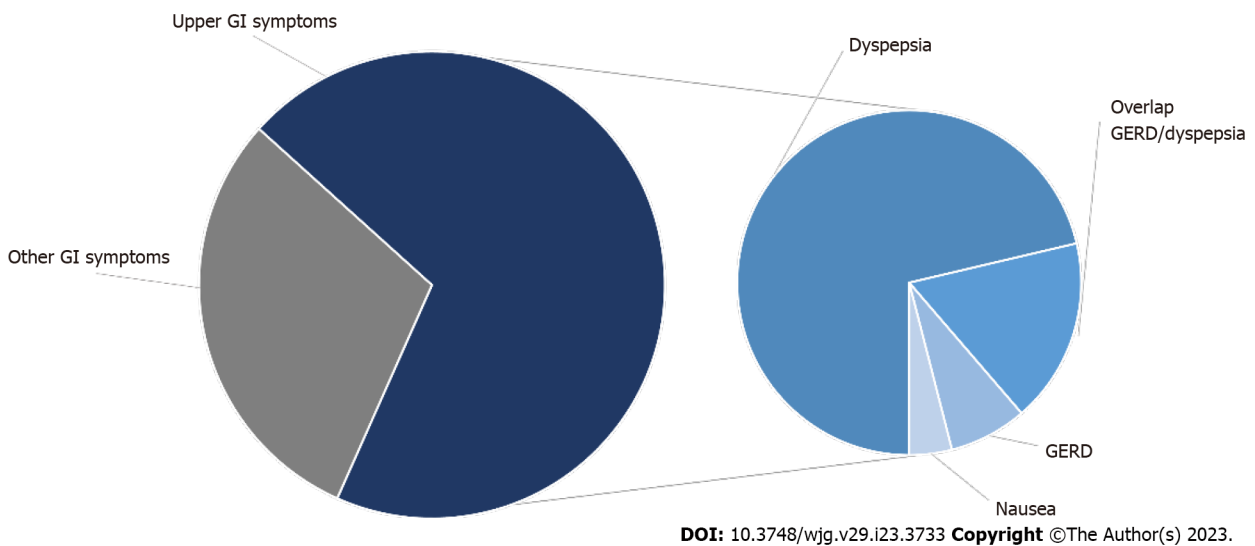


Figure 2 More common gastrointestinal symptoms seen in patients with autoimmune gastritis. GERD: Gastroesophageal reflux disease; GI: Gastrointestinal.

Dyspepsia, meant either as EPS or PDS, together with GERD symptoms such as acid regurgitation and heartburn, are reported as the most frequent symptoms also in the paper by Miceli *et al*[22] with a prevalence of 52.4% and 36.3%, respectively in the study population of 99 AIG patients. Contextually, weight loss and nausea are referred to approximately a quarter of patients (28.3% and 22.2%, respectively), while vomiting and dysphagia are in a lower percentage (9.1% and 3%, respectively).

According to another study[23], including a cohort of 54 patients with AIG, 70% were symptomatic for one or more upper GI symptoms, particularly a quarter of patients referred at least one typical GERD symptom such as regurgitation (18.5%) or heartburn (9%), while a major percentage complained

of atypical GERD symptoms including cough (29.6%), non-cardiac chest pain (22.2%) and dysphagia (14.8%).

As far as GERD symptom is concerned, in the prospective observational study published by Tenca *et al*[24], the prevalence of GERD has been investigated in a cohort of 41 AIG patients, 28 of whom with upper GI symptoms (53% GERD-related, 47% dyspepsia-like). The authors found that 24% of patients had GERD at multichannel intraluminal impedance-pH (MII-pH) monitoring mostly defined as non-acidic reflux, hypothesizing that non-acidic reflux could play a key role in the pathogenesis of the upper GI clinical manifestations. Consistent with the data above, those from the observational prospective study by Pilotto *et al*[25] confirm that among the group of AIG patients complaining of reflux symptoms (38/172, 22%) only 2 patients had documented GERD while 9 patients (24.7%) had reflux hypersensitivity predominantly related to non-acid-reflux (6/9 patients). The remaining 27 patients didn't have alterations at MII-pH but six of them had a major motility disorder. Therefore, the presence of upper GI symptoms appears to be paradoxical as AIG is typically characterized by gastric mucosal atrophy with resulting hypochlorhydria and alkaline gastric pH.

The pathophysiological mechanisms underlying GI symptoms in AIG are poorly understood. Several mechanisms have been hypothesized. The hypochlorhydria resulting from gastric oxyntic atrophy may contribute to dyspeptic symptoms[5], even if other mechanisms may be responsible, such as delayed gastric emptying[26,27], visceral hypersensitivity, and hormonal effects. Delayed gastric emptying may occur due to reduced acid secretion, which can lead to incomplete homogenization of gastric contents with macroscopic residues of undigested food and altered peristalsis, giving feelings of fullness, bloating, and discomfort after eating.

However, in patients with AIG, delayed gastric emptying has been described with elevated circulating gastrin levels and increase in parallel with the degree of the atrophy of the gastric mucosa, affecting gastric emptying T $\frac{1}{2}$ time[27]. Visceral hypersensitivity is an important candidate pathogenic mechanism for several disorders characterized by dyspepsia, even if only a few studies are available for AIG patients[26]. Moreover, some gut hormones such as motilin and ghrelin levels were significantly decreased in AIG subjects with delayed gastric emptying and deranged autonomic function[26], suggesting their potential role in the delayed gastric emptying observed in these subjects. Additionally, the loss of intrinsic factor may result in impaired absorption of nutrients such as iron and vitamin B12, which can contribute to fatigue and other symptoms. Also, low-grade chronic inflammation associated with AIG could contribute to the development of dyspepsia, in parallel to what is described for low-grade bowel inflammation with increased numbers of submucosal mast cells and lymphocytes reported in IBS[28]. Finally, chronic inflammation associated with AIG together with impaired gastric acid secretion may cause changes in the gut microbiota, and this may contribute to the development of dyspeptic symptoms; however, further research is needed to better understand the pathophysiological mechanisms underlying dyspeptic symptoms in AIG and to develop more effective treatments for this condition. It is also important to remember that abnormal thyroid function, which is quite commonly associated with AIG, has been blamed for gastric dysmotility and dyspeptic symptoms[29], which is another possible cause of dyspepsia in AIG patients. However, it is difficult to understand whether the dyspepsia observed in AIG patients is the direct result of abnormal thyroid function or is caused by AIG itself or by a combination of these two autoimmune diseases. **Table 1** summarizes the most frequent upper GI symptoms reported by AIG patients together with the underlying pathophysiological mechanisms.

Diagnostic work-up of dyspepsia in AIG

According to recent guidelines on the management of dyspepsia[30-32], upper GI endoscopy [esophagogastroduodenoscopy (EGDs)] is a key test to identify any organic disease of the upper digestive tract (*i.e.*, peptic ulcer, neoplasm), which may explain dyspeptic symptoms. Since EGDs is an invasive and expensive test and most patients with dyspepsia have FD[32], the American and British guidelines suggest limiting the use of EGDs to patients with suspected organic disease. Both the American and the British guidelines[30,32] as well as a recent evidence-based revision of the existing guidelines[31] suggest screening patients for past medical history and family history, medications, previous examinations, presence of *Helicobacter pylori* (*H. pylori*) infection, age, alarm symptoms and signs (*i.e.* anemia or bleeding, weight loss, age > 55 years, recurrent vomiting, dysphagia or odynophagia, fever). When one of the aforementioned alarm symptoms or signs is present, EGDs is mandatory to exclude or confirm an organic disease. If EGDs is negative for esophago-gastric diseases, an abdominal computed tomography -scan is suggested in order to exclude pancreatic, liver, or biliary tract cancers[32]. Distinguishing between AIG and FD in patients with dyspeptic symptoms may result difficult, as the two conditions can produce similar symptoms[20,21]. However, certain factors such as a medical history of autoimmune disease, anemia (including microcytic and macrocytic), vitamin B12 deficiency, and positivity for anti-parietal cells antibodies should raise clinical suspicion of AIG. In such cases, it is important to perform an EGDs to confirm the diagnosis, stage the disease, and evaluate for possible pre-cancerous lesions[33]. According to international guidelines[33], gastric biopsies should be picked up according to Sidney protocol. The protocol requires 5 gastric biopsies, which should be placed in separately labeled jars: 2 from the antrum along the lesser and greater curvature, within 2-3 cm of the pylorus; 2 from the gastric corpus (including 1 from the lesser curvature at 4 cm proximal to the incisura angularis and the

Table 1 Reported upper gastrointestinal symptoms and the underlying pathophysiological mechanisms in patients with autoimmune atrophic gastritis

Clinical manifestation	Pathophysiological mechanisms
Dyspeptic symptoms	
Postprandial fullness; Early satiety; Epigastric pain	Hypochlorhydria. Delayed gastric emptying due to: Hormonal effects (ghrelin, motilin); Reduced acid secretion. Visceral hypersensitivity. Low-grade chronic inflammation. Changes in the gut microbiota
Typical GER like symptoms	
Heartburn; Regurgitation	Non-acid reflux; Delayed gastric emptying; Visceral hypersensitivity; Changes in the gut microbiota
Atypical GERD-like symptoms	
Cough; Non-cardiac chest pain; Dysphagia	Delayed gastric emptying; Visceral hypersensitivity
Overlap dyspepsia-GER like symptoms	As above
Vomiting	Delayed gastric emptying; Visceral hypersensitivity
Nausea	Delayed gastric emptying
Fatigue	Impaired absorption of iron and vitamin B12

GER: Gastro-esophageal reflux; GERD: Gastroesophageal reflux disease.

other from the middle portion of the greater curvature of the gastric body at 8 cm from the cardia), and 1 from the incisura angularis[34]. Severity and topographic distribution of atrophic lesions should be reported according to Operative Link for Gastritis Assessment (OLGA)[35] and Operative Link for Gastric Intestinal Metaplasia Assessment (OLGIM)[36]. By following this protocol, it is less likely to miss the diagnosis of AIG. Moreover, OLGA e OLGIM scores are then used to determine whether endoscopic surveillance is needed and its frequency. Conversely, if there is no suspicion of organic disease, FD could be diagnosed. However, even in these cases, both the American and British guidelines[30,32] suggest testing dyspeptic patients for *H. pylori* with non-invasive tests (*i.e.* fecal antigen or carbon-urea breath testing) and treating the infected ones accordingly, as *H. pylori* infection is considered to be an etiologic factor of dyspepsia in 5% of dyspeptic patients[37].

In case of PDS, with dyspeptic symptoms that recall altered gastric emptying, gastric emptying scintigraphy (GES) is a useful tool to explore impaired (rapid or delayed) gastric dysmotility. Briefly, the test consists of a standard meal, which is marked with Technetium (Tc)-99m; after food ingestion, imaging is performed in the anterior and posterior projections at only four-time points (0, 1, 2, and 4 h). Delayed gastric emptying is determined to be > 90% at 1 h, > 60% at 2 h, and > 10% gastric retention at 4 h. Conversely, rapid gastric emptying is determined to be < 30% at 1 h[38]. While GES performs well in diagnosing gastroparesis[39], it is not reliable for the diagnosis of FD, which is supposed to be a lighter spectrum of the same gastric disorders[40], and no specific studies exist for AIG, therefore further studies are needed to clarify this item[39]. However, this technique can be time-consuming, as the test requires imaging at set intervals over several hours, it involves radiation exposure from the radioactive material in the meal and, as for FD, also in the case of AIG, it may not be reliable, as there is only a milder form of a gastric motility disorder. Moreover, it appears to have limited therapeutic implications, as it may suggest treating the patient with prokinetic drugs at most, which can also be done ex adjuvantibus. Recently, the wireless motility capsule (WMC) has been introduced, in order to simultaneously assess both regional and whole gut transit[41,42]. Ingestion of this non-digestible capsule that simultaneously measures luminal temperature, pH, and pressure facilitates the measurement of the gastric, small bowel, and colonic transit times. Approved by the United States Food and Drug Administration for the evaluation of gastroparesis and slow colonic transit, WMC should be considered in suspected GI motility disorders as it provides a single study capable of simultaneously assessing for regional, multi-regional, or generalized motility disorders[43]. Triadafilopoulos *et al*[43] suggested a potential WMC role in AIG diagnosis since it is able to register intragastric pH (usually > 6) and eventually associated dysmotility[43]. However, as for GES, even for WMC at present, considering the limited availability of prokinetic drugs, therapeutic implications are limited. Finally, a recent physiologic tool has been proposed to assess the functionality of the pyloric sphincter. The functional luminal imaging probe known as EndoFlip® is a 240-cm catheter with impedance electrodes at its distal end[44,45], that is used to assess the functionality of the pyloric sphincter. The device is placed in the pylorus either through the endoscope, under endoscopic visualization[45], or either by fluoroscopy guidance[46]. After positioning the device, the balloon is filled to set volumes of 10, 20, 30, 40, and 50 mL using a stepwise protocol, and the cross-sectional area (CSA), bag pressure, and distensibility index are recorded. The pyloric distensibility index (P-DI) is calculated in the zone with the narrowest CSA

with the corresponding intra-bag pressure[46]. A decreased P-DI has been observed in patients with gastroparesis[47], and also in patients with chronic nausea and vomiting without delayed gastric emptying, suggesting that pyloric dysfunction could explain “gastroparesis-like” symptoms in this group of patients[48]. However, normal and pathological values still need to be confirmed.

As mentioned above, GERD symptoms are frequently reported by AIG patients[24,25]. According to recent guidelines[49] and Lyon consensus[50], GERD is usually a clinical diagnosis, based on patients’ symptoms (typical GERD symptoms, pyrosis, and acidic regurgitation) and empiric proton pump inhibitors (PPIs) treatment response (*i.e.* single dose for 4-8 wk).

Since AIG patients are supposed to have a higher intragastric pH (registered in one study, being median intragastric pH of 6.2 (4.6-7.0)[24], due to parietal cells atrophy, it may be surprising that AIG patients complain of GERD symptoms. A previous paper by Tenca *et al*[24] registered that 15 out of 41 AIG patients had GERD symptoms. Among them, acidic reflux, recorded by MII-pH monitoring, had a minor role, being present in one patient only. This could be explained by the residual production of acid from partially atrophic mucosa. Non-acidic reflux was instead more frequent, being present in 22% of the AIG population studied. It is common knowledge that non-acidic reflux can give rise to typical or atypical GERD symptoms[51-53].

Moreover, it could be useful to study these patients with MII-pH-monitoring, which is able to identify acidic, weakly acidic, and non-acidic reflux events. The observation of a role of GERD in these patients’ symptoms independently of acid is clinically relevant because it can guide their management. These patients may benefit from drugs that lower their visceral sensitivity (*i.e.*, tricyclic antidepressants and selective serotonin reuptake inhibitors)[7,54]. Furthermore, for those with severe drug-unresponsive symptoms anti-reflux surgery is an option[55,56]. Another study by Pilotto *et al*[25] characterizes AIG patients according to their GERD symptoms and MII-pH-monitoring results. Similarly, Tenca *et al*[24] found pathologic esophageal acid exposure in two out of 38 patients reporting GERD symptoms. On the contrary, a great part of them (30 out of 38 patients) had an increased number of non-acidic reflux episodes. Combining symptoms and MII-pH-monitoring results, the Authors classified AIG patients as having GERD (5%), functional heartburn (50%), and reflux hypersensitivity (24%). Interestingly, the Authors studied AIG patients with high-resolution esophageal manometry (HRM) and found that 37% of AIG patients had various motility disorders, including 8 minor disorders ($n = 7$ weak peristalsis and $n = 1$ hypertensive peristalsis), and 6 major disorders ($n = 6$ EGI outflow obstruction) according to Chicago classification v 3.0[57]. Whether these manometric findings correlate with AIG is still debated. Similarly, the role of HRM in the diagnostic work-up of these patients remains unclear. MII-pH-monitoring could also have a role in the diagnosis of dyspepsia. It is known from the literature that epigastric pain is often more frequent in patients with pathologic MII-pH-monitoring[58]. In the population studied by Tenca *et al*[24], two dyspeptic patients showed a positive correlation between epigastric pain and non-acidic reflux. A possible diagnostic algorithm is represented in Figure 3.

In summary, dyspeptic symptoms and GERD are common in AIG patients; the diagnostic algorithm provides an EGDs study as the first diagnostic test to exclude organic disease and to confirm AIG diagnosis. If GERD symptoms are present, MII-pH-monitoring is useful to measure the entity of reflux and to classify patients (GERD, functional heartburn, hypersensitive esophagus) and treat them accordingly. Moreover, it could be useful in dyspepsia diagnosis. Esophageal motility tests, as well as gastric emptying tests, could have a role in AIG patients but further studies are needed to clarify these items.

Treatment

Dyspepsia is a common symptom in AIG and its management can be challenging, as the pathophysiology underlying dyspeptic symptoms in AIG is multifactorial. However, this issue is still understudied, and more research is needed to better understand the mechanisms of dyspepsia in AIG and to develop effective treatments tailored to the individual patient’s symptoms and underlying pathophysiology. Indeed, although the primary goal of AIG treatment is to address vitamin deficiencies and prevent and monitor for gastric neoplasms, effectively managing common and difficult-to-treat symptoms like dyspepsia is crucial for improving patients’ quality of life.

As a matter of fact, according to available guidelines[10], there is poor evidence regarding the best treatment options for dyspeptic symptoms in patients with AIG, also considering that PPIs are not indicated in this subset of patients who are typically hypochlorhydric. Despite this, several AIG patients referring dyspeptic symptoms are often prescribed PPIs by General Practitioners or gastroenterologists with no or low knowledge of this disease. The use of PPIs in this subgroup of patients should be discouraged for two main reasons. Firstly, AIG is characterized by a suppressed gastric acid secretion and consequent hypochlorhydria, thus treatment with antisecretory drugs is generally ineffective as already reported[24,59] taking into account that these patients refer reflux-like symptoms whose nature is non-acid. Secondly, and far more important, the long-term use of PPIs has been reported to be associated with the development or progression of gastric pre-malignant lesions. Of note, as already reported[60], the long-term treatment with PPIs which is responsible for increased levels of serum gastrin seems to be linked to a higher risk of progression of ECL-cell hyperplasia which precedes the development of gastric type 1 neuroendocrine neoplasm[61]; however, no clear-cut evidence was found between PPI therapy and increased progression of AIG or intestinal metaplasia[60].

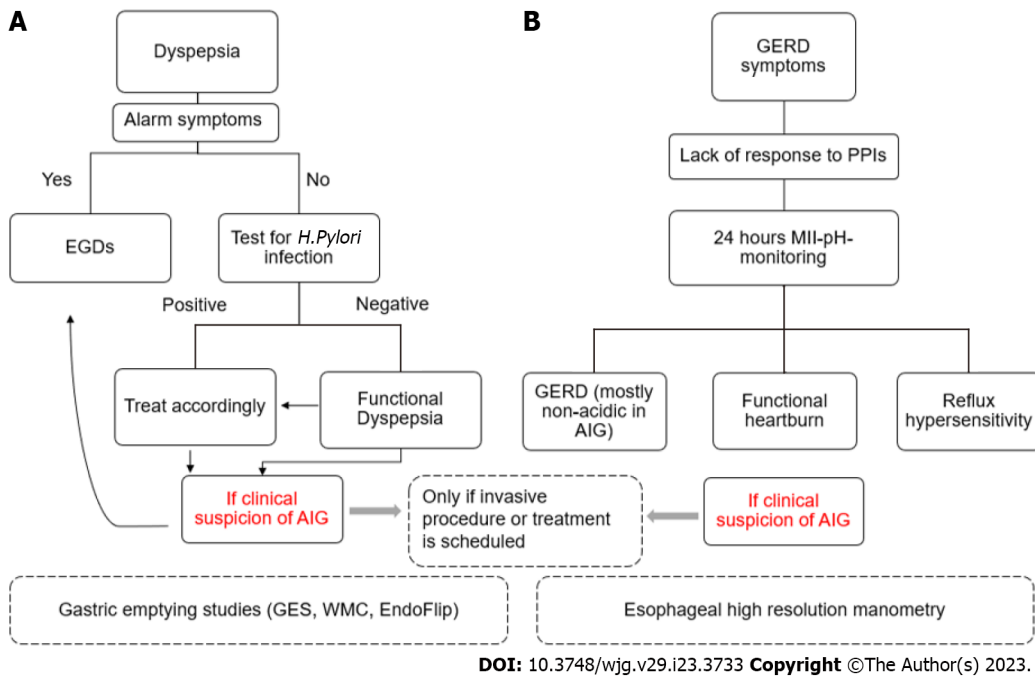


Figure 3 Possible diagnostic algorithm for dyspepsia or gastroesophageal reflux disease -like symptoms in autoimmune atrophic gastritis. A: Dyspeptic symptoms; B: Gastroesophageal reflux disease symptoms. AIG: Autoimmune gastritis; EGDs: Esophagogastroduodenoscopy; GERD: Gastroesophageal reflux disease; GI: Gastrointestinal; *H. pylori*: *Helicobacter pylori*; PPIs: Proton pump inhibitors.

Initial management of dyspepsia in AIG may involve dietary modifications, such as avoiding trigger foods or eating smaller, more frequent meals. Patients may also benefit from lifestyle modifications, such as weight loss or stress reduction techniques, even if these procedures are not evidence-supported.

It is important to highlight that patients with AIG often have evidence of current or prior *H. pylori* infection[62]. Therefore, it is important to test these patients for *H. pylori* and, if positive, to eradicate it according to guidelines that suggested the “Test and treat” strategy[63]. Of note, *H. pylori* eradication appears to reduce the risk of gastric cancer[64]. In the specific setting of AIG, according to a randomized double-blinded placebo-controlled trial[65], that compared triple eradication therapy for *H. pylori* with placebo in histologically diagnosed AIG patients, at 3-years follow-up dyspeptic symptoms scores improved significantly in the patients in whom *H. pylori* had been eradicated. Similar findings were reported by another recent study[66], which showed that the beneficial effect of *H. pylori* eradication treatment on dyspeptic symptoms lasted until one year after treatment, being associated with a higher pretreatment symptom score and age inferior to 70 years old. Obviously, the benefit of *H. pylori* eradication in AIG patients is further increased by the fact that *H. pylori* more than autoimmunity per se, is linked to the risk of evolution towards dysplasia and gastric cancer in AIG, as recently described[1].

In addition to *H. pylori* eradication, several treatment options[67] have been investigated for their efficacy in managing dyspeptic symptoms in AIG. These treatments include prokinetic agents, neuromodulators, and herbal agents, as well as non-pharmacological treatments such as acupuncture, cognitive-behavioral therapy, and hypnotherapy. However, the evidence regarding their effectiveness is conflicting also taken into account the lack of dedicated prospective studies exploring the efficacy of prokinetics and neuromodulators in this specific setting of patients, making the management of AIG patients experiencing dyspeptic symptoms very challenging. Medications such as prokinetic agents including metoclopramide or domperidone may be used to improve gastric motility and reduce symptoms of bloating and nausea in patients with predominantly PDS symptoms. For patients presenting with EPS symptoms, a rational approach could therefore be to guide therapy based on the altered pathophysiological mechanism. As mentioned before, 24-h MII-pH-monitoring may be a useful tool to classify AIG patients having GERD symptoms. If MII-pH-monitoring found true acidic GERD, PPIs treatment could have a role. Being this an extremely rare condition, there are no clear-cut recommendations on treatment dosage and duration. Conversely, if MII-pH-impedance diagnoses a non-acidic reflux disease, as well as functional heartburn and reflux hypersensitivity, these patients may benefit from drugs that lower their visceral sensitivity (*i.e.* tricyclic antidepressants and selective serotonin reuptake inhibitors)[7,54]. Moreover, patients who did not respond to medical treatment as well as patients with a high burden of non-acidic reflux, may benefit from anti-reflux surgery[55,56].

In cases where dyspepsia is associated with underlying anxiety or depression, treatment with antidepressants or anxiolytics may be warranted[7,54]. However, future research is needed to identify more effective treatments for dyspepsia in AIG and to better understand the underlying mechanisms that drive dyspeptic symptoms in this condition.

Furthermore, a known consequence of atrophic gastritis-related hypochlorhydria and/or achlorhydria is a change in the gastric microbiome composition. However, there are currently no specific therapies targeting dyspepsia in AIG based on changes in the microbiota, even if an abnormally elevated presence of endoluminal bacteria which produce acetaldehyde from glucose metabolism has been described[68]. Again, according to some authors[69,70], L-cysteine, a non-essential amino acid, can modify the microenvironment of the achlorhydric stomach by both inactivating acetaldehyde and promoting recovery of gastric function[71,72]; furthermore, there is some anecdotal evidence that L-cysteine might improve functional symptoms often associated with atrophic gastritis. Based on these observations, Di Mario *et al*[73] recently conducted a study including a total of 330 patients with atrophic gastritis (both autoimmune or *H. pylori*-related), who were divided into two groups, treated with long-term L-cysteine and no specific treatment, respectively, and reported a significant improvement in the symptom scores of patients treated with L-cysteine when compared to the non-treated group. Of note, symptom improvement lasted all the two years of the follow-up. One limitation of this study is the inclusion of different etiologies from atrophic gastritis, which might be responsible for a certain grade of heterogeneity. While research into the gut microbiota and its role in AIG is ongoing[74, 75], some studies suggest that probiotics and prebiotics may have a role in modulating the gut microbiota and reducing symptoms in patients with dyspepsia, including those with AIG[76,77]. Overall, while the potential for microbiota-based therapies in managing dyspepsia in AIG is promising, further research is needed to develop and validate such approaches.

Finally, further treatment may be available in the near future. Gastric per-oral endoscopic myotomy (G POEM) is a novel endoscopic procedure that has shown promising results in the management of refractory gastroparesis[78]. This technique has received increasing attention and emerged as a promising treatment for refractory gastroparesis, targeting the pylorus[79], as a result of the use of new tools to identify pyloric dysfunction in routine care, including functional luminal impedance planimetry (FLIP). The procedure involves creating a myotomy or an incision in the inner lining of the stomach, thereby allowing for better gastric emptying. Since AIG patients with PDS may have the same functional dysfunction of patients affected by gastroparesis, both from a pathophysiological and clinical point of view, G POEM may represent a feasible treatment for AIG patients with severe dyspeptic symptoms, which did not respond to medical treatment. Even if it is considered a safe procedure, a potential concern associated with G POEM is the risk of complications, such as bleeding, perforation, and infection[80]. Additionally, the long-term outcomes of G POEM are still unclear, and more studies are needed to assess its durability and impact on patient quality of life. Recently, Mandarino *et al*[81] found that a lower Intra-gastric Meal Distribution at pre-intervention gastric emptying study, which indicates antral food retention, could be associated with post-procedural functional success, defined as a decrease of more than 30% 2-h retention. However, further data are needed to establish long-term efficacy of endoscopic pyloromyotomy, especially in the management of dyspeptic AIG patients.

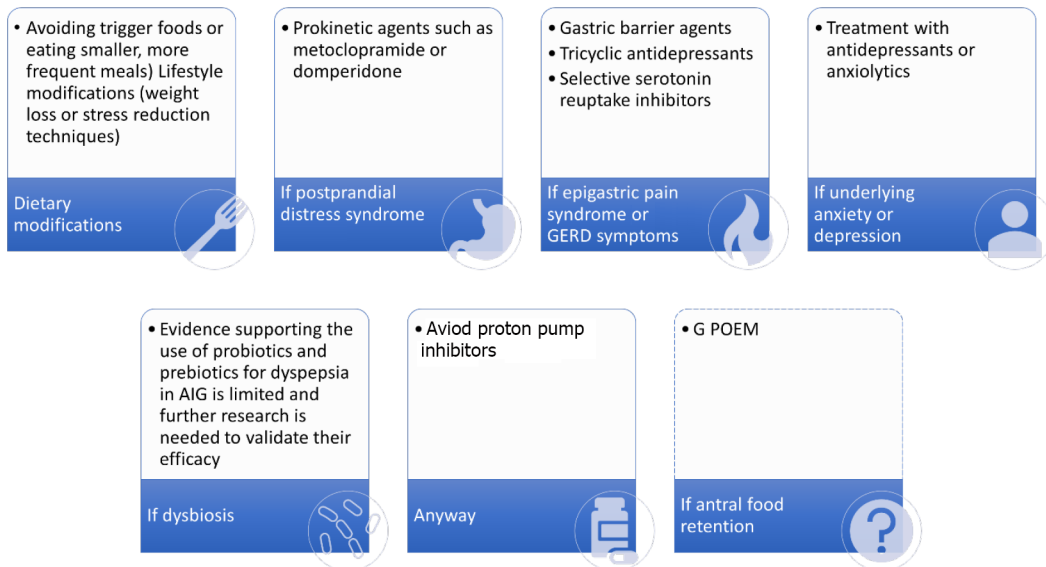
CONCLUSION

AIG can cause a range of clinical manifestations, including dyspepsia. Accurate diagnosis and appropriate management of dyspepsia in AIG are important to improve the patient's quality of life, as well as to prevent and monitor for potential complications such as vitamin deficiencies and gastric neoplasms. The pathophysiology of dyspepsia in AIG is complex and involves changes in acid secretion, gastric motility, hormone signaling, and gut microbiota, among other factors. Specifically, investigating the role of visceral hypersensitivity, impaired gastric accommodation, and impaired gastric motility in AIG-related dyspepsia may help to identify new targets for treatment.

Managing dyspeptic symptoms of AIG is challenging and there are no specific therapies targeting dyspepsia in AIG. While PPIs are commonly used to treat dyspepsia and GERD, they may not be appropriate for AIG, as the condition is already characterized by hypochlorhydria. Instead, prokinetic agents, antidepressant drugs, and non-pharmacological treatments may be of help, even if not adequately evidence-based supported.

Targeting dyspepsia in AIG based on changes in the microbiota is an area of ongoing research and some studies suggest that probiotics and prebiotics may have a role in reducing symptoms. G POEM may represent a feasible treatment for AIG patients with severe dyspeptic symptoms, even if more research is needed to establish its safety and efficacy in this specific setting of patients. **Figure 4** summarizes the possible therapeutic approaches for dyspeptic or with GERD-like symptoms in patients with AIG.

Overall, a multidisciplinary approach for the management of dyspepsia in AIG is recommended, and further research is needed to develop and validate more effective therapies for dyspepsia in AIG, as well as to better understand the underlying pathophysiology of the disease; GERD: Gastroesophageal reflux disease.



DOI: 10.3748/wjg.v29.i23.3733 Copyright ©The Author(s) 2023.

Figure 4 Therapeutic approaches for dyspeptic or with gastroesophageal reflux disease-like symptoms in patients with autoimmune gastritis. AIG: Autoimmune gastritis; G POEM: Gastric per-oral endoscopic myotomy; GERD: Gastroesophageal reflux disease.

ARTICLE HIGHLIGHTS

Research background

Gastrointestinal symptoms such as dyspepsia and early satiety are very common in autoimmune gastritis (AIG), being second in terms of frequency only to anemia, which is the most typical feature of AIG. Understanding the pathophysiology of each condition can also guide the choice of appropriate treatments, including lifestyle modifications, dietary changes, and medication management.

Research motivation

The management of dyspepsia in patients with AIG, a chronic, immune-mediated disease, remains a challenge, as it can overlap with functional dyspepsia and gastroesophageal reflux disease. Currently, there are no specific therapies. A tailored treatment approach based on a better understanding of putative pathogenic mechanisms underlying symptoms is needed.

Research objectives

In this review, we will discuss the putative pathogenic mechanisms underlying symptom generation in AIG, their clinical implications, and the current management strategies for this complex and multi-faceted disease.

Research methods

An extensive bibliographical search was performed in PubMed to identify guidelines and primary literature (retrospective and prospective studies, systematic reviews, case series) published in the last 10 years, using both medical subject heading terms and free-language keywords: Dyspepsia; dyspeptic symptoms; gastro-intestinal symptoms; chronic autoimmune atrophic gastritis; diagnosis; treatment.

Research results

A total of 125 records were reviewed and 80 were defined as fulfilling the criteria.

Research conclusions

AIG can cause a range of clinical manifestations, including dyspepsia. The pathophysiology of dyspepsia in AIG is complex and involves changes in acid secretion, gastric motility, hormone signaling, and gut microbiota, among other factors. Managing dyspeptic symptoms of AIG is challenging and currently, there are no specific therapies. A tailored treatment approach based on a better understanding of putative pathogenic mechanisms underlying symptoms is needed. While proton pump inhibitors are commonly used to treat dyspepsia and GERD, they may not be appropriate for AIG. Prokinetic agents, antidepressant drugs, and non-pharmacological treatments may be of help, even if not adequately evidence-based supported. A multidisciplinary approach for the management of dyspepsia in AIG is recommended, and further research is needed to develop and validate more effective therapies for dyspepsia.

Research perspectives

As a future perspective, targeting dyspepsia in AIG based on changes in the microbiota and advanced endoscopic techniques to treat severe dyspeptic symptoms might be an area of ongoing research.

FOOTNOTES

Author contributions: Massironi S conceived the idea for the review; Rossi RE, Elvevi A, Sciola V, and Mandarino FV conducted the literature search; Rossi RE, Elvevi A, and Sciola V screened the articles for inclusion and exclusion criteria; Rossi RE, Sciola V, and Elvevi A wrote the initial draft of the manuscript; Massironi S, Mandarino FV, Danese S, and Invernizzi P contributed to revising the manuscript critically for important intellectual content and finally all authors approved the final version for submission.

Conflict-of-interest statement: All the authors declare no conflict of interests for this article.

PRISMA 2009 Checklist statement: The authors have read the PRISMA 2009 Checklist, and the manuscript was prepared and revised according to the PRISMA 2009 Checklist.

Open-Access: This article is an open-access article that was selected by an in-house editor and fully peer-reviewed by external reviewers. It is distributed in accordance with the Creative Commons Attribution NonCommercial (CC BY-NC 4.0) license, which permits others to distribute, remix, adapt, build upon this work non-commercially, and license their derivative works on different terms, provided the original work is properly cited and the use is non-commercial. See: <https://creativecommons.org/licenses/by-nc/4.0/>

Country/Territory of origin: Italy

ORCID number: Roberta Elisa Rossi 0000-0003-4208-4372; Alessandra Elvevi 0000-0001-9841-2051; Francesco Vito Mandarino 0000-0002-9931-7221; Silvio Danese 0000-0001-7341-1351; Pietro Invernizzi 0000-0003-3262-1998; Sara Massironi 0000-0003-3214-8192.

S-Editor: Liu JH

L-Editor: A

P-Editor: Yuan YY

REFERENCES

- Rugge M, Bricca L, Guzzinati S, Sacchi D, Pizzi M, Savarino E, Farinati F, Zorzi M, Fassan M, Dei Tos AP, Malfertheiner P, Genta RM, Graham DY. Autoimmune gastritis: long-term natural history in naïve Helicobacter pylori-negative patients. *Gut* 2023; **72**: 30-38 [PMID: 35772926 DOI: 10.1136/gutjnl-2022-327827]
- Autoimmune gastritis. *Nat Rev Dis Primers* 2020; **6**: 57 [PMID: 32647157 DOI: 10.1038/s41572-020-0198-5]
- Massironi S, Zilli A, Elvevi A, Invernizzi P. The changing face of chronic autoimmune atrophic gastritis: an updated comprehensive perspective. *Autoimmun Rev* 2019; **18**: 215-222 [PMID: 30639639 DOI: 10.1016/j.autrev.2018.08.011]
- Lenti MV, Annibale B, Di Sabatino A, Lahner E. Editorial: Dissecting the immunological, pathological, and clinical aspects of autoimmune gastritis and its neoplastic complications. *Front Immunol* 2022; **13**: 1070250 [PMID: 36389672 DOI: 10.3389/fimmu.2022.1070250]
- Neumann WL, Coss E, Rugge M, Genta RM. Autoimmune atrophic gastritis--pathogenesis, pathology and management. *Nat Rev Gastroenterol Hepatol* 2013; **10**: 529-541 [PMID: 23774773 DOI: 10.1038/nrgastro.2013.101]
- Hall SN, Appelman HD. Autoimmune Gastritis. *Arch Pathol Lab Med* 2019; **143**: 1327-1331 [PMID: 31661309 DOI: 10.5858/arpa.2019-0345-RA]
- Broeders BWLCM, Carbone F, Balsiger LM, Schol J, Raymenants K, Huang I, Verheyden A, Vanuytsel T, Tack J. Review article: Functional dyspepsia-a gastric disorder, a duodenal disorder or a combination of both? *Aliment Pharmacol Ther* 2023; **57**: 851-860 [PMID: 36859629 DOI: 10.1111/apt.17414]
- Wauters L, Dickman R, Drug V, Mulak A, Serra J, Enck P, Tack J; ESNM FD Consensus Group, Accarino A, Barbara G, Bor S, Coffin B, Corsetti M, De Schepper H, Dumitrascu D, Farmer A, Gourcerol G, Hauser G, Hausken T, Karamanolis G, Keszthelyi D, Malagelada C, Milosavljevic T, Muris J, O'Morain C, Papathanasopoulos A, Pohl D, Romyantseva D, Sarnelli G, Savarino E, Schol J, Sheptulin A, Smet A, Stengel A, Storonova O, Storr M, Törblom H, Vanuytsel T, Velosa M, Waluga M, Zarate N, Zerbib F. United European Gastroenterology (UEG) and European Society for Neurogastroenterology and Motility (ESNM) consensus on functional dyspepsia. *United European Gastroenterol J* 2021; **9**: 307-331 [PMID: 33939891 DOI: 10.1002/ueg2.12061]
- Rustgi SD, Bijlani P, Shah SC. Autoimmune gastritis, with or without pernicious anemia: epidemiology, risk factors, and clinical management. *Therap Adv Gastroenterol* 2021; **14**: 17562848211038771 [PMID: 34484423 DOI: 10.1177/17562848211038771]
- Lahner E, Zagari RM, Zullo A, Di Sabatino A, Meggio A, Cesaro P, Lenti MV, Annibale B, Corazza GR. Chronic atrophic gastritis: Natural history, diagnosis and therapeutic management. A position paper by the Italian Society of Hospital Gastroenterologists and Digestive Endoscopists [AIGO], the Italian Society of Digestive Endoscopy [SIED], the

- Italian Society of Gastroenterology [SIGE], and the Italian Society of Internal Medicine [SIMI]. *Dig Liver Dis* 2019; **51**: 1621-1632 [PMID: 31635944 DOI: 10.1016/j.dld.2019.09.016]
- 11 **Rodriguez-Castro KI**, Franceschi M, Noto A, Miraglia C, Nouvenne A, Leandro G, Meschi T, De' Angelis GL, Di Mario F. Clinical manifestations of chronic atrophic gastritis. *Acta Biomed* 2018; **89**: 88-92 [PMID: 30561424 DOI: 10.23750/abm.v89i8-S.7921]
 - 12 **Yang GT**, Zhao HY, Kong Y, Sun NN, Dong AQ. Correlation between serum vitamin B12 level and peripheral neuropathy in atrophic gastritis. *World J Gastroenterol* 2018; **24**: 1343-1352 [PMID: 29599609 DOI: 10.3748/wjg.v24.i12.1343]
 - 13 **O'Leary F**, Samman S. Vitamin B12 in health and disease. *Nutrients* 2010; **2**: 299-316 [PMID: 22254022 DOI: 10.3390/nu2030299]
 - 14 **Wu H**, Liang G, Kong M, Zhang Y, Zhou Y, Han J, Hu X, Li Y, Zhan Q, Chen S, Du Y, Chen W. The status and risk factors for anxiety/depression in patients with atrophic chronic gastritis: a cross-sectional study. *Ann Palliat Med* 2022; **11**: 3147-3159 [PMID: 36096741 DOI: 10.21037/apm-22-730]
 - 15 **Miceli E**, Brondino N, Lenti MV, Di Stefano M, Staiani M, Zugnoni F, Pisati M, Caccia Dominioni C, Corazza GR, Politi P, Di Sabatino A. Impaired Quality of Life in Patients with Autoimmune Atrophic Gastritis. *Dig Dis Sci* 2021; **66**: 3322-3329 [PMID: 33098024 DOI: 10.1007/s10620-020-06656-x]
 - 16 **Utiyama SRR**, De Bem RS, Skare TL, De Carvalho GA, Teixeira LM, Bertolazo M, Ioshii SO, Nisihara R. Anti-parietal cell antibodies in patients with autoimmune thyroid diseases. *J Endocrinol Invest* 2018; **41**: 523-529 [PMID: 28929353 DOI: 10.1007/s40618-017-0755-2]
 - 17 **Kim HW**, Kim YH, Han K, Nam GE, Kim GS, Han BD, Lee A, Ahn JY, Ko BJ. Atrophic gastritis: a related factor for osteoporosis in elderly women. *PLoS One* 2014; **9**: e101852 [PMID: 25003598 DOI: 10.1371/journal.pone.0101852]
 - 18 **Goerss JB**, Kim CH, Atkinson EJ, Eastell R, O'Fallon WM, Melton LJ 3rd. Risk of fractures in patients with pernicious anemia. *J Bone Miner Res* 1992; **7**: 573-579 [PMID: 1615763 DOI: 10.1002/jbmr.5650070514]
 - 19 **Massironi S**, Cavalcoli F, Zilli A, Del Gobbo A, Ciafardini C, Bernasconi S, Felicetta I, Conte D, Peracchi M. Relevance of vitamin D deficiency in patients with chronic autoimmune atrophic gastritis: a prospective study. *BMC Gastroenterol* 2018; **18**: 172 [PMID: 30409113 DOI: 10.1186/s12876-018-0901-0]
 - 20 **Lenti MV**, Rugge M, Lahner E, Miceli E, Toh BH, Genta RM, De Block C, Hershko C, Di Sabatino A. Autoimmune gastritis. *Nat Rev Dis Primers* 2020; **6**: 56 [PMID: 32647173 DOI: 10.1038/s41572-020-0187-8]
 - 21 **Carabotti M**, Lahner E, Esposito G, Sacchi MC, Severi C, Annibale B. Upper gastrointestinal symptoms in autoimmune gastritis: A cross-sectional study. *Medicine (Baltimore)* 2017; **96**: e5784 [PMID: 28072728 DOI: 10.1097/MD.0000000000005784]
 - 22 **Miceli E**, Lenti MV, Padula D, Luinetti O, Vattiato C, Monti CM, Di Stefano M, Corazza GR. Common features of patients with autoimmune atrophic gastritis. *Clin Gastroenterol Hepatol* 2012; **10**: 812-814 [PMID: 22387252 DOI: 10.1016/j.cgh.2012.02.018]
 - 23 **Carabotti M**, Esposito G, Lahner E, Piloizzi E, Conti L, Ranazzi G, Severi C, Bellini M, Annibale B. Gastroesophageal reflux symptoms and microscopic esophagitis in a cohort of consecutive patients affected by atrophic body gastritis: a pilot study. *Scand J Gastroenterol* 2019; **54**: 35-40 [PMID: 30638085 DOI: 10.1080/00365521.2018.1553062]
 - 24 **Tenca A**, Massironi S, Pugliese D, Consonni D, Mauro A, Cavalcoli F, Franchina M, Spampatti M, Conte D, Penagini R. Gastro-esophageal reflux and antisecretory drugs use among patients with chronic autoimmune atrophic gastritis: a study with pH-impedance monitoring. *Neurogastroenterol Motil* 2016; **28**: 274-280 [PMID: 26568317 DOI: 10.1111/nmo.12723]
 - 25 **Pilotto V**, Maddalo G, Orlando C, Fassan M, Rugge M, Farinati F, Savarino EV. Objective Evidence of Gastro-Esophageal Reflux Disease is Rare in Patients with Autoimmune Gastritis. *J Gastrointest Liver Dis* 2021; **30**: 30-36 [PMID: 33723550 DOI: 10.15403/jgld-3033]
 - 26 **Kalkan Ç**, Soykan I. The Relations Among Serum Ghrelin, Motilin and Gastric Emptying and Autonomic Function in Autoimmune Gastritis. *Am J Med Sci* 2018; **355**: 428-433 [PMID: 29753372 DOI: 10.1016/j.amjms.2017.12.021]
 - 27 **Kalkan Ç**, Soykan I, Soydal Ç, Özkan E, Kalkan E. Assessment of Gastric Emptying in Patients with Autoimmune Gastritis. *Dig Dis Sci* 2016; **61**: 1597-1602 [PMID: 26725066 DOI: 10.1007/s10620-015-4021-1]
 - 28 **Bashashati M**, Moossavi S, Cremon C, Barbaro MR, Moraveji S, Talmon G, Rezaei N, Hughes PA, Bian ZX, Choi CH, Lee OY, Coëffier M, Chang L, Ohman L, Schmulson MJ, McCallum RW, Simren M, Sharkey KA, Barbara G. Colonic immune cells in irritable bowel syndrome: A systematic review and meta-analysis. *Neurogastroenterol Motil* 2018; **30**: 28851005 DOI: 10.1111/nmo.13192]
 - 29 **Daher R**, Yazbeck T, Jaoude JB, Abboud B. Consequences of dysthyroidism on the digestive tract and viscera. *World J Gastroenterol* 2009; **15**: 2834-2838 [PMID: 19533804 DOI: 10.3748/wjg.15.2834]
 - 30 **Moayyedi P**, Lacy BE, Andrews CN, Enns RA, Howden CW, Vakil N. ACG and CAG Clinical Guideline: Management of Dyspepsia. *Am J Gastroenterol* 2017; **112**: 988-1013 [PMID: 28631728 DOI: 10.1038/ajg.2017.154]
 - 31 **Miwa H**, Nagahara A, Asakawa A, Arai M, Oshima T, Kasugai K, Kamada K, Suzuki H, Tanaka F, Tominaga K, Futagami S, Hojo M, Mihara H, Higuchi K, Kusano M, Arisawa T, Kato M, Joh T, Mochida S, Enomoto N, Shimosegawa T, Koike K. Evidence-based clinical practice guidelines for functional dyspepsia 2021. *J Gastroenterol* 2022; **57**: 47-61 [PMID: 35061057 DOI: 10.1007/s00535-021-01843-7]
 - 32 **Black CJ**, Paine PA, Agrawal A, Aziz I, Eugenicos MP, Houghton LA, Hungin P, Overshott R, Vasant DH, Rudd S, Winning RC, Corsetti M, Ford AC. British Society of Gastroenterology guidelines on the management of functional dyspepsia. *Gut* 2022; **71**: 1697-1723 [PMID: 35798375 DOI: 10.1136/gutjnl-2022-327737]
 - 33 **Shah SC**, Piazzuelo MB, Kuipers EJ, Li D. AGA Clinical Practice Update on the Diagnosis and Management of Atrophic Gastritis: Expert Review. *Gastroenterology* 2021; **161**: 1325-1332.e7 [PMID: 34454714 DOI: 10.1053/j.gastro.2021.06.078]
 - 34 **Dixon MF**, Genta RM, Yardley JH, Correa P. Classification and grading of gastritis. The updated Sydney System. International Workshop on the Histopathology of Gastritis, Houston 1994. *Am J Surg Pathol* 1996; **20**: 1161-1181 [PMID: 8827022 DOI: 10.1097/0000478-199610000-00001]

- 35 **Rugge M**, Meggio A, Pennelli G, Piscioi F, Giacomelli L, De Pretis G, Graham DY. Gastritis staging in clinical practice: the OLGA staging system. *Gut* 2007; **56**: 631-636 [PMID: 17142647 DOI: 10.1136/gut.2006.106666]
- 36 **Capelle LG**, de Vries AC, Haringsma J, Ter Borg F, de Vries RA, Bruno MJ, van Dekken H, Meijer J, van Grieken NC, Kuipers EJ. The staging of gastritis with the OLGA system by using intestinal metaplasia as an accurate alternative for atrophic gastritis. *Gastrointest Endosc* 2010; **71**: 1150-1158 [PMID: 20381801 DOI: 10.1016/j.gie.2009.12.029]
- 37 **Moayyedi P**, Forman D, Braunholtz D, Feltbower R, Crocombe W, Liptrott M, Axon A. The proportion of upper gastrointestinal symptoms in the community associated with *Helicobacter pylori*, lifestyle factors, and nonsteroidal anti-inflammatory drugs. Leeds HELP Study Group. *Am J Gastroenterol* 2000; **95**: 1448-1455 [PMID: 10894577 DOI: 10.1111/j.1572-0241.2000.2126_1.x]
- 38 **Abell TL**, Camilleri M, Donohoe K, Hasler WL, Lin HC, Maurer AH, McCallum RW, Nowak T, Nusynowitz ML, Parkman HP, Shreve P, Szarka LA, Snape WJ Jr, Ziessman HA; American Neurogastroenterology and Motility Society and the Society of Nuclear Medicine. Consensus recommendations for gastric emptying scintigraphy: a joint report of the American Neurogastroenterology and Motility Society and the Society of Nuclear Medicine. *J Nucl Med Technol* 2008; **36**: 44-54 [PMID: 18287197 DOI: 10.2967/jnmt.107.048116]
- 39 **Camilleri M**, Kuo B, Nguyen L, Vaughn VM, Petrey J, Greer K, Yadlapati R, Abell TL. ACG Clinical Guideline: Gastroparesis. *Am J Gastroenterol* 2022; **117**: 1197-1220 [PMID: 35926490 DOI: 10.14309/ajg.0000000000001874]
- 40 **Pasricha PJ**, Grover M, Yates KP, Abell TL, Bernard CE, Koch KL, McCallum RW, Sarosiek I, Kuo B, Bulat R, Chen J, Shulman RJ, Lee L, Tonascia J, Miriel LA, Hamilton F, Farrugia G, Parkman HP; National Institute of Diabetes and Digestive and Kidney Diseases/National Institutes of Health Gastroparesis Clinical Research Consortium. Functional Dyspepsia and Gastroparesis in Tertiary Care are Interchangeable Syndromes With Common Clinical and Pathologic Features. *Gastroenterology* 2021; **160**: 2006-2017 [PMID: 33548234 DOI: 10.1053/j.gastro.2021.01.230]
- 41 **Lee YY**, Erdogan A, Rao SS. How to assess regional and whole gut transit time with wireless motility capsule. *J Neurogastroenterol Motil* 2014; **20**: 265-270 [PMID: 24840380 DOI: 10.5056/jnm.2014.20.2.265]
- 42 **Saad RJ**. The Wireless Motility Capsule: a One-Stop Shop for the Evaluation of GI Motility Disorders. *Curr Gastroenterol Rep* 2016; **18**: 14 [PMID: 26908282 DOI: 10.1007/s11894-016-0489-x]
- 43 **Triadafilopoulos G**, Lombard C. Use of the Wireless Motility Capsule in the Diagnosis of Gastric Hypochlorhydria: pHinding Extra Value. *Dig Dis Sci* 2021; **66**: 1442-1445 [PMID: 32974808 DOI: 10.1007/s10620-020-06605-8]
- 44 **Gourcerol G**, Tissier F, Melchior C, Touchais JY, Huet E, Prevost G, Leroi AM, Ducrotte P. Impaired fasting pyloric compliance in gastroparesis and the therapeutic response to pyloric dilatation. *Aliment Pharmacol Ther* 2015; **41**: 360-367 [PMID: 25523288 DOI: 10.1111/apt.13053]
- 45 **Malik Z**, Sankineni A, Parkman HP. Assessing pyloric sphincter pathophysiology using EndoFLIP in patients with gastroparesis. *Neurogastroenterol Motil* 2015; **27**: 524-531 [PMID: 25712043 DOI: 10.1111/nmo.12522]
- 46 **Wuestenberghs F**, Gourcerol G. Pyloric distensibility in health and disease. *Am J Physiol Gastrointest Liver Physiol* 2021; **321**: G133-G138 [PMID: 34160292 DOI: 10.1152/ajpgi.00460.2020]
- 47 **Desprez C**, Chambaz M, Melchior C, Basile P, Prevost G, Jacques J, Leroi AM, Gourcerol G. Assessment of pyloric sphincter distensibility and pressure in patients with diabetic gastroparesis. *Neurogastroenterol Motil* 2021; **33**: e14064 [PMID: 33314491 DOI: 10.1111/nmo.14064]
- 48 **Snape WJ**, Lin MS, Agarwal N, Shaw RE. Evaluation of the pylorus with concurrent intraluminal pressure and EndoFLIP in patients with nausea and vomiting. *Neurogastroenterol Motil* 2016; **28**: 758-764 [PMID: 26813266 DOI: 10.1111/nmo.12772]
- 49 **Yadlapati R**, Gyawali CP, Pandolfino JE; CGIT GERD Consensus Conference Participants. AGA Clinical Practice Update on the Personalized Approach to the Evaluation and Management of GERD: Expert Review. *Clin Gastroenterol Hepatol* 2022; **20**: 984-994.e1 [PMID: 35123084 DOI: 10.1016/j.cgh.2022.01.025]
- 50 **Gyawali CP**, Kahrilas PJ, Savarino E, Zerbib F, Mion F, Smout AJPM, Vaezi M, Sifrim D, Fox MR, Vela MF, Tutuian R, Tack J, Bredenoord AJ, Pandolfino J, Roman S. Modern diagnosis of GERD: the Lyon Consensus. *Gut* 2018; **67**: 1351-1362 [PMID: 29437910 DOI: 10.1136/gutjnl-2017-314722]
- 51 **Vela MF**, Camacho-Lobato L, Srinivasan R, Tutuian R, Katz PO, Castell DO. Simultaneous intraesophageal impedance and pH measurement of acid and nonacid gastroesophageal reflux: effect of omeprazole. *Gastroenterology* 2001; **120**: 1599-1606 [PMID: 11375942 DOI: 10.1053/gast.2001.24840]
- 52 **Sifrim D**, Dupont L, Blondeau K, Zhang X, Tack J, Janssens J. Weakly acidic reflux in patients with chronic unexplained cough during 24 hour pressure, pH, and impedance monitoring. *Gut* 2005; **54**: 449-454 [PMID: 15753524 DOI: 10.1136/gut.2004.055418]
- 53 **de Bortoli N**, Martinucci I, Savarino E, Franchi R, Bertani L, Russo S, Ceccarelli L, Costa F, Bellini M, Blandizzi C, Savarino V, Marchi S. Lower pH values of weakly acidic refluxes as determinants of heartburn perception in gastroesophageal reflux disease patients with normal esophageal acid exposure. *Dis Esophagus* 2016; **29**: 3-9 [PMID: 25212408 DOI: 10.1111/dote.12284]
- 54 **Viazis N**, Karamanolis G, Vienna E, Karamanolis DG. Selective-serotonin reuptake inhibitors for the treatment of hypersensitive esophagus. *Therap Adv Gastroenterol* 2011; **4**: 295-300 [PMID: 21922028 DOI: 10.1177/1756283X11409279]
- 55 **Mainie I**, Tutuian R, Shay S, Vela M, Zhang X, Sifrim D, Castell DO. Acid and non-acid reflux in patients with persistent symptoms despite acid suppressive therapy: a multicentre study using combined ambulatory impedance-pH monitoring. *Gut* 2006; **55**: 1398-1402 [PMID: 16556669 DOI: 10.1136/gut.2005.087668]
- 56 **del Genio G**, Tolone S, del Genio F, Aggarwal R, d'Alessandro A, Allaria A, Rossetti G, Bruscianno L, del Genio A. Prospective assessment of patient selection for antireflux surgery by combined multichannel intraluminal impedance pH monitoring. *J Gastrointest Surg* 2008; **12**: 1491-1496 [PMID: 18612705 DOI: 10.1007/s11605-008-0583-y]
- 57 **Kahrilas PJ**, Bredenoord AJ, Fox M, Gyawali CP, Roman S, Smout AJ, Pandolfino JE; International High Resolution Manometry Working Group. The Chicago Classification of esophageal motility disorders, v3.0. *Neurogastroenterol Motil* 2015; **27**: 160-174 [PMID: 25469569 DOI: 10.1111/nmo.12477]
- 58 **Tack J**, Caenepel P, Arts J, Lee KJ, Sifrim D, Janssens J. Prevalence of acid reflux in functional dyspepsia and its

- association with symptom profile. *Gut* 2005; **54**: 1370-1376 [PMID: 15972301 DOI: 10.1136/gut.2004.053355]
- 59 **Lahner E**, Carabotti M, Annibale B. Treatment of *Helicobacter pylori* infection in atrophic gastritis. *World J Gastroenterol* 2018; **24**: 2373-2380 [PMID: 29904244 DOI: 10.3748/wjg.v24.i22.2373]
- 60 **Song H**, Zhu J, Lu D. Long-term proton pump inhibitor (PPI) use and the development of gastric pre-malignant lesions. *Cochrane Database Syst Rev* 2014; CD010623 [PMID: 25464111 DOI: 10.1002/14651858.CD010623.pub2]
- 61 **Cavalcoli F**, Zilli A, Conte D, Ciafardini C, Massironi S. Gastric neuroendocrine neoplasms and proton pump inhibitors: fact or coincidence? *Scand J Gastroenterol* 2015; **50**: 1397-1403 [PMID: 26059834 DOI: 10.3109/00365521.2015.1054426]
- 62 **Annibale B**, Lahner E, Santucci A, Vaira D, Pasquali A, Severi C, Mini R, Figura N, Delle Fave G. CagA and VacA are immunoblot markers of past *Helicobacter pylori* infection in atrophic body gastritis. *Helicobacter* 2007; **12**: 23-30 [PMID: 17241297 DOI: 10.1111/j.1523-5378.2007.00467.x]
- 63 **Collin A**, Mion F, Kefleyesus A, Beets C, Jaafari N, Bousageon R. Critical appraisal of international guidelines for the management of *Helicobacter pylori* infection in case of dyspepsia. *Helicobacter* 2023; **28**: e12952 [PMID: 36897573 DOI: 10.1111/hel.12952]
- 64 **Kato M**, Hayashi Y, Nishida T, Oshita M, Nakanishi F, Yamaguchi S, Kitamura S, Nishihara A, Akasaka T, Ogiyama H, Nakahara M, Yamada T, Kishida O, Yamamoto M, Shimayoshi A, Tsujii Y, Kato M, Shinzaki S, Iijima H, Takehara T. *Helicobacter pylori* eradication prevents secondary gastric cancer in patients with mild-to-moderate atrophic gastritis. *J Gastroenterol Hepatol* 2021; **36**: 2083-2090 [PMID: 33403702 DOI: 10.1111/jgh.15396]
- 65 **Kamada T**, Haruma K, Hata J, Kusunoki H, Sasaki A, Ito M, Tanaka S, Yoshihara M. The long-term effect of *Helicobacter pylori* eradication therapy on symptoms in dyspeptic patients with fundic atrophic gastritis. *Aliment Pharmacol Ther* 2003; **18**: 245-252 [PMID: 12869086 DOI: 10.1046/j.1365-2036.2003.01669.x]
- 66 **Yamada S**, Tomatsuri N, Kawakami T, Nakatsugawa Y, Nishimura T, Fujii H, Sato H, Okuyama Y, Kimura H, Yoshida N. *Helicobacter pylori* Eradication Therapy Ameliorates Latent Digestive Symptoms in Chronic Atrophic Gastritis. *Digestion* 2018; **97**: 333-339 [PMID: 29587295 DOI: 10.1159/000486618]
- 67 **Masuy I**, Van Oudenhove L, Tack J. Review article: treatment options for functional dyspepsia. *Aliment Pharmacol Ther* 2019; **49**: 1134-1172 [PMID: 30924176 DOI: 10.1111/apt.15191]
- 68 **Jokelainen K**, Siitonen A, Jousimies-Somer H, Nosova T, Heine R, Salaspuro M. In vitro alcohol dehydrogenase-mediated acetaldehyde production by aerobic bacteria representing the normal colonic flora in man. *Alcohol Clin Exp Res* 1996; **20**: 967-972 [PMID: 8892513 DOI: 10.1111/j.1530-0277.1996.tb01932.x]
- 69 **Linderborg K**, Marvola T, Marvola M, Salaspuro M, Färkkilä M, Väkeväinen S. Reducing carcinogenic acetaldehyde exposure in the achlorhydric stomach with cysteine. *Alcohol Clin Exp Res* 2011; **35**: 516-522 [PMID: 21143248 DOI: 10.1111/j.1530-0277.2010.01368.x]
- 70 **Maejima R**, Iijima K, Kaihovaara P, Hatta W, Koike T, Imatani A, Shimosegawa T, Salaspuro M. Effects of ALDH2 genotype, PPI treatment and L-cysteine on carcinogenic acetaldehyde in gastric juice and saliva after intragastric alcohol administration. *PLoS One* 2015; **10**: e0120397 [PMID: 25831092 DOI: 10.1371/journal.pone.0120397]
- 71 **Hellström PM**, Hendolin P, Kaihovaara P, Kronberg L, Meierjohann A, Millerhöv A, Paloheimo L, Sundelin H, Syrjänen K, Webb DL, Salaspuro M. Slow-release L-cysteine capsule prevents gastric mucosa exposure to carcinogenic acetaldehyde: results of a randomised single-blinded, cross-over study of *Helicobacter*-associated atrophic gastritis. *Scand J Gastroenterol* 2017; **52**: 230-237 [PMID: 27806647 DOI: 10.1080/00365521.2016.1249403]
- 72 **Crafa P**, Di Mario F, Grillo S, Landi S, Franceschi M, Rodriguez-Castro K, Tursi A, Brandimarte G, Franzoni L. Recovery of gastric function in patients affected by chronic atrophic gastritis using L-cysteine (Acetium®): one year survey in comparison with a control group. *Acta Biomed* 2022; **93**: e2022184 [PMID: 35775759 DOI: 10.23750/abm.v93i3.12812]
- 73 **Di Mario F**, Rodriguez-Castro KI, Franceschi M, Landi S, Grillo S, Franzoni L, Russo M, Brandimarte G, Tursi A, Crafa P. Improvement of Symptoms in Patients Affected by Chronic Atrophic Gastritis Using L-Cysteine (Acetium®). *Dig Dis* 2023; **41**: 198-205 [PMID: 36423587 DOI: 10.1159/000528168]
- 74 **Conti L**, Borro M, Milani C, Simmaco M, Esposito G, Canali G, Pillozzi E, Ventura M, Annibale B, Lahner E. Gastric microbiota composition in patients with corpus atrophic gastritis. *Dig Liver Dis* 2021; **53**: 1580-1587 [PMID: 34116969 DOI: 10.1016/j.dld.2021.05.005]
- 75 **Parsons BN**, Ijaz UZ, D'Amore R, Burkitt MD, Eccles R, Lenzi L, Duckworth CA, Moore AR, Tiszlavicz L, Varro A, Hall N, Pritchard DM. Comparison of the human gastric microbiota in hypochlorhydric states arising as a result of *Helicobacter pylori*-induced atrophic gastritis, autoimmune atrophic gastritis and proton pump inhibitor use. *PLoS Pathog* 2017; **13**: e1006653 [PMID: 29095917 DOI: 10.1371/journal.ppat.1006653]
- 76 **Rajilic-Stojanovic M**, Figueiredo C, Smet A, Hansen R, Kupcinskis J, Rokkas T, Andersen L, Machado JC, Ianiro G, Gasbarrini A, Leja M, Gisbert JP, Hold GL. Systematic review: gastric microbiota in health and disease. *Aliment Pharmacol Ther* 2020; **51**: 582-602 [PMID: 32056247 DOI: 10.1111/apt.15650]
- 77 **Lahner E**, Conti L, Annibale B, Corleto VD. Current Perspectives in Atrophic Gastritis. *Curr Gastroenterol Rep* 2020; **22**: 38 [PMID: 32542467 DOI: 10.1007/s11894-020-00775-1]
- 78 **Gregor L**, Wo J, DeWitt J, Yim B, Siwiec R, Nowak T, Mendez M, Gupta A, Dickason D, Stainko S, Al-Haddad M. Gastric peroral endoscopic myotomy for the treatment of refractory gastroparesis: a prospective single-center experience with mid-term follow-up (with video). *Gastrointest Endosc* 2021; **94**: 35-44 [PMID: 33373646 DOI: 10.1016/j.gie.2020.12.030]
- 79 **Soliman H**, Gourcerol G. Targeting the pylorus in gastroparesis: From physiology to endoscopic pyloromyotomy. *Neurogastroenterol Motil* 2023; **35**: e14529 [PMID: 36594414 DOI: 10.1111/nmo.14529]
- 80 **Ichkhanian Y**, Vosoughi K, Aghaie Meybodi M, Jacques J, Sethi A, Patel AA, Aadam AA, Triggs JR, Bapaye A, Dorwat S, Benias P, Chaves DM, Barret M, Law RJ, Browers N, Pioche M, Draganov PV, Kotzev A, Estremera F, Albeniz E, Ujiki MB, Callahan ZM, Itani MI, Brewer OG, Khashab MA. Comprehensive Analysis of Adverse Events Associated with Gastric Peroral Endoscopic Myotomy: An International Multicenter Study. *Surg Endosc* 2021; **35**: 1755-1764 [PMID: 32328824 DOI: 10.1007/s00464-020-07570-z]

- 81 **Mandarino FV**, Testoni SGG, Barchi A, Pepe G, Esposito D, Fanti L, Viale E, Biamonte P, Azzolini F, Danese S. Gastric emptying study before gastric peroral endoscopic myotomy (G-POEM): can intragastric meal distribution be a predictor of success? *Gut* 2023; **72**: 1019-1020 [PMID: 35697421 DOI: 10.1136/gutjnl-2022-327701]



Published by **Baishideng Publishing Group Inc**
7041 Koll Center Parkway, Suite 160, Pleasanton, CA 94566, USA
Telephone: +1-925-3991568
E-mail: bpgoffice@wjgnet.com
Help Desk: <https://www.f6publishing.com/helpdesk>
<https://www.wjgnet.com>

