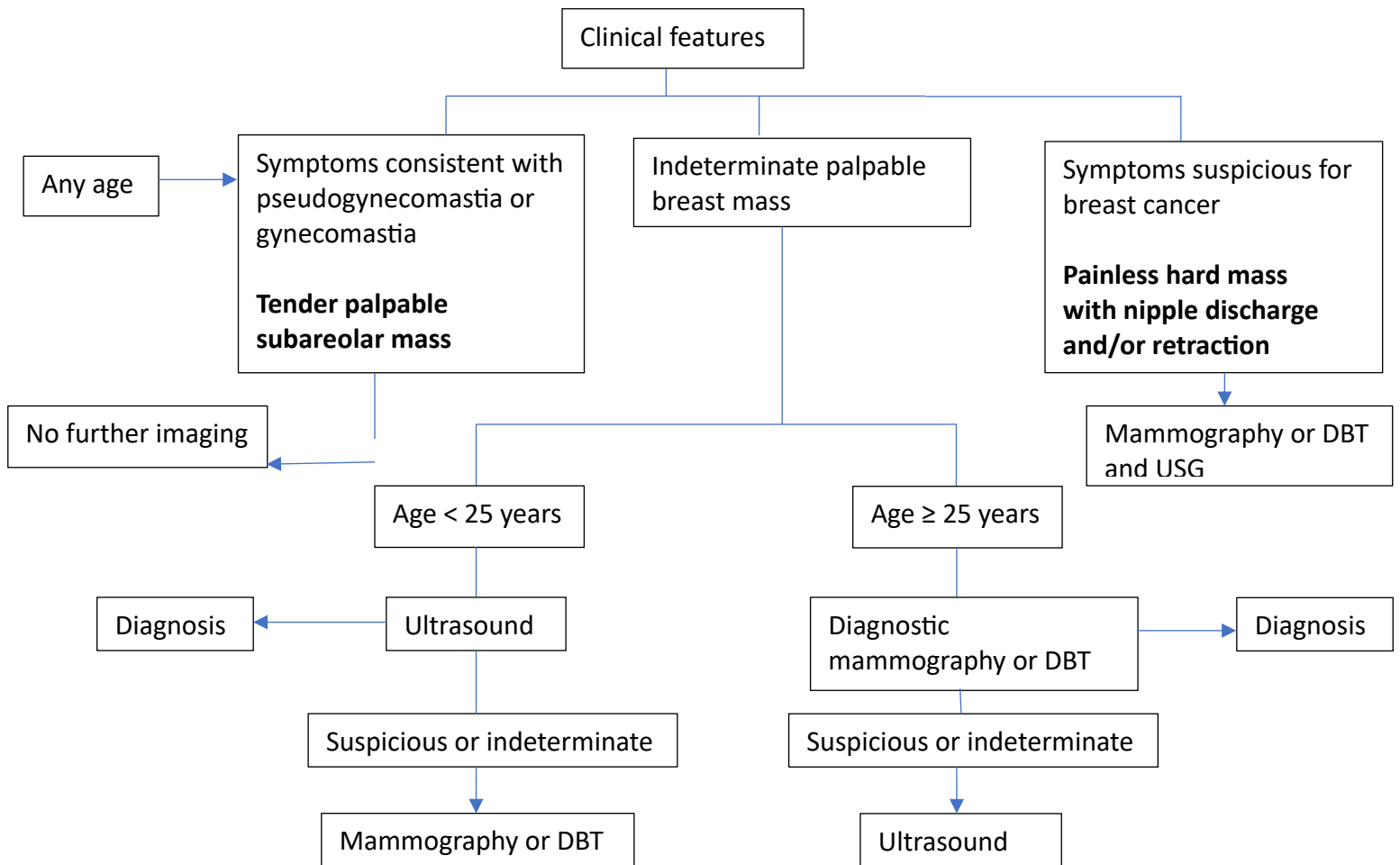


Supplementary Figure 1: Choosing the imaging modality for male breast



DBT; Digital Breast Tomosynthesis; USG: Ultrasonography

Supplementary Figure 2: Algorithmic approach to male breast

