World Journal of Gastroenterology

Submit a Manuscript: http://www.wjgnet.com/esps/
Help Desk: http://www.wjgnet.com/esps/helpdesk.aspx
DOI: 10.3748/wjg.v2.i3.144

World J Gastroenterol 1996 September 15; 2(3): 144-145
ISSN 1007-9327 (print) ISSN 2219-2840 (online)

CLINICAL ARTICLES

Radiological diagnosis of inflammatory ulcerative diseases of the small bowel

Yan Lu, Jian-Ying Duan, Yu Gao

Yan Lu, Jian-Ying Duan, Yu Gao, Department of Radiology, Sino Japan Friendship Hospital, Beijing 100029, China

Yan Lu, Professor of Radiology, having 56 papers and two books published. Born on June 24, 1934 in Fujian. Graduated from Tongji Medical University in 1957.

Author contributions: All authors contributed equally to the work.

Original title: *China National Journal of New Gastroenterology* (1995-1997) renamed *World Journal of Gastroenterology* (1998-).

Correspondence to: Dr. Yan Lu, Professor, Department of Radiology, Sino Japan Friendship Hospital, Beijing 100029, China
Telephone: +86-10-64222963

Received: Jun 2, 1996
Revised: July 4, 1996
Accepted: August 10, 1996
Published online: September 15, 1996

Abstract

AIM: To analyze the radiological features of ulcerative diseases of the small bowel.

METHODS: Thirty-five patients (20 men and 15 women) with inflammatory ulcerative bowel diseases were studied by radiography (barium meal and/or double contrast study). Patient diseases included eleven cases of tuberculosis (TB), thirteen cases of Crohn's disease, seven cases of bowel Behcet disease, two cases of simple ulcers, and two cases of ischemic bowel disease. Diagnosis was established pathologically in 33 cases and by clinical observation after therapy in two cases.

RESULTS: The lesions were located in the ileum of 82% of TB cases, 77% of Crohn's disease cases, 71% of bowel Behcet disease cases, 50% of simple ulcer cases, and 100% of ischemic bowel disease cases. Ulceration was always present with variable appearances. Longitudinal ulcers, and fissures were noted in Crohn's disease only. There were five cases of large and deep ulcers, three of which were bowel Behcet disease. Superficial and irregular ulcers were present in ten TB cases, and , and transverse ulcers were identified in two TB cases.

CONCLUSION: The morphological appearances of the ulcer, surrounding mucosal alterations, and bowel deformation were the basis for the radiological diagnosis. Correct diagnosis was dependent on optimal X-ray examination techniques and proper interpretation of the morphological changes.

Key words: Small intestine; Gastrointestinal tuberculosis; Crohn's disease/radiography

Lu Y, Duan JY, Gao Y. Radiological diagnosis of inflammatory ulcerative diseases of the small bowel. *World J Gastroenterol* 1996; 2(3): 144-145 Available from: URL: http://www.wjgnet.com/1007-9327/full/v2/i3/144.htm DOI: http://dx.doi.org/10.3748/wjg.v2.i3.144

INTRODUCTION

Intestinal ulcers are often found in cases of small intestine inflammatory disease. They are accompanied by a high mortality rate.

It is difficult to make differential diagnoses by radiographic examination[1,2]. In this study, we reviewed 35 cases of small intestine disease, and analyzed the radiographic characteristics of the disease. Serial changes in radiographic examination were observed.

MATERIALS AND METHODS

We performed radiography (barium meal and/or double contrast study) in 35 patients (20 men and 15 women). All patients were diagnosed with small intestine inflammation with an intestinal ulcer. Diagnosis was established by pathology in 33 cases and by clinical observation after therapy in two cases. The age range of the patients was 14 years to 78 years. Most patients had gastrointestinal symptoms such as abdominal pain, diarrhea, and bloody stool. The inflammatory ulcerative bowel diseases included eleven cases of tuberculosis (TB), thirteen cases of Crohn's disease, seven cases of bowel Behcet disease, two cases of simple ulcers, and two cases of ischemic bowel disease.

RESULT

The lesions were located in the ileum of 82% of TB cases, of 77% of Crohn's disease cases, of 71% of bowel Behcet disease cases, of 50% of simple ulcer cases, and of 100% of ischemic bowel disease cases. Ulceration was always present with variable appearances. Longitudinal ulcers and fissures were noted in Crohn's disease only. There were 5 cases of large and deep ulcers, three of which occurred in bowel Behcet disease. Superficial and irregular ulcers were present in ten TB cases, and transverse ulcers were observed in two TB cases (Figures 1 and 2).

DISCUSSION

Ulceration is present in the majority of small bowel inflammatory diseases including TB, Crohn's disease, bowel Behcet disease, simple ulcers, and ischemic bowel disease. The morphological appearances of the ulcer, surrounding mucosal alterations and bowel deformation were the basis for radiological diagnosis[3-9]. TB was located in the terminal ileum. Ulcerations had variable appearances, but no longitudinal ulcers and fissures were noted. In Crohn's disease, the above characteristics were noted. In addition, cobblestone and fistulas

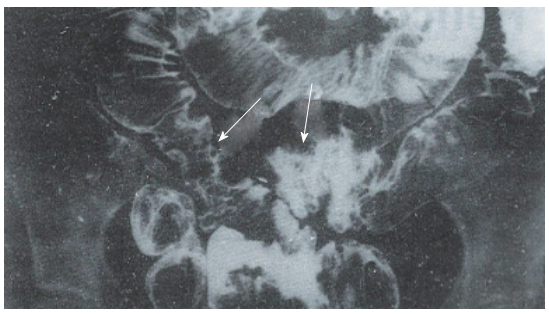

Figure 1 The mucosa is irregular and superficial ulcers (arrows) were present in several segments of the terminal ileum of TB cases.

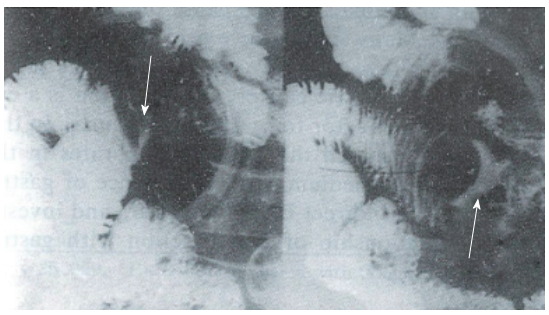

Figure 2 After compression, a transverse ulcer (arrow) is observed in a TB case.

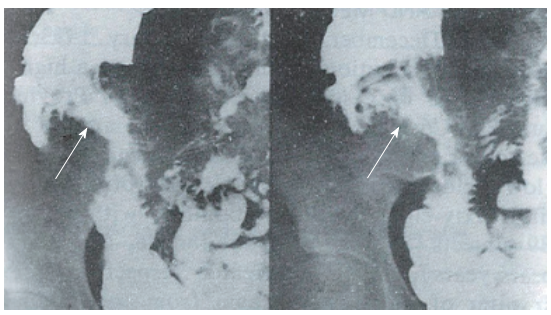

Figure 3 Triangular ulcers measuring 4 cm^2 in size at the terminal ileum (arrow) were present Crohn's disease cases. The surrounding mucosal pattern exhibited a cobblestone appearance.

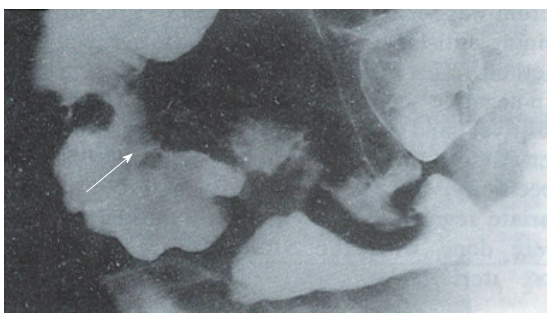

Figure 4 A round ulcer (arrow), with surrounding mild mucosal edema in the ileocecal region was present in a Crohn's disease case.

occurred frequently (Figures 3 and 4). The radiographic findings of bowel Behcet disease and simple ulcer were similar. However, the ulcers in bowel Behcet disease tended to be larger and deeper with surrounding mucosal edema (Figures 5 and 6). All patients had mucocutaneous ocular symptoms. Ulcers in ischemic bowel disease had no characteristics (Figure 7). Correct diagnosis was dependent on optimal X-ray examination techniques and proper interpretation of the morphological changes. Enteroclysis, a controlled infusion method offering a double contrast and highly detailed examination of the small bowel, is relatively easy to perform. Despite the introduction of enteroclysis, the peroral small bowel examination remains the predominant radiographic method of imaging the small intestine. This report emphasizes the technical factors needed to produce excellent peroral small bowel examinations.

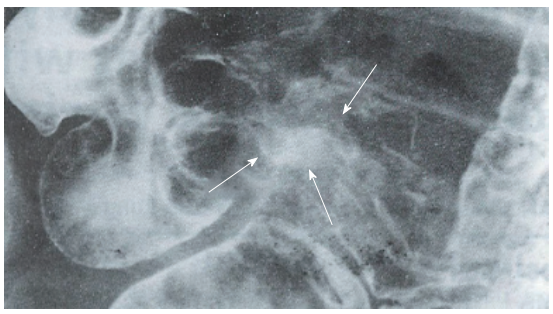

Figure 5 A large and deep irregular ulcer (4 × 3 cm^2 in size) at the terminal ileum near the ileocecal valve (double arrow) was present in a bowel Behcet disease case. The surrounding mucosal edema (arrow) is shown.

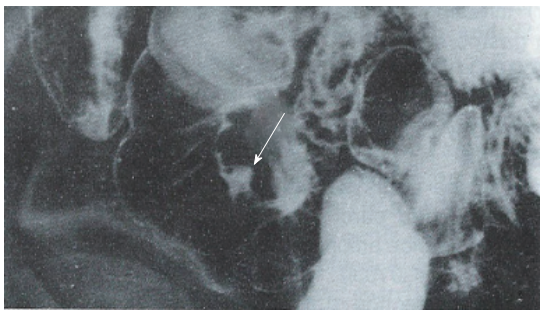

Figure 6 A small ulcer (0.3 × 0.4 cm^2 in size) at the ileum (arrow) was present in a bowel Behcet disease case. The surrounding mucosal edema (arrow) is shown.

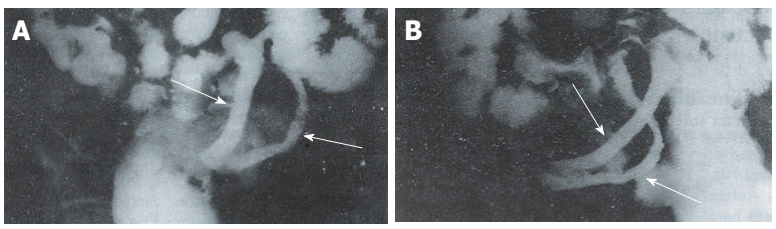

Figure 7 A and B: Several long, segmented, contracted, narrow, and rigid loops of the bowel in the ileum (arrow), with superficial ulcers were present in ischemic bowel disease. No mucosal abnormalities were observed.

REFERENCES

1 **Feczko PJ**, Holpert RD. Radiology of inflammatory bowel disease. *Radiol Clin North Am* 1987; **25**: 1-20

2 **Xie JX**. Diagnosis and Differential Diagnosis of inflammatory ulcerative diseases of the small bowel. *Zhonghua Fangshexue Zazhi* 1994; **28**: 128-130

3 **Vaidya MG**, Sodhi JS. Gastrointestinal tract tuberculosis: a study of 102 cases including 55 hemicolectomies. *Clin Radiol* 1978; **29**: 189-195 [PMID: 639458 DOI: 10.1016/S0009-9260(78)80230-X]

4 **Yao T**, Okada M, Fuchigami T, Iida M, Takenaka K, Date H, Fujita K. The relationship between the radiological and clinical features in patients with Crohn's disease. *Clin Radiol* 1989; **40**: 389-392 [PMID: 2758748 DOI: 10.1016/S0009-9260(89)80131-X]

5 **Marshak RH**. Granulomatous disease of the intestinal tract (Crohn's disease). *Radiology* 1975; **114**: 3-22 [PMID: 1108108 DOI: 10.1148/114.1.3]

6 **Nolan DJ**, Piris J. Crohn's disease of the small intestine: a comparative study of the radiological and pathological appearances. *Clin Radiol* 1980; **31**: 591-596 [PMID: 7471637 DOI: 10.1016/S0009-9260(80)80064-X]

7 **Nolan DJ**, Gourtsoyiannis NC. Crohn's disease of the small intestine: a review of the radiological appearances in 100 consecutive patients examined by a barium infusion technique. *Clin Radiol* 1980; **31**: 597-603 [PMID: 7471638 DOI: 10.1016/S0009-9260(80)80065-1]

8 **Iida M**, Kobayashi H, Matsumoto T, Okada M, Fuchigami T, Niizeki H, Yao T, Fujishima M. Intestinal Behçet disease: serial changes at radiography. *Radiology* 1993; **188**: 65-69 [PMID: 8511319 DOI: 10.1148/radiology.188.1.8511319]

9 **Scholz FJ**. Ischemic bowel disease. *Radiol Clin North Am* 1993; **31**: 1197-1218 [PMID: 8210346]

S- Editor: Ma JY **L- Editor**: Filipodia **E- Editor**: Li RF

Published by **Baishideng Publishing Group Inc**
8226 Regency Drive, Pleasanton, CA 94588, USA
Telephone: +1-925-223-8242
Fax: +1-925-223-8243
E-mail: bpgoffice@wjgnet.com
Help Desk: http://www.wjgnet.com/esps/helpdesk.aspx
http://www.wjgnet.com

ISSN 1007-9327