

# World Journal of *Clinical Cases*

*World J Clin Cases* 2022 July 16; 10(20): 6759-7186



**OPINION REVIEW**

- 6759 Semaglutide might be a key for breaking the vicious cycle of metabolically associated fatty liver disease spectrum?  
*Cigrovski Berkovic M, Rezic T, Bilic-Curcic I, Mrzljak A*

**MINIREVIEWS**

- 6769 Drainage of pancreatic fluid collections in acute pancreatitis: A comprehensive overview  
*Bansal A, Gupta P, Singh AK, Shah J, Samanta J, Mandavdhare HS, Sharma V, Sinha SK, Dutta U, Sandhu MS, Kochhar R*
- 6784 Frontiers of COVID-19-related myocarditis as assessed by cardiovascular magnetic resonance  
*Luo Y, Liu BT, Yuan WF, Zhao CX*

**ORIGINAL ARTICLE****Case Control Study**

- 6794 Urinary and sexual function changes in benign prostatic hyperplasia patients before and after transurethral columnar balloon dilatation of the prostate  
*Zhang DP, Pan ZB, Zhang HT*
- 6803 Effects of the information-knowledge-attitude-practice nursing model combined with predictability intervention on patients with cerebrovascular disease  
*Huo HL, Gui YY, Xu CM, Zhang Y, Li Q*

**Retrospective Cohort Study**

- 6811 Effects of Kampo medicine hangebyakujutsutemmato on persistent postural-perceptual dizziness: A retrospective pilot study  
*Miwa T, Kanemaru SI*

**Retrospective Study**

- 6825 Longitudinal changes in personalized platelet count metrics are good indicators of initial 3-year outcome in colorectal cancer  
*Herold Z, Herold M, Lohinszky J, Szasz AM, Dank M, Somogyi A*
- 6845 Efficacy of Kegel exercises in preventing incontinence after partial division of internal anal sphincter during anal fistula surgery  
*Garg P, Yagnik VD, Kaur B, Menon GR, Dawka S*

**Observational Study**

- 6855 Influence of the water jet system vs cavitron ultrasonic surgical aspirator for liver resection on the remnant liver  
*Hanaki T, Tsuda A, Sunaguchi T, Goto K, Morimoto M, Murakami Y, Kihara K, Matsunaga T, Yamamoto M, Tokuyasu N, Sakamoto T, Hasegawa T, Fujiwara Y*

- 6865** Critical values of monitoring indexes for perioperative major adverse cardiac events in elderly patients with biliary diseases

*Zhang ZM, Xie XY, Zhao Y, Zhang C, Liu Z, Liu LM, Zhu MW, Wan BJ, Deng H, Tian K, Guo ZT, Zhao XZ*

- 6876** Comparative study of surface electromyography of masticatory muscles in patients with different types of bruxism

*Lan KW, Jiang LL, Yan Y*

### Randomized Controlled Trial

- 6890** Dural puncture epidural technique provides better anesthesia quality in repeat cesarean delivery than epidural technique: Randomized controlled study

*Wang SY, He Y, Zhu HJ, Han B*

### SYSTEMATIC REVIEWS

- 6900** Network pharmacology-based strategy for predicting therapy targets of Sanqi and Huangjing in diabetes mellitus

*Cui XY, Wu X, Lu D, Wang D*

### META-ANALYSIS

- 6915** Endoscopic submucosal dissection for early signet ring cell gastric cancer: A systematic review and meta-analysis

*Weng CY, Sun SP, Cai C, Xu JL, Lv B*

- 6927** Prognostic value of computed tomography derived skeletal muscle mass index in lung cancer: A meta-analysis

*Pan XL, Li HJ, Li Z, Li ZL*

### CASE REPORT

- 6936** Autosomal dominant osteopetrosis type II resulting from a *de novo* mutation in the *CLCN7* gene: A case report

*Song XL, Peng LY, Wang DW, Wang H*

- 6944** Clinical expression and mitochondrial deoxyribonucleic acid study in twins with 14484 Leber's hereditary optic neuropathy: A case report

*Chuenkongkaew WL, Chinkulkitnivat B, Lertrit P, Chirapapaisan N, Kaewsutthi S, Suktitipat B, Mitrpant C*

- 6954** Management of the enteroatmospheric fistula: A case report

*Cho J, Sung K, Lee D*

- 6960** Lower lip recurrent keratoacanthoma: A case report

*Liu XG, Liu XG, Wang CJ, Wang HX, Wang XX*

- 6966** Optic disc coloboma associated with macular retinoschisis: A case report

*Zhang W, Peng XY*

- 6974** A 7-year-old boy with recurrent cyanosis and tachypnea: A case report  
*Li S, Chen LN, Zhong L*
- 6981** Schwannomatosis patient who was followed up for fifteen years: A case report  
*Li K, Liu SJ, Wang HB, Yin CY, Huang YS, Guo WT*
- 6991** Intentional replantation combined root resection therapy for the treatment of type III radicular groove with two roots: A case report  
*Tan D, Li ST, Feng H, Wang ZC, Wen C, Nie MH*
- 6999** Clinical features and genetic variations of severe neonatal hyperbilirubinemia: Five case reports  
*Lin F, Xu JX, Wu YH, Ma YB, Yang LY*
- 7006** Percutaneous transhepatic access for catheter ablation of a patient with heterotaxy syndrome complicated with atrial fibrillation: A case report  
*Wang HX, Li N, An J, Han XB*
- 7013** Secondary positioning of rotationally asymmetric refractive multifocal intraocular lens in a patient with glaucoma: A case report  
*Fan C, Zhou Y, Jiang J*
- 7020** Laparoscopic repair of diaphragmatic hernia associating with radiofrequency ablation for hepatocellular carcinoma: A case report  
*Tsunoda J, Nishi T, Ito T, Inaguma G, Matsuzaki T, Seki H, Yasui N, Sakata M, Shimada A, Matsumoto H*
- 7029** Hypopituitary syndrome with pituitary crisis in a patient with traumatic shock: A case report  
*Zhang XC, Sun Y*
- 7037** Solitary plasmacytoma of the left rib misdiagnosed as angina pectoris: A case report  
*Yao J, He X, Wang CY, Hao L, Tan LL, Shen CJ, Hou MX*
- 7045** Secondary coronary artery ostial lesions: Three case reports  
*Liu XP, Wang HJ, Gao JL, Ma GL, Xu XY, Ji LN, He RX, Qi BYE, Wang LC, Li CQ, Zhang YJ, Feng YB*
- 7054** Bladder perforation injury after percutaneous peritoneal dialysis catheterization: A case report  
*Shi CX, Li ZX, Sun HT, Sun WQ, Ji Y, Jia SJ*
- 7060** Myotonic dystrophy type 1 presenting with dyspnea: A case report  
*Jia YX, Dong CL, Xue JW, Duan XQ, Xu MY, Su XM, Li P*
- 7068** Novel mutation in the *SALL1* gene in a four-generation Chinese family with uraemia: A case report  
*Fang JX, Zhang JS, Wang MM, Liu L*
- 7076** Malignant transformation of primary mature teratoma of colon: A case report  
*Liu J*

- 7082** Treatment of pyogenic liver abscess by surgical incision and drainage combined with platelet-rich plasma: A case report  
*Wang JH, Gao ZH, Qian HL, Li JS, Ji HM, Da MX*
- 7090** Left bundle branch pacing in a ventricular pacing dependent patient with heart failure: A case report  
*Song BX, Wang XX, An Y, Zhang YY*
- 7097** Solitary fibrous tumor of the liver: A case report and review of the literature  
*Xie GY, Zhu HB, Jin Y, Li BZ, Yu YQ, Li JT*
- 7105** MutL homolog 1 germline mutation c.(453+1\_454-1)\_(545+1\_546-1)del identified in lynch syndrome: A case report and review of literature  
*Zhang XW, Jia ZH, Zhao LP, Wu YS, Cui MH, Jia Y, Xu TM*
- 7116** Malignant histiocytosis associated with mediastinal germ cell tumor: A case report  
*Yang PY, Ma XL, Zhao W, Fu LB, Zhang R, Zeng Q, Qin H, Yu T, Su Y*
- 7124** Immunoglobulin G4 associated autoimmune cholangitis and pancreatitis following the administration of nivolumab: A case report  
*Agrawal R, Guzman G, Karimi S, Giulianotti PC, Lora AJM, Jain S, Khan M, Boulay BR, Chen Y*
- 7130** Portal vein thrombosis in a noncirrhotic patient after hemihepatectomy: A case report and review of literature  
*Zhang SB, Hu ZX, Xing ZQ, Li A, Zhou XB, Liu JH*
- 7138** Microvascular decompression for a patient with oculomotor palsy caused by posterior cerebral artery compression: A case report and literature review  
*Zhang J, Wei ZJ, Wang H, Yu YB, Sun HT*
- 7147** Topical halometasone cream combined with fire needle pre-treatment for treatment of primary cutaneous amyloidosis: Two case reports  
*Su YQ, Liu ZY, Wei G, Zhang CM*
- 7153** Simultaneous robot-assisted approach in a super-elderly patient with urothelial carcinoma and synchronous contralateral renal cell carcinoma: A case report  
*Yun JK, Kim SH, Kim WB, Kim HK, Lee SW*
- 7163** Nursing a patient with latent autoimmune diabetes in adults with insulin-related lipodystrophy, allergy, and exogenous insulin autoimmune syndrome: A case report  
*He F, Xu LL, Li YX, Dong YX*
- 7171** Incidental diagnosis of medullary thyroid carcinoma due to persistently elevated procalcitonin in a patient with COVID-19 pneumonia: A case report  
*Saha A, Mukhopadhyay M, Paul S, Bera A, Bandyopadhyay T*
- 7178** Macular hole following phakic intraocular lens implantation: A case report  
*Li XJ, Duan JL, Ma JX, Shang QL*

**LETTER TO THE EDITOR**

**7184** Is every microorganism detected in the intensive care unit a nosocomial infection? Isn't prevention more important than detection?

*Yildirim F, Karaman I, Yildirim M*

**ABOUT COVER**

Editorial Board Member of *World Journal of Clinical Cases*, Jie-Feng Huang, PhD, Associate Chief Physician, Associate Professor, Department of Orthopaedics and Traumatology, The First Affiliated Hospital of Zhejiang Chinese Medical University, Hangzhou 310006, Zhejiang Province, China. 40983285@qq.com

**AIMS AND SCOPE**

The primary aim of *World Journal of Clinical Cases (WJCC, World J Clin Cases)* is to provide scholars and readers from various fields of clinical medicine with a platform to publish high-quality clinical research articles and communicate their research findings online.

*WJCC* mainly publishes articles reporting research results and findings obtained in the field of clinical medicine and covering a wide range of topics, including case control studies, retrospective cohort studies, retrospective studies, clinical trials studies, observational studies, prospective studies, randomized controlled trials, randomized clinical trials, systematic reviews, meta-analysis, and case reports.

**INDEXING/ABSTRACTING**

The *WJCC* is now abstracted and indexed in Science Citation Index Expanded (SCIE, also known as SciSearch®), Journal Citation Reports/Science Edition, Current Contents®/Clinical Medicine, PubMed, PubMed Central, Scopus, Reference Citation Analysis, China National Knowledge Infrastructure, China Science and Technology Journal Database, and Superstar Journals Database. The 2022 Edition of Journal Citation Reports® cites the 2021 impact factor (IF) for *WJCC* as 1.534; IF without journal self cites: 1.491; 5-year IF: 1.599; Journal Citation Indicator: 0.28; Ranking: 135 among 172 journals in medicine, general and internal; and Quartile category: Q4. The *WJCC*'s CiteScore for 2021 is 1.2 and Scopus CiteScore rank 2021: General Medicine is 443/826.

**RESPONSIBLE EDITORS FOR THIS ISSUE**

Production Editor: *Hua-Ge Yu*; Production Department Director: *Xu Guo*; Editorial Office Director: *Jin-Lei Wang*.

**NAME OF JOURNAL**

*World Journal of Clinical Cases*

**ISSN**

ISSN 2307-8960 (online)

**LAUNCH DATE**

April 16, 2013

**FREQUENCY**

Thrice Monthly

**EDITORS-IN-CHIEF**

Bao-Gan Peng, Jerzy Tadeusz Chudek, George Kontogeorgos, Maurizio Serati, Ja Hyeon Ku

**EDITORIAL BOARD MEMBERS**

<https://www.wjgnet.com/2307-8960/editorialboard.htm>

**PUBLICATION DATE**

July 16, 2022

**COPYRIGHT**

© 2022 Baishideng Publishing Group Inc

**INSTRUCTIONS TO AUTHORS**

<https://www.wjgnet.com/bpg/gerinfo/204>

**GUIDELINES FOR ETHICS DOCUMENTS**

<https://www.wjgnet.com/bpg/GerInfo/287>

**GUIDELINES FOR NON-NATIVE SPEAKERS OF ENGLISH**

<https://www.wjgnet.com/bpg/gerinfo/240>

**PUBLICATION ETHICS**

<https://www.wjgnet.com/bpg/GerInfo/288>

**PUBLICATION MISCONDUCT**

<https://www.wjgnet.com/bpg/gerinfo/208>

**ARTICLE PROCESSING CHARGE**

<https://www.wjgnet.com/bpg/gerinfo/242>

**STEPS FOR SUBMITTING MANUSCRIPTS**

<https://www.wjgnet.com/bpg/GerInfo/239>

**ONLINE SUBMISSION**

<https://www.f6publishing.com>

## Novel mutation in the *SALL1* gene in a four-generation Chinese family with uraemia: A case report

Jia-Xi Fang, Jin-Shi Zhang, Min-Min Wang, Lin Liu

**Specialty type:** Medicine, research and experimental

**Provenance and peer review:**

Unsolicited article; Externally peer reviewed.

**Peer-review model:** Single blind

**Peer-review report's scientific quality classification**

Grade A (Excellent): A

Grade B (Very good): B, B, B

Grade C (Good): C

Grade D (Fair): 0

Grade E (Poor): 0

**P-Reviewer:** Gonzalez FM, Chile;

Kaewput W, Thailand;

Sureshkumar KK, United States;

Taheri S, Iran; Yuksel S, Turkey

**A-Editor:** Yao QG, China

**Received:** December 21, 2021

**Peer-review started:** December 21, 2021

**First decision:** April 8, 2022

**Revised:** April 15, 2022

**Accepted:** May 28, 2022

**Article in press:** May 28, 2022

**Published online:** July 16, 2022



**Jia-Xi Fang, Jin-Shi Zhang, Min-Min Wang, Lin Liu**, Department of Nephrology, Zhejiang Provincial People's Hospital, Affiliated People's Hospital, Hangzhou Medical College, Hangzhou 310014, Zhejiang Province, China

**Jia-Xi Fang, Jin-Shi Zhang, Min-Min Wang, Lin Liu**, Department of Nephrology, Chinese Medical Nephrology Key Laboratory of Zhejiang Province, Hangzhou 310014, Zhejiang Province, China

**Jia-Xi Fang, Min-Min Wang, Lin Liu**, Department of Nephrology, Zhejiang Provincial People's Hospital, Qingdao University, Hangzhou 310014, Zhejiang Province, China

**Jin-Shi Zhang**, School of Medicine, Hangzhou Normal University, Hangzhou 310018, Zhejiang Province, China

**Corresponding author:** Lin Liu, PhD, Doctor, Department of Nephrology, Zhejiang Provincial People's Hospital, Affiliated People's Hospital, Hangzhou Medical College, No. 158 Shangtang Road, Hangzhou 310014, Zhejiang Province, China. [colin\\_ll@163.com](mailto:colin_ll@163.com)

### Abstract

#### BACKGROUND

Approximately 10% of adults and nearly all children who receive renal replacement therapy have inherited risk factors or are related to genetic factors. In the past, due to the limitations of detection technology and the nonspecific manifestations of uraemia, the etiological diagnosis is unclear. In addition to common monogenic diseases and complex disorders, advanced testing techniques have led to the recognition of more hereditary renal diseases. Here, we report a four-generation Chinese family in which four individuals had a novel *SALL1* mutation and presented with uraemia or abnormal urine tests.

#### CASE SUMMARY

A 32-year-old man presented with end-stage renal disease with a 4-year history of dialysis. His father and paternal aunt both had a history of unexplained renal failure with haemodialysis, and his 10-year-old daughter presented with proteinuria. The patient had multiple congenital abnormalities, including bilateral overlapping toes, unilateral dysplastic external ears, and sensorineural hearing loss. His family members also presented with similar defects. Genetic testing revealed that the proband carried a novel heterozygous shift mutation in *SALL1*\_exon 2 (c.3437delG), and Sanger sequencing confirmed the same mutation in all affected family members.



## CONCLUSION

We report a novel *SALL1* exon 2 (c.3437delG) mutation and clinical syndrome with kidney disease, bilateral overlapping toes, unilateral dysplastic external ears, and sensorineural hearing loss in a four-generation Chinese family.

**Key Words:** *SALL1*; Gene mutation; Uraemia; Hereditary renal diseases; End stage renal disease; Case report

©The Author(s) 2022. Published by Baishideng Publishing Group Inc. All rights reserved.

**Core Tip:** We report a novel *SALL1* exon 2 (c.3437delG) mutation and clinical syndrome with kidney disease, bilateral overlapping toes, unilateral dysplastic external ears, and sensorineural hearing loss in a four-generation Chinese family. As patients with kidney diseases do not have specific clinical presentations, symptoms other than kidney disease were relatively hidden or easily ignored, thus resulting in missed diagnosis. Gene sequencing is recommended in patients with a family history and with extrarenal phenotypes to avoid blind use of immunosuppressive drugs, which may cause adverse effects.

**Citation:** Fang JX, Zhang JS, Wang MM, Liu L. Novel mutation in the *SALL1* gene in a four-generation Chinese family with uraemia: A case report. *World J Clin Cases* 2022; 10(20): 7068-7075

**URL:** <https://www.wjgnet.com/2307-8960/full/v10/i20/7068.htm>

**DOI:** <https://dx.doi.org/10.12998/wjcc.v10.i20.7068>

## INTRODUCTION

Hereditary kidney disease is one of the important causes of end-stage renal disease (ESRD) in patients requiring renal replacement therapy. Rapid advances in detection techniques have allowed more unexplained kidney diseases to be accurately diagnosed, including polycystic kidney disease, Alport syndrome, Fabry disease, Bartter syndromes, Gitelman syndromes, and other multifactorial disorders [1]. New genetic mutations causing kidney disease are constantly identified, along with other extrarenal phenotypes.

Townes-Brocks syndrome (TBS), first described by Townes and Brocks [2] in 1972, is a rare autosomal dominant disease resulting from mutations in the developmental gene *SALL1* [2]. Its main features are the triad of anorectal, hand, and external ear malformations. Another key characteristic of TBS is kidney involvement, which results in progression to ESRD early in life. A report of 154 patients with TBS identified renal anomalies in 43% of affected individuals [3]. Previous reports have shown that syndrome-related kidney and genitourinary defects include renal hypoplasia, unilateral renal agenesis, dysplastic kidneys, vesicoureteric reflux, meatal stenosis, and glandular hypoplasia [3]. Here, we report a four-generation family including four affected individuals suffering from kidney disease who carry a novel *SALL1* mutation. Among them, three patients progressed to ESRD.

## CASE PRESENTATION

### Chief complaints

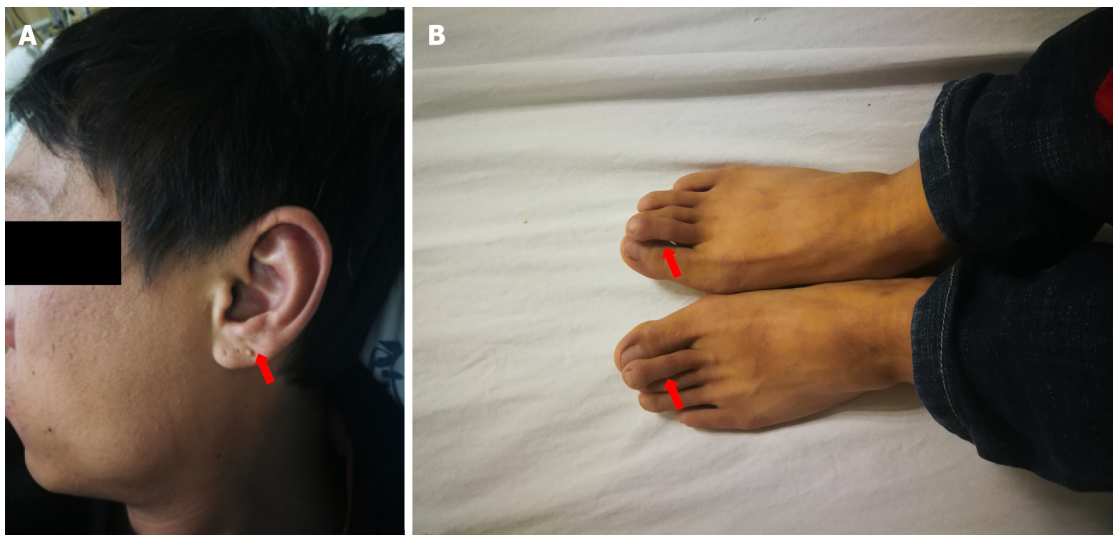
A 32-year-old man was admitted to our hospital because of ESRD characterized by severe hypertension and elevated serum creatinine (SCr) for 9 years and he had received renal dialysis for 4 years.

### History of present illness

Nine years ago, the patient was admitted to a hospital because of syncope and was diagnosed with uraemia. After diagnosis, he was treated with traditional Chinese medicine. He started renal dialysis 4 years ago because of gradually deteriorating kidney function with a SCr level of 900  $\mu\text{mol/L}$ . A kidney biopsy was not performed during the course of the kidney disease.

### History of past illness

The patient was born with multiple congenital abnormalities, including limb malformation (bilateral overlapping toes) and unilateral dysplastic external ears (Figure 1). A unilateral moderate degree of sensorineural hearing loss was noted when he was 10 years old.



DOI: 10.12998/wjcc.v10.i20.7068 Copyright ©The Author(s) 2022.

**Figure 1 Clinical features of the proband.** A: Unilateral dysplastic external ears. The left ear of the proband had a neoplasm on the earlobe; B: Bilateral overlapping toes, especially the second toes.

### Personal and family history

The family pedigree for the patient (proband, III.3) is shown in [Figure 2A](#). The patient's grandmother (I.2) died at an early age without a clear diagnosis due to the poor level of medical care. However, she presented with a sixth finger malformation, unilateral dysplastic external ears, and hearing loss. The patient's father (II.5) had unilateral dysplastic external ears, hearing loss, and bilateral overlapping toes. At the age of 53 years, he began dialysis therapy. The patient's aunt (II.4) was born with unilateral dysplastic external ears, hearing loss, and limb malformation (unilateral preaxial polydactyly of one hand). At the age of 53 years, she also began haemodialysis due to unexplained ESRD. The patient's daughter (IV.1) was born with bilateral dysplastic external ears, without limb malformation, and was found to have unilateral hearing dysfunction misdiagnosed as otitis media.

### Physical examination

Vital signs were in the normal ranges: Body temperature, 36.7 °C; respiratory rate, 18 breaths/min; pulse rate, 80 bpm; and blood pressure (under antihypertensive treatment), 134/85 mmHg. Limb malformation (bilateral overlapping toes) and unilateral dysplastic external ears existed. His ophthalmic examination results were normal, and no anorectal abnormalities were found.

### Laboratory examinations

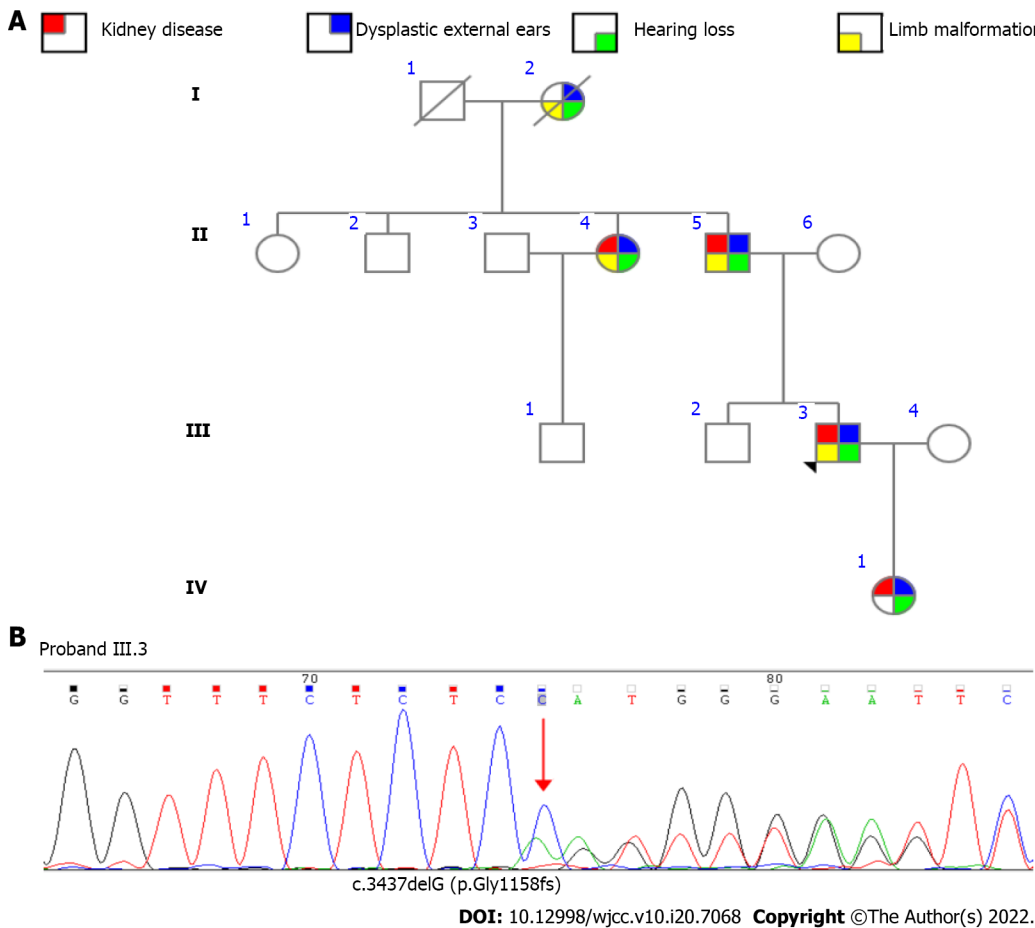
Laboratory analysis revealed an increased SCr level (941.9 μmol/L), high potassium level (6.87 mmol/L), high phosphate level (2.73 mmol/L), normal haemoglobin level (145 g/L), and high parathyroid hormone level (663.6 pg/mL). The patient was anuria.

### Imaging examinations

Ultrasound examination revealed bilaterally small kidneys (left kidney, 52 mm × 34 mm; right kidney, 50 mm × 25 mm) with multiple 5-7 mm medullary cysts. The urinary tract was normal, and no additional abnormalities of the liver, spleen, or pancreas were detected in the imaging studies.

## FINAL DIAGNOSIS

After obtaining informed consent, we conducted high-throughput detection and analysis of approximately 20000 genes of the proband, focusing on the genes related to uraemia and nephropathy. One pathogenic mutation, a heterozygous shift mutation in *SALL1*\_ exon 2 (c.3437delG), was found to be related to the patient's symptoms ([Figure 2B](#)). It was verified that the three relatives mentioned above carried the same mutation ([Figure 2B](#)). The genetic pattern of *SALL1* associated with TBS is autosomal dominant. It is speculated that this pathogenic mutation is the main cause of familial hereditary disease. Finally, based on clinical features and the presence of the *SALL1* pathogenic variant, the suspected diagnosis of TBS without imperforate anus was confirmed.



**Figure 2 Pedigree and gene mutation of the family.** A: Pedigree of the four-generation family; B: Analysis of *SALL1* mutations revealed the heterozygous mutation c.3473delG in the proband (III.3).

## TREATMENT

The patient received maintenance haemodialysis three times a week, sevelamer carbonate tablets of 1.6 g three times *per day*, calcitriol soft capsules of 0.5  $\mu\text{g}$  *per day*, and nifedipine controlled-release tablets of 60 mg *per day*.

## OUTCOME AND FOLLOW-UP

The patient and two relatives were on dialysis and received regular follow-up. His daughter currently presents with minimal proteinuria and normal SCr. She was treated with losartan potassium tablets of 25 mg *per day* and was followed every 3 mo.

## DISCUSSION

In this four-generation family diagnosed with TBS with renal manifestations, uraemia was the first symptom to prompt the affected members to go to the hospital. The diagnosis of TBS was confirmed by a genetic test in four family members, three of whom had already progressed to ESRF. This indicates that symptoms other than kidney disease were relatively hidden or easily ignored and resulted in missed diagnosis.

The transcoding mutation resulted in a change in the amino acid at position 1158 from glycine to glutamate, which changed the subsequent reading frame and caused advanced termination at the downstream codon 45. This mutation site has not been previously included in the ClinVar database. The frequency of mutation at this locus in the normal East Asian population has not been reported.

Since Townes and Brocks[2] first described TBS in 1972, hundreds of similar cases have been reported. It is characterized by ear anomalies, thumb anomalies (preaxial polydactyly, triphalangeal thumbs, and hypoplastic thumbs), and anal anomalies. The prevalence of TBS is estimated to be

Table 1 Details of *SALL1* gene variations in 76 patients diagnosed with Townes-Brocks syndrome with renal manifestations

Genetic finding	F/N	Gender	Phenotype						Ref.
			BRA	URA	PK	VR	RF	RFI	
c.313delA	FA/N1	F	0/1	0/1	0/1	0/1	0/1	1/1	[7]
c.419delC	FA/N1	M	0/1	1/1	0/1	0/1	0/1	1	[15]
c.764delT	FA/N1	M	0/1	0/1	1/1	0/1	1/1	0/1	[3]
c.792delGC	FA/N2	M/F	0/2	1/2	0/2	2/2	0/2	0/2	[16]
c.817delG	FA/N1	M	0/1	1/1	0/1	0/1	1/1	0/1	[17]
c.981insTGGC	FA/N1	M	0/1	1/1	0/1	0/1	0/1	1/1	[18]
c.995delC	FA/N1	M	1/1	0/1	0/1	0/1	0/1	0/1	[7]
c.1047dupC	FA/N1	M	0/1	0/1	0/1	1/1	0/1	0/1	[7]
c.1119del79	FA/N1	F	1/1	0/1	0/1	0/1	1/1	0/1	[7]
c.1134delT	FA/N1	F	0/1	1/1	0/1	0/1	0/1	0/1	[7]
c.1145insTA	FA/N1	M	0/1	0/1	1/1	0/1	0/1	1/1	[3]
	FB/N1	M	0/1	1/1	0/1	0/1	0/1	0/1	[7]
c.1146delT	FA/N3	2F/M	0/3	2/3	0/3	0/3	0/3	3/3	[15]
c.1174delCT	FA/N1	M	0/1	1/1	0/1	0/1	0/1	0/1	[7]
c.1200del7	FA/N1	M	1/1	0/1	0/1	0/1	1/1	0/1	[15]
c.1263delC	FA/N1	F	1/1	0/1	0/1	0/1	1/1	0/1	[3]
c.1273delC	FA/N1	M	0/1	1/1	0/1	0/1	0/1	0/1	[7]
c.1277del2bp	FA/N1	F	0/1	0/1	0/1	0/1	0/1	1/1	[15]
c.1291del10	FA/N2	2M	2/2	0/2	0/2	0/2	0/2	2/2	[15]
c.1321dupA	FA/N1	F	0/1	1/1	0/1	0/1	0/1	1/1	[3]
c.1327delG	FA/N2	M/?	1/2	1/2	0/2	0/2	0/2	0/2	[3]
c.1347delCA	FA/N1	M	1/1	0/1	0/1	0/1	0/1	0/1	[19]
c.1404dupG	FA/N9	4F/5M	3/9	3/9	0/9	2/9	2/9	1/9	[3]
c.1451del7insT	FA/N1	M	0/1	1/1	0/1	0/1	1/1	0/1	[18]
c.1470delG	FA/N1	M	0/1	0/1	0/1	1/1	0/1	1/1	[20]
c.1487del562	FA/N1	M	0/1	1/1	0/1	0/1	0/1	0/1	[19]
c.1516dupAT	FA/N2	2M	2/2	0/2	0/2	2/2	0/2	0/2	[7]
c.1819delG	FA/N3	2F/M	2/3	0/3	0/3	1/3	1/3	1/3	[21]
c.3249del7	FA/N1	M	1/1	0/1	0/1	1/1	0/1	0/1	[7]
c.3414delAT	FA/N1	M	0/1	1/1	0/1	0/1	0/1	0/1	[7]
	FB/N1	M	0/1	0/1	0/1	1/1	0/1	0/1	[22]
Total (%)	F31/N47	15F/31M/1?	16/47 (34)	18/47 (38)	2/47 (4)	11/47 (23)	9/47 (19)	14/47 (30)	
p.Gln272X	FA/N1	M	0/1	1/1	0/1	0/1	0/1	0/1	[7]
p.Leu275X	FA/N1	M	0/1	0/1	0/1	1/1	0/1	0/1	[12]
p.Arg276X	FA/N2	/	1/2	0/2	0/2	0/2	1/2	0/2	[19]
	F B/N1	F	1/1	0/1	0/1	0/1	0/1	0/1	[23]
	F C/N3	3M	0/3	0/3	0/3	0/3	1/3	2/3	[24]
	FD/N2	2M	0/2	1/2	1/2	0/2	0/2	1/2	[15]
	FE/N1	F	0/1	1/1	0/1	0/1	0/1	1/1	[25]
	FF/N1	F	0/1	1/1	0/1	0/1	0/1	0/1	[26]

P.Gln243X	FA/N2	F	2/2	0/2	0/2	0/2	2/2	0/2	[10]
p.Gln323X	FA/N2	2M	1/2	0/2	0/2	1/2	2/2	0/2	[3]
p.Ser371X	FA/N1	M	1/1	0/1	0/1	1/1	0/1	1/1	[3]
p.Ser372X	FA/N2	M/F	0/2	1/2	0/2	1/2	0/2	0/2	[17]
p.Lys419X	FA/N2	2F	2/2	0/2	0/2	0/2	1/2	0/2	[3]
	FB/N2	2F	0/2	2/2	0/2	0/2	0/2	0/2	[27]
p.Tyr503X	FA/N1	F	1/1	0/1	0/1	0/1	0/1	0/1	[21]
p.Gln507X	FA/N1	F	1/1	0/1	0/1	0/1	1/1	0/1	[3]
p.Gln927X	FA/N1	M	0/1	0/1	0/1	1/1	0/1	0/1	[3]
p.Arg1054X	FA/N1	F	0/1	0/1	1/1	0/1	0/1	1/1	[28]
Total (%)	F17/N27	13F/12M/2?	10/27 (37)	7/27 (26)	2/27 (7)	5/27 (18)	8/27 (30)	6/27 (22)	
del 3384 dp	FA/N1	F	0/1	0/1	0/1	1/1	1/1	0/1	[3]
IVS2/19T	FA/N1	M	1/1	0/1	0/1	0/1	1/1	0/1	[21]
Total (%)	F51/N76	29F/44M/3?	25/76 (33)	25/76 (33)	4/76 (5)	17/76 (22)	17/76 (22)	20/76 (26)	

BRA: Bilateral renal agenesis; URA: Unilateral renal agenesis; PK: Polycystic kidney; VR: Vesicoureteral reflux; RF: Renal failure; RFI: Renal function impaired; F/N: Family/number of the patients.

1/250000[4]. The gene mutated in TBS is *SALL1*, which is located on chromosome 16q12.1 and encodes a zinc finger protein believed to act as a transcriptional repressor[5]. *SALL1* is expressed in the metanephric mesenchyme surrounding the ureteric bud. Homozygous deletion of *SALL1* produces incomplete ureteric bud outgrowth. Therefore, *SALL1* is important for metanephros development[6]. Most mutations occur within a hotspot prior to the first C2H2 zinc finger domain encoded within exon 2 and result in the truncation of the protein upstream of the DNA binding domain[7].

In a murine experiment, all of the *SALL1* knockout mice (*SALL1*<sup>-/-</sup>) died within 24 h after birth owing to renal agenesis or severe dysgenesis[6]. Mutant mice that produced a truncated *SALL1* protein exhibited more severe defects than *SALL1*-null mice, including renal agenesis, exencephaly, and limb and anal deformities[8]. This finding may be explained by the fact that truncated proteins arising from certain *SALL1* mutations can disrupt cilia formation and function. Therefore, TBS might be considered a ciliopathy-like disease, just as the proband presented with multiple renal cysts. A recent study showed that the Dishevelled Binding Antagonist Of Beta Catenin 1 (DACT1) c.1256G>A nonsense variant was causative of a specific genetic syndrome with features overlapping those of TBS[3]. Therefore, genetic testing to identify the mutated gene is critical for the diagnosis.

Newman first drew attention to symptomatic renal failure in TBS[9]. A previous study of TBS showed that 43% of affected individuals exhibited renal abnormalities. To determine genotype-phenotype correlations in the renal manifestations of TBS, we reviewed 76 affected individuals from 51 families, including 44 men (57.9%), 29 women (38.1%), and three (3.9%) for whom sex was not reported, giving a female-to-male ratio of 0.5:1. The details of the *SALL1* gene variations and renal manifestations in these 76 patients with TBS are summarized in Table 1. Overall, 43 different variants were identified, including 29 frameshift mutations, 12 nonsense mutations, one intronic mutation, and one exonic deletion. The most common renal manifestations were renal hypodysplasia and unilateral renal agenesis (*n* = 25), followed by vesicoureteral reflux (*n* = 17). Almost half of the individuals had varying degrees of renal impairment, and 22% of the individuals progressed to renal failure. Some of the patients successfully underwent kidney transplantation, and two of them experienced graft rejection[3,7,9,10].

Because TBS is a polymorphic syndrome, it needs to be distinguished from the following syndromes: Vertebral, anal, cardiac, tracheal-esophageal, renal (VACTER) and limb anomalies association[11], Goldenhar syndrome (oculo-auriculo-vertebral; impaired development of structures such as the eyes, ears, lip, tongue, palate, mandible, and maxilla and deformations of the tooth structures)[12], Okhiro syndrome (forearm malformations with Duane syndrome of eye retraction)[13], branchio-oto-renal syndrome (hearing loss, auricular malformations, branchial arch remnants, and renal anomalies)[3], and syndactyly, telecanthus, anogenital, and renal malformations syndrome[14].

As patients with kidney diseases do not have specific clinical presentations, it is possible to find rare diseases in any dialysis patients. Doctors are advised to concern about the following issues: Ask patients for family history of kidney diseases, see whether the patient has ocular or hear pathologies, see whether there is poliglobulia or abdominal masses or a family history of cerebral aneurysms, and verify that if there is neuropathy or cardiopathy when they do not obey to uremia or hypertension alone. Gene sequencing is recommended in the following categories of patients with kidney disease: Individuals with a family history of kidney disease; individuals with an unexplained renal phenotype associated

with extrarenal phenotypes, especially in the eyes and ears; and individuals with polycystic kidney disease. Patients and their families can avoid the blind use of immunosuppressive drugs, which may cause adverse effects.

---

## CONCLUSION

We report a novel *SALL1* exon 2 (c.3437delG) mutation and clinical syndrome with kidney disease, bilateral overlapping toes, unilateral dysplastic external ears, and sensorineural hearing loss in a four-generation Chinese family.

---

## ACKNOWLEDGEMENTS

The authors are grateful to the family for their participation.

---

## FOOTNOTES

**Author contributions:** Fang JX and Liu L collected the family data, reviewed the literature, and participated in manuscript writing; Zhang JS and Wang MM assisted in literature retrieval and review; Wang MM provided critical advice and revised the manuscript; all authors reviewed the final manuscript.

**Supported by** Zhejiang Provincial Natural Science Foundation of China, No. LQ19H050003; and General Project Funds from the Health Department of Zhejiang Province, No. 2020KY439.

**Informed consent statement:** Informed consent was obtained from the patient for the publication of this case report.

**Conflict-of-interest statement:** All the authors report no relevant conflicts of interest for this article.

**CARE Checklist (2016) statement:** The authors have read the CARE Checklist (2016), and the manuscript was prepared and revised according to the CARE Checklist (2016).

**Open-Access:** This article is an open-access article that was selected by an in-house editor and fully peer-reviewed by external reviewers. It is distributed in accordance with the Creative Commons Attribution NonCommercial (CC BY-NC 4.0) license, which permits others to distribute, remix, adapt, build upon this work non-commercially, and license their derivative works on different terms, provided the original work is properly cited and the use is non-commercial. See: <https://creativecommons.org/licenses/by-nc/4.0/>

**Country/Territory of origin:** China

**ORCID number:** Jia-Xi Fang 0000-0001-5917-0125; Jin-Shi Zhang 0000-0002-5795-5575; Min-Min Wang 0000-0002-3348-6145; Lin Liu 0000-0002-7192-1603.

**S-Editor:** Fan JR

**L-Editor:** Wang TQ

**P-Editor:** Fan JR

---

## REFERENCES

- 1 **Mehta L**, Jim B. Hereditary Renal Diseases. *Semin Nephrol* 2017; **37**: 354-361 [PMID: 28711074 DOI: 10.1016/j.semnephrol.2017.05.007]
- 2 **Townes PL**, Brocks ER. Hereditary syndrome of imperforate anus with hand, foot, and ear anomalies. *J Pediatr* 1972; **81**: 321-326 [PMID: 5042490 DOI: 10.1016/s0022-3476(72)80302-0]
- 3 **Miller EM**, Hopkin R, Bao L, Ware SM. Implications for genotype-phenotype predictions in Townes-Brocks syndrome: case report of a novel *SALL1* deletion and review of the literature. *Am J Med Genet A* 2012; **158A**: 533-540 [PMID: 22308078 DOI: 10.1002/ajmg.a.34426]
- 4 **Martínez-Frías ML**, Bermejo Sánchez E, Arroyo Carrera I, Pérez Fernández JL, Pardo Romero M, Burón Martínez E, Hernández Ramón F. [The Townes-Brocks syndrome in Spain: the epidemiological aspects in a consecutive series of cases]. *An Esp Pediatr* 1999; **50**: 57-60 [PMID: 10083645]
- 5 **Netzer C**, Rieger L, Brero A, Zhang CD, Hinzke M, Kohlhase J, Bohlander SK. *SALL1*, the gene mutated in Townes-Brocks syndrome, encodes a transcriptional repressor which interacts with TRF1/PIN2 and localizes to pericentromeric heterochromatin. *Hum Mol Genet* 2001; **10**: 3017-3024 [PMID: 11751684 DOI: 10.1093/hmg/10.26.3017]
- 6 **Nishinakamura R**, Takasato M. Essential roles of *Sall1* in kidney development. *Kidney Int* 2005; **68**: 1948-1950 [PMID:

- 16221172 DOI: [10.1111/j.1523-1755.2005.00626.x](https://doi.org/10.1111/j.1523-1755.2005.00626.x)]
- 7 **Botzenhart EM**, Bartalini G, Blair E, Brady AF, Elmslie F, Chong KL, Christy K, Torres-Martinez W, Danesino C, Deardorff MA, Fryns JP, Marlin S, Garcia-Minaur S, Hellenbroich Y, Hay BN, Penttinen M, Shashi V, Terhal P, Van Maldergem L, Whiteford ML, Zackai E, Kohlhase J. Townes-Brocks syndrome: twenty novel SALL1 mutations in sporadic and familial cases and refinement of the SALL1 hot spot region. *Hum Mutat* 2007; **28**: 204-205 [PMID: [17221874](https://pubmed.ncbi.nlm.nih.gov/17221874/) DOI: [10.1002/humu.9476](https://doi.org/10.1002/humu.9476)]
  - 8 **Kiefer SM**, Ohlemiller KK, Yang J, McDill BW, Kohlhase J, Rauchman M. Expression of a truncated Sall1 transcriptional repressor is responsible for Townes-Brocks syndrome birth defects. *Hum Mol Genet* 2003; **12**: 2221-2227 [PMID: [12915476](https://pubmed.ncbi.nlm.nih.gov/12915476/) DOI: [10.1093/hmg/ddg233](https://doi.org/10.1093/hmg/ddg233)]
  - 9 **Newman WG**, Brunet MD, Donnai D. Townes-Brocks syndrome presenting as end stage renal failure. *Clin Dysmorphol* 1997; **6**: 57-60 [PMID: [9072124](https://pubmed.ncbi.nlm.nih.gov/9072124/)]
  - 10 **Beaudoux O**, Lebre AS, Doco Fenzy M, Spodenkiewicz M, Canivet E, Colosio C, Poirsier C. Adult diagnosis of Townes-Brocks syndrome with renal failure: Two related cases and review of literature. *Am J Med Genet A* 2021; **185**: 937-944 [PMID: [33438842](https://pubmed.ncbi.nlm.nih.gov/33438842/) DOI: [10.1002/ajmg.a.62050](https://doi.org/10.1002/ajmg.a.62050)]
  - 11 **van de Putte R**, Dworschak GC, Brosens E, Reutter HM, Marcelis CLM, Acuna-Hidalgo R, Kurtas NE, Steehouwer M, Dunwoodie SL, Schmiedeke E, Märzheuser S, Schwarzer N, Brooks AS, de Klein A, Sloots CEJ, Tibboel D, Brisighelli G, Morandi A, Bedeschi MF, Bates MD, Levitt MA, Peña A, de Blaauw I, Roelvelde N, Brunner HG, van Rooij IALM, Hoischen A. A Genetics-First Approach Revealed Monogenic Disorders in Patients With ARM and VACTERL Anomalies. *Front Pediatr* 2020; **8**: 310 [PMID: [32656166](https://pubmed.ncbi.nlm.nih.gov/32656166/) DOI: [10.3389/fped.2020.00310](https://doi.org/10.3389/fped.2020.00310)]
  - 12 **Liberalleso PBN**, Cordeiro ML, Karuta SCV, Koladiez KRJ, Nitsche A, Zeigelboim BS, Raskin S, Rauchman M. Phenotypic and genotypic aspects of Townes-Brook syndrome: case report of patient in southern Brazil with a new SALL1 hotspot region nonsense mutation. *BMC Med Genet* 2017; **18**: 125 [PMID: [29110636](https://pubmed.ncbi.nlm.nih.gov/29110636/) DOI: [10.1186/s12881-017-0483-7](https://doi.org/10.1186/s12881-017-0483-7)]
  - 13 **Kohlhase J**, Heinrich M, Schubert L, Liebers M, Kispert A, Laccone F, Turnpenny P, Winter RM, Reardon W. Okhiro syndrome is caused by SALL4 mutations. *Hum Mol Genet* 2002; **11**: 2979-2987 [PMID: [12393809](https://pubmed.ncbi.nlm.nih.gov/12393809/) DOI: [10.1093/hmg/11.23.2979](https://doi.org/10.1093/hmg/11.23.2979)]
  - 14 **Li AL**, Borooah S, Nudleman E. Multimodal imaging of retinal findings in syndactyly, telecanthus, anogenital, and renal malformations (STAR) syndrome. *Am J Ophthalmol Case Rep* 2022; **25**: 101284 [PMID: [35128153](https://pubmed.ncbi.nlm.nih.gov/35128153/) DOI: [10.1016/j.ajoc.2022.101284](https://doi.org/10.1016/j.ajoc.2022.101284)]
  - 15 **Kohlhase J**, Taschner PE, Burfeind P, Pasche B, Newman B, Blanck C, Breuning MH, ten Kate LP, Maaswinkel-Mooy P, Mitulla B, Seidel J, Kirkpatrick SJ, Pauli RM, Wargowski DS, Devriendt K, Proesmans W, Gabrielli O, Coppa GV, Wesby-van Swaay E, Trembath RC, Schinzel AA, Reardon W, Seemanova E, Engel W. Molecular analysis of SALL1 mutations in Townes-Brocks syndrome. *Am J Hum Genet* 1999; **64**: 435-445 [PMID: [9973281](https://pubmed.ncbi.nlm.nih.gov/9973281/) DOI: [10.1086/302238](https://doi.org/10.1086/302238)]
  - 16 **Surka WS**, Kohlhase J, Neunert CE, Schneider DS, Proud VK. Unique family with Townes-Brocks syndrome, SALL1 mutation, and cardiac defects. *Am J Med Genet* 2001; **102**: 250-257 [PMID: [11484202](https://pubmed.ncbi.nlm.nih.gov/11484202/) DOI: [10.1002/1096-8628\(20010815\)102:3<250::aid-ajmg1479>3.0.co;2-q](https://doi.org/10.1002/1096-8628(20010815)102:3<250::aid-ajmg1479>3.0.co;2-q)]
  - 17 **Salerno A**, Kohlhase J, Kaplan BS. Townes-Brocks syndrome and renal dysplasia: a novel mutation in the SALL1 gene. *Pediatr Nephrol* 2000; **14**: 25-28 [PMID: [10654325](https://pubmed.ncbi.nlm.nih.gov/10654325/) DOI: [10.1007/s004670050006](https://doi.org/10.1007/s004670050006)]
  - 18 **Faguer S**, Pillet A, Chassaing N, Merhenberger M, Bernadet-Monrozies P, Guitard J, Chauveau D. Nephropathy in Townes-Brocks syndrome (SALL1 mutation): imaging and pathological findings in adulthood. *Nephrol Dial Transplant* 2009; **24**: 1341-1345 [PMID: [19204018](https://pubmed.ncbi.nlm.nih.gov/19204018/) DOI: [10.1093/ndt/gfp014](https://doi.org/10.1093/ndt/gfp014)]
  - 19 **Marlin S**, Blanchard S, Slim R, Lacombe D, Denoyelle F, Alessandri JL, Calzolari E, Drouin-Garraud V, Ferraz FG, Fourmaintraux A, Philip N, Toubanc JE, Petit C. Townes-Brocks syndrome: detection of a SALL1 mutation hot spot and evidence for a position effect in one patient. *Hum Mutat* 1999; **14**: 377-386 [PMID: [10533063](https://pubmed.ncbi.nlm.nih.gov/10533063/) DOI: [10.1002/\(SICI\)1098-1004\(199911\)14:5<377::AID-HUMU3>3.0.CO;2-A](https://doi.org/10.1002/(SICI)1098-1004(199911)14:5<377::AID-HUMU3>3.0.CO;2-A)]
  - 20 **Choi WI**, Kim JH, Yoo HW, Oh SH. A family with Townes-Brocks syndrome with congenital hypothyroidism and a novel mutation of the SALL1 gene. *Korean J Pediatr* 2010; **53**: 1018-1021 [PMID: [21253317](https://pubmed.ncbi.nlm.nih.gov/21253317/) DOI: [10.3345/kjp.2010.53.12.1018](https://doi.org/10.3345/kjp.2010.53.12.1018)]
  - 21 **Blanck C**, Kohlhase J, Engels S, Burfeind P, Engel W, Bottani A, Patel MS, Kroes HY, Cobben JM. Three novel SALL1 mutations extend the mutational spectrum in Townes-Brocks syndrome. *J Med Genet* 2000; **37**: 303-307 [PMID: [10819639](https://pubmed.ncbi.nlm.nih.gov/10819639/) DOI: [10.1136/jmg.37.4.303](https://doi.org/10.1136/jmg.37.4.303)]
  - 22 **Lawrence C**, Hong-McAtee I, Hall B, Hartsfield J, Rutherford A, Bonilla T, Bay C. Endocrine abnormalities in Townes-Brocks syndrome. *Am J Med Genet A* 2013; **161A**: 2266-2273 [PMID: [23894113](https://pubmed.ncbi.nlm.nih.gov/23894113/) DOI: [10.1002/ajmg.a.36104](https://doi.org/10.1002/ajmg.a.36104)]
  - 23 **Keegan CE**, Mulliken JB, Wu BL, Korf BR. Townes-Brocks syndrome vs expanded spectrum hemifacial microsomia: review of eight patients and further evidence of a "hot spot" for mutation in the SALL1 gene. *Genet Med* 2001; **3**: 310-313 [PMID: [11478532](https://pubmed.ncbi.nlm.nih.gov/11478532/) DOI: [10.1097/00125817-200107000-00007](https://doi.org/10.1097/00125817-200107000-00007)]
  - 24 **Kohlhase J**, Liebers M, Backe J, Baumann-Müller A, Bembea M, Destrée A, Gattas M, Grüssner S, Müller T, Mortier G, Skrypnyk C, Yano S, Wirbelauer J, Michaelis RC. High incidence of the R276X SALL1 mutation in sporadic but not familial Townes-Brocks syndrome and report of the first familial case. *J Med Genet* 2003; **40**: e127 [PMID: [14627694](https://pubmed.ncbi.nlm.nih.gov/14627694/) DOI: [10.1136/jmg.40.11.e127](https://doi.org/10.1136/jmg.40.11.e127)]
  - 25 **van Bever Y**, Gischler SJ, Hoeve HL, Smit LS, Nauta J, Dooijes D. Obstructive apneas and severe dysphagia in a girl with Townes-Brocks syndrome and atypical feet involvement. *Eur J Med Genet* 2009; **52**: 426-429 [PMID: [19737635](https://pubmed.ncbi.nlm.nih.gov/19737635/) DOI: [10.1016/j.ejmg.2009.09.001](https://doi.org/10.1016/j.ejmg.2009.09.001)]
  - 26 **Barry JS**, Reddy MA. The association of an epibulbar dermoid and Duane syndrome in a patient with a SALL1 mutation (Townes-Brocks Syndrome). *Ophthalmic Genet* 2008; **29**: 177-180 [PMID: [19005989](https://pubmed.ncbi.nlm.nih.gov/19005989/) DOI: [10.1080/13816810802354224](https://doi.org/10.1080/13816810802354224)]
  - 27 **Sudo Y**, Numakura C, Abe A, Aiba S, Matsunaga A, Hayasaka K. Phenotypic variability in a family with Townes-Brocks syndrome. *J Hum Genet* 2010; **55**: 550-551 [PMID: [20520617](https://pubmed.ncbi.nlm.nih.gov/20520617/) DOI: [10.1038/jhg.2010.64](https://doi.org/10.1038/jhg.2010.64)]
  - 28 **Vodopituz J**, Zoller H, Fenwick AL, Arnhold R, Schmid M, Prayer D, Müller T, Repa A, Pollak A, Aufrecht C, Wilkie AO, Janecke AR. Homozygous SALL1 mutation causes a novel multiple congenital anomaly-mental retardation syndrome. *J Pediatr* 2013; **162**: 612-617 [PMID: [23069192](https://pubmed.ncbi.nlm.nih.gov/23069192/) DOI: [10.1016/j.jpeds.2012.08.042](https://doi.org/10.1016/j.jpeds.2012.08.042)]



Published by **Baishideng Publishing Group Inc**  
7041 Koll Center Parkway, Suite 160, Pleasanton, CA 94566, USA  
**Telephone:** +1-925-3991568  
**E-mail:** [bpgoffice@wjgnet.com](mailto:bpgoffice@wjgnet.com)  
**Help Desk:** <https://www.f6publishing.com/helpdesk>  
<https://www.wjgnet.com>

