

# World Journal of *Gastrointestinal Surgery*

*World J Gastrointest Surg* 2023 February 27; 15(2): 121-306



## Contents

Monthly Volume 15 Number 2 February 27, 2023

## EDITORIAL

- 121 Hot topics in pancreatic cancer management  
*Caputo D*

## REVIEW

- 127 Minimum platelet count threshold before invasive procedures in cirrhosis: Evolution of the guidelines  
*Biolato M, Vitale F, Galasso T, Gasbarrini A, Grieco A*
- 142 Comprehensive multimodal management of borderline resectable pancreatic cancer: Current status and progress  
*Wu HY, Li JW, Li JZ, Zhai QL, Ye JY, Zheng SY, Fang K*

## MINIREVIEWS

- 163 Impact of endoscopic ultrasound-guided radiofrequency ablation in managing pancreatic malignancy  
*Lesmana CRA*
- 169 Current management of concomitant cholelithiasis and common bile duct stones  
*Pavlidis ET, Pavlidis TE*
- 177 Surveillance strategies following curative resection and non-operative approach of rectal cancer: How and how long? Review of current recommendations  
*Lauretta A, Montori G, Guerrini GP*

## ORIGINAL ARTICLE

## Retrospective Study

- 193 Causes of epigastric pain and vomiting after laparoscopic-assisted radical right hemicolectomy - superior mesenteric artery syndrome  
*Xie J, Bai J, Zheng T, Shu J, Liu ML*
- 201 Analysis of the impact of ERAS-based respiratory function training on older patients' ability to prevent pulmonary complications after abdominal surgery  
*Gu YX, Wang XY, Xu MX, Qian JJ, Wang Y*
- 211 Prognostic value of preoperative immune-nutritional scoring systems in remnant gastric cancer patients undergoing surgery  
*Zhang Y, Wang LJ, Li QY, Yuan Z, Zhang DC, Xu H, Yang L, Gu XH, Xu ZK*
- 222 Efficacy and safety of preoperative immunotherapy in patients with mismatch repair-deficient or microsatellite instability-high gastrointestinal malignancies  
*Li YJ, Liu XZ, Yao YF, Chen N, Li ZW, Zhang XY, Lin XF, Wu AW*

### Observational Study

- 234 Hepatobiliary manifestations following two-stages elective laparoscopic restorative proctocolectomy for patients with ulcerative colitis: A prospective observational study

*Habeeb TAAM, Hussain A, Podda M, Cianci P, Ramshaw B, Safwat K, Amr WM, Wasefy T, Fiad AA, Mansour MI, Moursi AM, Osman G, Qasem A, Fawzy M, Alsaad MIA, Kalmoush AE, Nassar MS, Mustafa FM, Badawy MHM, Hamdy A, Elbelkasi H, Mousa B, Metwalli AEM, Mawla WA, Elaidy MM, Baghdadi MA, Raafat A*

### SYSTEMATIC REVIEWS

- 249 Hypophosphatemia as a prognostic tool for post-hepatectomy liver failure: A systematic review

*Riauka R, Ignatavicius P, Barauskas G*

### META-ANALYSIS

- 258 Network meta-analysis of the prognosis of curative treatment strategies for recurrent hepatocellular carcinoma after hepatectomy

*Chen JL, Chen YS, Ker CG*

- 273 Does size matter for resection of giant versus non-giant hepatocellular carcinoma? A meta-analysis

*Lee AJ, Wu AG, Yew KC, Shelat VG*

### CASE REPORT

- 287 Primary malignant melanoma of the esophagus combined with squamous cell carcinoma: A case report

*Zhu ML, Wang LY, Bai XQ, Wu C, Liu XY*

- 294 Mesh erosion into the colon following repair of parastomal hernia: A case report

*Zhang Y, Lin H, Liu JM, Wang X, Cui YF, Lu ZY*

### LETTER TO THE EDITOR

- 303 Fecal microbiota transplantation as potential first-line treatment for patients with *Clostridioides difficile* infection and prior appendectomy

*Zhao JW, Chang B, Sang LX*

**ABOUT COVER**

Editorial Board Member of *World Journal of Gastrointestinal Surgery*, Dirk Uhlmann, FACS, MD, PhD, Chief Doctor, Professor, Department of Visceral, Thoracic and Vascular Surgery, Klinikum Döbeln, Döbeln 04720, Germany. [dirk.uhlmann@klinikum-doebeln.de](mailto:dirk.uhlmann@klinikum-doebeln.de)

**AIMS AND SCOPE**

The primary aim of *World Journal of Gastrointestinal Surgery* (WJGS, *World J Gastrointest Surg*) is to provide scholars and readers from various fields of gastrointestinal surgery with a platform to publish high-quality basic and clinical research articles and communicate their research findings online.

WJGS mainly publishes articles reporting research results and findings obtained in the field of gastrointestinal surgery and covering a wide range of topics including biliary tract surgical procedures, biliopancreatic diversion, colectomy, esophagectomy, esophagostomy, pancreas transplantation, and pancreatectomy, etc.

**INDEXING/ABSTRACTING**

The WJGS is now abstracted and indexed in Science Citation Index Expanded (SCIE, also known as SciSearch®), Current Contents/Clinical Medicine, Journal Citation Reports/Science Edition, PubMed, PubMed Central, Reference Citation Analysis, China National Knowledge Infrastructure, China Science and Technology Journal Database, and Superstar Journals Database. The 2022 Edition of Journal Citation Reports® cites the 2021 impact factor (IF) for WJGS as 2.505; IF without journal self cites: 2.473; 5-year IF: 3.099; Journal Citation Indicator: 0.49; Ranking: 104 among 211 journals in surgery; Quartile category: Q2; Ranking: 81 among 93 journals in gastroenterology and hepatology; and Quartile category: Q4.

**RESPONSIBLE EDITORS FOR THIS ISSUE**

Production Editor: Rui-Rui Wu; Production Department Director: Xiang Li; Editorial Office Director: Jia-Ru Fan.

**NAME OF JOURNAL**

*World Journal of Gastrointestinal Surgery*

**ISSN**

ISSN 1948-9366 (online)

**LAUNCH DATE**

November 30, 2009

**FREQUENCY**

Monthly

**EDITORS-IN-CHIEF**

Peter Schemmer

**EDITORIAL BOARD MEMBERS**

<https://www.wjgnet.com/1948-9366/editorialboard.htm>

**PUBLICATION DATE**

February 27, 2023

**COPYRIGHT**

© 2023 Baishideng Publishing Group Inc

**INSTRUCTIONS TO AUTHORS**

<https://www.wjgnet.com/bpg/gerinfo/204>

**GUIDELINES FOR ETHICS DOCUMENTS**

<https://www.wjgnet.com/bpg/GerInfo/287>

**GUIDELINES FOR NON-NATIVE SPEAKERS OF ENGLISH**

<https://www.wjgnet.com/bpg/gerinfo/240>

**PUBLICATION ETHICS**

<https://www.wjgnet.com/bpg/GerInfo/288>

**PUBLICATION MISCONDUCT**

<https://www.wjgnet.com/bpg/gerinfo/208>

**ARTICLE PROCESSING CHARGE**

<https://www.wjgnet.com/bpg/gerinfo/242>

**STEPS FOR SUBMITTING MANUSCRIPTS**

<https://www.wjgnet.com/bpg/GerInfo/239>

**ONLINE SUBMISSION**

<https://www.f6publishing.com>



## Impact of endoscopic ultrasound-guided radiofrequency ablation in managing pancreatic malignancy

Cosmas Rinaldi Adithya Lesmana

**Specialty type:** Gastroenterology and hepatology

**Provenance and peer review:** Invited article; Externally peer reviewed.

**Peer-review model:** Single blind

**Peer-review report's scientific quality classification**

Grade A (Excellent): 0  
Grade B (Very good): B, B  
Grade C (Good): C, C  
Grade D (Fair): D  
Grade E (Poor): 0

**P-Reviewer:** Arcidiacono PG, Italy; Sahewalla A, India; Yao J, China

**Received:** September 23, 2022

**Peer-review started:** September 23, 2022

**First decision:** October 5, 2022

**Revised:** October 21, 2022

**Accepted:** January 3, 2023

**Article in press:** January 3, 2023

**Published online:** February 27, 2023



**Cosmas Rinaldi Adithya Lesmana**, Hepatobiliary Division, Internal Medicine Department, Dr. Cipto Mangunkusumo National General Hospital, Universitas Indonesia, Jakarta 10430, Indonesia

**Cosmas Rinaldi Adithya Lesmana**, Digestive Disease and Gastrointestinal Oncology Center, Medistra Hospital, Jakarta 12950, Indonesia

**Cosmas Rinaldi Adithya Lesmana**, Gastrointestinal Cancer Center, MRCCC Siloam Semanggi Hospital, Jakarta 12930, Indonesia

**Corresponding author:** Cosmas Rinaldi Adithya Lesmana, FACP, FACP, MD, PhD, Assistant Professor, Senior Lecturer, Hepatobiliary Division, Internal Medicine Department, Dr. Cipto Mangunkusumo National General Hospital, Universitas Indonesia, JL. Diponegoro 71 Jakarta Pusat, Jakarta 10430, Indonesia. [medicaldr2001id@yahoo.com](mailto:medicaldr2001id@yahoo.com)

### Abstract

Pancreatic malignancy is still the most lethal gastrointestinal malignancy. It has a very poor prognosis with low survival rate. Surgery is still the main treatment option for pancreatic malignancy. Most patients already have locally advanced and even late stage disease due to non-specific abdominal symptoms. Even though some cases are still suitable for surgical treatment, due to its aggressiveness adjuvant chemotherapy is becoming the standard treatment for controlling the disease. Radiofrequency ablation (RFA) is a thermal therapy that has been used as one of the standard treatments for liver malignancy. It can also be performed intraoperatively. There are several reports on percutaneous RFA treatment for pancreatic malignancy using transabdominal ultrasound and guided by computed tomography scan. However, due to its anatomical location and the risk of high radiation exposure, these methods seem to be very limited. Endoscopic ultrasound (EUS) has been widely used for pancreatic abnormality evaluation due to its ability to detect more accurately, especially small pancreatic lesions, compared to other imaging modalities. By the EUS approach, it is easier to achieve good visualization of tumor ablation and necrosis as the echoendoscope position is closer to the tumor area. Based on studies and a recent meta-analysis, EUS-guided RFA is a promising treatment approach for most pancreatic malignancy cases, but most studies only collected data from a small sample size. Larger studies are needed before clinical recommendations can be made.

**Key Words:** Endoscopic ultrasound; Radio frequency ablation; Percutaneous; Surgery;



**Core Tip:** Pancreatic cancer is still the most lethal gastrointestinal malignancy. Most patients are diagnosed at the late stage of the disease. Surgery is still the definitive treatment for managing pancreatic cancer. However, skill, experience, and expertise are required of the surgeon due to its high risk of complications. Recently, endoscopic ultrasound has been used for managing pancreatic cancer. Studies have shown its practicability, efficacy, and benefit in combination with standard chemotherapy. It would need larger studies before it can be recommended as standard management in clinical practice.

**Citation:** Lesmana CRA. Impact of endoscopic ultrasound-guided radiofrequency ablation in managing pancreatic malignancy. *World J Gastrointest Surg* 2023; 15(2): 163-168

**URL:** <https://www.wjgnet.com/1948-9366/full/v15/i2/163.htm>

**DOI:** <https://dx.doi.org/10.4240/wjgs.v15.i2.163>

## INTRODUCTION

Pancreatic malignancy is still the most lethal gastrointestinal malignancy, and it is ranked seventh for mortality. It has a very poor prognosis with a low survival rate[1]. There are many risk factors that might contribute to pancreatic cancer development, such as genetics, obesity, diabetes mellitus, smoking, chronic pancreatitis, fatty pancreas, and heavy alcohol consumption[2]. It has been classified into two categories, *i.e.*, exocrine cancer, which is dominated by pancreatic adenocarcinoma, and endocrine cancer, also known as pancreatic neuroendocrine tumor (pNET). In the clinical stage, it is classified into type IA and IB (considered as resectable disease with a maximum 4 cm diameter), type II (locally advanced with diameter > 4 cm with possible lymph nodes involvement), type III (unresectable with vascular involvement), and type IV (metastatic cancer)[3].

Pancreatoduodenectomy (Whipple) operation is still the best option to prolong survival. However, most cases already come in at the late stage, and overall mortality remains low. Endoscopic ultrasound (EUS) is an innovation dedicated to managing pancreatobiliary disorders[4]. In the history of developing the EUS procedure, a diagnostic comparison study by Palazzo *et al*[5] showed that EUS had higher accuracy to detect small pancreatic lesions when compared to computed tomography (CT) scan or ultrasonography. Based on the pioneering study by Vilman *et al*[6] in which the EUS-guided pancreas biopsy technique used a catheter with aspiration needle, therapeutic EUS has been recently developed not only for biliary drainage procedure but also for managing pancreatic malignancy through direct tumor ablation therapy or radiofrequency ablation (RFA) in a multidisciplinary context and evaluation[4,7].

The RFA procedure is an electrocautery-based technique that results in tissue necrosis. It has been used widely for managing unresectable primary as well as secondary liver cancer, where it has been previously reported by Nießen *et al*[8]. The local recurrence was primarily dependent on tumor size. Another RFA innovation study has been reported by Gervais *et al*[9] for managing renal cell carcinoma up to 5 cm in size with overall median survival of 9.9 mo. No recurrent disease in patients with technically successful treatment, no metastasis during treatment course, and no dialysis was needed in post ablation patients.

## SURGICAL TREATMENT IN PANCREATIC MALIGNANCY

Surgery is still the main treatment option for pancreatic malignancy. However, due to its aggressiveness, neo-adjuvant chemotherapy is becoming the standard treatment for controlling the disease. Most patients are diagnosed at an advanced stage of cancer. In surgical treatment, tumor size and margin, vascular involvement, and lymph nodes are important parameters for the patient's outcome [10]. A questionnaire-based retrospective study was conducted for pancreatic cancer with 6-year follow-up on patient outcomes, and it showed that the 30-d mortality rate was 5.3% with median survival of only 16.3 mo. Three out of twenty patients who had 5-year survival with positive histology results had recurrent disease in the 6-year follow-up. Some of these patients already showed locally advanced disease as there was evidence of positive margin. The median survival was lower in patients with positive margin compared to patients with negative margin (13.9 mo *vs* 20.6 mo)[11].

Another study looking at patient survival after pancreatic head resection for ductal adenocarcinoma observed an overall mortality rate of 4.10% and 3-year and 5-year survival rates of only 31.50% and 11.86%, respectively. In this study, 81.50% of patients already had obstructive jaundice condition. The pathology results of tumor differentiation revealed that 52.40% of patients were already at G2 intermediate differentiation, 42.00% of patients at G3 poor differentiation (42.00%), and 2.60% of patients at G4 differentiation[12].

A recent systematic review on quality of life in patients who underwent pancreatoduodenectomy showed that there was a decrease in physical functioning 3 mo after operation. Mental health issues were the only parameter shown to be stable 3 mo after operation. Several parameters, such as fatigue, postoperative pain, dyspnea, insomnia, loss of appetite, and bowel movement problems, were reported as negative influences after the operation, even though most parameters were resolved within 3 to 6 mo. This might become an important issue since most patients are offered for chemotherapy after the operation[13].

## RFA TREATMENT AND ITS ROLE IN PANCREATIC MALIGNANCY

There are different ablation methods following temperature increase or impedance and probes (surgical or endoscopic using catheters or needles), such as chemical ablation and thermal ablation (cryoablation and hyperthermic ablation). RFA is one of the thermal therapies that has been used as one of the standard treatments for liver malignancy[14]. A prospective study by Curley *et al*[15], which was looking at the role of RFA treatment for primary as well as metastatic liver malignancies, showed that this procedure was effective and safe for tumor destruction with low tumor recurrence rate and no mortality related to the procedure.

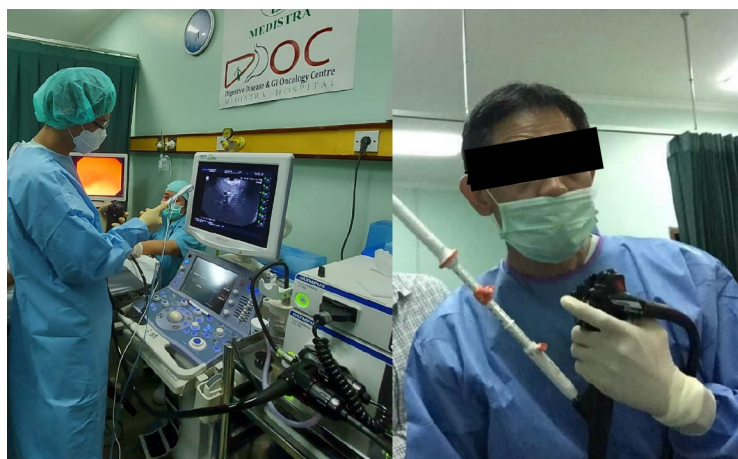An experimental study by Date *et al*[16] on pig pancreas with surrounding organ and vessels were ablated using temperature changing evaluation showed that temperature is the most important parameter to achieve complete ablation. With localized ablation therapy, there was no damage at the duodenal site or the other parts of the pancreas. Another innovative study by Hadjicostas *et al*[17] reported their experience in performing intraoperative RFA concomitantly with surgery for locally advanced and unresectable pancreatic cancer patients. RFA seemed to be a promising treatment as it could control the tumor growth.

A case series by Varshney *et al*[18] on RFA treatment guided by CT scan during the operation for unresectable pancreatic cancer showed that tumor necrosis could be achieved without any mortality events related to the procedure. The percutaneous RFA approach using abdominal ultrasound has also been reported by D'Onofrio *et al*[19] in patients with locally advanced pancreatic adenocarcinoma, where a 93% technical success rate was reported without any complications. The survival rate was recorded to be longer than 6 mo. However, there are limitations for the percutaneous RFA treatment approach. RFA treatment using transabdominal ultrasound is sometimes difficult due to overlying abdominal gas, and there is a risk of radiation exposure when using a CT scan-guided approach. On the other hand, Karim *et al*[20] reported several technical complications after the Whipple procedure, such as wound infection in 23.5% of patients and pancreatic leak in 21.4% of patients. Other complications noted in this study were lung complications (17.3%) and intra-abdominal collection (12.2%).

## INNOVATION ON EUS-GUIDED RFA IN PANCREATIC MALIGNANCY

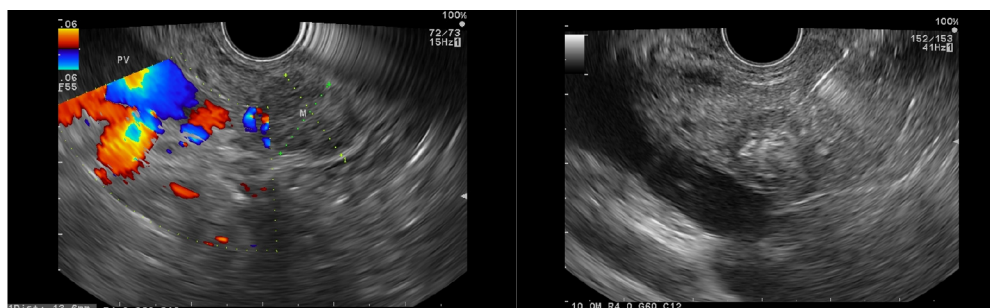
EUS has been widely used for pancreatic abnormality evaluation due to its ability to detect lesions more accurately, especially small pancreatic lesions, compared to other imaging modalities[21]. One pioneer animal experimental study by Goldberg *et al*[22] showed that EUS-guided RFA (EUSRA) can be successfully performed with a good necrosis coagulation target area. Recently, a needle dedicated for EUSRA was developed (Figure 1), where it showed a 100% technical success rate in animal models. There are four types of EUS-guided radiofrequency dedicated needles or probes, namely the 19 G fine needle aspiration (Radionics, Inc., Burlington, MA, United States), the Habib catheter (EMcision Ltd., London, United Kingdom), the Hybrid cryotherapy probe (Hybrid-Therma; ERBE, Tübingen, Germany), and the EUSRA needle (STARmed, Koyang, Korea). The only bipolar probe is Hybrid cryotherapy. Both the Hybrid cryotherapy probe and EUSRA needle have internal cooling system. The cooling system uses a water-based cooled needle (cool-tip system). This system uses the electrical current from a generator with a monopolar electrode because bipolar pancreatic probes under endoscopic control do not exist. The electrode types are single internally cooled electrodes, cluster internal cooled electrode systems, and variations (StarBurst from RITA and LeVein from Boston Scientific). All RFA needles or probe are connected to the generators to deliver a thermal effect to the lesion[23].

By using the EUS approach, it is easier to achieve good visualization of the tumor ablation and necrosis as the echoendoscope position is closer to the tumor area (Figure 2). Several case series have been reported to have a high technical success rate (73%-100%). However, several adverse events (AE) have also been noted, such as abdominal pain, bleeding, hyperamylasemia, obstructive jaundice,



DOI: 10.4240/wjgs.v15.i2.163 Copyright ©The Author(s) 2023.

**Figure 1** Endoscopic ultrasound-guided radiofrequency ablation procedure using dedicated radiofrequency ablation needle. Medistra Hospital, Jakarta.



DOI: 10.4240/wjgs.v15.i2.163 Copyright ©The Author(s) 2023.

**Figure 2** Endoscopic ultrasound images of a patient with a pancreatic neuroendocrine tumor who underwent endoscopic ultrasound-guided radiofrequency ablation. Endoscopy unit database, Medistra Hospital, Jakarta.

duodenal stricture, pancreatitis, pancreatic duct stenosis, and bacteremia[24,25]. In 2016, Lakhtakia *et al* [26] reported their experience using the EUSRA procedure in 3 patients with insulinoma. After a 12-mo follow-up, patients were still asymptomatic with a normoglycemic condition. A multi-center pilot study was conducted on the use of EUSRA in pancreatic cystic neoplasms and pNETs, where EUSRA was completed in all cases, and no major complications were observed after the procedure. There was complete resolution in 2 patients as well as cyst reduction in 3 patients after a 3-6-mo follow-up. Patients with pNETs showed a good response as tumor necrosis was recorded[27].

A pilot study by Rossi *et al*[28] on the feasibility, efficacy, and safety of EUSRA for secreting pNET patients showed that serum hormone levels reverted to normal within 24 h, and the symptoms regressed. After a 34-mo follow-up, no mortality was recorded, and tumor shrinkage and disappearance were noted after 24 mo. A case series by de Nucci *et al*[29] on patients with pNETs showed that complete ablation can be achieved within one session with a short period of hospitalization. Another prospective study by Song *et al*[30] using the EUSRA treatment approach for unresectable pancreatic cancer showed that the procedure was performed successfully in 6 cases, and systemic chemotherapy was completed on the same day in 3 patients. In this study, there were no major AEs even though 2 patients experienced mild abdominal pain.

Recently, a meta-analysis on EUSRA efficacy in pancreatic tumor management was performed with 13 studies included in the analysis. Based on this meta-analysis, the technical success rate was 100%, and the overall clinical success rate was 91.8%. Abdominal pain was the most common AE observed (9.82%), whereas perforation and infection were found in 1 patient, and pancreatitis was noted in 2 patients. This analysis concluded that EUSRA is a promising treatment strategy. However, most studies only collected a small sample size[31].

A recent longitudinal cohort study by Thosani *et al*[32] in 10 patients with pancreatic adenocarcinoma, where one to four RFA sessions per patient were performed, revealed that CA 19-9 levels decreased after 12 treatment sessions. Tumor size reduction of more than 50% was recorded in 3 patients. The median survival was 20.5 mo, whereas median survival of 13.4 mo was recorded after RFA treatment. All patients also underwent systemic chemotherapy. No significant complications were



recorded in this study. A recent clinical case series study by Rossi *et al*[33] in elderly patients with pancreatic insulinoma showed that the EUSRA procedure was a safe procedure for elderly patients at high surgical risk. In this study, no major complications occurred during the procedure.

## CONCLUSION

EUSRA is a promising treatment approach for pancreatic malignancy. However, further larger studies are needed, especially in pancreatic adenocarcinoma. The role of EUSRA in combination with systemic chemotherapy might become a new approach for managing unresectable pancreatic cancer. It may also become a promising combination strategy for tumor downstaging where it can be followed by surgery for possible tumor elimination or cure.

## ACKNOWLEDGEMENTS

I would like to thank Prof. Ho Khek Yu, National University Hospital Singapore and Prof. Dong Wan Seo, Asan Medical Center, Seoul, South Korea, who have given their support for the development of endoscopic ultrasound procedures in our center, Digestive Disease and Gastrointestinal Oncology Center, Medistra Hospital, Jakarta.

## FOOTNOTES

**Author contributions:** Lesmana CRA contributed to the concept of the manuscript and wrote the manuscript.

**Conflict-of-interest statement:** The author declares no conflicts of interest.

**Open-Access:** This article is an open-access article that was selected by an in-house editor and fully peer-reviewed by external reviewers. It is distributed in accordance with the Creative Commons Attribution NonCommercial (CC BY-NC 4.0) license, which permits others to distribute, remix, adapt, build upon this work non-commercially, and license their derivative works on different terms, provided the original work is properly cited and the use is non-commercial. See: <https://creativecommons.org/licenses/by-nc/4.0/>

**Country/Territory of origin:** Indonesia

**ORCID number:** Cosmas Rinaldi Adithya Lesmana 0000-0002-8218-5971.

**S-Editor:** Zhang H

**L-Editor:** Filipodia

**P-Editor:** Zhang H

## REFERENCES

- 1 **GBD 2017 Pancreatic Cancer Collaborators.** The global, regional, and national burden of pancreatic cancer and its attributable risk factors in 195 countries and territories, 1990-2017: a systematic analysis for the Global Burden of Disease Study 2017. *Lancet Gastroenterol Hepatol* 2019; **4**: 934-947 [PMID: 31648972 DOI: 10.1016/S2468-1253(19)30347-4]
- 2 **Ranganath R, Chu Q.** Global trends in pancreas cancer among Asia-Pacific population. *J Gastrointest Oncol* 2021; **12**: S374-S386 [PMID: 34422401 DOI: 10.21037/jgo-20-118]
- 3 **Rawla P, Sunkara T, Gaduputi V.** Epidemiology of Pancreatic Cancer: Global Trends, Etiology and Risk Factors. *World J Oncol* 2019; **10**: 10-27 [PMID: 30834048 DOI: 10.14740/wjon1166]
- 4 **Nakai Y, Takahara N, Mizuno S, Kogure H, Koike K.** Current Status of Endoscopic Ultrasound Techniques for Pancreatic Neoplasms. *Clin Endosc* 2019; **52**: 527-532 [PMID: 31337194 DOI: 10.5946/ce.2019.025]
- 5 **Palazzo L, Roseau G, Gayet B, Vilgrain V, Belghiti J, Fékété F, Paolaggi JA.** Endoscopic ultrasonography in the diagnosis and staging of pancreatic adenocarcinoma. Results of a prospective study with comparison to ultrasonography and CT scan. *Endoscopy* 1993; **25**: 143-150 [PMID: 8491130 DOI: 10.1055/s-2007-1010273]
- 6 **Vilmann P, Jacobsen GK, Henriksen FW, Hancke S.** Endoscopic ultrasonography with guided fine needle aspiration biopsy in pancreatic disease. *Gastrointest Endosc* 1992; **38**: 172-173 [PMID: 1568614 DOI: 10.1016/s0016-5107(92)70385-x]
- 7 **Yoon WJ, Daglilar ES, Kamionek M, Mino-Kenudson M, Brugge WR.** Evaluation of radiofrequency ablation using the 1-Fr wire electrode in the porcine pancreas, liver, gallbladder, spleen, kidney, stomach, and lymph nodes: A pilot study. *Dig Endosc* 2015; Epub ahead of print [PMID: 26583346 DOI: 10.1111/den.12575]
- 8 **Nießen A, Hackert T.** State-of-the-art surgery for pancreatic cancer. *Langenbecks Arch Surg* 2022; **407**: 443-450 [PMID: 34751822 DOI: 10.1007/s00423-021-02362-y]

- 9 **Gervais DA**, McGovern FJ, Arellano RS, McDougal WS, Mueller PR. Renal cell carcinoma: clinical experience and technical success with radio-frequency ablation of 42 tumors. *Radiology* 2003; **226**: 417-424 [PMID: [12563135](#) DOI: [10.1148/radiol.2262012062](#)]
- 10 **McGuigan A**, Kelly P, Turkington RC, Jones C, Coleman HG, McCain RS. Pancreatic cancer: A review of clinical diagnosis, epidemiology, treatment and outcomes. *World J Gastroenterol* 2018; **24**: 4846-4861 [PMID: [30487695](#) DOI: [10.3748/wjg.v24.i43.4846](#)]
- 11 **Speer AG**, Thursfield VJ, Torn-Broers Y, Jefford M. Pancreatic cancer: surgical management and outcomes after 6 years of follow-up. *Med J Aust* 2012; **196**: 511-515 [PMID: [22571308](#) DOI: [10.5694/mja11.10890](#)]
- 12 **Distler M**, Rückert F, Hunger M, Kersting S, Pilarsky C, Saeger HD, Grützmann R. Evaluation of survival in patients after pancreatic head resection for ductal adenocarcinoma. *BMC Surg* 2013; **13**: 12 [PMID: [23607915](#) DOI: [10.1186/1471-2482-13-12](#)]
- 13 **van Dijk SM**, Heerkens HD, Tseng DSJ, Intven M, Molenaar IQ, van Santvoort HC. Systematic review on the impact of pancreatoduodenectomy on quality of life in patients with pancreatic cancer. *HPB (Oxford)* 2018; **20**: 204-215 [PMID: [29249649](#) DOI: [10.1016/j.hpb.2017.11.002](#)]
- 14 **Ahmed M**, Brace CL, Lee FT Jr, Goldberg SN. Principles of and advances in percutaneous ablation. *Radiology* 2011; **258**: 351-369 [PMID: [21273519](#) DOI: [10.1148/radiol.10081634](#)]
- 15 **Curley SA**, Izzo F, Delrio P, Ellis LM, Granchi J, Vallone P, Fiore F, Pignata S, Daniele B, Cremona F. Radiofrequency ablation of unresectable primary and metastatic hepatic malignancies: results in 123 patients. *Ann Surg* 1999; **230**: 1-8 [PMID: [10400029](#) DOI: [10.1097/0000658-199907000-00001](#)]
- 16 **Date RS**, Biggins J, Paterson I, Denton J, McMahon RF, Siriwardena AK. Development and validation of an experimental model for the assessment of radiofrequency ablation of pancreatic parenchyma. *Pancreas* 2005; **30**: 266-271 [PMID: [15782106](#) DOI: [10.1097/01.mpa.0000153334.65729.a6](#)]
- 17 **Hadjicostas P**, Malakounides N, Varianos C, Kitiiris E, Lerni F, Symeonides P. Radiofrequency ablation in pancreatic cancer. *HPB (Oxford)* 2006; **8**: 61-64 [PMID: [18333241](#) DOI: [10.1080/13651820500466673](#)]
- 18 **Varshney S**, Sewkani A, Sharma S, Kapoor S, Naik S, Sharma A, Patel K. Radiofrequency ablation of unresectable pancreatic carcinoma: feasibility, efficacy and safety. *JOP* 2006; **7**: 74-78 [PMID: [16407624](#)]
- 19 **D'Onofrio M**, Crosara S, De Robertis R, Butturini G, Salvia R, Paiella S, Bassi C, Mucelli RP. Percutaneous Radiofrequency Ablation of Unresectable Locally Advanced Pancreatic Cancer: Preliminary Results. *Technol Cancer Res Treat* 2017; **16**: 285-294 [PMID: [27193941](#) DOI: [10.1177/1533034616649292](#)]
- 20 **Karim SAM**, Abdulla KS, Abdulkarim QH, Rahim FH. The outcomes and complications of pancreaticoduodenectomy (Whipple procedure): Cross sectional study. *Int J Surg* 2018; **52**: 383-387 [PMID: [29438817](#) DOI: [10.1016/j.ijssu.2018.01.041](#)]
- 21 **DiMaggio EP**, DiMaggio MJ. Endoscopic Ultrasonography: From the Origins to Routine EUS. *Dig Dis Sci* 2016; **61**: 342-353 [PMID: [26694170](#) DOI: [10.1007/s10620-015-3999-8](#)]
- 22 **Goldberg SN**, Mallery S, Gazelle GS, Brugge WR. EUS-guided radiofrequency ablation in the pancreas: results in a porcine model. *Gastrointest Endosc* 1999; **50**: 392-401 [PMID: [10462663](#) DOI: [10.1053/ge.1999.v50.98847](#)]
- 23 **Lakhtakia S**, Seo DW. Endoscopic ultrasonography-guided tumor ablation. *Dig Endosc* 2017; **29**: 486-494 [PMID: [28171697](#) DOI: [10.1111/den.12833](#)]
- 24 **Choi JH**, Seo DW, Song TJ, Park DH, Lee SS, Lee SK, Kim MH. Endoscopic ultrasound-guided radiofrequency ablation for management of benign solid pancreatic tumors. *Endoscopy* 2018; **50**: 1099-1104 [PMID: [29727904](#) DOI: [10.1055/a-0583-8387](#)]
- 25 **Yousaf MN**, Ehsan H, Muneeb A, Wahab A, Sana MK, Neupane K, Chaudhary FS. Role of Radiofrequency Ablation in the Management of Unresectable Pancreatic Cancer. *Front Med (Lausanne)* 2020; **7**: 624997 [PMID: [33644089](#) DOI: [10.3389/fmed.2020.624997](#)]
- 26 **Lakhtakia S**, Ramchandani M, Galasso D, Gupta R, Venugopal S, Kalpala R, Reddy DN. EUS-guided radiofrequency ablation for management of pancreatic insulinoma by using a novel needle electrode (with videos). *Gastrointest Endosc* 2016; **83**: 234-239 [PMID: [26394384](#) DOI: [10.1016/j.gie.2015.08.085](#)]
- 27 **Pai M**, Habib N, Senturk H, Lakhtakia S, Reddy N, Cicinnati VR, Kaba I, Beckebaum S, Drymoussis P, Kahaleh M, Brugge W. Endoscopic ultrasound guided radiofrequency ablation, for pancreatic cystic neoplasms and neuroendocrine tumors. *World J Gastrointest Surg* 2015; **7**: 52-59 [PMID: [25914783](#) DOI: [10.4240/wjgs.v7.i4.52](#)]
- 28 **Rossi S**, Viera FT, Ghittoni G, Cobianchi L, Rosa LL, Siciliani L, Bortolotto C, Veronese L, Vercelli A, Gallotti A, Ravetta V. Radiofrequency ablation of pancreatic neuroendocrine tumors: a pilot study of feasibility, efficacy, and safety. *Pancreas* 2014; **43**: 938-945 [PMID: [24717825](#) DOI: [10.1097/MPA.0000000000000133](#)]
- 29 **de Nucci G**, Imperatore N, Mandelli ED, di Nuovo F, d'Urbano C, Manes G. Endoscopic ultrasound-guided radiofrequency ablation of pancreatic neuroendocrine tumors: a case series. *Endosc Int Open* 2020; **8**: E1754-E1758 [PMID: [33269307](#) DOI: [10.1055/a-1261-9359](#)]
- 30 **Song TJ**, Seo DW, Lakhtakia S, Reddy N, Oh DW, Park DH, Lee SS, Lee SK, Kim MH. Initial experience of EUS-guided radiofrequency ablation of unresectable pancreatic cancer. *Gastrointest Endosc* 2016; **83**: 440-443 [PMID: [26344883](#) DOI: [10.1016/j.gie.2015.08.048](#)]
- 31 **Dhaliwal A**, Kolli S, Dhindsa BS, Choa J, Mashiana HS, Ramai D, Chandan S, Bhogal N, Sayles H, Bhat I, Singh S, Adler DG. Efficacy of EUS-RFA in pancreatic tumors: Is it ready for prime time? *Endosc Int Open* 2020; **8**: E1243-E1251 [PMID: [33015325](#) DOI: [10.1055/a-1221-5012](#)]
- 32 **Thosani N**, Cen P, Rowe J, Guha S, Bailey-Lundberg JM, Bhakta D, Patil P, Wray CJ. Endoscopic ultrasound-guided radiofrequency ablation (EUS-RFA) for advanced pancreatic and periampullary adenocarcinoma. *Sci Rep* 2022; **12**: 16516 [PMID: [36192558](#) DOI: [10.1038/s41598-022-20316-2](#)]
- 33 **Rossi G**, Petrone MC, Capurso G, Partelli S, Falconi M, Arcidiacono PG. Endoscopic ultrasound radiofrequency ablation of pancreatic insulinoma in elderly patients: Three case reports. *World J Clin Cases* 2022; **10**: 6514-6519 [PMID: [35979317](#) DOI: [10.12998/wjcc.v10.i19.6514](#)]



Published by **Baishideng Publishing Group Inc**  
7041 Koll Center Parkway, Suite 160, Pleasanton, CA 94566, USA

**Telephone:** +1-925-3991568

**E-mail:** [bpgoffice@wjgnet.com](mailto:bpgoffice@wjgnet.com)

**Help Desk:** <https://www.f6publishing.com/helpdesk>

<https://www.wjgnet.com>

