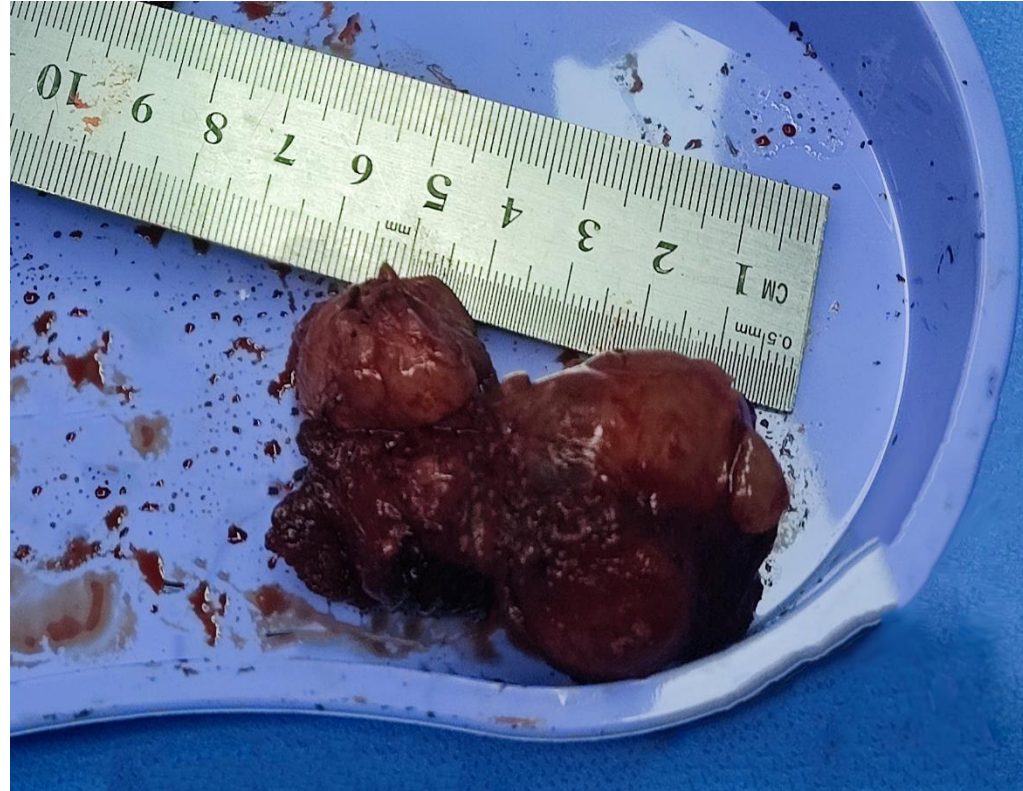


Supplementary material



Post-subtotal thyroidectomy specimens of right lobe