

WJO 5th Anniversary Special Issues (5): Knee

Treatment of meniscal tears: An evidence based approach

Simon C Mordecai, Nawfal Al-Hadithy, Howard E Ware, Chinmay M Gupte

Simon C Mordecai, Nawfal Al-Hadithy, Howard E Ware, Chinmay M Gupte, Imperial College NHS Trust, St Mary's and Charing Cross Hospitals, London W21NY, United Kingdom
 Howard E Ware, Chinmay M Gupte, The Wellington Hospital, The Knee Surgery Unit, London NW8 9LE, United Kingdom
 Author contributions: Mordecai SC and Al-Hadithy N wrote the manuscript; Ware HE and Gupte CM provided specialist input and edited the manuscript.

Correspondence to: Dr. Simon C Mordecai, Imperial College NHS Trust, St Mary's and Charing Cross Hospitals, Praed St, London W21NY, United Kingdom. simon.mordecai@gmail.com
 Telephone: +44-020-33130970 Fax: +44-020-33130971

Received: December 31, 2013 Revised: April 5, 2014

Accepted: May 16, 2014

Published online: July 18, 2014

© 2014 Baishideng Publishing Group Inc. All rights reserved.

Key words: Meniscus; Meniscectomy; Meniscal tear; Meniscal repair; Arthroscopic surgery

Core tip: Meniscal tears are a common orthopaedic pathology. Selecting the correct treatment can be challenging and involves multiple factors. This review explores the evidence for managing meniscal tears and when to consider each treatment option based on current available evidence.

Mordecai SC, Al-Hadithy N, Ware HE, Gupte CM. Treatment of meniscal tears: An evidence based approach. *World J Orthop* 2014; 5(3): 233-241 Available from: URL: <http://www.wjgnet.com/2218-5836/full/v5/i3/233.htm> DOI: <http://dx.doi.org/10.5312/wjo.v5.i3.233>

Abstract

Treatment options for meniscal tears fall into three broad categories; non-operative, meniscectomy or meniscal repair. Selecting the most appropriate treatment for a given patient involves both patient factors (*e.g.*, age, co-morbidities and compliance) and tear characteristics (*e.g.*, location of tear/age/reducibility of tear). There is evidence suggesting that degenerative tears in older patients without mechanical symptoms can be effectively treated non-operatively with a structured physical therapy programme as a first line. Even if these patients later require meniscectomy they will still achieve similar functional outcomes than if they had initially been treated surgically. Partial meniscectomy is suitable for symptomatic tears not amenable to repair, and can still preserve meniscal function especially when the peripheral meniscal rim is intact. Meniscal repair shows 80% success at 2 years and is more suitable in younger patients with reducible tears that are peripheral (*e.g.*, nearer the capsular attachment) and horizontal or longitudinal in nature. However, careful patient selection and repair technique is required with good compliance to post-operative rehabilitation, which often consists of bracing and non-weight bearing for 4-6 wk.

INTRODUCTION

Meniscal tears are the most common pathology of the knee with a mean annual incidence of 66 per 100000^[1]. Historically it was believed that the menisci served no functional purpose and they were often excised with open total meniscectomy^[2]. McMurray^[3] described that insufficient removal of the meniscus was the cause of failure of meniscectomy. In 1948 Fairbank^[4] reported the clinical outcomes of 107 patients after total meniscectomies and found that the majority had progressive flattening of the condyle, narrowing of the joint space and ridge formation. This study significantly changed our approach to dealing with meniscal tears. More recent studies have shown that function of the knee was directly related to the amount of meniscal tissue that remained^[5]. Increased knowledge of the long term consequences and altered biomechanics in the knee post meniscectomy has placed greater emphasis on meniscal preserving techniques. This review explores the evidence

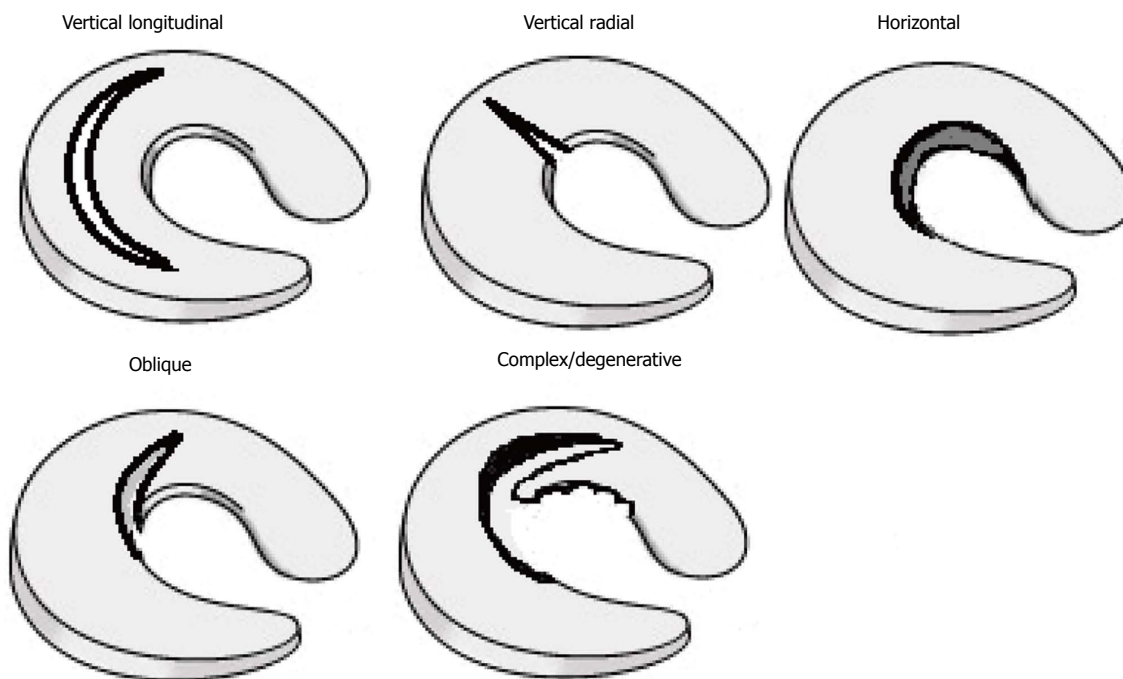


Figure 1 Meniscal tear patterns.

for managing meniscal tears and when to consider each treatment option based on current available evidence.

ANATOMICAL STRUCTURE

The menisci are wedge shaped fibrocartilagenous structures located between the femoral condyles and tibial plateau. The medial meniscus is “U” shaped covering around 60% of the medial compartment whereas the lateral meniscus is more “C” with a shorter distance between its anterior and posterior horns covering 80% of the lateral compartment^[6]. Meniscal tissue consists mainly of water and type I collagen fibres^[7]. These fibres run circumferentially from the anterior horn insertional ligament to the posterior horn insertional ligament with predominance in the outer third. The fibres help to absorb the energy by converting axial loading forces across the joint into hoop stresses within the tissue. There are also radial fibres which prevent longitudinal splitting of the circumferential fibres^[8]. The structure of these fibres are important clinically when deciding which meniscal tears are stable or which are unstable and warrant resection or repair.

The blood supply to the menisci is of high relevance having important implications for the potential healing of a meniscal repair. Supply is from the periphery *via* the medial and lateral geniculate arteries. A cadaveric study has demonstrated that only the peripheral 10%-25% of the meniscus benefits from a blood supply in the mature skeleton^[9]. Two distinct zones have been termed, the red-red vascular zone in the periphery and the white-white avascular zone centrally. They are separated by a red-white region with attributes from each zone. Tears located in the white zone are unlikely to generate a healing response.

CLASSIFICATION OF MENISCAL TEARS

Meniscal tears are often classified according to their orientation. They can be vertical longitudinal, vertical radial, horizontal, oblique or complex^[10] (Figure 1). Longitudinal tears are more common medially, whereas radial tears are more frequently seen laterally^[11].

Vertical longitudinal tears occur between the circumferential collagen fibres. The biomechanics of the knee is therefore not always disrupted and these tears may be asymptomatic. Complete vertical tears can sometime twist within the joint known as “bucket handle” tears. These are unstable tears which cause mechanical symptoms or true locking of the knee. Vertical radial tears disrupt the circumferential collagen fibres and affect the ability of the meniscus to absorb tibiofemoral load^[12]. These tears are usually not amenable to repair. Partial meniscectomy does not restore complete function and accelerated degenerative changes are likely to occur^[13]. Horizontal tears split the meniscus into an upper and lower part and can exist without clinical symptoms^[14]. They are usually mechanically stable but may give rise to flap tears. Their frequency increases with age and often accompanied by meniscal cysts^[15]. Oblique tears give rise to flaps which are mechanically unstable and associated with mechanical symptoms. This pattern of tear requires resection to prevent propagation of the tear as the flap gets caught within the joint during flexion. Complex or degenerative tears are where two or more tear patterns exist. They are more common in the elderly and have associated osteoarthritic changes in the knee.

NON-OPERATIVE MANAGEMENT

Non-operative treatments for meniscal injuries have been

well documented, particularly for degenerative tears. Exercise has been shown to improve knee function and reduce joint pain^[16,17]. Mangione *et al*^[18] found that quadriceps strengthening with static cycling for twenty five minutes three times a week for ten weeks improved knee function by 35% in patients with osteoarthritis. Herrlin *et al*^[19] extended this theory to patients with degenerative medial meniscal tears in a prospective randomised study. Ninety middle aged patients with non-traumatic MRI confirmed medial meniscal tears were split into two treatment groups^[1], arthroscopic partial meniscectomy followed by supervised exercise or^[2] supervised exercise alone. The aims of the exercise were to improve muscle strength, flexibility and proprioception for a period of eight weeks. Multiple outcome scores were performed at eight weeks and 6 mo. Significant improvements in all outcomes were found at follow-up. There were no significant differences in improvement between the groups suggesting that a combination of arthroscopic partial meniscectomy and supervised exercise does not necessarily lead to greater improvements than exercise alone in this patient group. Authors recommend a trial of supervised exercise alone as first line treatment. A follow-up study showed that the similarities between the groups were maintained at five years^[20]. However, one third of the patients from the exercise group still had disabling knee symptoms after exercise therapy but improved to the same level as the rest of the patients after arthroscopic surgery with partial meniscectomy. These results were echoed by a multicentre randomised controlled study of 351 patients over 45 years of age with a meniscal tear and evidence of osteoarthritis^[21]. No significant differences were found in the magnitude of improvement in functional status and pain between the partial meniscectomy and physical therapy alone at twelve months follow up. It should be noted though, that there was also crossover from the physical therapy group to the surgery group in 35% of patients. The factors for this crossover were not defined and may have skewed the results. Functional outcomes of the crossover patients after 12 mo however, were similar to those patients who had surgery initially, suggesting that non-operative treatment is a reasonable first line strategy.

Yim *et al*^[22] compared non-operative strengthening exercises with meniscectomy for degenerative horizontal tears of the posterior horn of the medial meniscus. Satisfactory clinical results were found in each group at 2 years follow up with no significant difference in terms of pain, function and patient satisfaction. All clinical data was obtained using questionnaires which can be very subjective. Another study^[23] following the effect of supervised exercise therapy on 37 patients with degenerative tears of the medial meniscus found improvement in functional knee scores up to 6 mo, after which there was decline and progression of osteoarthritis. The decline was also related to the patients' BMI.

Previous studies have suggested that early degenerative changes are more likely to occur after meniscectomy than non-operative management^[24,25]. However the

current evidence suggests that although non-operative management can be beneficial initially around a third of patients will go on to have a meniscectomy to achieve satisfactory pain relief and functional outcomes. Provided patients with degenerative tears have a robust and supervised exercise programme they can initially be managed conservatively. If symptoms persist they could then go on to have a meniscectomy. There were no studies reporting on non-operative management of acute meniscal tears in young patients.

MENISCECTOMY

It is now well known that the menisci serve an important role in the knee. Their main functions include load bearing, shock absorption and stabilisation. In addition they may have roles in joint lubrication, nutrition of the articular cartilage and proprioception^[26].

Baratz *et al*^[27] conducted a biomechanical cadaveric study and found that following total medial meniscectomy there is a decrease in intra-articular contact area of approximately 75% and the peak contact pressure increased by approximately 235%. Comparable results were found in a study by Ahmed and Burke^[28]. Pressure on the meniscus increased by 85% during flexion and contact pressure by 100%-200% following total meniscectomy. Roos *et al*^[29] report on a long term clinical study with follow-up of 21 years of patients after total meniscectomy compared to matched controls. They confirm that the increased pressure seen in the biomechanical studies leads to radiographic evidence of osteoarthritis with a relative risk of 14. It has also been shown that the risk of developing osteoarthritis after lateral meniscectomy is greater than the equivalent for the medial side^[30,31]. This is due to the convexity of lateral tibial plateau mirroring the convexity of the distal femoral condyle. In the absence of a meniscus there is greater tendency to point loading. The medial tibial plateau is concave providing some degree of congruity even without a meniscus^[32]. Furthermore as previously mentioned the lateral meniscus covers a greater percentage of the compartment and carries 70% of the compartment load compared to 50% medially adding to the risk of developing osteoarthritis^[33]. Given the drastic changes in the biomechanics of the knee after total meniscectomy much interest has focused on the benefits of preserving as much meniscus as possible. Partial meniscectomy aims to remove only the torn piece of meniscus while retaining as much normal meniscus especially in the peripheral rim which is mostly responsible for the biomechanical function of the knee^[34].

Northmore-Ball *et al*^[35] compared arthroscopic partial meniscectomy with open partial and total meniscectomy in 219 knees. They reported that 90% of patients had either good or excellent satisfaction following arthroscopic partial meniscectomy compared to only 68% who had open total meniscectomy after 4.3 years follow-up. Burks *et al*^[36] also found good or excellent results in 88% of patients after partial meniscectomy and Jaureguito *et al*^[37] report 90% of patients report good or excellent results

with 85% resuming pre-injury level of activities at 2 years after surgery.

Short term results following partial meniscectomy are encouraging with around 90% showing satisfactory clinical results. Several long term studies show that partial meniscectomy may delay degeneration but not prevent it. In a study^[38] looking at 136 patients following partial meniscectomy for isolated meniscal tears, at 8.5 years follow-up there was a re-operation rate of 22.8% and 53% of patients had osteoarthritic radiographic changes compared to only 22% in the unaffected control knee. A longitudinal study^[39] of 147 athletes following meniscectomy for an isolated meniscal injuries were followed up at 4.5 years and then again at 14 years. At the first follow-up around half were asymptomatic but this reduced to around one third at final follow-up. Also the incidence of radiographic changes rose from 40% to 89% between follow-ups and 46% had given up or reduced their sporting activity. Radiographic degeneration was more frequently seen after lateral meniscectomy than medial.

Determining which patients will do well following partial meniscectomy is a challenging task and multiple factors need to be considered. Matsue *et al.*^[40] conducted a retrospective analysis of 65 patients over forty years of age who had undergone partial medial meniscectomy. Patients were divided into two groups based on degree of articular degeneration. In the group with no pre-existing articular damage 87% had an excellent outcome, and only one patient had a poor result. In contrast, patients from the other group had significantly worse results, with only one knee having an excellent outcome, and four knees having poor results. Authors concluded that arthroscopic partial medial meniscectomy in patients older than 40 years is an acceptable and effective long-term treatment, particularly in patients without significant articular cartilage damage. Arthroscopic resection of flap tears from the posterior horn of the medial meniscus was also shown to have less favourable outcomes in the presence of chondromalacia in a review of 93 patients^[41].

A randomised double blinded placebo controlled study published in The New England Journal of Medicine^[42] looked at 180 patients who were randomly assigned to receive arthroscopic debridement, arthroscopic lavage or placebo surgery. Patients in the placebo group received skin incisions and simulated debridement. Patients were followed up multiple times over a 2 year period. Authors concluded that in patients with osteoarthritis the outcomes after arthroscopic lavage or debridement were no better than after a placebo procedure. Also function did not improve in any group. Although this is a very well designed study providing the highest level of evidence practice should not be changed on the basis of just one study as the authors suggest and certain limitations should also be taken into account. Firstly there is an element of selection bias. All patients were recruited from the Houston Veterans Affairs Medical Centre of which 97% were male. Even though response to surgery is not known to differ between sexes, osteoarthritis af-

fects millions of people worldwide and results from just one single institution cannot be a true representation. Secondly there is no clear indication of the severity of the osteoarthritis in each case. Bernstein and Quach^[43] in a critique of this paper believe the inclusion criteria were too broad and arthroscopy based these indications should be invalidated. Finally the authors' state that the billions of dollars spent on arthroscopies annually might be put to better use. If these patients were subjected to total knee replacements instead this carries a five times greater cost than arthroscopy. Also as the knee replacements will be done earlier they are more likely to need revision further adding to the costs.

Katz *et al.*^[44] reviewed 105 patients following partial medial meniscectomy with aim to establish multiple predictors of functional outcome. They identified that although partial meniscectomy generally had favourable outcomes, extent of cartilage damage as well as workers' compensation case pending and low preoperative physical function were predictors of poor outcome. Predictors of good outcomes in arthroscopic partial meniscectomy include age younger than 40 years, symptoms present less than 1 year, absent patellar symptoms, no preoperative radiographic evidence of degeneration and absence of ligamentous injury^[45].

Despite selecting patients with characteristics for more favourable outcomes, long term studies have suggested that they will eventually go on to have accelerated degenerative changes. Table 1 summarises the factors influencing the risk of developing arthritis based on the evidence previously discussed.

MENISCAL REPAIR

Owing to the long term complications associated with meniscectomy, as well as the recognition of the functional importance of the meniscus, there has been increasing interest in avoidance of meniscectomy where possible and meniscal repair has gained popularity.

In the early 1980s animal studies were performed to evaluate the response of the meniscus to injury, and showed that meniscal tissue was capable generating a healing response particularly at its periphery. Cabaud *et al.*^[46] performed transverse medial meniscal lacerations and repair with a single Dexon suture on 20 canine and 12 rhesus knee joints. At just four months, 94% showed sufficient healing to protect the underlying articular cartilage. Only 6% failed to heal. Histology revealed that the scar tissue was composed of unorganised collagen without common ground substance components. Arnoczky and Warren^[47] reported on the vascular response to complete midportion transaction of the medial meniscus in 15 dogs. They found that at ten weeks all of the lacerations healed with fibrovascular scar tissue. The response originated from the peripheral synovial tissues. Interestingly longitudinal incisions in the avascular portion of the meniscus all failed to heal.

The blood supply is fundamental to the success of

Table 1 Factors influencing the risk of developing arthritis following meniscectomy

| | |
|-----------------------|--|
| Compartment involved | Greater risk with lateral meniscectomy |
| Volume of resection | Greater risk with larger resection volume |
| Orientation of tear | Greater risk with radial tear – destroys hoops stress function |
| Associated conditions | Greater risk with pre-existing chondral damage Greater risk with ACL insufficiency |
| Knee alignment | Varus malalignment → greater medial compartment load Valgus malalignment → great lateral compartment load |
| Body habitus | Greater risk for larger BMI |
| Patient age | Greater risk over 40-year-old |
| Activity level | Greater risk with lower preoperative activity level |

BMI: Body mass index.

a meniscal repair. Only tears in the red-red or possibly the red-white zone are expected to heal. The absence of blood vessels in the remaining meniscus prevents widespread use of meniscal repair and patients are subjected to meniscectomy. Attempts have been made to encourage bleeding in otherwise avascular zones. Exogenous fibrin clots have been used to stimulate a reparative response in an avascular zone^[48]. Five cases of posterolateral meniscal tears just anterior to the popliteus fossa that are devoid of penetrating blood vessels were repaired and enhanced with a fibrin clot. All patients returned to initial level of sports and second look arthroscopy showed healing of the periphery occurred in all cases. Trephination of vascular channels on the free meniscal edges has also been shown to improve healing rates. In a study^[49] comparing meniscal repair plus trephination with meniscal repair alone, there was a significantly lower re-tear rate in the group who had additional trephination. Further evidence that bleeding can aid meniscal repair is from a study by Cannon and Vittori^[50]. Patients with meniscal repairs in conjunction with anterior cruciate ligament reconstruction were compared with patient undergoing meniscal repair alone. They report a 93% healing rate in the anterior cruciate ligament reconstruction group compared to 50% in meniscal repair alone. Anterior cruciate ligament reconstruction involves tibial and femoral drilling this delivers local growth and clotting factors which may account for the higher repair success rate. It was also noted that acute repairs within 8 wk of injury did better than the more chronic repairs.

Johnson *et al*^[51] reviewed a consecutive series of 48 patients who had arthroscopically assisted repair of medial meniscal tears. Exclusion criteria was any other knee pathology or a tear less than 10mm. Clinical success was based on history of pain, physical examination and bilateral standing radiographs. The average follow-up period was just over 10 years. Authors found a clinical success rate of 76%. Furthermore radiographic examination revealed only 8% of operated knees had minimal joint changes compared to 3% in the contralateral knee. As patients were contacted on average 10 years following the procedure almost 30% were lost to follow-up. Another study^[52] with long term follow-up over 10 years also report encouraging results. Thirty-three consecutive open

meniscal repairs were evaluated. No patients were lost to follow-up. None of the 12 menisci in the stable knees sustained re-tears compared with 7 of 21 (33%) menisci in nearly stable or unstable knees. Authors concluded a long term survival for 79% with radiographic evidence for the biomechanical function of successful meniscal repairs. A review^[53] of sixty two meniscal repairs has shown that early repair within 3 mo of injury had better results than late repair (91% *vs* 58% success rate) and traumatic tears fared better than chronic tears (73% *vs* 42%). Authors concluded that isolated atraumatic medial meniscal tears appeared to do particularly poorly and may be better treated by meniscectomy.

Seo *et al*^[54] performed second look arthroscopies in 11 patients who underwent arthroscopic repair of the posterior root attachment at 13.4 mo postoperatively and in none of them had the repair healed. A study^[55] evaluating healing after meniscal repair using arthro-CT scan also found that posterior segment healing rate was lower compared to middle portion tears. Despite this most patients still showed clinical improvement suggesting that the favourable results seen after meniscal repair do not necessarily correlate with the appearance of a normal looking meniscus.

Studies comparing meniscal repair with meniscectomy are limited. Defining whether or not a meniscal tear has healed post-operatively is difficult. MRI scans are only 80%-90% accurate at diagnosing meniscal tears initially and even less accurate post-operatively. High signal in the meniscal tissue can represent oedema, degeneration, an actual tear or a healing tear post repair^[56]. Second-look arthroscopy to directly visualise the repair, requires an invasive surgical procedure and would be hard to justify. Furthermore randomising patients to receive either repair or resection would not be ethical as different tear patterns require different interventions. Stein *et al*^[57] report on the long term outcome after arthroscopic meniscal repair versus arthroscopic partial repair meniscectomy for traumatic meniscal tears. Eight-one patients were assigned to either repair or resection. Meniscal repair was performed in full thickness and vertical longitudinal tears greater than 1cm or bucket handle tears in the red-red to red-white zone. Partial meniscectomy was for ruptures in the white-white zone, or for all tears considered non-

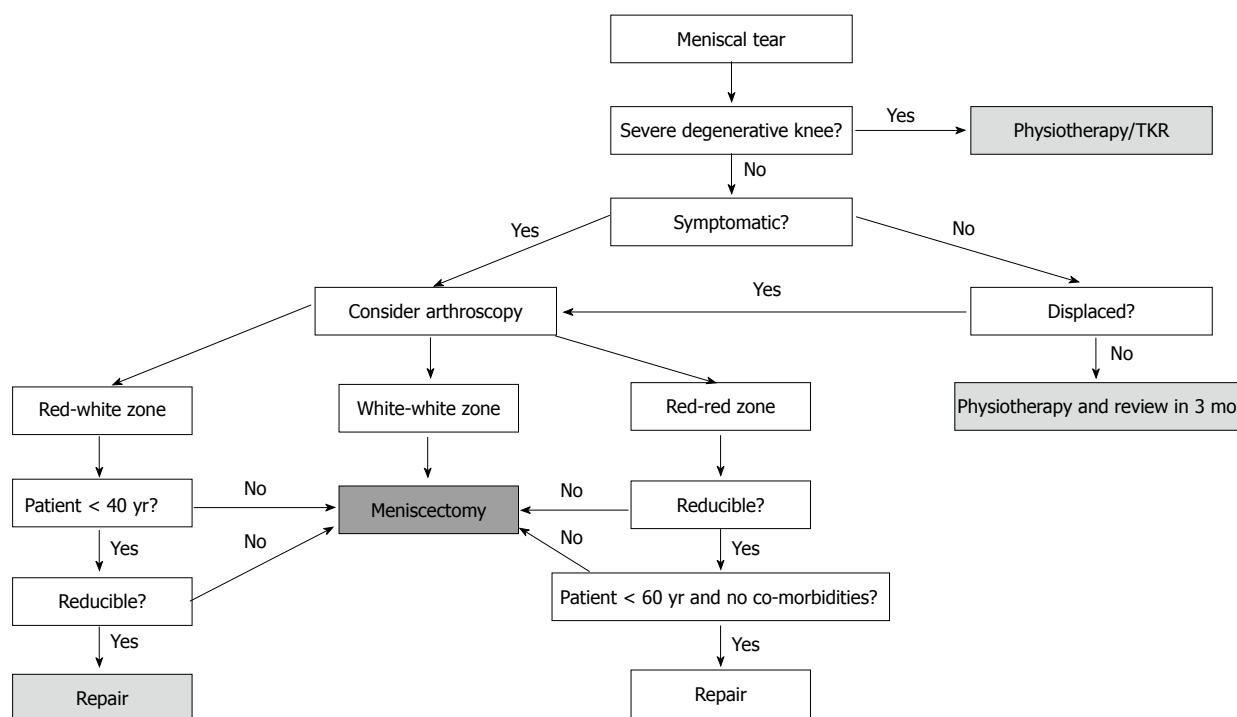


Figure 2 Meniscal tear management tree.

repairable due to type and size. Full rehabilitation was performed for all repairs. This included six weeks of protected weight bearing in motion limiting braces. At long term follow-up (8.8 years) no osteoarthritic progression was detectable in 80.8% after repair compared with 40.0% after meniscectomy. Pre-injury level of activity was achieved in 96.2% after repair compared with 50% after meniscectomy. Function score revealed no significant difference. An important point to note from this study is that all patients benefited from surgery. One cannot deduce that repair is better than resection as treatment was not randomised but specifically chosen depending on the type of tear. Also potential benefits of meniscal repair must be weighed up against significant differences in post-operative rehabilitation. Patients having simple meniscectomy can usually return to full work after a couple of weeks. However for a successful result following meniscal repair, patients are required to wear a hinged brace for up to 6 wk followed by extensive physiotherapy. Such restriction should be taken into account and evaluated on a patient by patient basis.

MENISCAL REPAIR TECHNIQUES

With the growing trend towards meniscal repair, naturally there have also been advances in repair techniques particularly since the introduction of arthroscopic surgery. Open meniscal repair through an incision posterior to the collateral ligaments is now rarely performed due to associated neurovascular injury. Rockbom and Gillquist^[58] report on a 13 year follow-up of 31 patients who underwent open meniscal repair. They found an overall failure rate of 29%. Interestingly, although knee function was

reduced in the repair group compared to an uninjured control group; there was no difference in incidence of radiological changes between groups. Other more commonly used techniques include inside-out, outside-in and all inside repairs.

Both inside-out and outside-in repair techniques involve passing a suture from either the inside or the outside of the knee *via* arthroscopy and tied beyond the joint capsule using a small incision. These techniques are particularly useful for anterior and middle third tears which are not easily accessed by an all-inside technique. However care of neurovascular structures in particular the saphenous nerve medially and the common peroneal nerve laterally must be taken when making the accessory incisions^[59].

Advances in meniscal repair devices have allowed for all-inside arthroscopic meniscal repair techniques to evolve with the advantage of avoiding the need for accessory incisions. Initially rigid biodegradable devices were used. Gill *et al*^[60] report on 32 meniscal repairs using the rigid biodegradable Meniscus Arrow (Bionx Implants, Blue Bell, PA). At 2.3 years follow-up they show a 90.6% success rate with only 3 patients requiring further surgery. However in a follow-up study^[61] at 6.6 years, this success had declined to just 71.4%. A biomechanical study^[62] of rigid biodegradable devices found that at 24 wk hydrolysis was responsible for a significant decrease in failure strength.

Suture based devices consisting of an anchor component and a sliding knot were the next generation to be developed in an attempt to avoid the complications associated with rigid devices and to allow and more flexible fixation of the meniscal fragments. Success rates

of 83%-88%^[63,64] have been reported so far. Barber and Herbert^[65] investigated load-to-failure strength of meniscal repair devices and found that suture based devices had superior pullout strength than rigid devices, with a double vertical suture being the strongest. Drawbacks associated with suture based devices include, increased costs, retained polymer fragments, chondral injury and a significant learning curve with a high rate of anchor pull-out during insertion^[66].

Several studies have been published in order to establish the optimum repair technique. Grant *et al.*^[67] performed a systematic review comparing 19 studies looking at different repair techniques for isolated meniscal tears. They found no differences in clinical failure rate or subjective outcome between inside-out and all-inside meniscus repair techniques. Complications were associated with both techniques. More nerve symptoms are associated with the inside-out repair and more implant-related complications are associated with the all-inside techniques. Nepple *et al.*^[68] found similar results in a systematic review of 13 studies with a minimum of five year follow-up. A pooled rate of failure from 20.2% to 24.3% was found for all repair techniques. It was noted that modern all-inside repair devices were not included in the review and long term results are still awaited before firm conclusion on the best repair technique and device can be made.

CONCLUSION

Meniscal tears are a common orthopaedic pathology. Selecting the correct treatment can be challenging and involves multiple factors. Knowledge and understanding of the anatomical structure and vascularity of the meniscus as well as the pattern of tear is important. Evidence shows that non-operative treatment can be successful especially in the short term and in the presence of osteoarthritis. Partial meniscectomy can preserve some of the function of the meniscus and is beneficial for tears within the avascular white-white zone. Meniscal repair has grown in popularity and boasts excellent long-term results. This should be considered for all repairable tears provided the patient can comply with the post-operative rehabilitation. Figure 2 summarises the evidence discussed in this review as well as contributions from the senior author in a decision tree for dealing with meniscal tears.

REFERENCES

- 1 **Hede A**, Jensen DB, Blyme P, Sonne-Holm S. Epidemiology of meniscal lesions in the knee. 1,215 open operations in Copenhagen 1982-84. *Acta Orthop Scand* 1990; **61**: 435-437 [PMID: 2239168 DOI: 10.3109/17453679008993557]
- 2 **McDermott ID**, Amis AA. The consequences of meniscectomy. *J Bone Joint Surg Br* 2006; **88**: 1549-1556 [PMID: 17159163 DOI: 10.1302/0301-620X.88B12.18140]
- 3 **McMurray TP**. The semilunar cartilages. *Br J Surg* 1942; **29**: 407-414 [DOI: 10.1002/bjs.18002911612]
- 4 **FAIRBANK TJ**. Knee joint changes after meniscectomy. *J Bone Joint Surg Br* 1948; **30B**: 664-670 [PMID: 18894618]

- 5 **Hede A**, Larsen E, Sandberg H. The long term outcome of open total and partial meniscectomy related to the quantity and site of the meniscus removed. *Int Orthop* 1992; **16**: 122-125 [PMID: 1428307 DOI: 10.1007/BF00180200]
- 6 **Kohn D**, Moreno B. Meniscus insertion anatomy as a basis for meniscus replacement: a morphological cadaveric study. *Arthroscopy* 1995; **11**: 96-103 [DOI: 10.1016/0749-8063(95)90095-0]
- 7 **Herwig J**, Egner E, Buddecke E. Chemical changes of human knee joint menisci in various stages of degeneration. *Ann Rheum Dis* 1984; **43**: 635-640 [PMID: 6548109 DOI: 10.1136/ard.43.4.635]
- 8 **Bullough PG**, Munuera L, Murphy J, Weinstein AM. The strength of the menisci of the knee as it relates to their fine structure. *J Bone Joint Surg Br* 1970; **52**: 564-567 [PMID: 5468789]
- 9 **Arnoczky SP**, Warren RF. Microvasculature of the human meniscus. *Am J Sports Med* 1982; **10**: 90-95 [PMID: 7081532 DOI: 10.1177/036354658201000205]
- 10 **Binfield PM**, Maffulli N, King JB. Patterns of meniscal tears associated with anterior cruciate ligament lesions in athletes. *Injury* 1993; **24**: 557-561 [DOI: 10.1016/0020-1383(93)90038-8]
- 11 **Klimkiewicz JJ**, Shaffer B. Meniscal surgery 2002 update: indications and techniques for resection, repair, regeneration, and replacement. *Arthroscopy* 2002; **18**: 14-25 [PMID: 12426527 DOI: 10.1053/jars.2002.36505]
- 12 **Maffulli N**, Longo UG, Campi S, Denaro V. Meniscal tears. *Open Access J Sports Med* 2010; **1**: 45-54 [PMID: 24198542]
- 13 **Magee T**, Shapiro M, Williams D. Comparison of high-field-strength versus low-field-strength MRI of the shoulder. *AJR Am J Roentgenol* 2003; **181**: 1211-1215 [PMID: 14573405 DOI: 10.2214/ajr.181.5.1811211]
- 14 **Noble J**. Lesions of the menisci. Autopsy incidence in adults less than fifty-five years old. *J Bone Joint Surg Am* 1977; **59**: 480-483 [PMID: 577209]
- 15 **Muddu BN**, Barrie JL, Morris MA. Aspiration and injection for meniscal cysts. *J Bone Joint Surg Br* 1992; **74**: 627-628 [PMID: 1624532]
- 16 **Börjesson M**, Robertson E, Weidenhielm L, Mattsson E, Olsson E. Physiotherapy in knee osteoarthritis: effect on pain and walking. *Physiother Res Int* 1996; **1**: 89-97 [PMID: 9238726 DOI: 10.1002/pri.6120010205]
- 17 **Matthews P**, St-Pierre DM. Recovery of muscle strength following arthroscopic meniscectomy. *J Orthop Sports Phys Ther* 1996; **23**: 18-26 [PMID: 8749746 DOI: 10.2519/jospt.1996.23.1.18]
- 18 **Mangione KK**, McCully K, Gloviak A, Lefebvre I, Hofmann M, Craik R. The effects of high-intensity and low-intensity cycle ergometry in older adults with knee osteoarthritis. *J Gerontol A Biol Sci Med Sci* 1999; **54**: M184-M190 [PMID: 10219009 DOI: 10.1093/gerona/54.4.M184]
- 19 **Herrlin S**, Hällander M, Wange P, Weidenhielm L, Werner S. Arthroscopic or conservative treatment of degenerative medial meniscal tears: a prospective randomised trial. *Knee Surg Sports Traumatol Arthrosc* 2007; **15**: 393-401 [PMID: 17216272 DOI: 10.1007/s00167-006-0243-2]
- 20 **Herrlin SV**, Wange PO, Lapidus G, Hällander M, Werner S, Weidenhielm L. Is arthroscopic surgery beneficial in treating non-traumatic, degenerative medial meniscal tears? A five year follow-up. *Knee Surg Sports Traumatol Arthrosc* 2013; **21**: 358-364 [PMID: 22437659 DOI: 10.1007/s00167-012-1960-3]
- 21 **Katz JN**, Brophy RH, Chaisson CE, de Chaves L, Cole BJ, Dahm DL, Donnell-Fink LA, Guermazi A, Haas AK, Jones MH, Levy BA, Mandl LA, Martin SD, Marx RG, Miniaci A, Matava MJ, Palmisano J, Reinke EK, Richardson BE, Rome BN, Safran-Norton CE, Skonieczki DJ, Solomon DH, Smith MV, Spindler KP, Stuart MJ, Wright J, Wright RW, Losina E. Surgery versus physical therapy for a meniscal tear and osteoarthritis. *N Engl J Med* 2013; **368**: 1675-1684 [PMID:

- 23506518 DOI: 10.1056/NEJMoa1301408]
- 22 **Yim JH**, Seon JK, Song EK, Choi JI, Kim MC, Lee KB, Seo HY. A comparative study of meniscectomy and nonoperative treatment for degenerative horizontal tears of the medial meniscus. *Am J Sports Med* 2013; **41**: 1565-1570 [PMID: 23703915 DOI: 10.1177/0363546513488518]
 - 23 **Neogi DS**, Kumar A, Rijal L, Yadav CS, Jainan A, Nag HL. Role of nonoperative treatment in managing degenerative tears of the medial meniscus posterior root. *J Orthop Traumatol* 2013; **14**: 193-199 [PMID: 23532300 DOI: 10.1007/s10195-013-0234-2]
 - 24 **Lohmander LS**, Roos H. Knee ligament injury, surgery and osteoarthritis. Truth or consequences? *Acta Orthop Scand* 1994; **65**: 605-609 [PMID: 7839844 DOI: 10.3109/17453679408994613]
 - 25 **Roos H**, Adalberth T, Dahlberg L, Lohmander LS. Osteoarthritis of the knee after injury to the anterior cruciate ligament or meniscus: the influence of time and age. *Osteoarthritis Cartilage* 1995; **3**: 261-267 [PMID: 8689461 DOI: 10.1016/S1063-4584(05)80017-2]
 - 26 **Krause WR**, Pope MH, Johnson RJ, Wilder DG. Mechanical changes in the knee after meniscectomy. *J Bone Joint Surg Am* 1976; **58**: 599-604 [PMID: 946970]
 - 27 **Baratz ME**, Fu FH, Mengato R. Meniscal tears: the effect of meniscectomy and of repair on intraarticular contact areas and stress in the human knee. A preliminary report. *Am J Sports Med* 1986; **14**: 270-275 [PMID: 3755296 DOI: 10.1177/036354658601400405]
 - 28 **Ahmed AM**, Burke DL. In-vitro measurement of static pressure distribution in synovial joints--Part I: Tibial surface of the knee. *J Biomech Eng* 1983; **105**: 216-225 [PMID: 6688842 DOI: 10.1115/1.3138409]
 - 29 **Roos H**, Laurén M, Adalberth T, Roos EM, Jonsson K, Lohmander LS. Knee osteoarthritis after meniscectomy: prevalence of radiographic changes after twenty-one years, compared with matched controls. *Arthritis Rheum* 1998; **41**: 687-693 [PMID: 9550478]
 - 30 **Bonneux I**, Vandekerckhove B. Arthroscopic partial lateral meniscectomy long-term results in athletes. *Acta Orthop Belg* 2002; **68**: 356-361 [PMID: 12415937]
 - 31 **Chatain F**, Adeleine P, Chambat P, Neyret P. A comparative study of medial versus lateral arthroscopic partial meniscectomy on stable knees: 10-year minimum follow-up. *Arthroscopy* 2003; **19**: 842-849 [PMID: 14551546 DOI: 10.1016/S0749-8063(03)00735-7]
 - 32 **McDermott ID**. Meniscal tears. *Curr Orthop* 2006; **20**: 85-94 [DOI: 10.1016/j.cuor.2006.02.010]
 - 33 **Seedhom BB**, Dowson D, Wright V. Proceedings: Functions of the menisci. A preliminary study. *Ann Rheum Dis* 1974; **33**: 111 [PMID: 4821376 DOI: 10.1136/ard.33.1.111]
 - 34 **Jeong HJ**, Lee SH, Ko CS. Meniscectomy. *Knee Surg Relat Res* 2012; **24**: 129-136 [PMID: 22977789 DOI: 10.5792/ksrr.2012.24.3.129]
 - 35 **Northmore-Ball MD**, Dandy DJ, Jackson RW. Arthroscopic, open partial, and total meniscectomy. A comparative study. *J Bone Joint Surg Br* 1983; **65**: 400-404 [PMID: 6874710]
 - 36 **Burks RT**, Metcalf MH, Metcalf RW. Fifteen-year follow-up of arthroscopic partial meniscectomy. *Arthroscopy* 1997; **13**: 673-679 [PMID: 9442319 DOI: 10.1016/S0749-8063(97)90000-1]
 - 37 **Jaureguito JW**, Elliot JS, Lietner T, Dixon LB, Reider B. The effects of arthroscopic partial lateral meniscectomy in an otherwise normal knee: a retrospective review of functional, clinical, and radiographic results. *Arthroscopy* 1995; **11**: 29-36 [PMID: 7727009 DOI: 10.1016/0749-8063(95)90085-3]
 - 38 **Faunø P**, Nielsen AB. Arthroscopic partial meniscectomy: a long-term follow-up. *Arthroscopy* 1992; **8**: 345-349 [PMID: 1418207 DOI: 10.1016/0749-8063(92)90066-K]
 - 39 **Jørgensen U**, Sonne-Holm S, Lauridsen F, Rosenklint A. Long-term follow-up of meniscectomy in athletes. A prospective longitudinal study. *J Bone Joint Surg Br* 1987; **69**: 80-83 [PMID: 3818740]
 - 40 **Matsusue Y**, Thomson NL. Arthroscopic partial medial meniscectomy in patients over 40 years old: a 5- to 11-year follow-up study. *Arthroscopy* 1996; **12**: 39-44 [PMID: 8838727 DOI: 10.1016/S0749-8063(96)90217-0]
 - 41 **Aune AK**, Madsen JE, Moen H. Clinical significance of condylar chondromalacia after arthroscopic resection of flap-tears of the medial meniscus. A prospective study of 93 cases. *Arch Orthop Trauma Surg* 1995; **114**: 199-201 [PMID: 7662473 DOI: 10.1007/BF00444262]
 - 42 **Moseley JB**, O'Malley K, Petersen NJ, Menke TJ, Brody BA, Kuykendall DH, Hollingsworth JC, Ashton CM, Wray NP. A controlled trial of arthroscopic surgery for osteoarthritis of the knee. *N Engl J Med* 2002; **347**: 81-88 [PMID: 12110735 DOI: 10.1056/NEJMoa013259]
 - 43 **Bernstein J**, Quach T. A perspective on the study of Moseley et al: questioning the value of arthroscopic knee surgery for osteoarthritis. *Cleve Clin J Med* 2003; **70**: 401, 405-406, 405-406 [PMID: 12779130 DOI: 10.3949/ccjm.70.5.401]
 - 44 **Katz JN**, Harris TM, Larson MG, Krushell RJ, Brown CH, Fossel AH, Liang MH. Predictors of functional outcomes after arthroscopic partial meniscectomy. *J Rheumatol* 1992; **19**: 1938-1942 [PMID: 1294743]
 - 45 **Bernstein J**, Bartolozzi AR. Management of meniscal tears. *J Clin Outcomes Manage* 2000; **7**: 30-34
 - 46 **Cabaud HE**, Rodkey WG, Fitzwater JE. Medical meniscus repairs. An experimental and morphologic study. *Am J Sports Med* 1981; **9**: 129-134 [PMID: 6894516 DOI: 10.1177/036354658100900301]
 - 47 **Arnoczky SP**, Warren RF. The microvasculature of the meniscus and its response to injury. An experimental study in the dog. *Am J Sports Med* 1983; **11**: 131-141 [PMID: 6688156 DOI: 10.1177/036354658301100305]
 - 48 **vanTrommel MF**, Simonian PT, Potter HG, Wickiewicz TL. Arthroscopic meniscal repair with fibrin clot of complete radial tears of the lateral meniscus in the avascular zone. *Arthroscopy* 1998; **14**: 360-365 [PMID: 9620646 DOI: 10.1016/S0749-8063(98)70002-7]
 - 49 **Zhang Z**, Arnold JA. Trephination and suturing of avascular meniscal tears: a clinical study of the trephination procedure. *Arthroscopy* 1996; **12**: 726-731 [PMID: 9115563 DOI: 10.1016/S0749-8063(96)90178-4]
 - 50 **Cannon WD**, Vittori JM. The incidence of healing in arthroscopic meniscal repairs in anterior cruciate ligament-reconstructed knees versus stable knees. *Am J Sports Med* 1992; **20**: 176-181 [PMID: 1558246 DOI: 10.1177/036354659202000214]
 - 51 **Johnson MJ**, Lucas GL, Dusek JK, Henning CE. Isolated arthroscopic meniscal repair: a long-term outcome study (more than 10 years). *Am J Sports Med* 1992; **27**: 44-49 [PMID: 9934417]
 - 52 **DeHaven KE**, Lohrer WA, Lovelock JE. Long-term results of open meniscal repair. *Am J Sports Med* 1995; **23**: 524-530 [PMID: 8526265 DOI: 10.1177/036354659502300502]
 - 53 **Venkatachalam S**, Godsiff SP, Harding ML. Review of the clinical results of arthroscopic meniscal repair. *Knee* 2001; **8**: 129-133 [PMID: 11337239 DOI: 10.1016/S0968-0160(01)00061-8]
 - 54 **Seo HS**, Lee SC, Jung KA. Second-look arthroscopic findings after repairs of posterior root tears of the medial meniscus. *Am J Sports Med* 2011; **39**: 99-107 [PMID: 21051426 DOI: 10.1177/0363546510382225]
 - 55 **Pujol N**, Panarella L, Selmi TA, Neyret P, Fithian D, Beaufile P. Meniscal healing after meniscal repair: a CT arthrography assessment. *Am J Sports Med* 2008; **36**: 1489-1495 [PMID: 18483200 DOI: 10.1177/0363546508316771]
 - 56 **Getgood A**, Robertson A. Meniscal tears, repairs and replacement - a current concepts review. *Orthop Trauma* 2010; **24**: 121-128
 - 57 **Stein T**, Mehling AP, Welsch F, von Eisenhart-Rothe R, Jäger A. Long-term outcome after arthroscopic meniscal re-

- pair versus arthroscopic partial meniscectomy for traumatic meniscal tears. *Am J Sports Med* 2010; **38**: 1542-1548 [PMID: 20551284 DOI: 10.1177/0363546510364052]
- 58 **Rockborn P**, Gillquist J. Results of open meniscus repair. Long-term follow-up study with a matched uninjured control group. *J Bone Joint Surg Br* 2000; **82**: 494-498 [PMID: 10855869 DOI: 10.1302/0301-620X.82B4.9942]
- 59 **Barber FA**, McGarry JE. Meniscal repair techniques. *Sports Med Arthrosc* 2007; **15**: 199-207 [PMID: 18004219 DOI: 10.1097/JSA.0b013e3181595bed]
- 60 **Gill SS**, Diduch DR. Outcomes after meniscal repair using the meniscus arrow in knees undergoing concurrent anterior cruciate ligament reconstruction. *Arthroscopy* 2002; **18**: 569-577 [PMID: 12098116 DOI: 10.1053/jars.2002.29897]
- 61 **Lee GP**, Diduch DR. Deteriorating outcomes after meniscal repair using the Meniscus Arrow in knees undergoing concurrent anterior cruciate ligament reconstruction: increased failure rate with long-term follow-up. *Am J Sports Med* 2005; **33**: 1138-1141 [PMID: 16000655 DOI: 10.1177/0363546505275348]
- 62 **Arnoczky SP**, Lavagnino M. Tensile fixation strengths of absorbable meniscal repair devices as a function of hydrolysis time. An in vitro experimental study. *Am J Sports Med* 2001; **29**: 118-123 [PMID: 11292034]
- 63 **Kotsovolos ES**, Hantes ME, Mastrokalos DS, Lorbach O, Paessler HH. Results of all-inside meniscal repair with the FasT-Fix meniscal repair system. *Arthroscopy* 2006; **22**: 3-9 [PMID: 16399454 DOI: 10.1016/j.arthro.2005.10.017]
- 64 **Barber FA**, Schroeder FA, Oro FB, Beavis RC. FasT-Fix meniscal repair: mid-term results. *Arthroscopy* 2008; **24**: 1342-1348 [PMID: 19038704 DOI: 10.1016/j.arthro.2008.08.001]
- 65 **Barber FA**, Herbert MA. Meniscal repair devices. *Arthroscopy* 2000; **16**: 613-618 [PMID: 10976122 DOI: 10.1053/jars.2000.4819]
- 66 **Miller MD**, Kline AJ, Gonzales J, Beach WR. Pitfalls associated with FasT-Fix meniscal repair. *Arthroscopy* 2002; **18**: 939-943 [PMID: 12368795 DOI: 10.1053/jars.2002.36146]
- 67 **Grant JA**, Wilde J, Miller BS, Bedi A. Comparison of inside-out and all-inside techniques for the repair of isolated meniscal tears: a systematic review. *Am J Sports Med* 2012; **40**: 459-468 [PMID: 21737837 DOI: 10.1177/0363546511411701]
- 68 **Nepple JJ**, Dunn WR, Wright RW. Meniscal repair outcomes at greater than five years: a systematic literature review and meta-analysis. *J Bone Joint Surg Am* 2012; **94**: 2222-2227 [PMID: 23318612 DOI: 10.2106/JBJS.K.01584]

P- Reviewers: Serhan H, Sadoghi P **S- Editor:** Wen LL
L- Editor: A **E- Editor:** Lu YJ





Published by **Baishideng Publishing Group Inc**

8226 Regency Drive, Pleasanton, CA 94588, USA

Telephone: +1-925-223-8242

Fax: +1-925-223-8243

E-mail: bpgoffice@wjgnet.com

Help Desk: <http://www.wjgnet.com/esps/helpdesk.aspx>

<http://www.wjgnet.com>

