

Managing panniculitis in alpha-1 antitrypsin deficiency: Systematic review of evidence behind treatment

Donah K Sabbagh, Behrad Barmayehvar, Thanh Nguyen, Ross G Edgar, Alice M Turner

Donah K Sabbagh, the Medical Research Institute of New Zealand (MRINZ), CSB Building, Wellington Hospital, Newtown, Wellington 6021, New Zealand

Behrad Barmayehvar, Department of Colorectal Surgery, the Royal Wolverhampton Trust, Wolverhampton Road, West Midlands WV10 0QP, United Kingdom

Thanh Nguyen, Department of Intensive Care, United Lincolnshire Hospitals NHS Trust, Lincolnshire LN2 4AX, United Kingdom

Ross G Edgar, Therapy Services, University Hospitals Birmingham NHS Foundation Trust, Birmingham B15 2WG, United Kingdom

Alice M Turner, Institute of Applied Health Research, University of Birmingham, Birmingham B15 2TT, United Kingdom

ORCID number: Donah K Sabbagh (0000-0003-2629-9584); Behrad Barmayehvar (0000-0003-1824-601X); Thanh Nguyen (0000-0003-0546-7411); Ross G Edgar (0000-0002-5971-3035); Alice M Turner (0000-0002-5947-3254).

Author contributions: Sabbagh DK, Barmayehvar B and Nguyen T contributed equally to this work; Turner AM and Edgar RG designed the study; Edgar RG conducted the literature search; Barmayehvar B and Nguyen T screened the titles and abstracts of retrieved articles, involving a third reviewer (Edgar RG or Turner AM) where required; Turner AM and Edgar RG conducted quality assessment; Sabbagh DK extracted the data, and was checked by another (Barmayehvar B or Nguyen T); Sabbagh DK wrote the majority of the original draft of the paper in consultation with Turner AM; Barmayehvar B and Nguyen T participated in writing the paper; all authors discussed the results and commented on the manuscript; Turner AM was in charge of overall direction and planning.

Conflict-of-interest statement: Edgar RG has received non-commercial research funds from Grifols Biotherapeutics. Edgar RG reports grants from Health Education England (HEE) and the National Institute for Health Research (NIHR), outside the scope of this study.

Data sharing statement: This is not applicable to this review as only data from published works were processed and reviewed.

Open-Access: This article is an open-access article which was

selected by an in-house editor and fully peer-reviewed by external reviewers. It is distributed in accordance with the Creative Commons Attribution Non Commercial (CC BY-NC 4.0) license, which permits others to distribute, remix, adapt, build upon this work non-commercially, and license their derivative works on different terms, provided the original work is properly cited and the use is non-commercial. See: <http://creativecommons.org/licenses/by-nc/4.0/>

Manuscript source: Unsolicited manuscript

Correspondence to: Dr. Alice M Turner, MBChB, MRCP, PhD, Doctor, Senior Lecturer, Honorary Consultant Respiratory Physician, Institute of Applied Health Research, University of Birmingham, Edgbaston, Birmingham B15 2TT, United Kingdom. a.m.turner@bham.ac.uk
Telephone: +44-121-3713885
Fax: +44-121-3713887

Received: November 4, 2017

Peer-review started: November 5, 2017

First decision: November 20, 2017

Revised: November 27, 2017

Accepted: December 6, 2017

Article in press: December 6, 2017

Published online: February 2, 2018

Abstract

AIM

To systematically review literature for management of alpha-1 antitrypsin deficiency (AATD) panniculitis.

METHODS

Multiple databases were searched using combinations of pertinent terms. Articles were selected describing panniculitis treatment in patients with AAT < 11 μ mol and/or PiZZ genotype, with no language limitation. All relevant articles were accessed in full text. Independent review of abstracts and full manuscripts was conducted by 2 reviewers, and quality assessment by one reviewer (checked by a second). Data extraction was conducted by

one reviewer (checked by a second). Narrative synthesis only was conducted, as data were unsuitable for meta-analysis.

RESULTS

Thirty-two case reports and 4 case series were found. Augmentation therapy (infusions of plasma-derived AAT) was the most successful, with complete resolution of symptoms in all patients. Dapsone is a less expensive option, and it achieved clinical resolution in 62% of patients, but it is very poorly tolerated. Among other single-agent antibiotics, doxycycline was the most successful with complete clinical resolution seen in 33% of patients. Immunosuppressants were largely unsuccessful; 80% of patients exhibited no response. Liver transplantation and therapeutic plasma exchange displayed complete resolution in 66% of patients. Other strategies, such as non-steroidal anti-inflammatory drugs or antibiotics other than dapsone did not show sufficient response rates to recommend their use. Authors note the risk of bias imposed by the type of evidence (case reports, case series) available in this field.

CONCLUSION

Dapsone is the recommended first line therapy for AATD panniculitis, followed by augmentation therapy. Plasma exchange may be an alternative in the setting of rapidly progressive disease.

Key words: Alpha-1 antitrypsin deficiency; Dermatological treatment; Panniculitis; Dapsone; Augmentation therapy

© **The Author(s) 2018.** Published by Baishideng Publishing Group Inc. All rights reserved.

Core tip: There is limited evidence regarding treatment of alpha-1 antitrypsin deficiency (AATD)-related panniculitis. This study aims to systematically review literature for management of AATD-related panniculitis. The most effective treatment is augmentation therapy. Dapsone shows moderate success, but is significantly cheaper and easier to administer. Other treatments have shown limited benefit. Recommended first line therapy for AATD-related panniculitis is dapsone, followed by augmentation therapy. Plasma exchange may be an alternative in the setting of rapidly progressive disease, if augmentation were not available.

Sabbagh DK, Barmayehvar B, Nguyen T, Edgar RG, Turner AM. Managing panniculitis in alpha-1 antitrypsin deficiency: Systematic review of evidence behind treatment. *World J Dermatol* 2018; 7(1): 1-8 Available from: URL: <http://www.wjgnet.com/2218-6190/full/v7/i1/1.htm> DOI: <http://dx.doi.org/10.5314/wjd.v7.i1.1>

INTRODUCTION

Panniculitis is inflammation of subcutaneous fat tissue,

which can result from various causes and presents as tender, erythematous or pigmented skin nodules. Although the diagnosis is established with a skin biopsy, additional work-up is usually needed to investigate for the underlying cause^[1]. Panniculitis is associated with a variety of conditions, including alpha-1 antitrypsin deficiency (AATD), erythema nodosum and vasculitis^[2]. Classically, panniculitis due to underlying AATD has potentially distinguishing features, namely preference of lesions to the lower trunk and thighs, precipitation by trauma, and release of more oily yellow discharge than is otherwise seen^[3,4]. A skin biopsy displaying excessive fat necrosis and dense neutrophil infiltration into the dermis and connective tissue, alongside low alpha-1 antitrypsin (AAT) level and genotyping, confirms the diagnosis.

AATD is a rare, autosomal co-dominant genetic disorder that increases the risk of emphysema, liver cirrhosis, systemic vasculitis, and less frequently panniculitis^[5]. These complications are caused by the same underlying pathophysiological process; AAT is produced in the liver, and to a lesser degree in the lung, pancreas, colon and cornea. It controls the inflammatory cascade by regulating proteolytic enzymes such as neutrophil elastase^[5] and proteinase 3^[6]. Deficiency in AAT gives rise to unopposed proteolytic enzyme activity, inducing inflammatory processes in various body tissues, thus leading to the aforementioned clinical manifestations.

The AAT gene (*SERPINA1*) is on chromosome 14, and over 100 allelic variants are known^[5]. In AATD, mutations in *SERPINA1* lead to the production of misfolded and dysfunctional AAT proteins; depending on their electrophoretic mobility, allelic variants are referred to as M (medium), S (slow) or Z (very slow). The genotype is referred to as Pi followed by the two letters of the alleles, such that normal is PiMM. The most common genotype observed in symptomatic patients is PiZZ (70% of cases); other allele combinations include PiMZ, PiMS, PiSS, PiSNull and PiSZ, which all have varying phenotypic manifestations, often dependent on co-factors such as cigarette smoke exposure for lung disease^[7,8].

The association of AATD with panniculitis was first reported in 1972, although it remains a relatively rare complication. As a result, there is still great uncertainty with regards to management. Hence, the aim of this study is to systematically review the evidence for treatment of panniculitis in AATD.

MATERIALS AND METHODS

Search strategy

This review was part of a wider review of all management strategies for AATD and is registered on PROSPERO (PROSPERO 2016: CRD42016040142). The following electronic databases were searched using a strategy which combined textwords and index terms: MEDLINE (Ovid), MEDLINE In Process (Ovid), EMBASE (Ovid), Cochrane Library (Wiley) CENTRAL, CDSR, HTA, EED and

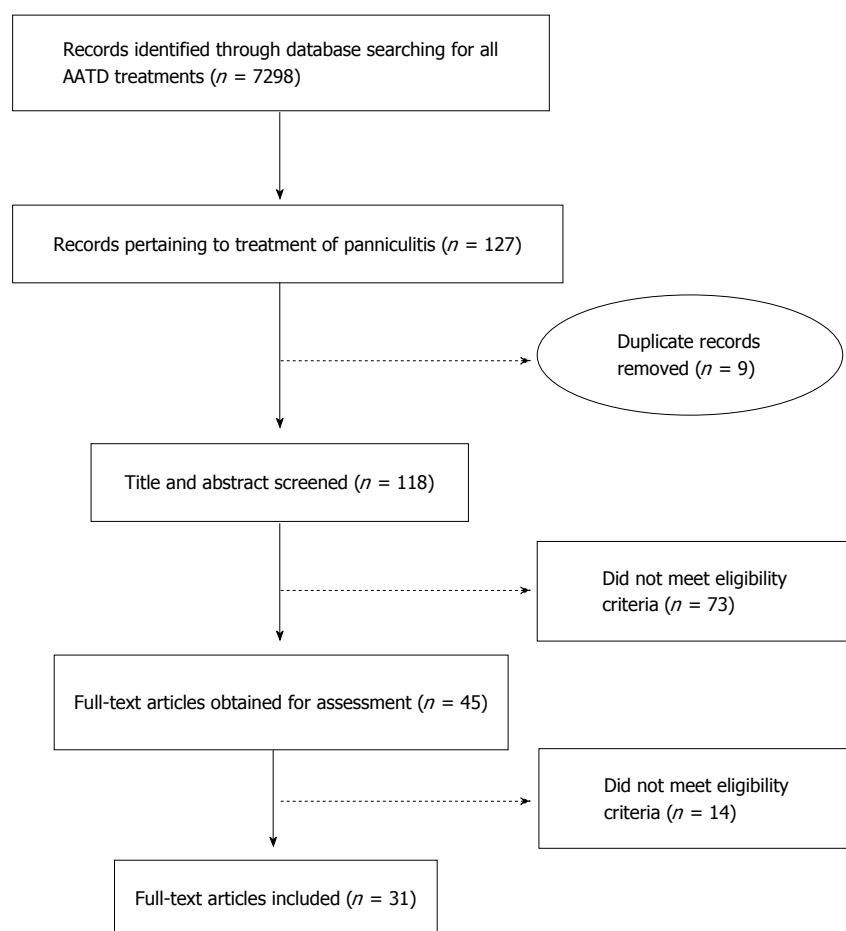


Figure 1 PRISMA flow diagram. A graphical representation of the flow of eligible citations through the separate phases of this systematic review's exclusion criteria, resulting in 36 articles suitable for inclusion. AATD: Alpha-1 antitrypsin deficiency.

DARE databases. In addition, Conference Proceedings Citation Index (CPCI) *via* Web of Science and British Library's ZETOC were searched for proceedings and abstracts, and ClinicalTrials.gov and WHO ICTRP (International Clinical Trials Registry Platform) were searched for ongoing trials. No language or date restrictions were applied. Any study design was eligible for inclusion if it reported a management strategy for panniculitis in an individual with AATD (confirmed by a serum AAT level of $< 11 \mu\text{mol/L}$ or $< 75\%$ of lower limit of normal (approximately 0.9 g/L), and/or confirmed PiZZ genotype). Non-systematic reviews were excluded, as were studies in heterozygotes with intermediate levels (e.g., PiMZ, PiMS), or where the level and genotype were not reported. Full search strategies are shown in the supplement.

Study selection, quality assessment and data extraction

Titles and abstracts of retrieved articles were screened by two reviewers independently (Behrad Barmayehvar and Thanh Nguyen), involving a third reviewer (Alice M Turner or Ross G Edgar) where required. Eligible articles were subsequently obtained and assessed against the full selection criteria independently (BS, TN or DS). Quality assessment was conducted by Alice M

Turner and checked by Ross G Edgar; since we did not find any manuscripts concerning designs other than case reports, case series or non-systematic reviews a formal scale to do this was inappropriate. For each study, data on study type, publication year and country, patient demographics, phenotype, serum AAT levels, time from start of symptoms to presentation, total time from admission to resolution, attempted treatments, response and duration of follow-up for each treatment, final outcome, side effects and complications were extracted by one reviewer (Donah K Sabbagh) and checked by another (BS or TN).

Evidence synthesis

The nature of the data meant that only narrative synthesis was performed. Data was summarised for each treatment in terms of complete, partial or no response.

RESULTS

Thirty-two case reports and 4 case-series, encompassing 42 patients were found (see PRISMA diagram, Figure 1). Panniculitis was described more commonly in female patients, and generally presented when patients were in their 30 s. The majority of the studies were performed

Table 1 Characteristics of patients studied and their response to treatment

	Total, <i>n</i> (male)	Age, median (range)	Response, <i>n</i> (%)				Ref.
			Complete	Partial	None	Not tolerated	
Dapsone	21 (5)	33 (13-65)	13 (62)	-	4 (19)	4 (19)	[9-25]
Single-agent antibiotics	21 (9)	33 (7-62)	4 (19)	4 (19)	13 (62)	-	[9,12,15,20,23,25-31]
Immunosuppressants	21 (8)	33 (13-65)	3 (14)	1 (5)	16 (76)	1 (5)	[9,11,14,15,18-20,25,27,28,31-35]
Augmentation	12 (2)	33 (16-65)	12 (100)	-	-	-	[1,12,14,18,19,29,30,36-39]
Antibiotics and steroids	10 (2)	34 (32-42)	1 (10)	3 (30)	6 (60)	-	[19,20,28,34,38,40]
Combination antibiotics	9 (4)	24 (20-62)	-	-	9 (100)	-	[14,15,23,25,36,37,39,41]
NSAIDs	8 (2)	32 (16-65)	1 (13)	1 (13)	6 (75)	-	[1,12,19,23,27,31,42]
Liver transplant	3 (2)	56 (53-57)	2 (67)	1 (33)	-	-	[23,36,43]
Plasma exchange	3 (1)	33 (23-33)	2 (67)	-	1 (33)	-	[18,27,31]
No treatment	2 (1)	34 (7-62)	-	2 (100)	-	-	[15,29]
Other	13 (4)	42 (26-62)	2 (15)	1 (8)	9 (69)	1 (8)	[17,18,20,26,29,32,33,41,42]

Note that each patient investigated could have multiple treatments attempted to control their AATD-related panniculitis. A complete response was one reported by the authors as clinically successful, requiring no further intervention. This may have taken the form of maintenance or intermittent therapy. A partial response was one of incomplete or temporary resolution of symptoms, requiring further treatments. NSAID: Non-steroidal anti-inflammatory drugs.

in Europe ($n = 21$) and the United States ($n = 17$), as expected for a disease prevalent in individuals with European ancestry. Characteristics of patients studied, stratified by treatment used, are shown in Table 1. Case reports and series are inherently prone to bias and no scoring systems exist to grade them, hence a formal assessment of quality was not applicable.

Augmentation therapy was the most successful treatment, with complete resolution of symptoms in all 12 patients (100%). However, it was less likely to be used to treat symptoms than dapsone monotherapy, single-agent antibiotics, and immunosuppressants. Of these, dapsone was the most likely to achieve clinical resolution of AATD-related panniculitis (62%). Unfortunately, dapsone was also the most poorly tolerated treatment, with 19% of patients discontinuing therapy as a result of the side effects. The relative success rate of each treatment strategy is shown in Table 1 and Figure 2.

The single-agent antibiotics investigated were doxycycline (29%); unspecified tetracycline (14%); cefazolin, minocycline, and clindamycin (10% each); and ampicillin, lincomycin, sulphonamide, penicillin, erythromycin (5% each). Of these, doxycycline was most successful, with complete clinical resolution seen in two of six patients treated. Only two other agents resulted in at least partial symptom control - minocycline and nafcillin - use of minocycline alongside augmentation therapy ensured full disease control in one case.

A variety of immunosuppressants were attempted: Prednisolone (57%), methylprednisolone (17%), dexamethasone, cyclophosphamide, combination dexamethasone/cyclophosphamide (dex/cyc), ciclosporin, deflazacort, and unspecified "systemic steroid" (8% each). Success was seen in two patients receiving oral prednisolone (either repeated courses or prophylactic therapy), and one patient on a prolonged course of dex/cyc. The duration of follow up for the prednisolone-

receiving patients was not defined, but remission was seen for two years in the patient who received dex/cyc (excluding two minor trauma-exacerbated lesions, which did not require treatment). A single patient received partial resolution of symptoms with methylprednisolone, but this was later supplemented with dapsone for complete effect. Despite these few successes, immunosuppressants were largely unsuccessful, with 80% of patients exhibiting no response.

Antibiotic and steroid combinations tried in reported studies are listed in the supplementary material. Only one combination proved successful; methylprednisolone with dapsone. Partial responses were seen with prednisolone/doxycycline/dapsone and deflazacort/minocycline. Overall, antibiotics with glucocorticoids were unsuccessful, with 60% receiving no benefit. Nine patients received unique antibiotic combinations (*e.g.*, dapsone/doxycycline) and two patients received unspecified "antibiotics". Combination antibiotics were the most unsuccessful treatment, with all cases failing to respond, seemingly irrespective of the antibiotics used in combination.

Non-steroidal anti-inflammatory drug (NSAID) therapy was attempted on 8 patients, in the form of colchicine (50%), ibuprofen, diclofenac (13% each), and unspecified NSAIDs. One patient receiving colchicine had complete resolution, another showed partial response to unspecified NSAID, but required augmentation for complete symptom control. Liver transplantation and therapeutic plasma exchange exhibited positive results with complete resolution of symptoms in 2 of 3 patients managed with each therapy. There were also a range of other treatments attempted on individual patients (see supplement). Successful outcomes were achieved with combination colchicine/cloxacillin and ketoconazole monotherapy. A partial response was also seen with cryotherapy, however the lesions re-appeared after two months, and required colchicine to manage them.

All remaining treatments were unsuccessful.

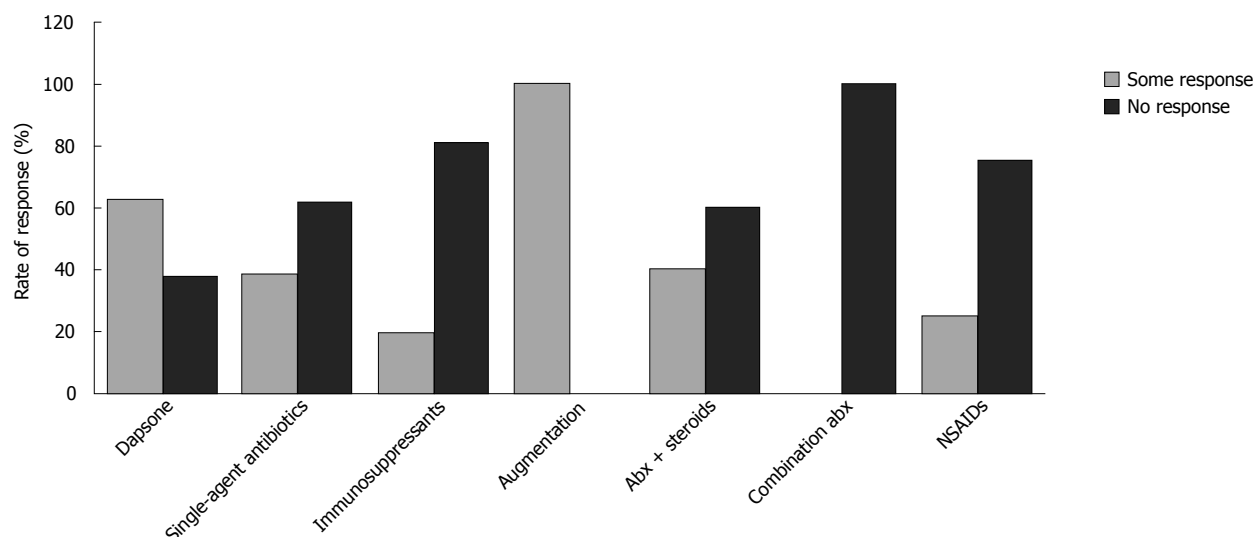


Figure 2 Rate of response of alpha-1 antitrypsin deficiency panniculitis to key treatments. "Some response" represents either complete or partial clinical resolution of symptoms; "No response" represents either no clinical response or intolerance of the treatment option. Abx: Antibiotics; NSAID: Non-steroidal anti-inflammatory drugs.

DISCUSSION

This unique systematic review has revealed the most effective treatment for AATD panniculitis to be augmentation therapy. Dapsone also exhibited a good effect in a high proportion of patients, and is significantly easier to administer and less expensive, thereby making it a better first-line therapeutic option. The quality of the evidence is poor, although the rarity of the condition has likely been a key factor precluding more robust study designs such as RCTs. As a result, the evolution of disease in each patient was not documented to a degree allowing comparison or commentary. Furthermore, as only PIZZ genotypes were included, it is not possible to assess whether different genotypes respond better to different treatments.

Intravenous infusion of AAT from pooled human plasma is a direct and efficient method for increasing plasma AAT levels, and can reduce progression of emphysema in AATD^[44]. Controversially, a recent Cochrane review suggests there is insufficient evidence supporting the efficacy of IV AAT in emphysema and lung disease^[45]. This conclusion may be due to the difficulty in assessing success in AATD lung pathology - progression of disease is best confirmed with CT imaging, which is currently only used in a research setting. In contrast, the response of panniculitis to augmentation therapy is easy to assess clinically. Indeed, the results of this narrative review suggest that augmentation therapy is the most successful medical treatment for AATD-related panniculitis, as everyone of the twelve patients who received it had complete resolution of their disease. There is a good biological rationale for use of augmentation, in that it should correct the protease imbalance observed in areas of AAT panniculitis and modulate neutrophil activation and degranulation^[46], with the end result of decreasing inflammatory cytokine

burden and downstream proteolysis. However, cost-effectiveness remains questionable, particularly as two-thirds of the investigated patients required multiple courses of augmentation or lifelong intermittent/maintenance therapy^[1,12,14,18,19,36-38]. These patients were followed up for variable durations, with a mean of 47 wk follow-up (excluding two unspecified periods). The third of patients who required a single course of augmentation therapy were followed-up for an average of only four weeks (excluding one unknown duration)^[19,29,30,39]. This is likely an insufficient duration, thus not representative of numbers of courses of augmentation required by those individuals. It is probable the majority will require repeated courses if disease recurs, hence accumulating a large cost. For this reason, despite the safety and effectiveness of this therapy, initial use of more conservative methods of symptom control seems warranted.

Systemic dapsone is best known for its part in the first-line combination therapy of leprosy^[47]. As a medication which can be taken orally, dapsone has several advantages over augmentation for AATD panniculitis, being simpler to administer and less expensive. Various antimicrobials, such as tetracyclines, are believed to protect AAT from neutrophil-mediated degradation^[48]. Dapsone not only possesses this property^[49] but also has antibiotic and anti-inflammatory effects - it is bacteriostatic, inhibits reactive oxygen species production^[50], prostaglandin production^[51] and IL8 release in the context of inflammatory stimuli^[52], as well as reducing CD11b mediated neutrophil adhesion^[53]. This multitude of effects could explain why it appears to have greater efficacy for treating panniculitis than other antibiotics. However, if it is this combined action which explains its effect, it's unclear why combinations of other antibiotics and anti-inflammatories possessing similar actions have been hitherto demonstrated unsuccessful.

For those in whom dapsone failed, augmentation therapy succeeded and was well tolerated^[12,14,18,19,39], suggesting it would be a sensible second-line therapy.

Three patients described in our included cases received therapeutic plasmapheresis. Two had complete resolution of symptoms, with follow up times varying between fourteen days and three months. One patient received plasma exchange in combination with theophylline and hydrocortisone, but received no benefit from treatment and died soon thereafter^[26]. Due to the lack of evidence to support plasmapheresis and a lower treatment resolution rate, augmentation seems superior to plasma exchange, but it might remain an option in countries where augmentation is unavailable, or disease is very severe with rapid benefit required.

All other treatment regimens reported had either low success rates, or were impractical to use widely. Twenty-one patients received single-agent antibiotics other than dapsone. Panniculitis in AATD is thought to be due to a prolonged and exaggerated inflammatory response, secondary to protease-antiprotease imbalance. Tetracyclines such as doxycycline can protect AAT from breakdown by neutrophil collagenase and gelatinase enzymes^[48], however the included studies indicated that this theoretical benefit on pathogenesis was not borne out clinically in AATD panniculitis for any antimicrobials other than dapsone. Post-steroid panniculitis is a subtype of the panniculitis, seen in children following the withdrawal of steroids^[54]; consequently a role for immunosuppressant or steroid therapies in AATD panniculitis would not be unreasonable. Paradoxically, no benefit was seen. There is no apparent cause for the failure of steroids or steroid-sparing agents in AATD-panniculitis. Perhaps the mechanism of AATD does not facilitate the action of immunosuppressants, or there is a narrow therapeutic window. This could be explored by stratification of patients by dose and route of administration. Further understanding of this may unlock better comprehension of AATD.

A number of medical conditions benefit from antibiotic-corticosteroid combinations, yet the utility of this management in AATD panniculitis had little supporting evidence. Co-administration of steroids with antibiotics have reduced inpatient durations of stay in other neutrophilic conditions such as pneumonia^[55], but the data here was insufficient to say this effect would be consistently seen. One difficulty with combination therapy is assessing if the benefit is from a single agent or the combination. In addition, poor description of combined therapies made comparison to single-agents impossible. Indeed, the seemingly positive response rates of antimicrobial/steroid combinations may be over-estimated due to a single patient who received multiple combinations and displayed positive responses to them.

Improvements of solid organ transplantation techniques have made hepatic transplants a viable therapeutic option for end-stage liver disease in AATD. This is advantageous, as secretion of AAT by the donor liver

cures the deficiency. Post-operative survival rates of liver transplants in AATD are good, with a 5-year survival of adult patients between 80%-83%^[56,57], and a 10-year survival of 72%^[56]. However, due to the reservation of liver transplants for only the fittest patients with end-stage hepatic disease, as well as the large number of contraindications to surgery, intra-operative risks, post-operative risks associated with immunosuppression, and the costs of surgery, this is not a practical option for patients with AATD associated panniculitis.

Two patients within this systematic review received no treatment for their AATD-panniculitis. One patient re-presented to hospital after two weeks, and the other after 25 years. Although withholding treatment is not a feasible management option in most cases of AATD-panniculitis, this does open up questions to whether commencing treatment should be delayed in simple panniculitis, to see whether natural resolution will occur.

This review was limited primarily by the relatively poor quality of the available evidence. Further exploration is also necessary to deduce the mechanism of action of dapsone in AATD panniculitis, which seems to work in ways not explained by other anti-inflammatory or antimicrobial therapies alone, or combined. Further understanding of dapsone might unlock deeper knowledge of the disease process in necrotizing panniculitis in AATD, and reveal further treatment options.

Dapsone should be first-line therapy for AATD panniculitis, and augmentation therapy second-line. Plasma exchange may be an alternative in the setting of rapidly progressive disease, particularly if augmentation were not available.

ARTICLE HIGHLIGHTS

Research background

Panniculitis is a rare manifestation of an alpha-1 antitrypsin deficiency (AATD), an already rare disease. This rarity has created a paucity in the data concerning effective management strategies of AATD-panniculitis.

Research motivation

This systematic review has investigated the available literature for the optimal management strategies for clinical resolution of AATD-panniculitis. Effective management will be helpful for both patients and clinicians, as well as opening up avenues of research allowing better understanding of this disease process.

Research objectives

To perform a systematic review of the management of patients with AATD-panniculitis, investigating interventions used and whether clinical resolution was achieved. This objective was realised, enabling the authors to advise an effective management strategy for clinical resolution. Successful management will be helpful for both patients and clinicians, as well as opening up avenues of research allowing better understanding of this disease process.

Research methods

A variety of databases were searched for appropriate papers. A title and abstract review was performed by two reviewers, and pertinent studies were obtained in full - to include 32 case reports and 4 case series. The appropriate data was extracted by one reviewer and checked by another. The nature of the data meant that only narrative synthesis was performed, and a formal assessment of quality was not applicable.

Research results

Augmentation therapy was the most successful treatment, achieving clinical resolution in 100% of managed patients. Dapsone was a cheaper alternative, achieving clinical resolution in 62%, but being very poorly tolerated. Other single-agent antibiotics were mostly unsuccessful, with the exception of doxycycline (complete resolution in 33%). Immunosuppressants were also largely unsuccessful; 80% of patients exhibited no response. Liver transplantation and therapeutic plasma exchange displayed complete resolution in 66% of patients. Other strategies, such as non-steroidal anti-inflammatory drugs (NSAIDs), or combination antibiotics, did not show sufficient response rates to recommend their use. These results contribute valuable information on effective therapeutic strategies for AATD-panniculitis. Further understanding on the mechanisms of certain therapeutic agents (e.g., dapsone/immunosuppressants) are yet to be investigated, and might unlock key concepts on the pathogenesis of panniculitis or AATD.

Research conclusions

This study suggests an effective management strategy for panniculitis presenting in AATD. Based on likelihood of complete clinical resolution and cost-implications, AATD-panniculitis should be managed with dapsone first-line, and augmentation as a second-line measure. In countries where augmentation is not available, or in cases of rapidly progressing disease, plasmapheresis may be a valuable alternative.

Research perspectives

This study has the potential to change the future management of AATD-panniculitis, both unifying an effective management strategy amongst current/future clinicians, and opening up avenues of further research to enable better understanding of this disease presentation

ACKNOWLEDGMENTS

The authors would like to acknowledge Mitesh Patel and Sue Bayliss who assisted the wider searches in the parent systematic review of all AATD treatments. This study is exempt from ethical review.

REFERENCES

- Gross B, Grebe M, Wencker M, Stoller JK, Bjursten LM, Janciauskiene S. New Findings in PiZZ alpha1-antitrypsin deficiency-related panniculitis. Demonstration of skin polymers and high dosing requirements of intravenous augmentation therapy. *Dermatology* 2009; **218**: 370-375 [PMID: 19218787 DOI: 10.1159/000202982]
- Lyon MJ. Metabolic panniculitis: alpha-1 antitrypsin deficiency panniculitis and pancreatic panniculitis. *Dermatol Ther* 2010; **23**: 368-374 [PMID: 20666824 DOI: 10.1111/j.1529-8019.2010.01337.x]
- Valverde R, Rosales B, Ortiz-de Frutos FJ, Rodriguez-Peralto JL, Ortiz-Romero PL. Alpha-1-antitrypsin deficiency panniculitis. *Dermatol Clin* 2008; **26**: 447-451, vi [PMID: 18793976 DOI: 10.1016/j.det.2008.05.001]
- Geraminejad P, DeBloom JR 2nd, Walling HW, Sontheimer RD, VanBeek M. Alpha-1-antitrypsin associated panniculitis: the MS variant. *J Am Acad Dermatol* 2004; **51**: 645-655 [PMID: 15389208 DOI: 10.1016/j.jaad.2003.12.053]
- Stockley RA, Turner AM. α -1-Antitrypsin deficiency: clinical variability, assessment, and treatment. *Trends Mol Med* 2014; **20**: 105-115 [PMID: 24380646 DOI: 10.1016/j.molmed.2013.11.006]
- Sinden NJ, Stockley RA. Proteinase 3 activity in sputum from subjects with alpha-1-antitrypsin deficiency and COPD. *Eur Respir J* 2013; **41**: 1042-1050 [PMID: 22936713 DOI: 10.1183/09031936.00089712]
- Green CE, Vayalappa S, Hampson JA, Mukherjee D, Stockley RA, Turner AM. PiSZ alpha-1 antitrypsin deficiency (AATD): pulmonary phenotype and prognosis relative to PiZZ AATD and PiMM COPD. *Thorax* 2015; **70**: 939-945 [PMID: 26141072 DOI: 10.1136/thoraxjnl-2015-206906]
- Molloy K, Hersh CP, Morris VB, Carroll TP, O'Connor CA, Lasky-Su JA, Greene CM, O'Neill SJ, Silverman EK, McElvaney NG. Clarification of the risk of chronic obstructive pulmonary disease in α 1-antitrypsin deficiency PiMZ heterozygotes. *Am J Respir Crit Care Med* 2014; **189**: 419-427 [PMID: 24428606 DOI: 10.1164/rccm.201311-1984OC]
- Kunz B, Boer-Auer A, Loegering B, Lentz E, Reich K. Panniculitis as presenting sign of hereditary alpha-1-antitrypsin-deficiency in a 13 year old boy. *J Dtsch Dermatol Ges* 2014; **12**: 1-2
- Martinón Sánchez F, Fernández Villar MC, Otero Esteban JJ, García Rodríguez JL. [Panniculitis associated with alpha 1-antitrypsin deficiency]. *An Esp Pediatr* 1993; **38**: 269-270 [PMID: 8460849]
- Edmonds BK, Hodge JA, Rietschel RL. Alpha 1-antitrypsin deficiency-associated panniculitis: case report and review of the literature. *Pediatr Dermatol* 1991; **8**: 296-299 [PMID: 1792202 DOI: 10.1111/j.1525-1470.1991.tb00937.x]
- Al-Niaimi F, Lyon C. Severe ulcerative panniculitis caused by alpha 1-antitrypsin deficiency: remission induced and maintained with intravenous alpha 1-antitrypsin. *J Am Acad Dermatol* 2011; **65**: 227-229 [PMID: 21679830 DOI: 10.1016/j.jaad.2009.11.587]
- Geller JD, Su WP. A subtle clue to the histopathologic diagnosis of early alpha 1-antitrypsin deficiency panniculitis. *J Am Acad Dermatol* 1994; **31**: 241-245 [PMID: 8040408 DOI: 10.1016/S0190-9622(94)70155-5]
- Kjus T, Lützw-Holm C, Christensen OB. Treatment of panniculitis associated with alpha-1-antitrypsin deficiency with alpha-1-protease inhibitor. *Acta Derm Venereol* 2003; **83**: 462-463 [PMID: 14690345 DOI: 10.1080/00015550310015004]
- Hendrick SJ, Silverman AK, Solomon AR, Headington JT. Alpha 1-antitrypsin deficiency associated with panniculitis. *J Am Acad Dermatol* 1988; **18**: 684-692 [PMID: 3259592 DOI: 10.1016/S0190-9622(88)70091-2]
- Irvine C, Neild V, Stephens C, Black M. Alpha-1-antitrypsin deficiency panniculitis. *J R Soc Med* 1990; **83**: 743-744 [PMID: 2250276]
- Yesudian PD, Dobson CM, Wilson NJ. alpha1-Antitrypsin deficiency panniculitis (phenotype PiZZ) precipitated postpartum and successfully treated with dapsone. *Br J Dermatol* 2004; **150**: 1222-1223 [PMID: 15214923 DOI: 10.1111/j.1365-2133.2004.05991.x]
- Chowdhury MM, Williams EJ, Morris JS, Ferguson BJ, McGregor AD, Hedges AR, Stamatakis JD, Pope FM. Severe panniculitis caused by homozygous ZZ alpha1-antitrypsin deficiency treated successfully with human purified enzyme (Prolastin). *Br J Dermatol* 2002; **147**: 1258-1261 [PMID: 12452881 DOI: 10.1046/j.1365-2133.2002.05095.x]
- Pittelkow MR, Smith KC, Su WP. Alpha-1-antitrypsin deficiency and panniculitis. Perspectives on disease relationship and replacement therapy. *Am J Med* 1988; **84**: 80-86 [PMID: 3260076 DOI: 10.1016/0002-9343(88)90163-5]
- Ginarte M, Rosón E, Peteiro C, Toribio J. Treatment of alpha1-antitrypsin-deficiency panniculitis with minocycline. *Cutis* 2001; **68**: 86-88 [PMID: 11534920]
- Rajagopal R, Malik AK, Murthy PS, Neog LS. Alpha-1 antitrypsin deficiency panniculitis. *Indian J Dermatol Venereol Leprol* 2002; **68**: 362-364 [PMID: 17657006]
- Ortiz PG, Skov BG, Benfeldt E. Alpha1-antitrypsin deficiency-associated panniculitis: case report and review of treatment options. *J Eur Acad Dermatol Venereol* 2005; **19**: 487-490 [PMID: 15987301 DOI: 10.1111/j.1468-3083.2005.01194.x]
- Harris S, Naina H. Alpha 1 antitrypsin associated panniculitis-recurrence following liver transplantation. *Am J Gastroenterol* 2012; **107**: S198-S199
- Schadendorf D, Haas N, Nürnberger F, Czarnetzki BM. [Recurrent nodular panniculitis in alpha 1-antitrypsin deficiency. Successful dapsone therapy]. *Hautarzt* 1993; **44**: 653-657 [PMID: 8225975]
- Korver G, Liu C, Petersen M. alpha1-Antitrypsin deficiency presenting with panniculitis and incidental discovery of chronic obstructive pulmonary disease. *Int J Dermatol* 2007; **46**: 1078-1080 [PMID: 17910720 DOI: 10.1111/j.1365-4632.2006.03067.x]

- 26 **Balk E**, Bronsveld W, Van der Deyl JA, Kwee WS, Thiss LG. Alpha 1-antitrypsin deficiency with vascular leakage syndrome and panniculitis. *Neth J Med* 1982; **25**: 138-141 [PMID: 6980376]
- 27 **de Oliveira P**, Paz-Melgar L, Takahashi MD, Nico MM, Rivitti EA, Mendrone A Jr, Tatsui NH. Alpha-1-antitrypsin deficiency associated with panniculitis treated with plasma exchange therapy. *Int J Dermatol* 2004; **43**: 693-697 [PMID: 15357756 DOI: 10.1111/j.1365-4632.2004.02054.x]
- 28 **Fongers A**, Horvath B. A rare presentation of alpha-1-antitrypsin deficiency: Panniculitis and generalized edema. [Dutch] Een zeldzame presentatie van alfa-1-antitrypsine deficiëntie: Panniculitis en generaliseerd oedeem. *Nederlands Tijdschrift voor Dermatologie & Venereologie* 2008; **18**: 380-382
- 29 **Furey NL**, Golden RS, Potts SR. Treatment of alpha-1-antitrypsin deficiency, massive edema, and panniculitis with alpha-1 protease inhibitor. *Ann Intern Med* 1996; **125**: 699 [PMID: 8849167 DOI: 10.7326/0003-4819-125-8-199610150-00027]
- 30 **Genders R**, Basdew VR, Pavel S. Panniculitis with alpha-1-antitrypsin deficiency. [Dutch] Panniculitis bij alfa-1-anti-trypsinedeficiëntie. *Nederlands Tijdschrift voor Dermatologie en Venereologie* 2010; **20**: 318-319
- 31 **Viraben R**, Massip P, Dicostanzo B, Mathieu C. Necrotic panniculitis with alpha-1 antitrypsin deficiency. *J Am Acad Dermatol* 1986; **14**: 684-687 [PMID: 3485667 DOI: 10.1016/S0190-9622(86)80466-2]
- 32 **Alvarez Lopez J**, Zulaica A, Fabeiro JM, Caeiro JL, Peteiro C, Toribio J. Liquefying panniculitis associated to alpha-1-antitrypsin deficiency. [Spanish] Panniculitis Licuefactiva Asociada a Deficit De Alfa-1-Antitripsina. *Med Cutan Ibero Lat Am* 1993; **21**: 126-130
- 33 **Breit SM**, Clark P, Robinson JP, Luckhurst E, Dawkins RL, Penny R. Familial occurrence of alpha 1-antitrypsin deficiency and Weber-Christian disease. *Arch Dermatol* 1983; **119**: 198-202 [PMID: 6600598 DOI: 10.1001/archderm.1983.01650270016009]
- 34 **Filaci G**, Contini P, Barbera P, Bernardini L, Indiveri F. Autoantibodies to neutrophilic proteases in a case of panniculitis by deficit of alpha-1-antitrypsin. *Rheumatology (Oxford)* 2000; **39**: 1289-1290 [PMID: 11085814 DOI: 10.1093/rheumatology/39.11.1289]
- 35 **Lonchamp F**, Blanc D, Terrasse F, Humbert P, Kienzler JL, Agache P. [Weber-Christian disease associated with familial alpha-1-antitrypsin deficiency. Apropos of a case]. *Ann Dermatol Venereol* 1985; **112**: 35-39 [PMID: 3874579]
- 36 **O'Riordan K**, Blei A, Rao MS, Abecassis M. alpha 1-antitrypsin deficiency-associated panniculitis: resolution with intravenous alpha 1-antitrypsin administration and liver transplantation. *Transplantation* 1997; **63**: 480-482 [PMID: 9039946]
- 37 **Sandhu MS**, Dimov V, Bewtra A. Alpha-1 antitrypsin deficiency associated panniculitis. *Ann Allergy Asthma Immunol* 2009; **3**: A142
- 38 **Olson JM**, Moore EC, Valasek MA, Williams LH, Vary JC. Panniculitis in alpha-1 antitrypsin deficiency treated with enzyme replacement. *J Am Acad Dermatol* 2012; **66**: e139-e141 [PMID: 22421127 DOI: 10.1016/j.jaad.2010.11.006]
- 39 **Rasool S**, Harman K, Bamford M, Saldanha G. Alpha-1-antitrypsin deficiency panniculitis treated with enzyme replacement. *Br J Dermatol* 2014; **171**: 56-57
- 40 **Rubinstein HM**, Jaffer AM, Kudrna JC, Lertratanakul Y, Chandrasekhar AJ, Slater D, Schmid FR. Alpha-1-antitrypsin deficiency with severe panniculitis. Report of two cases. *Ann Intern Med* 1977; **86**: 742-744 [PMID: 301370 DOI: 10.7326/0003-4819-86-6-742]
- 41 **Pottage JC Jr**, Trenholme GM, Aronson IK, Harris AA. Panniculitis associated with histoplasmosis and alpha 1-antitrypsin deficiency. *Am J Med* 1983; **75**: 150-153 [PMID: 6305193 DOI: 10.1016/0002-9343(83)91179-8]
- 42 **Linares-Barrios M**, Conejo-Mir IS, Artola Igarza JL, Navarrete M. Panniculitis due to alpha 1-antitrypsin deficiency induced by cryosurgery. *Br J Dermatol* 1998; **138**: 552-553 [PMID: 9580825 DOI: 10.1046/j.1365-2133.1998.02149.x]
- 43 **Fernández-Torres R**, García-Silva J, Robles O, Otero A, Vázquez MA, Fonseca E. Alfa-1-antitrypsin deficiency panniculitis acquired after liver transplant and successfully treated with retransplant. *J Am Acad Dermatol* 2009; **60**: 715-716 [PMID: 19293031 DOI: 10.1016/j.jaad.2008.10.012]
- 44 **Chapman KR**, Burdon JG, Piitulainen E, Sandhaus RA, Seersholm N, Stocks JM, Stoel BC, Huang L, Yao Z, Edelman JM, McElvaney NG; RAPID Trial Study Group. Intravenous augmentation treatment and lung density in severe α 1 antitrypsin deficiency (RAPID): a randomised, double-blind, placebo-controlled trial. *Lancet* 2015; **386**: 360-368 [PMID: 26026936 DOI: 10.1016/S0140-6736(15)60860-1]
- 45 **Gotzsche PC**, Johansen HK. Intravenous alpha-1 antitrypsin augmentation therapy for treating patients with alpha-1 antitrypsin deficiency and lung disease. *Cochrane Database Syst Rev* 2016; **9**: CD007851 [PMID: 27644166 DOI: 10.1002/14651858.CD007851.pub3]
- 46 **Bergin DA**, Reeves EP, Hurley K, Wolfe R, Jameel R, Fitzgerald S, McElvaney NG. The circulating proteinase inhibitor α -1 antitrypsin regulates neutrophil degranulation and autoimmunity. *Sci Transl Med* 2014; **6**: 217ra1 [PMID: 24382893 DOI: 10.1126/scitranslmed.3007116]
- 47 **Freerksen E**, Rosenfeld M, Depasquale G, Bonnici E, Gatt P. The Malta Project--a country freed itself of leprosy. A 27-year progress study (1972-1999) of the first successful eradication of leprosy. *Chemotherapy* 2001; **47**: 309-331 [PMID: 11561134 DOI: 10.1159/000048539]
- 48 **Sorsa T**, Lindy O, Kontinen YT, Suomalainen K, Ingman T, Saari H, Halinen S, Lee HM, Golub LM, Hall J. Doxycycline in the protection of serum alpha-1-antitrypsin from human neutrophil collagenase and gelatinase. *Antimicrob Agents Chemother* 1993; **37**: 592-594 [PMID: 8384819 DOI: 10.1128/AAC.37.3.592]
- 49 **Theron A**, Anderson R. Investigation of the protective effects of the antioxidants ascorbate, cysteine, and dapsone on the phagocyte-mediated oxidative inactivation of human alpha-1-protease inhibitor in vitro. *Am Rev Respir Dis* 1985; **132**: 1049-1054 [PMID: 2998243]
- 50 **Suda T**, Suzuki Y, Matsui T, Inoue T, Niide O, Yoshimaru T, Suzuki H, Ra C, Ochiai T. Dapsone suppresses human neutrophil superoxide production and elastase release in a calcium-dependent manner. *Br J Dermatol* 2005; **152**: 887-895 [PMID: 15888142 DOI: 10.1111/j.1365-2133.2005.06559.x]
- 51 **Anderson R**. Enhancement by clofazimine and inhibition by dapsone of production of prostaglandin E2 by human polymorphonuclear leukocytes in vitro. *Antimicrob Agents Chemother* 1985; **27**: 257-262 [PMID: 3857019 DOI: 10.1128/AAC.27.2.257]
- 52 **Kanoh S**, Tanabe T, Rubin BK. Dapsone inhibits IL-8 secretion from human bronchial epithelial cells stimulated with lipopolysaccharide and resolves airway inflammation in the ferret. *Chest* 2011; **140**: 980-990 [PMID: 21436242 DOI: 10.1378/chest.10-2908]
- 53 **Booth SA**, Moody CE, Dahl MV, Herron MJ, Nelson RD. Dapsone suppresses integrin-mediated neutrophil adherence function. *J Invest Dermatol* 1992; **98**: 135-140 [PMID: 1732379 DOI: 10.1111/1523-1747.ep12555654]
- 54 **Torrelo A**, Hernández A. Panniculitis in children. *Dermatol Clin* 2008; **26**: 491-500, vii [PMID: 18793982 DOI: 10.1016/j.det.2008.05.010]
- 55 **Horita N**, Otsuka T, Haranaga S, Namkoong H, Miki M, Miyashita N, Higa F, Takahashi H, Yoshida M, Kohno S, Kaneko T. Adjunctive Systemic Corticosteroids for Hospitalized Community-Acquired Pneumonia: Systematic Review and Meta-Analysis 2015 Update. *Sci Rep* 2015; **5**: 14061 [PMID: 26374694 DOI: 10.1038/srep14061]
- 56 **Carey EJ**, Iyer VN, Nelson DR, Nguyen JH, Krowka MJ. Outcomes for recipients of liver transplantation for alpha-1-antitrypsin deficiency-related cirrhosis. *Liver Transpl* 2013; **19**: 1370-1376 [PMID: 24019185 DOI: 10.1002/lt.23744]
- 57 **Kemmer N**, Kaiser T, Zacharias V, Neff GW. Alpha-1-antitrypsin deficiency: outcomes after liver transplantation. *Transplant Proc* 2008; **40**: 1492-1494 [PMID: 18589136 DOI: 10.1016/j.transproceed.2008.02.075]

P- Reviewer: Cuevas-Covarrubias SA, Kaliyadan F, Yap FBB

S- Editor: Ji FF L- Editor: A E- Editor: Lu YJ





Published by **Baishideng Publishing Group Inc**
7901 Stoneridge Drive, Suite 501, Pleasanton, CA 94588, USA
Telephone: +1-925-223-8242
Fax: +1-925-223-8243
E-mail: bpgoffice@wjgnet.com
Help Desk: <http://www.f6publishing.com/helpdesk>
<http://www.wjgnet.com>

