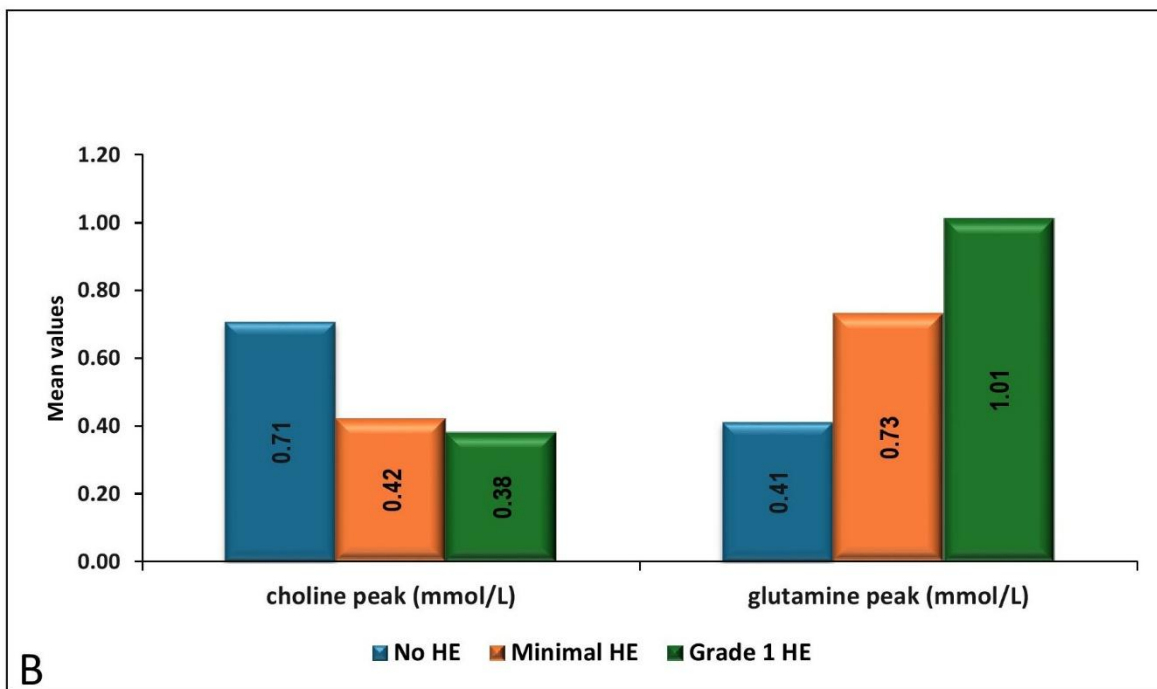
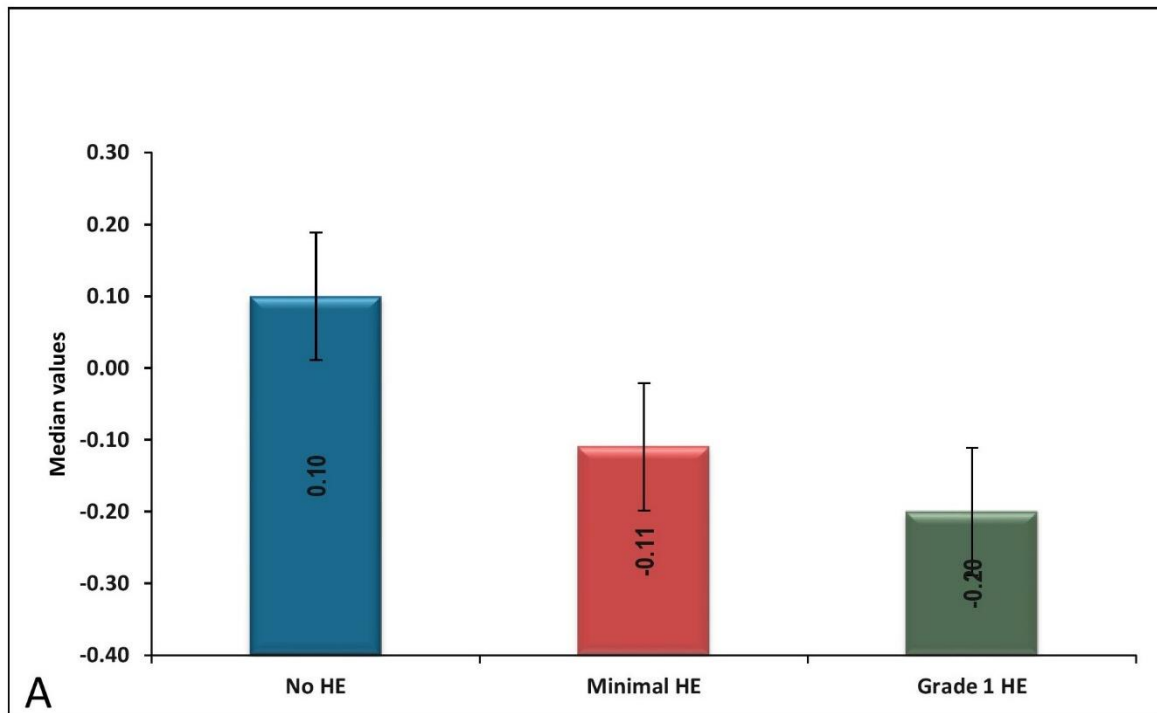
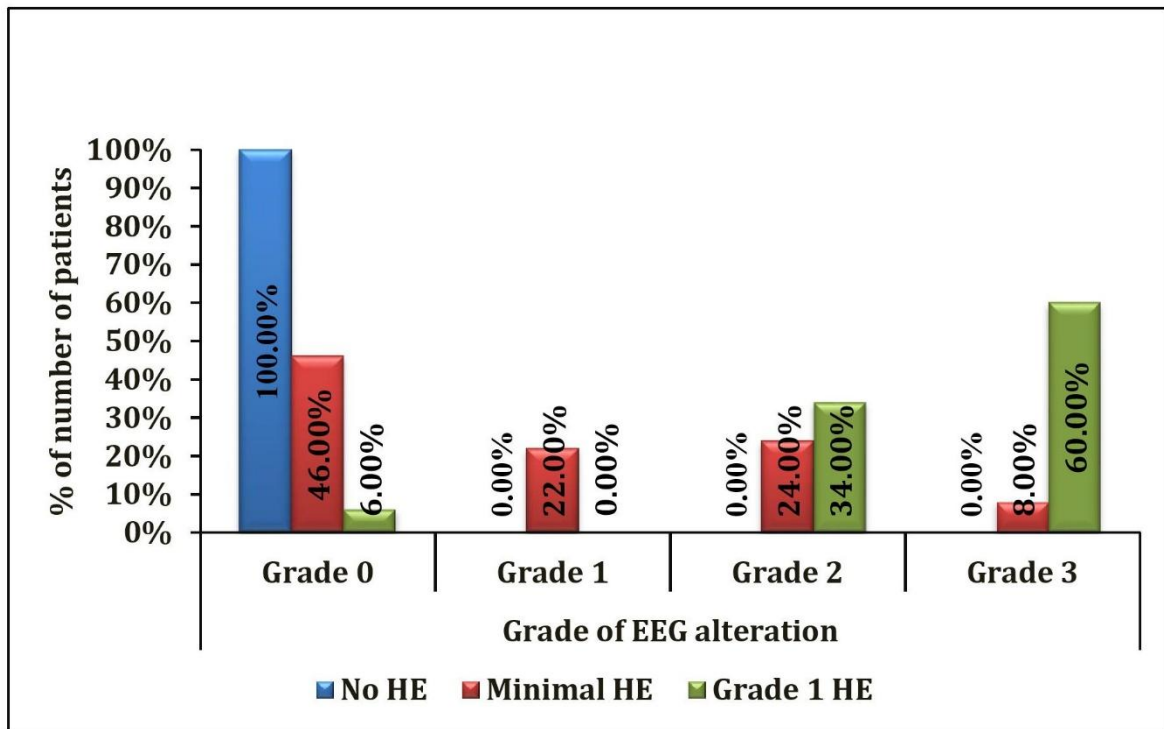


## Supplementary-material



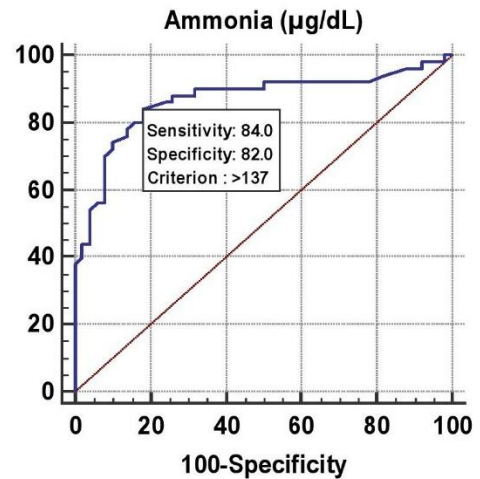
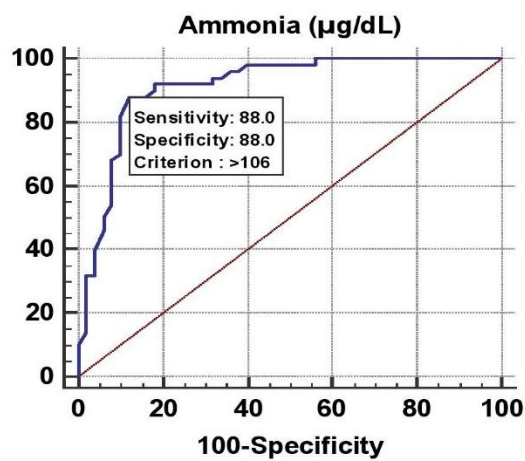
**Supplementary Figure 1 Comparison of myoinositol peaks in no HE, MHE and grade 1 HE. (A); Comparison of choline and glutamine peaks in no HE, MHE and grade 1 HE (B).**

HE - Hepatic Encephalopathy; MHE - Minimal Hepatic Encephalopathy



**Supplementary Figure 2 Comparison of grades of EEG in no HE, MHE and grade 1 HE.**

EEG - Electroencephalogram; HE - Hepatic Encephalopathy; MHE - Minimal Hepatic Encephalopathy



**Supplementary Figure 3 ROC curves for serum ammonia predicting MHE (left - AUROC -0.914) and grade 1 HE (right - AUROC - 0.867)**

AUROC: Area under the Receiver Operating Characteristic; HE - Hepatic Encephalopathy; MHE - Minimal Hepatic Encephalopathy; ROC: Receiver Operating Characteristic;

