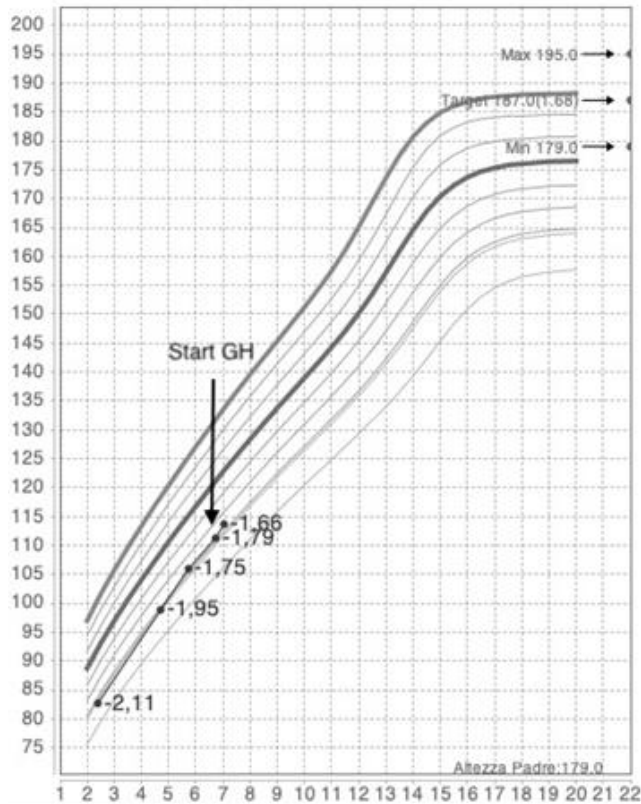
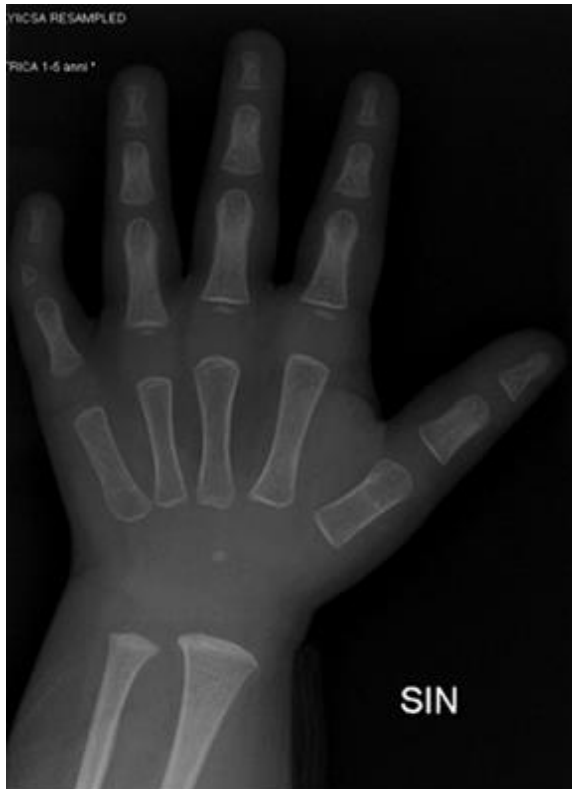

Supplementary material



Supplementary Figure 1 WHO growth chart 0-24 mo for length (1A), weight (1B), occipital-frontal circumference (1C) and SIEDP growth chart 2-18 years (1D).



Supplementary Figure 2 Bone x ray performed at 3 years of age, was correspondent to 3 mo of age for the carpus and 12-16 mo for the phalanges in the presence of suspected malformation of the intermediate phalanx of the fifth finger.