

Dear Editors and Reviewer,

Thank you for your letter and for the comments concerning our manuscript entitled "Mixed neuroendocrine-nonneuroendocrine neoplasm of the ampulla: Four case reports and a literature review" (ID: 70045). Those comments are all valuable and very helpful for revising and improving our paper. We have studied comments carefully and have made corrections which we hope meet with approval.

With best regards,

Yours sincerely,

Yang Wang

Responds to the reviewer's and editorial office's comments:

Reviewer #1

1.Comment: This is a valuable article that summarizes the clinical experience of four rare cases of mixed neuroendocrine-nonneuroendocrine neoplasm of the ampulla. However, it has been shown that the prognosis is poor and preoperative diagnosis is difficult. Therefore, the authors should describe the significance of this four-case report, compared to the previously reported 16 cases.

Response: Thank you very much for your comments. This issue that reviewer raised is very critical and worth considering, we described it in the Discussion section of the article:

At present, the best treatment for MiNEN is not clear. It has been reported that for MiNEN without distant metastases, radical surgery can be the first choice for treatment, and palliative chemotherapy can be selected when the patient has distant metastases. Regarding chemotherapy, the treatment target of MiNEN should be mainly toward the more aggressive tumor components. If the neuroendocrine components of MiNEN are well differentiated and the malignant behavior is benign or low-grade, then chemotherapy should focus on the more aggressive exocrine components. In contrast, in patients with neuroendocrine cancer, the neuroendocrine cancer will become the main target for treatment. Among the reported cases of MiNEN in the ampulla, most cases undergo surgical radical resection (pancreaticoduodenectomy). Postoperative chemotherapy regimens are different, such as oxaliplatin-based combination chemotherapy and S-1, and chemotherapy for NEC components is usually recommended [2,5]. Among the 3 patients undergoing chemotherapy in this study, the regimen was different from the previously reported regimen. After the tumor recurrence was observed in these patients, they were treated with chemotherapeutic drugs, and the reduction of metastases was observed, suggesting that it may be effective. Regarding the regimen and efficacy of chemotherapy, further research is needed in the future. We report 4 cases of MiNEN in the ampulla, summarize the clinical features and treatment of these cases, help to better understand the disease, and provide references for further

research on the disease.

[2] Yoshimachi S, Ohtsuka H, Aoki T, Miura T, Ariake K, Masuda K, Ishida M, Mizuma M, Hayashi H, Nakagawa K, Morikawa T, Motoi F, Kanno A, Masamune A, Fujishima F, Sasano H, Kamei T, Naitoh T, Unno M. Mixed adenoneuroendocrine carcinoma of the ampulla of Vater: a case report and literature review. Clin J Gastroenterol 2020; 13(1): 37-45 [PMID: 31342462 DOI: 10.1007/s12328-019-01009-2]

[5] Li X, Li D, Sun X, Lv G. Mixed adenoneuroendocrine carcinoma (MANEC) of the ampulla of Vater in a Chinese patient: A case report. J Int Med Res 2020; 48(8): 300060520947918 [PMID: 32833541 DOI: 10.1177/0300060520947918]

2.Comment: The description that “adjuvant chemotherapy can improve the prognosis” in conclusion is inappropriate because none of the four cases suggest that adjuvant chemotherapy may be effective.

Response: Thank you for your comments. According to your opinion, the conclusion section in the Abstract has been revised as follows:
Mixed neuroendocrine-non-neuroendocrine tumors of the ampulla are extremely rare, lacking typical clinical symptoms and imaging features, and are usually diagnosed after postoperative histopathological and immunohistochemical examinations. **The main treatment is radical surgical resection, which can be combined with chemotherapy. The best method of diagnosis and treatment needs further research.**

Reviewer #2

1.Comment: regarding Abstract: yes it summarize work, mortality needs to be written in better format.

Response: Thank you very much for your comments. According to your opinion, mortality in the abstract has been revised as follows:
Four cases were followed up: **one patient developed severe complications after the operation, his condition deteriorated, and he survived for 1 month. In the other 3 patients, tumor recurrence was observed during follow-up, and 2 of them survived for 29 months and 22 months respectively. One case survived and is still being followed up.**

2.Comment: if possible include histopathology picture with illustration.

Response: Thank you very much for your comments. According to your opinion, We have added histopathology and immunohistochemistry images.

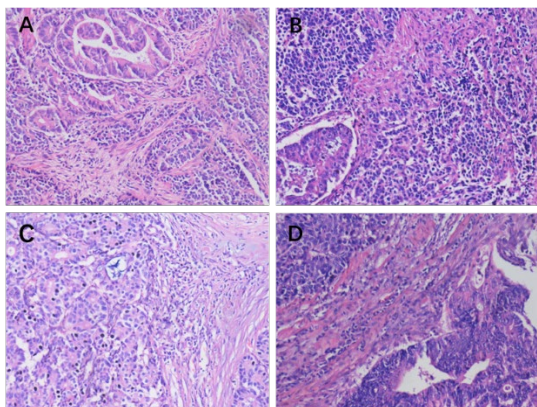


Figure3: Light microscope images of hematoxylin-eosin stained lesion sections of 4 patients. Original magnification: $\times 200$.

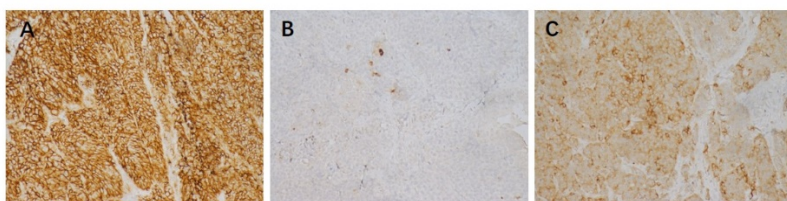


Figure4: Light microscope image with immunohistochemical staining. A:CD56+;B:CgA+;C:Syn+. Original magnification: $\times 200$.

Science editor and Company editor-in-chief:

1.Scientific quality: The manuscript describes a case report of the mixed neuroendocrine-nonneuroendocrine neoplasm of the ampulla. The topic is within the scope of the WJCC. (1) Classification: Grade B and Grade C; (2) Summary of the Peer-Review Report: This is a valuable article that summarizes the clinical experience of four rare cases of mixed neuroendocrine-nonneuroendocrine neoplasm of the ampulla. The questions raised by the reviewers should be answered; (3) Format: There are 2 tables and 2 figures; (4) References: A total of 13 references are cited, including 6 references published in the last 3 years; (5) Self-cited references: There is no self-cited reference; and (6) References recommendations: The authors have the right to refuse to cite improper references recommended by the peer reviewer(s), especially references published by the peer reviewer(s) him/herself (themselves). If the authors find the peer reviewer(s) request for the authors to cite improper references published by him/herself (themselves), please send the peer reviewer's ID number to editorialoffice@wjgnet.com. The Editorial Office will close and remove the peer reviewer from the F6Publishing system immediately. 2 Language evaluation: Classification: Two Grades B. A language editing certificate issued by AJE was provided. 3 Academic norms and rules: The authors provided the

written informed consent. No academic misconduct was found in the Bing search. 4 Supplementary comments: This is an unsolicited manuscript. The study was supported by The First Affiliated Hospital of Wannan Medical College. The topic has not previously been published in the WJCC.

1.Comment: The “Author Contributions” section is missing. Please provide the author contributions.

Response: Thank you very much for your comments. According to your opinion, the “Author Contributions” section has been added to the revision manuscript.

2.Comment: The authors did not provide the approved grant application form(s). Please upload the approved grant application form(s) or funding agency copy of any approval document(s).

Response: Thank you very much for your comments. According to your opinion, We have uploaded funding agency copy of approval document.

3.Comment: The authors did not provide original pictures. Please provide the original figure documents. Please prepare and arrange the figures using PowerPoint to ensure that all graphs or arrows or text portions can be reprocessed by the editor.

Response: Thank you very much for your comments. We have reviewed the latest journal standards and edited the original pictures of Figures 1 to 4 in PowerPoint as required, ensuring that each image, each arrow and each text can be reworked by the editor. Figure 1 to 4 have been uploaded. If there is anything wrong, please inform us in time. Thanks again for your comments.