

# World Journal of *Gastrointestinal Surgery*

*World J Gastrointest Surg* 2023 January 27; 15(1): 1-120



**OPINION REVIEW**

- 1 Hereditary polyposis syndromes remain a challenging disease entity: Old dilemmas and new insights  
*Pachler FR, Byrjalsen A, Karstensen JG, Jelsig AM*

**MINIREVIEWS**

- 9 Application of ablative therapy for intrahepatic recurrent hepatocellular carcinoma following hepatectomy  
*Cong R, Ma XH, Wang S, Feng B, Cai W, Chen ZW, Zhao XM*
- 19 Postoperative adjuvant therapy for hepatocellular carcinoma with microvascular invasion  
*Li J, Yang F, Li J, Huang ZY, Cheng Q, Zhang EL*

**ORIGINAL ARTICLE****Retrospective Cohort Study**

- 32 Prognostic effect of excessive chemotherapy cycles for stage II and III gastric cancer patients after D2 + gastrectomy  
*Li YF, Zhang WB, Gao YY*

**Retrospective Study**

- 49 Development and validation of a novel nomogram for predicting overall survival in gastric cancer based on inflammatory markers  
*Luo PQ, Song ED, Liu F, Rankine AN, Zhang LX, Wei ZJ, Han WX, Xu AM*
- 60 New perspectives on robotic pancreaticoduodenectomy: An analysis of the National Cancer Database  
*Kalabin A, Mani VR, Kruse RL, Schlesselman C, Li KY, Staveley-O'Carroll KF, Kimchi ET*
- 72 Impact of body mass index in elderly patients treated with laparoscopic liver resection for hepatocellular carcinoma  
*Conticchio M, Inchingolo R, Delvecchio A, Ratti F, Gelli M, Anelli MF, Laurent A, Vitali GC, Magistri P, Assirati G, Felli E, Wakabayashi T, Pessaux P, Piardi T, di Benedetto F, de'Angelis N, Briceño J, Rampoldi A, Adam R, Cherqui D, Aldrighetti LA, Memeo R*
- 82 Effects of postoperative use of proton pump inhibitors on gastrointestinal bleeding after endoscopic variceal treatment during hospitalization  
*Zhang YY, Wang L, Shao XD, Zhang YG, Ma SZ, Peng MY, Xu SX, Yin Y, Guo XZ, Qi XS*
- 94 Associate factors for endoscopic submucosal dissection operation time and postoperative delayed hemorrhage of early gastric cancer  
*Cai RS, Yang WZ, Cui GR*

**Clinical Trials Study**

- 105** Short-term efficacy assessment of transarterial chemoembolization combined with radioactive iodine therapy in primary hepatocellular carcinoma

*Wang L, Huang K, Zhang Y, Wu YF, Yue ZD, Fan ZH, Liu FQ, Li YW, Dong J*

**CASE REPORT**

- 114** Intestinal erosion caused by meshoma displacement: A case report

*Wu JF, Chen J, Hong F*

**ABOUT COVER**

Editorial Board Member of *World Journal of Gastrointestinal Surgery*, Abdul-Wahed Meshikhes, MBChB (Dublin), FRCS (Gen Surg), Senior Consultant Surgeon, Department of Surgery, Alzahra General Hospital, Qatif 31911, Saudi Arabia. meshikhes@gmail.com

**AIMS AND SCOPE**

The primary aim of *World Journal of Gastrointestinal Surgery* (*WJGS, World J Gastrointest Surg*) is to provide scholars and readers from various fields of gastrointestinal surgery with a platform to publish high-quality basic and clinical research articles and communicate their research findings online.

*WJGS* mainly publishes articles reporting research results and findings obtained in the field of gastrointestinal surgery and covering a wide range of topics including biliary tract surgical procedures, biliopancreatic diversion, colectomy, esophagectomy, esophagostomy, pancreas transplantation, and pancreatectomy, *etc.*

**INDEXING/ABSTRACTING**

The *WJGS* is now abstracted and indexed in Science Citation Index Expanded (SCIE, also known as SciSearch®), Current Contents/Clinical Medicine, Journal Citation Reports/Science Edition, PubMed, PubMed Central, Reference Citation Analysis, China National Knowledge Infrastructure, China Science and Technology Journal Database, and Superstar Journals Database. The 2022 Edition of Journal Citation Reports® cites the 2021 impact factor (IF) for *WJGS* as 2.505; IF without journal self cites: 2.473; 5-year IF: 3.099; Journal Citation Indicator: 0.49; Ranking: 104 among 211 journals in surgery; Quartile category: Q2; Ranking: 81 among 93 journals in gastroenterology and hepatology; and Quartile category: Q4.

**RESPONSIBLE EDITORS FOR THIS ISSUE**

Production Editor: Rui-Rui Wu; Production Department Director: Xiang Li; Editorial Office Director: Jia-Ru Fan.

**NAME OF JOURNAL**

*World Journal of Gastrointestinal Surgery*

**ISSN**

ISSN 1948-9366 (online)

**LAUNCH DATE**

November 30, 2009

**FREQUENCY**

Monthly

**EDITORS-IN-CHIEF**

Peter Schemmer

**EDITORIAL BOARD MEMBERS**

<https://www.wjgnet.com/1948-9366/editorialboard.htm>

**PUBLICATION DATE**

January 27, 2023

**COPYRIGHT**

© 2023 Baishideng Publishing Group Inc

**INSTRUCTIONS TO AUTHORS**

<https://www.wjgnet.com/bpg/gerinfo/204>

**GUIDELINES FOR ETHICS DOCUMENTS**

<https://www.wjgnet.com/bpg/GerInfo/287>

**GUIDELINES FOR NON-NATIVE SPEAKERS OF ENGLISH**

<https://www.wjgnet.com/bpg/gerinfo/240>

**PUBLICATION ETHICS**

<https://www.wjgnet.com/bpg/GerInfo/288>

**PUBLICATION MISCONDUCT**

<https://www.wjgnet.com/bpg/gerinfo/208>

**ARTICLE PROCESSING CHARGE**

<https://www.wjgnet.com/bpg/gerinfo/242>

**STEPS FOR SUBMITTING MANUSCRIPTS**

<https://www.wjgnet.com/bpg/GerInfo/239>

**ONLINE SUBMISSION**

<https://www.f6publishing.com>

## Retrospective Study

# Effects of postoperative use of proton pump inhibitors on gastrointestinal bleeding after endoscopic variceal treatment during hospitalization

Yi-Yan Zhang, Le Wang, Xiao-Dong Shao, Yong-Guo Zhang, Shao-Ze Ma, Meng-Yuan Peng, Shi-Xue Xu, Yue Yin, Xiao-Zhong Guo, Xing-Shun Qi

**Specialty type:** Gastroenterology and hepatology

**Provenance and peer review:**

Unsolicited article; Externally peer reviewed.

**Peer-review model:** Single blind

**Peer-review report's scientific quality classification**

Grade A (Excellent): 0  
Grade B (Very good): 0  
Grade C (Good): C, C  
Grade D (Fair): 0  
Grade E (Poor): 0

**P-Reviewer:** Delsa H, Morocco; Wu R, China

**Received:** July 25, 2022

**Peer-review started:** July 25, 2022

**First decision:** September 26, 2022

**Revised:** October 11, 2022

**Accepted:** November 7, 2022

**Article in press:** November 7, 2022

**Published online:** January 27, 2023



Yi-Yan Zhang, Le Wang, Xiao-Dong Shao, Yong-Guo Zhang, Shao-Ze Ma, Meng-Yuan Peng, Shi-Xue Xu, Yue Yin, Xiao-Zhong Guo, Xing-Shun Qi, Liver Cirrhosis Study Group, Department of Gastroenterology, General Hospital of Northern Theater Command, Shenyang 110840, Liaoning Province, China

Yi-Yan Zhang, Le Wang, Shi-Xue Xu, Yue Yin, Postgraduate College, China Medical University, Shenyang 110122, Liaoning Province, China

Shao-Ze Ma, Postgraduate College, Dalian Medical University, Dalian 116044, Liaoning Province, China

**Corresponding author:** Xing-Shun Qi, MD, PhD, Associate Professor, Liver Cirrhosis Study Group, Department of Gastroenterology, General Hospital of Northern Theater Command, No. 83 Wenhua Road, Shenyang 110840, Liaoning Province, China. [xingshunqi@126.com](mailto:xingshunqi@126.com)

## Abstract

### BACKGROUND

Endoscopic variceal treatment (EVT) is recommended as the mainstay choice for the management of high-risk gastroesophageal varices and acute variceal bleeding in liver cirrhosis. Proton pump inhibitors (PPIs) are widely used for various gastric acid-related diseases. However, the effects of PPIs on the development of post-EVT complications, especially gastrointestinal bleeding (GIB), remain controversial.

### AIM

To evaluate the effects of postoperative use of PPIs on post-EVT complications in patients with liver cirrhosis during hospitalization.

### METHODS

Patients with a diagnosis of liver cirrhosis who were admitted to the Department of Gastroenterology of the General Hospital of Northern Theater Command, treated by an attending physician between January 2016 and June 2020 and underwent EVT during their hospitalization were included. Logistic regression analyses were performed to explore the effects of postoperative use of PPIs on the development of post-EVT complications during hospitalization. Odds ratios (ORs)

with 95% confidence intervals (CIs) were calculated.

## RESULTS

A total of 143 patients were included. The incidence of post-EVT GIB and other post-EVT complications was 4.90% and 46.85%, respectively. In the overall analyses, postoperative use of PPIs did not significantly reduce the risk of post-EVT GIB (OR = 0.525, 95%CI = 0.113-2.438,  $P = 0.411$ ) or other post-EVT complications (OR = 0.804, 95%CI = 0.413-1.565,  $P = 0.522$ ). In the subgroup analyses according to the enrollment period, type and route of PPIs after the index EVT, use of PPIs before the index EVT, use of vasoactive drugs after the index EVT, indication of EVT (prophylactic and therapeutic), and presence of portal venous system thrombosis, ascites, and hepatocellular carcinoma, the effects of postoperative use of PPIs on the risk of post-EVT GIB or other post-EVT complications remain not statistically significant.

## CONCLUSION

Routine use of PPIs after EVT should not be recommended in patients with liver cirrhosis for the prevention of post-EVT complications during hospitalization.

**Key Words:** Endoscopic variceal treatment; Gastrointestinal bleeding; Proton pump inhibitors; Complications; Liver cirrhosis; Acute variceal bleeding

©The Author(s) 2023. Published by Baishideng Publishing Group Inc. All rights reserved.

**Core Tip:** The role of proton pump inhibitors (PPIs) in the management of post-endoscopic variceal treatment (EVT) complications remains controversial. We conducted a retrospective study to explore the effects of postoperative use of PPIs on post-EVT gastrointestinal bleeding (GIB) and other post-EVT complications in patients with liver cirrhosis during hospitalization. We found that postoperative use of PPIs was not beneficial for reducing the development of post-EVT GIB and other post-EVT complications during hospitalization. Collectively, routine use of PPIs after EVT during hospitalization may not be recommended, and their indications should be carefully evaluated.

**Citation:** Zhang YY, Wang L, Shao XD, Zhang YG, Ma SZ, Peng MY, Xu SX, Yin Y, Guo XZ, Qi XS. Effects of postoperative use of proton pump inhibitors on gastrointestinal bleeding after endoscopic variceal treatment during hospitalization. *World J Gastrointest Surg* 2023; 15(1): 82-93

**URL:** <https://www.wjgnet.com/1948-9366/full/v15/i1/82.htm>

**DOI:** <https://dx.doi.org/10.4240/wjgs.v15.i1.82>

## INTRODUCTION

Acute variceal bleeding (AVB) is a serious complication of liver cirrhosis, indicating the disease progression and development of hepatic decompensation[1,2]. Endoscopic variceal treatment (EVT) is recommended as the major choice for the prevention and treatment of AVB[3,4]. However, the incidence of post-EVT gastrointestinal bleeding (GIB) ranges from 8% to 25%[5,6], which is mainly due to recurrent varices and post-EVT ulcers[7]. In detail, about 4% of patients develop recurrent variceal bleeding after EVT, and 3-25% of patients develop post-EVT ulcer-related GIB[2,8]. Notably, the mortality of GIB secondary to post-EVT ulcer is as high as 52%[2].

Considering the benefits of proton pump inhibitors (PPIs) on the prevention of post-EVT GIB[9,10], the American Society for Gastrointestinal Endoscopy recommends the use of PPIs after endoscopic variceal ligation (EVL) to decrease the rate of ligation-induced ulcer[11] and the Chinese Medical Association also recommends the postoperative use of PPIs to improve the hemostasis success and reduce the rates of ulcer and recent post-EVT GIB[12]. Indeed, the clinicians often use PPIs after EVT in clinical practice[13]. However, the British Society of Gastroenterology states that PPIs are only recommended in the presence of peptic ulcers[14]. Additionally, the Baveno VII consensus also states that patients who used PPIs before EVT should discontinue their use immediately after EVT unless they are strictly indicated[3]. Recent evidence also suggests that the use of PPIs in patients with liver cirrhosis may increase the risk of hepatic encephalopathy and spontaneous bacterial peritonitis[15]. Therefore, whether the routine use of PPIs after EVT is beneficial remains controversial. For this reason, we conducted a retrospective study to evaluate the effects of postoperative use of PPIs on post-EVT GIB and other post-EVT complications in patients with liver cirrhosis during hospitalization.

## MATERIALS AND METHODS

### Study design

This study was approved by the Medical Ethical Committee of the General Hospital of Northern Theater Command with an approval number [Y (2022) 072] and was performed according to the principles of Declaration of Helsinki. The requirement for patients' informed consent for this study was waived due to its retrospective nature. In this study, we retrospectively reviewed the medical records of 911 patients who were consecutively admitted to the Department of Gastroenterology of the General Hospital of Northern Theater Command between January 2016 and June 2020 and treated by an attending physician (XQ)[16-20]. We further selected patients who were diagnosed with liver cirrhosis and underwent EVT during their hospitalization. Exclusion criteria were: 1) patients who developed GIB or were discharged within 24 h after the index EVT; and 2) patients who started the use of PPIs beyond 24 h after the index EVT. Repeated admissions, malignancies, and other comorbidities were not excluded.

### Data extraction

By reviewing electronic medical records, demographic data (*i.e.*, age and gender), etiologies of liver cirrhosis, laboratory tests (*i.e.*, white blood cell, hemoglobin, platelet count, total bilirubin, albumin, alanine aminotransferase, serum creatinine, sodium, and international normalized ratio), and other complications of liver cirrhosis [*i.e.*, ascites, jaundice, hepatic encephalopathy, portal venous system thrombosis (PVST)[17], and hepatocellular carcinoma (HCC)] at admission were collected. Model for end-stage liver disease (MELD) score, Child-Pugh score, and Child-Pugh class at admission were calculated[21].

### EVT

All EVT procedures were performed by the same experienced endoscopist (XS) at our department[22, 23]. EVL and endoscopic cyanoacrylate glue injection (ECGI) were the first-line choices for the management of esophageal and gastric varices, respectively. Endoscopic injection sclerotherapy (EIS) was performed, if EVL was technically difficult, where active massive bleeding impaired visualization or local scar tissue prevented esophageal varices from being aspirated into the cap to achieve ligation. Indication (*i.e.*, treatment of AVB and primary and secondary prophylaxis of variceal bleeding) and type (*i.e.*, EVL, ECGI and EIS) of EVT and endoscopic findings [*i.e.*, grade of esophageal varices (EVs), red sign of EVs, and active bleeding under endoscopy] were reviewed. The use of PPIs before the index EVT and vasoactive drugs (*i.e.*, octreotide, somatostatin, and terlipressin) after the index EVT were also reviewed. If a patient underwent two or more EVT procedures during the same hospitalization, only the data before the second EVT procedure would be collected.

### PPIs after the index EVT

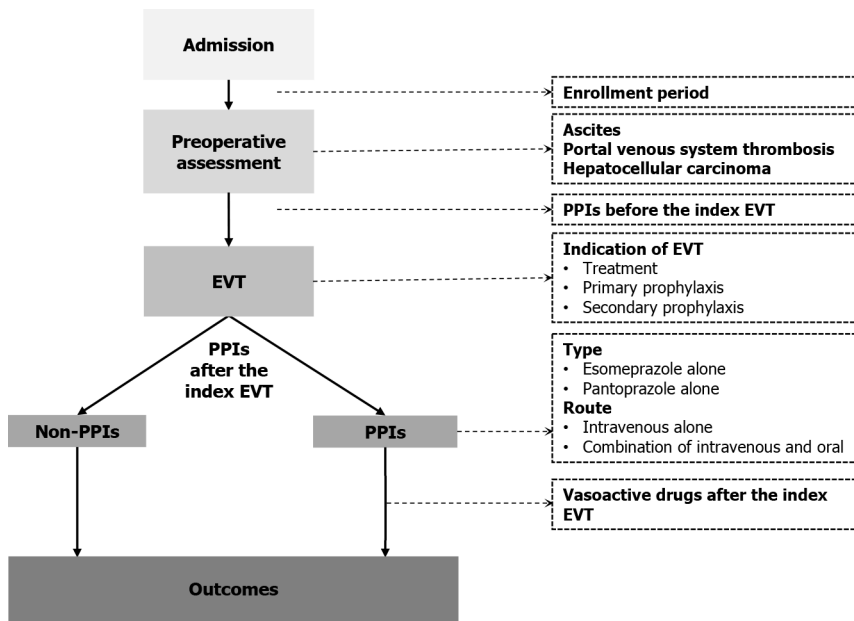
Postoperative PPIs were routinely used in all patients who underwent EVT before January 2018. Since then, this attending physician has systematically reviewed the evidence and questioned the clinical significance of use of PPIs following EVT[10]. Thus, postoperative PPIs would be given on demand if a patient was diagnosed with peptic ulcers, esophageal, gastric, and/or duodenal mucosal erosions, or white nipple signs on endoscopy, developed active variceal bleeding during EVT procedures, or complained of acid-related upper gastrointestinal symptoms (*i.e.*, heartburn and acid regurgitation). Enrollment period, type (*i.e.*, esomeprazole and pantoprazole), route (*i.e.*, intravenous and oral), dosage (*i.e.*, 40 mg once daily, 40 mg twice daily, and 80 mg twice daily), date of starting and discontinuation, and duration of PPIs after the index EVT were reviewed. These data were extracted until post-EVT GIB, the second EVT procedure, or discharge, whichever came first.

### Grouping

Patients were divided into PPIs and non-PPIs groups. The PPIs group was defined as patients who had started on PPIs within 24 h after the index EVT for at least one day before post-EVT GIB, the second EVT procedure, or discharge, whichever came first. The non-PPIs group was defined as patients who had not received PPIs after the index EVT until post-EVT GIB, the second EVT procedure, or discharge, whichever came first (Figure 1).

### Outcomes

The primary outcome was the development of post-EVT GIB during hospitalization. Post-EVT GIB was defined as the presence of hematemesis, and/or melena, and/or hematochezia, and/or firm clinical or laboratory evidence of acute blood loss from the gastrointestinal tract after the index EVT[24]. Other post-EVT complications included retrosternal pain/discomfort, nausea/vomiting, heartburn/acid regurgitation, fever, diarrhea, and abdominal pain.



DOI: 10.4240/wjgs.v15.i1.82 Copyright ©The Author(s) 2023.

Figure 1 A schematic chart of study design. EVT: Endoscopic variceal treatment; PPIs: Proton pump inhibitors.

### Statistical analyses

All statistical analyses were performed using the IBM SPSS 20.0 (IBM Corp, Armonk, NY, USA). Continuous variables were expressed as median (range) and mean  $\pm$  standard deviation, and categorical variables were expressed as frequency (percentage). The non-parametric Mann-Whitney U test was used to compare continuous variables between PPIs and non-PPIs groups, and the Chi-square test and Fisher's exact test were used to compare categorical variables between the two groups. Logistic regression analyses were performed to explore the impact of postoperative PPIs on post-EVT GIB and other post-EVT complications during hospitalization. Odds ratios (ORs) with 95% confidence intervals (CIs) were calculated. Subgroup analyses were performed according to the enrollment period, type and route of PPIs after the index EVT, use of PPIs before the index EVT, use of vasoactive drugs after the index EVT, indication of EVT, and presence of PVST, ascites, and HCC (Figure 1). A two-sided  $P < 0.05$  was considered statistically significant.

## RESULTS

### Patient characteristics

A total of 148 patients with cirrhosis underwent EVT during their hospitalization. Finally, 143 patients were included (Figure 2). Of them, 83 were in the PPIs group and 60 in the non-PPIs group. The median duration of PPIs administration was 6 (1-13) d. The median hospital stay after EVT was 6 (2-16) d. Patient characteristics are shown in Table 1. Hepatitis B virus infection alone (36.36%) was the most common etiology of liver cirrhosis followed by alcohol abuse alone (23.08%). The median MELD score and Child-Pugh score were 10.24 and 6.00, respectively. Eighty (55.94%), 14 (9.79%), 6 (4.20%), 41 (28.67%), 1 (0.70%), and 1 (0.70%) patient were treated with EVL alone, ECGI alone, EIS alone, EVL combined with ECGI, EIS combined with ECGI, and EVL combined with ECGI and EIS, respectively (Table 2).

### Overall analyses

Seven (4.90%) patients developed post-EVT GIB, including three in the PPIs group and four in the non-PPIs group. The median interval between the index EVT and post-EVT GIB was 4 (2-7) d. Only one of them underwent endoscopy and it was found that the source of post-EVT GIB was a post-EVT ulcer. All of them were administered immediately with intravenous vasoactive drugs for the management of post-EVT GIB and two received blood transfusions. Other post-EVT complications were recorded in 67 (46.85%) patients. Logistic regression analyses showed that postoperative use of PPIs was not significantly associated with the risk of post-EVT GIB (OR = 0.525, 95%CI = 0.113-2.438,  $P = 0.411$ ) (Figure 3) or other post-EVT complications (OR = 0.804, 95%CI = 0.413-1.565,  $P = 0.522$ ) (Figure 4).



Table 1 Comparison of baseline characteristics between proton pump inhibitors and non-proton pump inhibitors groups

Variables	Overall		PPIs		Non-PPIs		P value
	No.Pts	Median (range), mean $\pm$ SD, or frequency (percentage)	No.Pts	Median (range), mean $\pm$ SD, or frequency (percentage)	No.Pts	Median (range), mean $\pm$ SD, or frequency (percentage)	
Age (yr)	143	56.00 (28.00-88.00) 55.88 $\pm$ 11.77	83	58.00 (30.00-88.00) 57.40 $\pm$ 11.86	60	54.50 (28.00-79.00) 53.78 $\pm$ 11.41	0.089
Male	143	104 (72.73%)	83	61 (73.49%)	60	43 (71.67%)	0.809
HBV infection alone	143	52 (36.36%)	83	31 (37.35%)	60	21 (35.00%)	0.773
HCV infection alone	143	11 (7.69%)	83	4 (4.82%)	60	7 (11.67%)	0.202
Alcohol abuse alone	143	33 (23.08%)	83	22 (26.51%)	60	11 (18.33%)	0.252
White blood cell ( $10^9$ /L)	141	3.50 (0.80-19.60) 3.99 $\pm$ 2.60	81	3.60 (0.80-19.60) 4.15 $\pm$ 2.74	60	3.45 (1.00-17.40) 3.78 $\pm$ 2.40	0.381
Hemoglobin (g/L)	141	89.00 (48.00-155.00) 93.21 $\pm$ 26.69	81	83.00 (48.00-155.00) 90.15 $\pm$ 27.48	60	97.50 (57.00-149.00) 97.35 $\pm$ 25.23	0.081
Platelet count ( $10^9$ /L)	141	75.00 (15.00-470.00) 92.58 $\pm$ 66.85	81	76.00 (22.00-268.00) 87.80 $\pm$ 52.28	60	71.00 (15.00-470.00) 99.03 $\pm$ 82.61	0.970
Total bilirubin ( $\mu$ mol/L)	132	20.40 (5.60-106.10) 25.67 $\pm$ 18.53	74	24.35 (7.00-106.10) 28.72 $\pm$ 19.92	58	16.30 (5.60-96.60) 21.78 $\pm$ 15.91	0.006
Albumin (g/L)	133	33.40 (20.50-48.70) 33.21 $\pm$ 5.91	75	31.80 (20.50-45.70) 32.41 $\pm$ 5.48	58	35.30 (21.80-48.70) 34.26 $\pm$ 6.32	0.048
Alanine aminotransferase (U/L)	132	20.92 (4.47-1465.50) 38.52 $\pm$ 127.21	74	19.40 (7.57-1465.50) 43.85 $\pm$ 168.05	58	23.62 (4.47-185.02) 31.72 $\pm$ 30.61	0.228
Serum creatinine ( $\mu$ mol/L)	135	64.93 (34.51-501.52) 70.77 $\pm$ 42.31	76	64.52 (34.51-117.66) 66.97 $\pm$ 18.75	59	65.21 (36.39-501.52) 75.68 $\pm$ 60.31	0.591
Sodium (mmol/L)	134	138.85 (124.00-151.00) 138.55 $\pm$ 3.38	75	138.70 (124.00-151.00) 138.49 $\pm$ 3.65	59	139.00 (133.10-147.70) 138.64 $\pm$ 3.04	0.798
International normalized ratio	135	1.29 (0.90-2.55) 1.36 $\pm$ 0.26	75	1.29 (0.90-2.55) 1.37 $\pm$ 0.27	60	1.31 (0.92-2.04) 1.35 $\pm$ 0.25	0.685
MELD score	129	10.24 (6.65-30.03) 11.44 $\pm$ 3.78	71	10.51 (6.65-30.03) 11.75 $\pm$ 4.03	58	9.93 (7.14-22.06) 11.05 $\pm$ 3.45	0.214
Child-Pugh score	130	6.00 (5.00-12.00) 6.76 $\pm$ 1.59	72	7.00 (5.00-12.00) 6.89 $\pm$ 1.68	58	6.00 (5.00-10.00) 6.60 $\pm$ 1.47	0.388
Child-Pugh class							
A		66 (50.77%)		35 (48.61%)		31 (53.45%)	
B	130	57 (43.85%)	72	32 (44.44%)	58	25 (43.10%)	0.709
C		7 (5.38%)		5 (6.94%)		2 (3.45%)	
Ascites	143	75 (52.45%)	83	45 (54.22%)	60	30 (50.00%)	0.618
Jaundice	132	12 (9.09%)	74	9 (12.16%)	58	3 (5.17%)	0.166
Hepatic encephalopathy	143	1 (0.70%)	83	0 (0.00%)	60	1 (1.67%)	0.420

Portal venous system thrombosis	90	39 (43.33%)	55	25 (45.45%)	35	14 (40.00%)	0.611
Hepatocellular carcinoma	143	10 (6.99%)	83	6 (7.23%)	60	4 (6.67%)	1.000

PPIs: Proton pump inhibitors; No. Pts: Numbers of patients; SD: Standard deviation; HBV: Hepatitis B virus; HCV: Hepatitis C virus; MELD: Model for end-stage liver disease.

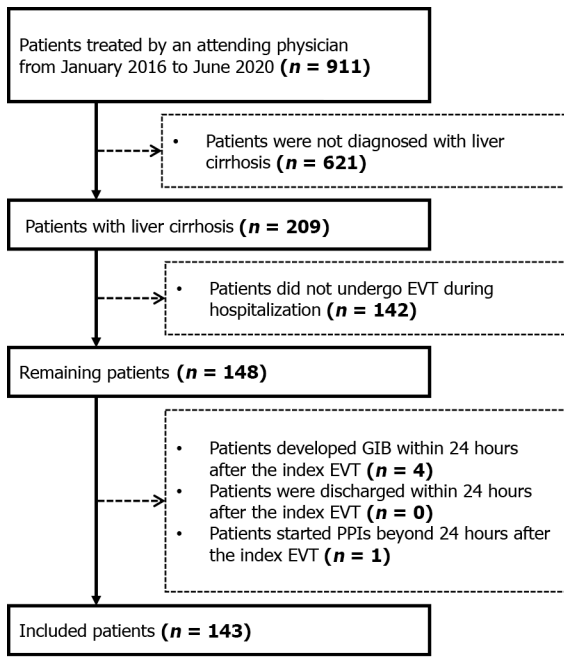
**Table 2 Comparison of endoscopic findings, treatment, and outcomes between proton pump inhibitors and non-proton pump inhibitors groups**

Variables	Overall		PPIs		Non-PPIs		P value
	No.Pts	Frequency (percentage)	No.Pts	Frequency (percentage)	No.Pts	Frequency (percentage)	
Grade of esophageal varices							
Mild		27 (19.01%)		14 (17.07%)		13 (21.67%)	
Moderate	142	35 (24.65%)	82	21 (25.61%)	60	14 (23.33%)	0.783
Severe		80 (56.34%)		47 (57.32%)		33 (55.00%)	
Red sign of esophageal varices	143	98 (68.53%)	83	57 (68.67%)	60	41 (68.33%)	0.965
Active bleeding	143	5 (3.50%)	83	5 (6.02%)	60	0 (0.00%)	0.074
Indication of EVT							
Treatment		56 (39.16%)		34 (40.96%)		22 (36.67%)	
Primary prophylaxis	143	11 (7.69%)	83	10 (12.05%)	60	1 (1.67%)	0.035
Secondary prophylaxis		76 (53.15%)		39 (46.99%)		37 (61.67%)	
Type of EVT							
EVL		80 (55.94%)		46 (55.42%)		34 (56.67%)	
ECGI		14 (9.79%)		6 (7.23%)		8 (13.33%)	
EIS	143	6 (4.20%)	83	4 (4.82%)	60	2 (3.33%)	0.799
EVL+ECGI		41 (28.67%)		25 (30.12%)		16 (26.67%)	
EIS+ECGI		1 (0.70%)		1 (1.20%)		0 (0.00%)	
EVL+ECGI+EIS		1 (0.70%)		1 (1.20%)		0 (0.00%)	
PPIs before the index EVT	143	66 (46.15%)	83	42 (50.60%)	60	24 (40.00%)	0.209
Vasoactive drugs after the index EVT	143	38 (26.57%)	83	27 (32.53%)	60	11 (18.33%)	0.058
Post-EVT GIB	143	7 (4.90%)	83	3 (3.61%)	60	4 (6.67%)	0.453
Other post-EVT complications	143	67 (46.85%)	83	37 (44.58%)	60	30 (50.00%)	0.521

PPIs: Proton pump inhibitors; No. Pts: Numbers of patients; EVT: Endoscopic variceal treatment; EVL: Endoscopic variceal ligation; ECGI: Endoscopic cyanoacrylate glue injection; EIS: Endoscopic injection sclerotherapy; GIB: Gastrointestinal bleeding.

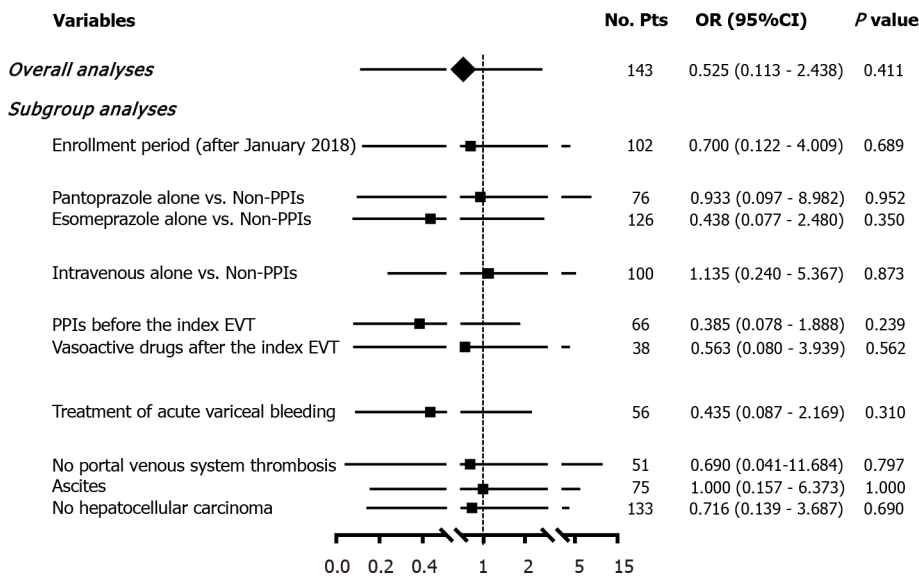
### Subgroup analyses

In all subgroup analyses according to the enrollment period, type and route of PPIs after the index EVT, use of PPIs before the index EVT, use of vasoactive drugs after the index EVT, indication of EVT, and presence of PVST, ascites, and HCC, logistic regression analyses showed that postoperative use of PPIs was not significantly associated with the risk of post-EVT GIB (Figure 3) or other post-EVT complications (Figure 4).



DOI: 10.4240/wjgs.v15.i1.82 Copyright ©The Author(s) 2023.

Figure 2 A flow chart of patients' selection. EVT: Endoscopic variceal treatment; GIB: Gastrointestinal bleeding; PPIs: Proton pump inhibitors.



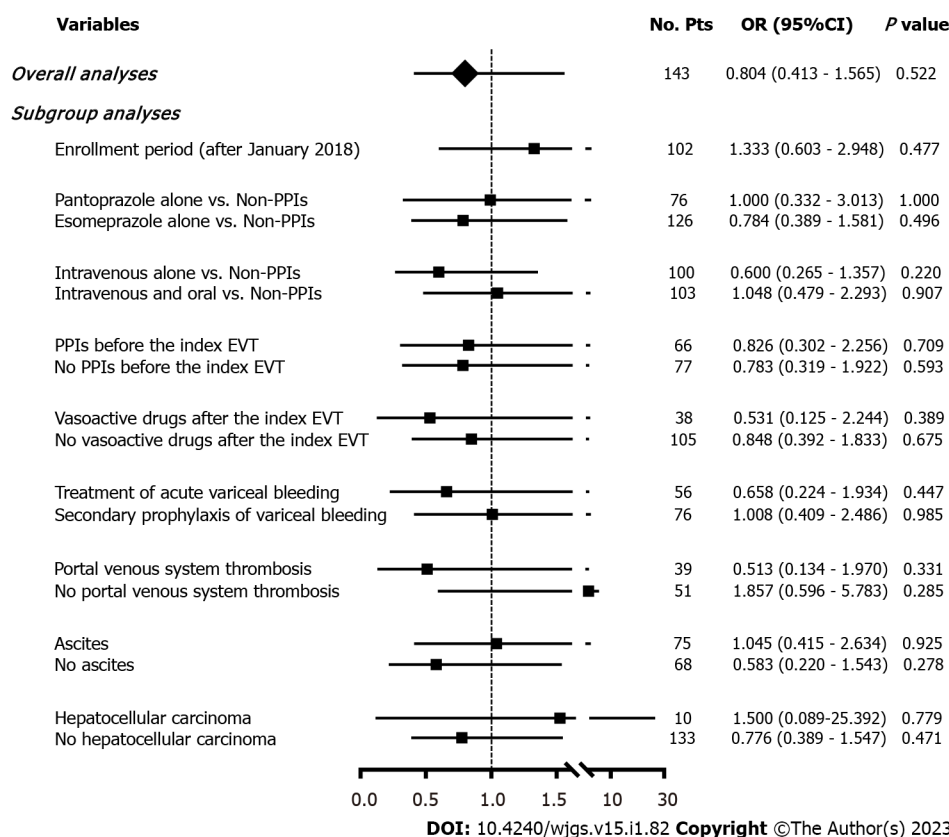
DOI: 10.4240/wjgs.v15.i1.82 Copyright ©The Author(s) 2023.

Figure 3 Forest plots showing the effects of postoperative use of proton pump inhibitors on post-EVT GIB during hospitalization. No. Pts: Numbers of patients; OR: Odds ratio; CI: Confidence interval; PPIs: Proton pump inhibitors; EVT: Endoscopic variceal treatment; GIB: Gastrointestinal bleeding.

## DISCUSSION

PPIs are one of the most commonly used drugs in the world[25]. Increasing evidence suggests that the use of PPIs may reduce the abundance and diversity of gut microbiota, leading to the growth of pathogens and the overgrowth of unhealthy species, and that it may be associated with bone fracture, clostridium difficile infection, spontaneous bacterial peritonitis, and hepatic encephalopathy[25,26]. These harms have raised serious concerns about the rational use of PPIs worldwide[27]. Therefore, clinicians should carefully consider the postoperative use of PPIs during hospitalization, and assess the optimal effective dosage and duration of PPIs to avoid their related side effects.

Our study found that postoperative use of PPIs had no significant effect on post-EVT GIB and other post-EVT complications. Our study has several advantages in terms of study design. First, all patients were diagnosed and treated by the same attending physician and all EVT procedures were also performed by the same endoscopist, which avoids heterogeneity in the management of patients. Second,



**Figure 4** Forest plots showing the effects of postoperative use of proton pump inhibitors on other post-EVT complications during hospitalization. No. Pts: Numbers of patients; OR: Odds ratio; CI: Confidence interval; PPIs: Proton pump inhibitors; EVT: Endoscopic variceal treatment.

patients who underwent prophylactic and therapeutic EVT procedures were both included. Third, subgroup analyses were comprehensively performed according to the enrollment period, type and route of PPIs after the index EVT, use of PPIs before the index EVT, use of vasoactive drugs after the index EVT, indication of EVT (prophylactic and therapeutic EVT), and presence of PVST, ascites, and HCC, which minimizes the impact of confounding factors on statistical results. Fourth, all included patients had been evaluated for at least 24 h since the index EVT, which potentially rules out the effect of technical failure on patients’ outcomes.

Post-EVT ulcer, which is one of the main causes of post-EVT GIB, is primarily due to early slippage of rubber bands, sclerosant-induced inflammatory necrosis, and tissue glue-induced caseous necrosis[7,28-31]. It has been traditionally believed that the presence of gastric acid delays ulcer healing[32]. Esophageal motility may be temporarily impaired due to nerve plexus injury after EVT, which delays gastric acid clearance and aggravates the progression of ulcers[33,34]. PPIs are potent acid inhibitors widely used for various acid-related diseases and may promote early healing of post-EVT ulcers by reducing gastric acid secretion, thereby probably decreasing the risk of post-EVT GIB[26,32,35]. In contrast, our study did not demonstrate the benefits of postoperative PPIs in reducing the development of post-EVT GIB. There are some explanations for this unexpected phenomenon. First, post-EVT ulcers are more prone to develop bleeding primarily due to persistent portal hypertension, but not gastric acid [4,31]. Second, the use of PPIs can only reduce the size of ulcers, but not the number of ulcers[36]. Notably, the size of ulcers is not associated with the risk of bleeding[36]. Third, we only observed the impact of short-term use of PPIs on the development of post-EVT GIB during hospitalization. However, post-EVT ulcer healing often requires a duration of about 2 wk[37,38].

Our previous meta-analysis showed a significant benefit of PPIs on post-EVT GIB in patients who underwent prophylactic EVT, but not therapeutic EVT[10]. However, the present study could not confirm the protective effect of postoperative use of PPIs on GIB after prophylactic EVT, because none of the patients who underwent EVT for primary or secondary prophylaxis of variceal bleeding developed post-EVT GIB. Nevertheless, it has been proposed that post-EVT ulcers are usually shallower with only superficial mucosal damage, which may heal more easily with the use of PPIs[37]. Patients who need EVT for the treatment of AVB often have a white nipple, red nipple, or mucosal erosion on endoscopy. Undoubtedly, their conditions are more severe, where the anti-acid effect of PPIs may be insufficient for the improvement of ulcer healing[4].

Except for post-EVT GIB, EVT can also cause other procedure-related complications, which are mild and reversible[3,7]. We did not find any significant effect of PPIs on the development of other post-EVT

complications. This can be explained by the fact that only a fraction of post-EVT complications, such as acid regurgitation and heartburn, are related to gastric acid[39]. By comparison, retrosternal discomfort/pain, nausea, and vomiting are mostly mechanical injuries caused by EVT, and fever may be secondary to bacterial infection[40,41]. Garg *et al*[28] also achieved similar findings, but Lo *et al*[42] showed fewer complications in patients receiving PPIs. Such a discrepancy might be related to the type of complications evaluated, endoscopic techniques, and patients' conditions.

Our study has some limitations. First, the total number of the patients included was small in this study. Second, there were a few cases of post-EVT GIB, which made our statistical analyses underpowered and increased the possibility of type II errors (*i.e.*, false-negative findings). Third, only one patient who developed post-EVT GIB underwent second-look endoscopy, because all of the six patients who developed post-EVT GIB were successfully treated with pharmacotherapy. Fourth, none died of post-EVT GIB or other causes during hospitalization, compromising further analyses regarding the impact of PPIs on death. Fifth, follow-up data were lacking to assess the 6-wk and long-term mortality.

---

## CONCLUSION

---

Our study suggested that postoperative use of PPIs could not reduce the development of post-EVT GIB and other post-EVT complications during hospitalization. Therefore, PPIs after EVT should not be routinely used during hospitalization, and their indications should be carefully evaluated.

## ARTICLE HIGHLIGHTS

### **Research background**

Endoscopic variceal treatment (EVT) is frequently used in cirrhosis with high-risk gastroesophageal varices and acute variceal bleeding. However, it is often associated with a high risk of post-EVT complications, especially postoperative gastrointestinal bleeding (GIB).

### **Research motivation**

The role of proton pump inhibitors (PPIs) after EVT remains controversial.

### **Research objectives**

To evaluate the impact of postoperative use of PPIs on post-EVT GIB and other post-EVT complications in patients with liver cirrhosis during hospitalization.

### **Research methods**

We retrospectively reviewed 911 patients who were consecutively admitted to the Department of Gastroenterology of the General Hospital of Northern Theater Command between January 2016 and June 2020 and treated by an attending physician. Logistic regression analyses were performed to explore the impact of postoperative PPIs on post-EVT GIB and other post-EVT complications during hospitalization.

### **Research results**

A total of 143 patients were included. The incidence of post-EVT GIB and other post-EVT complications was 4.90% and 46.85%, respectively. In either overall or subgroup analyses, postoperative use of PPIs did not significantly reduce the risk of post-EVT GIB or other post-EVT complications.

### **Research conclusions**

Postoperative use of PPIs was not beneficial for reducing the development of post-EVT GIB and other post-EVT complications during hospitalization.

### **Research perspectives**

PPIs after EVT should not be routinely used during hospitalization, and their indications should be carefully evaluated. Prospective studies are required to further validate the conclusions of this study.

---

## ACKNOWLEDGEMENTS

---

We are indebted to our study team, including Wen-Chun Bao, Fei-Fei Hou, Ze-Qi Guo, Jing-Qiao Zhang, Xin-Miao Zhou, Miao-Miao Li, Yang An, Rui-Rui Feng, Cen Hong, Yang-Lan He, Hai-Juan Yao, and Le Wang, for establishing and updating the database which prospectively recorded the patients

treated by Dr. Xing-Shun Qi.

## FOOTNOTES

**Author contributions:** Qi XS contributed to conceptualization; Zhang YY, Wang L, Shao XD, Zhang YG, Ma SZ, Peng MY, Xu SX, Yin Y, Guo XZ, and Qi XS contributed to methodology; Zhang YY and Qi XS contributed to formal analysis; Zhang YY, Wang L, Shao XD, Zhang YG, Ma SZ, Peng MY, Xu SX, Yin Y, Guo XZ, and Qi XS contributed to data curation; Zhang YY and Qi XS contributed to writing original draft; Zhang YY, Wang L, Shao XD, Zhang YG, Ma SZ, Peng MY, Xu SX, Yin Y, Guo XZ, and Qi XS contributed to writing review and editing; Guo XZ and Qi XS contributed to supervision; Qi XS contributed to project administration; all authors have read and approved the final manuscript.

**Institutional review board statement:** This study has been approved by the Medical Ethical Committee of the General Hospital of Northern Theater Command with an approval number [Y (2022) 072] and was performed according to the Declaration of Helsinki.

**Informed consent statement:** The requirement for patients' informed consent for this study was waived due to its retrospective nature.

**Conflict-of-interest statement:** All the authors report no relevant conflicts of interest for this article.

**Data sharing statement:** The dataset of the current study is available from the corresponding author on reasonable request.

**STROBE statement:** The authors have read the STROBE Statement – checklist of items, and the manuscript was prepared and revised according to the STROBE Statement – checklist of items.

**Open-Access:** This article is an open-access article that was selected by an in-house editor and fully peer-reviewed by external reviewers. It is distributed in accordance with the Creative Commons Attribution NonCommercial (CC BY-NC 4.0) license, which permits others to distribute, remix, adapt, build upon this work non-commercially, and license their derivative works on different terms, provided the original work is properly cited and the use is non-commercial. See: <https://creativecommons.org/licenses/by-nc/4.0/>

**Country/Territory of origin:** China

**ORCID number:** Yi-Yan Zhang 0000-0003-4550-8724; Le Wang 0000-0002-1475-0334; Xiao-Dong Shao 0000-0002-7693-2969; Yong-Guo Zhang 0000-0001-9330-1651; Shao-Ze Ma 0000-0002-8298-9435; Meng-Yuan Peng 0000-0003-0391-7300; Shi-Xue Xu 0000-0002-9928-6074; Yue Yin 0000-0003-3279-4602; Xiao-Zhong Guo 0000-0002-6397-0501; Xing-Shun Qi 0000-0002-9448-6739.

**S-Editor:** Liu GL

**L-Editor:** Ma JY - MedE A

**P-Editor:** Liu GL

## REFERENCES

- 1 **Ginès P**, Krag A, Abraldes JG, Solà E, Fabrellas N, Kamath PS. Liver cirrhosis. *Lancet* 2021; **398**: 1359-1376 [PMID: 34543610 DOI: 10.1016/S0140-6736(21)01374-X]
- 2 **Vanbiervliet G**, Giudicelli-Bornard S, Piche T, Berthier F, Gelsi E, Filippi J, Anty R, Arab K, Huet PM, Hebuterne X, Tran A. Predictive factors of bleeding related to post-banding ulcer following endoscopic variceal ligation in cirrhotic patients: a case-control study. *Aliment Pharmacol Ther* 2010; **32**: 225-232 [PMID: 20412065 DOI: 10.1111/j.1365-2036.2010.04331.x]
- 3 **de Franchis R**, Bosch J, Garcia-Tsao G, Reiberger T, Ripoll C; Baveno VII Faculty. Baveno VII - Renewing consensus in portal hypertension. *J Hepatol* 2022; **76**: 959-974 [PMID: 35120736 DOI: 10.1016/j.jhep.2021.12.022]
- 4 **Garcia-Tsao G**, Abraldes JG, Berzigotti A, Bosch J. Portal hypertensive bleeding in cirrhosis: Risk stratification, diagnosis, and management: 2016 practice guidance by the American Association for the study of liver diseases. *Hepatology* 2017; **65**: 310-335 [PMID: 27786365 DOI: 10.1002/hep.28906]
- 5 **Petrascu F**, Grothaus J, Mössner J, Schiefke I, Hoffmeister A. Differences in bleeding behavior after endoscopic band ligation: a retrospective analysis. *BMC Gastroenterol* 2010; **10**: 5 [PMID: 20074379 DOI: 10.1186/1471-230X-10-5]
- 6 **Schepke M**, Kleber G, Nürnberg D, Willert J, Koch L, Veltke-Schlieker W, Hellerbrand C, Kuth J, Schanz S, Kahl S, Fleig WE, Sauerbruch T; German Study Group for the Primary Prophylaxis of Variceal Bleeding. Ligation versus propranolol for the primary prophylaxis of variceal bleeding in cirrhosis. *Hepatology* 2004; **40**: 65-72 [PMID: 15239087 DOI: 10.1002/hep.20284]
- 7 **Zuckerman MJ**, Elhanafi S, Mendoza Ladd A. Endoscopic Treatment of Esophageal Varices. *Clin Liver Dis* 2022; **26**: 21-37 [PMID: 34802661 DOI: 10.1016/j.cld.2021.08.003]

- 8 **Schmitz RJ**, Sharma P, Badr AS, Qamar MT, Weston AP. Incidence and management of esophageal stricture formation, ulcer bleeding, perforation, and massive hematoma formation from sclerotherapy versus band ligation. *Am J Gastroenterol* 2001; **96**: 437-441 [PMID: 11232687 DOI: 10.1111/j.1572-0241.2001.03460.x]
- 9 **Lin L**, Cui B, Deng Y, Jiang X, Liu W, Sun C. The Efficacy of Proton Pump Inhibitor in Cirrhotics with Variceal Bleeding: A Systemic Review and Meta-Analysis. *Digestion* 2021; **102**: 117-127 [PMID: 32088712 DOI: 10.1159/000505059]
- 10 **Zhu J**, Qi X, Yu H, Su C, Guo X. Acid suppression in patients treated with endoscopic therapy for the management of gastroesophageal varices: a systematic review and meta-analysis. *Expert Rev Gastroenterol Hepatol* 2018; **12**: 617-624 [PMID: 29564926 DOI: 10.1080/17474124.2018.1456918]
- 11 **Hwang JH**, Shergill AK, Acosta RD, Chandrasekhara V, Chathadi KV, Decker GA, Early DS, Evans JA, Fanelli RD, Fisher DA, Foley KQ, Fonkalsrud L, Jue T, Khashab MA, Lightdale JR, Muthusamy VR, Pasha SF, Saltzman JR, Sharaf R, Cash BD; American Society for Gastrointestinal Endoscopy. The role of endoscopy in the management of variceal hemorrhage. *Gastrointest Endosc* 2014; **80**: 221-227 [PMID: 25034836 DOI: 10.1016/j.gie.2013.07.023]
- 12 **Chinese Society of Hepatology Chinese Medical Association**; Chinese Society of Gastroenterology Chinese Medical Association; Chinese Society of Endoscopy Chinese Medical Association. Guidelines for the diagnosis and treatment of esophageal and gastric variceal bleeding in cirrhotic portal hypertension. *J Clin Hepatol* 2016; **32**: 203-219 [DOI: 10.3969/j.issn.1001-5256.2016.02.002]
- 13 **Blasi A**, Machlab S, Risco R, Costa-Freixas JP, Hernández-Cely G, Horta D, Bofill A, Ruiz-Ramirez P, Profitos J, Sanahuja JM, Fernandez-Simon A, Gómez MV, Sánchez-Delgado J, Cardenas A. A multicenter analysis of the role of prophylactic transfusion of blood products in patients with cirrhosis and esophageal varices undergoing endoscopic band ligation. *JHEP Rep* 2021; **3**: 100363 [PMID: 34765959 DOI: 10.1016/j.jhepr.2021.100363]
- 14 **Tripathi D**, Stanley AJ, Hayes PC, Patch D, Millson C, Mehrzad C, Austin A, Ferguson JW, Olliff SP, Hudson M, Christie JM; Clinical Services and Standards Committee of the British Society of Gastroenterology. U.K. guidelines on the management of variceal haemorrhage in cirrhotic patients. *Gut* 2015; 1680-704 [PMID: 25887380 DOI: 10.1136/gutjnl-2015-309262]
- 15 **Li DK**, Chung RT. Use of proton pump inhibitors in chronic liver diseases. *Clin Liver Dis (Hoboken)* 2017; **10**: 148-151 [PMID: 30992776 DOI: 10.1002/cld.678]
- 16 **Hong C**, Xu X, Feng R, Romeiro FG, Zhang D, Bai Z, Guo X, Qi X. Use of iron sucrose injection in anemia patients with reduced serum iron concentration during hospitalizations of digestive and liver diseases. *Ann Palliat Med* 2021; **10**: 1145-1153 [PMID: 32954752 DOI: 10.21037/apm-19-499]
- 17 **Wang L**, Guo X, Xu X, Xu S, Han J, Wang R, Guo Z, Yi F, Qi X. No Association of Homocysteine, Anticardiolipin Antibody, and Anti-β2 Glycoprotein I Antibody With Portal Venous System Thrombosis in Liver Cirrhosis. *Clin Appl Thromb Hemost* 2021; **27**: 10760296211010969 [PMID: 33882699 DOI: 10.1177/10760296211010969]
- 18 **Li M**, Guo Z, Zhang D, Xu X, Romeiro FG, Mancuso A, Zhang J, Feng R, Zhou X, Hong C, Qi X. Correlation of Serum Cardiac Markers with Acute Decompensating Events in Liver Cirrhosis. *Gastroenterol Res Pract* 2020; **2020**: 4019289 [PMID: 33029132 DOI: 10.1155/2020/4019289]
- 19 **Feng R**, Guo X, Kou Y, Xu X, Hong C, Zhang W, An Y, Philips CA, Mancuso A, Qi X. Association of lipid profile with decompensation, liver dysfunction, and mortality in patients with liver cirrhosis. *Postgrad Med* 2021; **133**: 626-638 [PMID: 33993838 DOI: 10.1080/00325481.2021.1930560]
- 20 **An Y**, Xu X, Ren T, Tong Z, Romeiro FG, Mancuso A, Guo X, Qi X. Adherence to Non-Selective Beta Blockers for Prevention of Variceal Bleeding in Cirrhotic Patients. *Int J Gen Med* 2021; **14**: 6713-6724 [PMID: 34675632 DOI: 10.2147/IJGM.S326192]
- 21 **Peng Y**, Qi X, Guo X. Child-Pugh Versus MELD Score for the Assessment of Prognosis in Liver Cirrhosis: A Systematic Review and Meta-Analysis of Observational Studies. *Medicine (Baltimore)* 2016; **95**: e2877 [PMID: 26937922 DOI: 10.1097/MD.0000000000002877]
- 22 **Wang L**, Guo X, Shao X, Xu X, Zheng K, Wang R, Chawla S, Basaranoglu M, Qi X. Association of endoscopic variceal treatment with portal venous system thrombosis in liver cirrhosis: a case-control study. *herap Adv Gastroenterol* 2022; **15**: 17562848221087536 [PMID: 35574427 DOI: 10.1177/17562848221087536]
- 23 **Li Q**, Wang R, Guo X, Li H, Shao X, Zheng K, Qi X, Li Y. Contrast-Enhanced CT May Be a Diagnostic Alternative for Gastroesophageal Varices in Cirrhosis with and without Previous Endoscopic Variceal Therapy. *Gastroenterol Res Pract* 2019; **2019**: 6704673 [PMID: 31781196 DOI: 10.1155/2019/6704673]
- 24 **Drolz A**, Schramm C, Seiz O, Groth S, Vettorazzi E, Horvatits T, Wehmeyer MH, Goeser T, Roesch T, Lohse AW, Kluwe J. Risk factors associated with bleeding after prophylactic endoscopic variceal ligation in cirrhosis. *Endoscopy* 2021; **53**: 226-234 [PMID: 32894867 DOI: 10.1055/a-1214-5355]
- 25 **Imhann F**, Bonder MJ, Vich Vila A, Fu J, Mujagic Z, Vork L, Tigchelaar EF, Jankipersadsing SA, Cenit MC, Harmsen HJ, Dijkstra G, Franke L, Xavier RJ, Jonkers D, Wijmenga C, Weersma RK, Zhernakova A. Proton pump inhibitors affect the gut microbiome. *Gut* 2016; **65**: 740-748 [PMID: 26657899 DOI: 10.1136/gutjnl-2015-310376]
- 26 **Zhu J**, Yu H, Mancuso A, Qi X. Proton pump inhibitors in liver cirrhosis: a review of benefits and harms. *AME Medical Journal* 2017; **2**: 36-36 [DOI: 10.21037/AMJ.2017.03.04]
- 27 **Savarino V**, Tosetti C, Benedetto E, Compare D, Nardone G. Appropriateness in prescribing PPIs: A position paper of the Italian Society of Gastroenterology (SIGE) - Study section "Digestive Diseases in Primary Care". *Dig Liver Dis* 2018; **50**: 894-902 [PMID: 30093304 DOI: 10.1016/j.dld.2018.07.004]
- 28 **Garg PK**, Sidhu SS, Bhargava DK. Role of omeprazole in prevention and treatment of postendoscopic variceal sclerotherapy esophageal complications. Double-blind randomized study. *Dig Dis Sci* 1995; **40**: 1569-1574 [PMID: 7628284 DOI: 10.1007/bf02285210]
- 29 **Woodward SC**, Herrmann JB, Cameron JL, Brandes G, Pulaski EJ, Leonard F. Histotoxicity of cyanoacrylate tissue adhesive in the rat. *Ann Surg* 1965; **162**: 113-122 [PMID: 14308782 DOI: 10.1097/0000658-196507000-00017]
- 30 **Kunstlinger F**, Brunelle F, Chaumont P, Doyon D. Vascular occlusive agents. *AJR Am J Roentgenol* 1981; **136**: 151-156 [PMID: 6779563 DOI: 10.2214/ajr.136.1.151]
- 31 **Cho E**, Jun CH, Cho SB, Park CH, Kim HS, Choi SK, Rew JS. Endoscopic variceal ligation-induced ulcer bleeding: What

- are the risk factors and treatment strategies? *Medicine (Baltimore)* 2017; **96**: e7157 [PMID: 28614248 DOI: 10.1097/MD.00000000000007157]
- 32 **Johlin FC**, Labrecque DR, Neil GA. Omeprazole heals mucosal ulcers associated with endoscopic injection sclerotherapy. *Dig Dis Sci* 1992; **37**: 1373-1376 [PMID: 1505288 DOI: 10.1007/bf01296006]
- 33 **Snady H**, Korsten MA. Esophageal acid-clearance and motility after endoscopic sclerotherapy of esophageal varices. *Am J Gastroenterol* 1986; **81**: 419-422 [PMID: 3706259]
- 34 **Grande L**, Planas R, Lacima G, Boix J, Ros E, Esteve M, Morillas R, Gasull MA. Sequential esophageal motility studies after endoscopic injection sclerotherapy: a prospective investigation. *Am J Gastroenterol* 1991; **86**: 36-40 [PMID: 1986552]
- 35 **Gimson A**, Polson R, Westaby D, Williams R. Omeprazole in the management of intractable esophageal ulceration following injection sclerotherapy. *Gastroenterology* 1990; **99**: 1829-1831 [PMID: 2227299 DOI: 10.1016/0016-5085(90)90495-m]
- 36 **Shaheen NJ**, Stuart E, Schmitz SM, Mitchell KL, Fried MW, Zacks S, Russo MW, Galanko J, Shrestha R. Pantoprazole reduces the size of postbanding ulcers after variceal band ligation: a randomized, controlled trial. *Hepatology* 2005; **41**: 588-594 [PMID: 15726658 DOI: 10.1002/hep.20593]
- 37 **Young MF**, Sanowski RA, Rasche R. Comparison and characterization of ulcerations induced by endoscopic ligation of esophageal varices versus endoscopic sclerotherapy. *Gastrointest Endosc* 1993; **39**: 119-122 [PMID: 8495829 DOI: 10.1016/s0016-5107(93)70049-8]
- 38 **Nijhawan S**, Rai RR, Nepalia S, Pokharana DS, Bharagava N. Natural history of postligation ulcers. *Am J Gastroenterol* 1994; **89**: 2281-2282 [PMID: 7977270]
- 39 **Boparai V**, Rajagopalan J, Triadafilopoulos G. Guide to the use of proton pump inhibitors in adult patients. *Drugs* 2008; **68**: 925-947 [PMID: 18457460 DOI: 10.2165/00003495-200868070-00004]
- 40 **Zubarik R**, Eisen G, Mastropietro C, Lopez J, Carroll J, Benjamin S, Fleischer DE. Prospective analysis of complications 30 days after outpatient upper endoscopy. *Am J Gastroenterol* 1999; **94**: 1539-1545 [PMID: 10364022 DOI: 10.1111/j.1572-0241.1999.01141.x]
- 41 **Kapoor A**, Dharel N, Sanyal AJ. Endoscopic Diagnosis and Therapy in Gastroesophageal Variceal Bleeding. *Gastrointest Endosc Clin N Am* 2015; **25**: 491-507 [PMID: 26142034 DOI: 10.1016/j.giec.2015.03.004]
- 42 **Lo GH**, Perng DS, Chang CY, Tai CM, Wang HM, Lin HC. Controlled trial of ligation plus vasoconstrictor versus proton pump inhibitor in the control of acute esophageal variceal bleeding. *J Gastroenterol Hepatol* 2013; **28**: 684-689 [PMID: 23278466 DOI: 10.1111/jgh.12107]





Published by **Baishideng Publishing Group Inc**  
7041 Koll Center Parkway, Suite 160, Pleasanton, CA 94566, USA  
**Telephone:** +1-925-3991568  
**E-mail:** [bpgoffice@wjgnet.com](mailto:bpgoffice@wjgnet.com)  
**Help Desk:** <https://www.f6publishing.com/helpdesk>  
<https://www.wjgnet.com>

