

# World Journal of *Methodology*

*World J Methodol* 2023 September 20; 13(4): 166-372



**EDITORIAL**

- 166 Importance of methodological considerations in documenting psychological trauma  
*Vyshka G, Elezi F, Mana T*

**OPINION REVIEW**

- 170 ChatGPT in action: Harnessing artificial intelligence potential and addressing ethical challenges in medicine, education, and scientific research  
*Jeyaraman M, Ramasubramanian S, Balaji S, Jeyaraman N, Nallakumarasamy A, Sharma S*

**REVIEW**

- 179 Compensated liver cirrhosis: Natural course and disease-modifying strategies  
*Kumar R, Kumar S, Prakash SS*
- 194 Telemedicine in inflammatory bowel diseases: A new brick in the medicine of the future?  
*Gravina AG, Pellegrino R, Durante T, Palladino G, D'Onofrio R, Mammone S, Arboretto G, Auletta S, Imperio G, Ventura A, Romeo M, Federico A*

**ORIGINAL ARTICLE****Basic Study**

- 210 Utilization of online systems to promote youth participation in research: A methodological study  
*Salem M, Pollack L, Zepeda A, Tebb KP*
- 223 Comprehensive analysis of cell-extracellular matrix protein Ras suppressor-1 in function and prognosis of gastrointestinal cancers  
*Xu Y, Hou YY, Wu Z, Fang ZX, Wu HT, Liu J*

**Retrospective Cohort Study**

- 238 Role of the phase angle in the prognosis of the cirrhotic patient: 15 years of follow-up  
*Pinto LP, Marroni CA, Czermainski J, Dahlem MLF, Carteri RB, Fernandes SA*

**Retrospective Study**

- 248 Association of carbon monoxide poisonings and carboxyhemoglobin levels with COVID-19 and clinical severity  
*Coskun A, Demirci B, Turkdogan KA*

**Observational Study**

- 259 External validation of the Moroccan Arabic version of the European Organization for Research and Treatment of Cancer colorectal (CR29) module: Monocentric study  
*Bachri H, Essangri H, El Bahaoui N, Benkabbou A, Mohsine R, Majbar AM, Souadka A*

- 272 Biliary fistula and late recurrence of liver hydatid cyst: Role of cysto-biliary communication: A prospective multicenter study

*Habeeb TAAM, Podda M, Tadic B, Shelat VG, Tokat Y, Abo Alsaad MI, Kalmoush AE, Nassar MS, Mustafa FM, Morsi Badawy MH, Sobhy Shaaban M, Mohamed TZ, El Sayed Henish MI, Elbelkasi H, Abdou Yassin M, Mostafa A, Ibrahim A, A-Abdelhady W, Elshahidy TM, Mansour MI, Moursi AM, Abdallah Zaitoun M, Abd-Allah ES, Abdelmonem Elsayed A, S Elsayed R, M Yehia A, Abdelghani A, Negm M, Abo-Alella HA, Elaigy MM*

### Prospective Study

- 287 Role of endoscopic ultrasound and endoscopic ultrasound-guided tissue acquisition in diagnosing hepatic focal lesions

*Okasha HH, Delsa H, Alsawaf A, Hashim AM, Khattab HM, Abdelfatah D, Abdellatef A, Albitar A*

### SYSTEMATIC REVIEWS

- 296 Post-COVID-19 cholangiopathy: Systematic review

*Rasheed MA, Ballotin VR, Bigarella LG, Soldera J*

- 323 Potential long-term neurological and gastrointestinal effects of COVID-19: A review of adult cohorts

*Sherif ZA, Deverapalli M, Challa SR, Martirosyan Z, Whitesell P, Pizuorno AM, Naqvi Z, Tulloch IK, Oskrochi G, Brim H, Ashktorab H*

### SCIENTOMETRICS

- 337 Physician-scientists or celebrities? Kardashian-index of gastroenterologists

*Ugonabo O, Malik SU, Akbar UA, Zamani Z, Frandah W*

- 345 Mapping research trends of transarterial chemoembolization for hepatocellular carcinoma from 2012 to 2021: A bibliometric analysis

*Zhang N, He XF, Niu XK*

### CASE REPORT

- 359 Clinical, imaging, arthroscopic, and histologic features of bilateral anteromedial meniscofemoral ligament: A case report

*Luco JB, Di Memmo D, Gomez Sicre V, Nicolino TI, Costa-Paz M, Astoul J, Garcia-Mansilla I*

- 366 Sclerotic marginal zone lymphoma: A case report

*Moureiden Z, Tashkandi H, Hussaini MO*

**ABOUT COVER**

Peer Reviewer of *World Journal of Methodology*, Ahmad Ozair, MBBS, Postdoctoral Fellow, Miami Cancer Institute, Baptist Health South Florida, Miami, FL 33176, United States. ahmad.ozair@baptisthealth.net

**AIMS AND SCOPE**

The primary aim of *World Journal of Methodology* (*WJM*, *World J Methodol*) is to provide scholars and readers from various fields of methodology with a platform to publish high-quality basic and clinical research articles and communicate their research findings online.

*WJM* mainly publishes articles reporting research results obtained in the field of methodology and covering a wide range of topics including breath tests, cardiac imaging techniques, clinical laboratory techniques, diagnostic self-evaluation, cardiovascular diagnostic techniques, digestive system diagnostic techniques, endocrine diagnostic techniques, neurological diagnostic techniques, obstetrical and gynecological diagnostic techniques, ophthalmological diagnostic techniques, otological diagnostic techniques, radioisotope diagnostic techniques, respiratory system diagnostic techniques, surgical diagnostic techniques, *etc.*

**INDEXING/ABSTRACTING**

The *WJM* is now abstracted and indexed in PubMed, PubMed Central, Reference Citation Analysis, China National Knowledge Infrastructure, China Science and Technology Journal Database, and Superstar Journals Database.

**RESPONSIBLE EDITORS FOR THIS ISSUE**

Production Editor: *Zi-Hang Xu*, Production Department Director: *Xu Guo*, Editorial Office Director: *Ji-Hong Liu*.

**NAME OF JOURNAL**

*World Journal of Methodology*

**ISSN**

ISSN 2222-0682 (online)

**LAUNCH DATE**

September 26, 2011

**FREQUENCY**

Quarterly

**EDITORS-IN-CHIEF**

Timotius Ivan Hariyanto

**EDITORIAL BOARD MEMBERS**

<https://www.wjgnet.com/2222-0682/editorialboard.htm>

**PUBLICATION DATE**

September 20, 2023

**COPYRIGHT**

© 2023 Baishideng Publishing Group Inc

**INSTRUCTIONS TO AUTHORS**

<https://www.wjgnet.com/bpg/gerinfo/204>

**GUIDELINES FOR ETHICS DOCUMENTS**

<https://www.wjgnet.com/bpg/gerinfo/287>

**GUIDELINES FOR NON-NATIVE SPEAKERS OF ENGLISH**

<https://www.wjgnet.com/bpg/gerinfo/240>

**PUBLICATION ETHICS**

<https://www.wjgnet.com/bpg/gerinfo/288>

**PUBLICATION MISCONDUCT**

<https://www.wjgnet.com/bpg/gerinfo/208>

**ARTICLE PROCESSING CHARGE**

<https://www.wjgnet.com/bpg/gerinfo/242>

**STEPS FOR SUBMITTING MANUSCRIPTS**

<https://www.wjgnet.com/bpg/gerinfo/239>

**ONLINE SUBMISSION**

<https://www.f6publishing.com>

## Post-COVID-19 cholangiopathy: Systematic review

Mazen Abdalla Rasheed, Vinícius Remus Ballotin, Lucas Goldmann Bigarella, Jonathan Soldera

**Specialty type:** Medical laboratory technology

**Provenance and peer review:** Invited article; Externally peer reviewed.

**Peer-review model:** Single blind

**Peer-review report's scientific quality classification**

Grade A (Excellent): 0  
Grade B (Very good): 0  
Grade C (Good): C  
Grade D (Fair): D, D  
Grade E (Poor): 0

**P-Reviewer:** Gaspar R, Portugal; Giacomelli L, Italy

**Received:** April 15, 2023

**Peer-review started:** April 15, 2023

**First decision:** May 12, 2023

**Revised:** June 7, 2023

**Accepted:** August 23, 2023

**Article in press:** August 23, 2023

**Published online:** September 20, 2023



**Mazen Abdalla Rasheed, Jonathan Soldera,** Acute Medicine, University of South Wales, Cardiff CF37 1DL, United Kingdom

**Vinícius Remus Ballotin, Lucas Goldmann Bigarella,** School of Medicine, Universidade de Caxias do Sul, Caxias do Sul 95070-560, Brazil

**Corresponding author:** Jonathan Soldera, MD, MSc, Tutor, Acute Medicine, University of South Wales, 86-88 Adam St, Cardiff CF37 1DL, United Kingdom.  
[jonathansoldera@gmail.com](mailto:jonathansoldera@gmail.com)

### Abstract

#### BACKGROUND

The coronavirus disease 2019 (COVID-19) pandemic has had a profound impact on global health, primarily characterized by severe respiratory illness. However, emerging evidence suggests that COVID-19 can also lead to secondary sclerosing cholangitis (SC), referred to as post-COVID-19 cholangiopathy.

#### AIM

To synthesize currently reported cases to assess the current state of knowledge on post-COVID-19 cholangiopathy.

#### METHODS

Medical Subject Headings and Health Sciences Descriptors were used to retrieve relevant studies, which were combined using Boolean operators. Searches were conducted on electronic databases including Scopus, Web of Science, and MEDLINE (PubMed). Studies published in English, Spanish, or Portuguese were included, with no restrictions on the publication date. Additionally, the reference lists of retrieved studies were manually searched. Simple descriptive analyses were used to summarize the results. Then the data were extracted and assessed based on Reference Citation Analysis (<https://www.referencecitationanalysis.com/>).

#### RESULTS

The initial search yielded a total of 192 articles. After screening, 85 articles were excluded due to duplication, leaving 107 articles for further review. Of these, 63 full-length articles met the inclusion criteria and were included in the analyses. Most of the patients were male and exhibited elevated liver function tests (93.8%). Magnetic resonance imaging revealed duct thickening with contrast enhancement (47.7%), as well as beading of the intrahepatic ducts (45.7%) with peribiliary contrast enhancement on diffusion (28.7%). Liver biopsy results confirmed SC in most cases (74.4%). Sixteen patients underwent liver transplantation, with three

experiencing successful outcomes.

## CONCLUSION

Post-COVID-19 cholangiopathy is a serious condition that is expected to become increasingly concerning in the coming years, particularly considering long COVID syndromes. Although liver transplantation has been proposed as a potential treatment option, more research is necessary to establish its efficacy and explore other potential treatments.

**Key Words:** Coronavirus disease 2019; Severe acute respiratory syndrome coronavirus 2; Cholangiopathy; Liver function tests; Liver transplantation

©The Author(s) 2023. Published by Baishideng Publishing Group Inc. All rights reserved.

**Core Tip:** Post-coronavirus disease 2019 (COVID-19) cholangiopathy is a rare but serious complication that can occur after contracting COVID-19. It is characterized by inflammation and damage to the bile ducts. To better understand this condition and its treatment, we conducted a systematic review of post-COVID-19 cholangiopathy cases. Sixty-three articles met the inclusion criteria, representing 540 patients. Males over 50-years-old were more prone to this condition, which is often accompanied by elevated liver function, bile duct thickening, and kidney failure after prolonged use of mechanical ventilation. Further research is needed to confirm the effectiveness of liver transplantation in treating post-COVID-19 cholangiopathy.

**Citation:** Rasheed MA, Ballotin VR, Bigarella LG, Soldera J. Post-COVID-19 cholangiopathy: Systematic review. *World J Methodol* 2023; 13(4): 296-322

**URL:** <https://www.wjgnet.com/2222-0682/full/v13/i4/296.htm>

**DOI:** <https://dx.doi.org/10.5662/wjm.v13.i4.296>

## INTRODUCTION

On March 2020, the World Health Organization declared a global health pandemic after the first case was recognized on December 2019 in Wuhan City, China, of what was called severe acute respiratory syndrome coronavirus 2 (SARS-CoV-2) [1]. This led to catastrophic events in the world resulting in more than 6 million deaths globally. The pandemic has led to a great financial and humanitarian loss due to prolonged lockdowns, which have had a tragic effect on the global economy[2].

Also, coronavirus disease 2019 (COVID-19) keeps enduring second and third waves of outbreaks in many countries, probably caused by mutant new variants of the virus[2]. Despite the accelerated speed of vaccine development for the prevention of COVID-19 to control the disease and robust mass vaccination worldwide including booster doses, these new SARS-CoV-2 variants threaten the progress made so far with the purpose of controlling the spread of the disease[2, 3].

Respiratory symptoms are the most common manifestation of the disease, which range from mild to severe and may include fever, dry cough, shortness of breath, anosmia, ageusia, and fatigue[4]. It may lead to viral pneumonia with severe complications such as acute respiratory failure, acute respiratory distress syndrome requiring intubation, mechanical ventilation (MV), and intensive care management[5,6].

In addition to respiratory symptoms, COVID-19 might also cause a range of extrapulmonary manifestations including cardiovascular, neurological, and renal complications[7]. Gastrointestinal symptoms, including diarrhea, nausea, and vomiting, are also commonly reported[8]. Post-COVID-19, derangement of liver enzymes is a potential complication observed in admitted COVID-19 patients, with a prevalence ranging from 14% to 83%[9]. Other liver-related conditions such as autoimmune hepatitis, vascular thrombosis, and hemophagocytic lymphohistiocytosis have also been associated with the post-COVID-19 period[9,10].

However, one emerging complication of COVID-19 is post-COVID-19 cholangiopathy (PCC), a novel clinical entity characterized by inflammation and damage to the bile ducts in individuals who have recovered from COVID-19 infection [11]. The clinical presentation of PCC can vary, but common symptoms may include abdominal pain, fever, and jaundice [12]. PCC has been observed in patients without a history of prior liver disease. This condition can manifest in various clinical settings, such as in individuals with severe COVID-19 infection requiring MV, as well as in those experiencing milder forms of the disease[5,13]. The prevalence of PCC is not well understood, and it is not clear if it is more common in certain patient populations. Some researchers have suggested a potential association between certain drugs, including immunomodulator agents, ketamine, and antiviral medications, and the development of PCC. However, the available evidence regarding these drugs causing cholangiopathy remains insufficient[9].

This systematic review comprehensively analyzes and synthesizes the existing evidence pertaining to PCC. The primary objective is to explore the clinical presentation and management approaches documented in the available cases reported in the literature. By conducting this review, we provide a comprehensive overview of the current understanding

and knowledge gaps surrounding PCC, which can contribute to the development of effective strategies for diagnosis and treatment in clinical practice.

---

## MATERIALS AND METHODS

---

### **Study design**

This study was conducted in accordance with the guidelines for preferred reporting items for systematic reviews and meta-analyses (PRISMA) protocol guidelines[14].

### **Data sources**

The studies included in this review were identified using the search strategy: in ("COVID-19" OR "SARS-COV-2") AND ("cholangiopathy" OR "cholangitis" OR "liver transplantation"). This search command was run on the electronic databases Scopus, Web of Science, and Medline (PubMed). Languages were restricted to English, Spanish, and Portuguese. There was no date of publication restrictions. The reference lists of the retrieved studies were also manually searched. The databases were searched in March 2023. Reference Citation Analysis (<https://www.referencecitationanalysis.com/>) was used to supplement the search.

### **Inclusion and exclusion criteria**

Inclusion criteria were clinical case reports or case series of post-COVID cholangiopathy. Studies needed to include detailed information about the clinical presentation, diagnosis, management, and outcomes. Articles unrelated to the topic were excluded as were those that did not provide sufficient detail about the cases. If there was more than one study published using the same case, the variables were complemented with both articles. Studies published only as abstracts were included, as long as the available data made data collection possible.

### **Study selection and data extraction**

A comprehensive search of various databases was conducted using the search terms listed in the COVID-19, cholangitis, and liver transplantation ("COVID-19" OR "SARS-COV-2") AND ("cholangiopathy" OR "cholangitis" OR "liver transplantation"). The initial screening process involved reviewing titles and abstracts to identify potentially relevant studies. These studies were then analyzed in full, and some were excluded due to a lack of clinical information. Two reviewers independently extracted data from eligible studies using a standardized form and assessed the characteristics of the subjects and outcomes measured. Any discrepancies in study selection or data extraction were resolved by a third party.

### **Data collection**

Variables included were age, sex, clinical presentation, liver function tests, renal function test, imaging findings, histopathology, whether or not the patient had undergone orthotopic liver transplantation (OLT), and outcome.

### **Data processing and analysis**

Data were analyzed and summarized using descriptive techniques such as frequency, means, and median. The analyses were performed using Microsoft Excel 2010.

---

## RESULTS

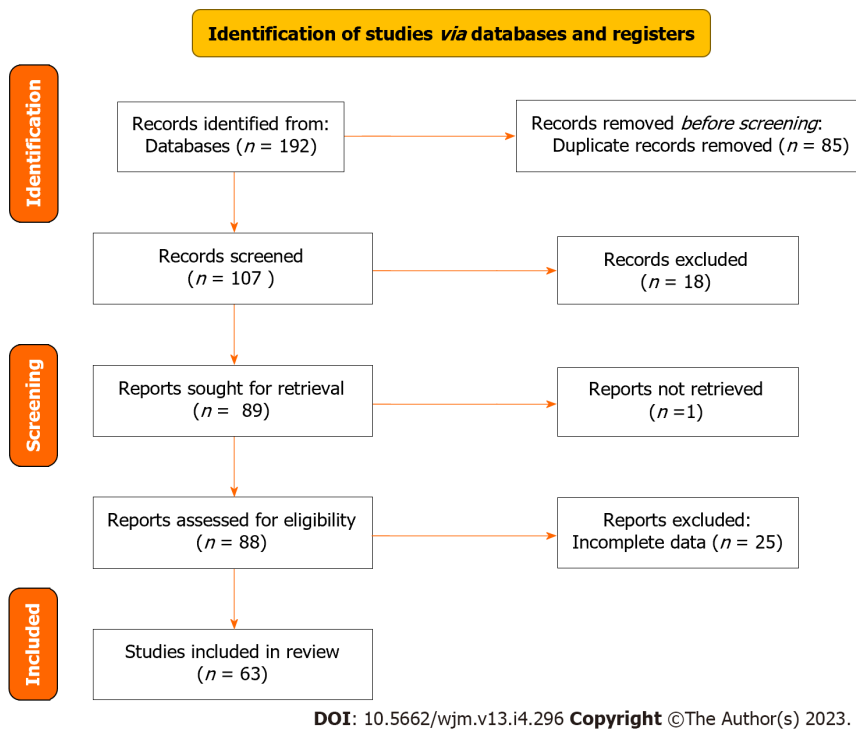
---

The search strategy retrieved 192 articles; 85 articles were excluded because they were duplicates and 107 articles were screened in the review. A total of 88 full-length articles were included and retrieved, of which 63 were included in the review. The PRISMA flowchart illustrating the search strategy is shown in [Figure 1](#). Studies reviewed were either a case report or a case series.

This systematic review included a total of 540 patients, of whom 69 (12.7%) were male, 26 (4.8%) were female, and 445 (82.5%) did not note their sex. The majority of patients (66, 12.2%) were over 50-years-old. Almost all patients (93.8%) had elevated liver enzymes in the acute phase, with an increase of these levels in the chronic phase. Total bilirubin was elevated in 343 patients (63.5%), while only 80 (14.8%) had levels lower than 1.2 mg/dL. Data on bilirubin levels were not reported for 19 cases. Levels of alkaline phosphatase were high among 488 patients (90.3%) and gamma-glutamyl transferase were consistently elevated, often surpassing 1000 U/L.

In this study, based on imaging findings, 225 of 540 (41.6%) patients had biliary ductal dilatation with fibrosis on ultrasound, while 50 (9.2%) patients did not show any alteration. Furthermore, according to magnetic resonance imaging (MRI) results, 258 (47.7%) patients had bile duct thickening with contrast enhancement, 247 (45.7%) had beading of the intrahepatic ducts, and 155 (28.7%) had peribiliary enhancement on diffusion.

Moreover, 223 (41.3%) patients with PCC had respiratory failure type 2, which was characterized by acute respiratory distress syndrome (ARDS). Some of these patients underwent bilateral lung transplantation, but unfortunately 1 patient died. Additionally, 355 patients (65.7%) had acute renal injury that required either dialysis or renal transplantation after OLT. Data on renal function were not reported for 16 patients. According to liver biopsy results, 402 patients (74.4%) had



**Figure 1** The preferred reporting items for systematic reviews and meta-analyses flowchart for the systematic review.

sclerosing cholangitis (SC). Moreover, 16 patients (2.96%) with post-COVID-19 cholangitis underwent OLT. Of these, 15 patients experienced successful outcomes, with an improvement in liver enzyme levels post-transplantation.

## DISCUSSION

After the first of case of SARS-CoV-2 disease in 2019[1], a novel clinical entity emerged. This condition has been reported in a small number of patients who have recovered from the virus and is characterized by elevated liver enzymes, biliary ductal dilatation on imaging, and histopathological findings of secondary SC (SSC)[11]. This systematic review examined the clinical presentations and outcomes of 540 patients with PCC, a rare complication of COVID-19 that affects the biliary system.

It is important to consider the differential diagnosis, as other diseases may present with a similar presentation[15]. Ketamine-induced cholangiopathy can lead to fusiform dilatation of the common bile ducts, without evidence of extrinsic or intrinsic obstruction[16]. The severity depends on the duration of using ketamine, and it is reversible in abstinent patients. Another difference is ischemic cholangitis, which occurs as a consequence of deficient blood flow to the bile duct wall[17]. This can affect the bile ducts leading to segmental strictures and cholangiectasis, resulting in mechanical restriction of bile acid flow.

SC is a medical condition characterized by the destruction of bile ducts due to inflammation and fibrosis and severe progressive stenosis of the bile tracts including three types: primary SC (PSC); immunoglobulin G-related SC (IgG-SC); and secondary cholangitis such as bacterial cholangitis, viral cholangitis (cytomegalovirus), postoperative biliary stenosis, and choledocholithiasis. Usually the patients present with similar cholestatic features such as itching and jaundice, and blood tests reveal high cholestatic enzymes[18,19]. Although the clinical presentation of PSC and IgG4-SC are nearly the same, they differ in treatment response, outcomes and comorbidities, and how to differentiate it from cholangiocarcinoma[18,19]. The difference between them is that IgG4-SC patients respond actively to prednisolone and steroid therapy, whereas PSC has no standard treatment approved; only ursodeoxycholic acid can be used in some patients, but it does not improve the overall prognosis[18-21].

Distinguishing and differentiating between PSC-high IgG and IgG-SC is challenging. A promising study that calculated serum IgG4:IgG1 ratios showed excellent specificity in distinguishing IgG4-SC from PSC-high IgG4[18,19]. The most common diagnostic test for PSC is cholangiography, which shows a pruned tree appearance, beaded ducts, and band-like stricture; thus, endoscopic retrograde cholangiopancreatography (ERCP) or magnetic resonance cholangiopancreatography is highly recommended. PSC is also highly associated with inflammatory bowel disease (ulcerative colitis more than Crohn's disease); thus, a colonoscopy is recommended for the diagnosis, which increases the risk of cholangiocarcinoma and gallbladder carcinoma[18,19]. Therefore, more studies are required on the diagnostic procedures of PSC, IgG4-SC, and cholangiocarcinoma and their treatment and management[18,19].

The present results on PCC showed that most patients are male (12.7%) older than 50-years-old, consistent with the previous literature[9]. Every patient had elevated liver enzymes in the acute phase, and their levels increased in chronic



**Table 1** Baseline features in 540 patients with post-COVID-19 cholangiopathy, *n* (%)

Variable	Patients, <i>n</i> = 540 (100)
Sex	
Male	69 (12.7)
Female	26 (4.8)
Age > 50 year	66 (12.2)
Liver enzymes	
High (> 45)	507 (93.8)
Total bilirubin	
High (> 1.2 mg/dL)	343 (63.5)
Alkaline phosphatase	
High (> 147 IU/L)	488 (90.3)
Ultrasound findings	
Biliary ductal dilatation with fibrosis	225 (41.6)
MRI Findings	
Bile duct thickening and enhancement	258 (47.7)
Beading of intrahepatic ducts	247 (45.7)
Peribiliary diffusion	155 (28.7)
Histopathology with secondary sclerosing cholangitis	402 (74.4)
Orthotopic liver transplantation	16 (2.96)

COVID-19: Coronavirus disease 2019; MRI: Magnetic resonance imaging.

phase if left untreated.

Also, ultrasound findings showed that 225 patients (41.6%) presented with biliary ductal dilatation. The MRI findings in this systematic review showed that only a small number of patients (28.7%) had peribiliary enhancement on diffusion, while a larger number of patients (47.7%) had bile duct thickening and enhancement, and 247 patients (45.7%) had beading of the intrahepatic ducts. By contrast, a previous retrospective study by Faruqui *et al*[13] showed that a higher proportion of patients (11/12, 92%) had beading of the intrahepatic ducts, 7/12 (58%) had bile duct wall thickening with enhancement, and 10/12 (83%) had peribiliary diffusion high signal[11]. Details can be found in [Table 1](#) and [Table 2](#).

PCC appears to have different histologic characteristics compared to SSC in critically ill patients caused by other factors. Biopsy samples from patients with PCC show extensive degeneration and injury of cholangiocytes, as well as unique microvascular features such as swelling of hepatic artery endothelial cells, phlebitis in the portal vein, and sinusoidal obstruction syndrome[5]. Several studies have suggested that COVID-19 cholangiopathy is the result of progressive paucity of bile ducts; however, the exact pathophysiology is not well known[11]. Our histopathology biopsy results showed SSC in 402 patients (74.4%).

On the other hand, PCC presentation is difficult to treat, and sometimes requires OLT[5,6,21]. Almost all patients presented with respiratory failure type 2 as they had ARDS, and 1 patient had bilateral lung transplant and unfortunately died. Every patient presented with acute kidney injury, which required either dialysis or renal transplantation post OLT. As described in the literature, PCC is often accompanied by respiratory failure and acute renal injury[22-25]. Also, some cases of biliary casts have been described, removed *via* ERCP. The diagnosis and management of post-COVID 19 cholangiopathy requires an ERCP, especially in the presence of a dilated choledocus in imaging studies[9,26].

Also, 16 patients (2.96%) underwent OLT, which can be a viable treatment option for this condition[5,27]. One of these cases was reported by Durazo *et al*[5], which comprised SSC in a 47-year-old patient who was recovering from severe acute respiratory distress syndrome caused by COVID-19 infection. He was admitted to the intensive care unit for prolonged MV (29 d) and was listed for liver transplantation with a model for end-stage hepatic disease score of 37. On day 108 from his presentation, the patient underwent successful OLT with a whole liver allograft from a deceased donor.

## CONCLUSION

In conclusion, this paper presents an extensive review of post-COVID-19 cholangiopathy published in medical journals. Our analysis indicates that post-COVID-19 cholangiopathy is a serious systemic illness that can affect the liver in addition to the lungs. Most cases were found in males over 50-years-old, and patients with cholangiopathy exhibited elevated liver

Table 2 Summary of systemically reviewed clinical cases

Ref.	Age, yr	Sex	Clinical presentation	Elevated liver enzyme	U/S findings	MRI findings	Respiratory failure	Renal failure	Histopathology	OLT	Outcome
Roth <i>et al</i> [28], 2021	38	Male	Post-COVID-19 cholangiopathy	Yes	Intrahepatic bile ducts beading, with sub-segmental strictures and dilatation	Beading of intrahepatic ducts	Yes, required MV; On supplemental oxygen, then off on day 63 and decannulated	Yes, recovered	Portal tract findings; Mild duct paucity, moderate bile duct swelling & reaction; Mild portal tract inflammation; Endothelial hepatic artery swelling; Portal veins with focal endo phlebitis	Not done	Recovered
	25	Male	Post-COVID-19 cholangiopathy	Yes	Hepatomegaly, extrahepatic bile duct dilatation, intrahepatic bile duct dilatation	Beading of intrahepatic ducts	Yes, required MV; On supplemental oxygen, then off on day 112 and decannulated	Yes, recovered	Portal tract findings; Moderate duct paucity, moderate bile duct swelling & reaction. Moderate portal tract inflammation; Endothelial hepatic artery swelling; Portal veins with focal endo phlebitis	Not done	Recovered
	40	Female	Post-COVID-19 cholangiopathy	Yes	Hepatomegaly, no dilatation	Peribiliary diffusion, moderate portal and periportal fibrosis	Yes, remains with tracheostomy & MV, and then off MV on day 63	Yes, recovered	Portal tract findings; Moderate duct paucity, moderate bile duct swelling & reaction; Severe portal tract inflammation; Endothelial hepatic artery swelling; Portal veins with focal endo phlebitis	Not done	Death, cardiac arrest
Faruqui <i>et al</i> [13], 2021	Mean age 58	Male	Post-COVID-19 cholangiopathy	Yes	U/S showed; extrahepatic bile duct dilatation and intrahepatic bile duct dilatation and periportal diffusion	MRI showed, beading of intrahepatic ducts (11/12, 92%); Peribiliary diffusion (10/12, 83%); Bile duct wall thickening (7/12, 58%)	Patients required MV	Yes, recovered	Large duct obstruction without clear bile duct loss	Done OLT	Had t successful recovery and rapid clinical improvement
	Mean age 58	Female	Post-COVID-19 cholangiopathy	Yes	Experiencing persistent	Beading of intrahepatic ducts;	Patients required MV	Yes, recovered	Large duct obstruction without	Highly recommended	Recovery with long-term

					jaundice, hepatic insufficiency, and/or recurrent bacterial cholangitis	Peribiliary diffusion; Bile duct wall thickening			clear bile duct loss	for OLT. Patient on transplantation waiting list, still not done OLT at time of study	liability and comorbidity
Mean age 58	Male	Post-COVID-19 cholangiopathy	Yes	Experiencing persistent jaundice, hepatic insufficiency, and/or recurrent bacterial cholangitis	Beading of intrahepatic ducts; Peribiliary diffusion; Bile duct wall thickening	Patients required MV	Yes, recovered	Large duct obstruction without clear bile duct loss	Highly recommended for OLT. Patient on transplantation waiting list, still not done OLT at time of study	Recovery with long-term liability and comorbidity	
Mean age 58	Male	Post-COVID-19 cholangiopathy	Yes	Experiencing persistent jaundice, hepatic insufficiency, and/or recurrent bacterial cholangitis	Beading of intrahepatic ducts; Peribiliary diffusion; Bile duct wall thickening	Patients required MV	Yes, recovered	Large duct obstruction without clear bile duct loss	Highly recommended for OLT. Patient on transplantation waiting list, still not done OLT at time of study	Recovery with long-term liability and comorbidity	
Mean age 58	Male	Post-COVID-19 cholangiopathy	Yes	Experiencing persistent jaundice, hepatic insufficiency, and/or recurrent bacterial cholangitis	Beading of intrahepatic ducts; Peribiliary diffusion; Bile duct wall thickening	Patients required MV	Yes, recovered	Secondary sclerosing cholangitis	Highly recommended for OLT, patient on transplantation waiting list, still not done OLT at time of study	Recovery with long-term liability and comorbidity	
Mean age 58	Male	Post-COVID-19 cholangiopathy	Yes	Intrahepatic bile duct dilatation and periportal diffusion	Beading of intrahepatic ducts; Peribiliary diffusion; Bile duct wall thickening	Patients required MV	Yes, recovered	Secondary sclerosing cholangitis	OLT Not done	Recovery with long-term liability and comorbidity	
Mean age 58	Male	Post-COVID-19 cholangiopathy	Yes	Intrahepatic bile duct dilatation and periportal diffusion	Beading of intrahepatic ducts; Peribiliary diffusion; Bile duct wall thickening	Patients required MV	Yes, recovered	Secondary sclerosing cholangitis	OLT Not done	Recovery with long-term liability and comorbidity	
Mean age 58	Male	Post-COVID-19 cholangiopathy	Yes	Intrahepatic bile duct dilatation and periportal	Beading of intrahepatic ducts; Peribiliary diffusion	Patients required MV	Yes, recovered	Secondary sclerosing cholangitis	OLT Not done	Recovery with long-term liability and comorbidity	

					diffusion						
	Mean age 58	Male	Post-COVID-19 cholangiopathy	Yes	Intrahepatic bile duct dilatation and periportal diffusion	Beading of intrahepatic ducts; Peribiliary diffusion	Patients required MV	Yes, recovered	Secondary sclerosing cholangitis	OLT Not done	Recovery with long-term liability and comorbidity
	Mean age 58	Male	Post-COVID-19 cholangiopathy	Yes	Intrahepatic bile duct dilatation and periportal diffusion	Beading of intrahepatic ducts; Peribiliary diffusion	Patients required MV	Yes, recovered	Secondary sclerosing cholangitis	OLT Not done	Recovery with long-term liability and comorbidity
	Mean age 58	Male	Post-COVID-19 cholangiopathy	Yes	Intrahepatic bile duct dilatation and periportal diffusion	Beading of intrahepatic ducts	Patients required MV	Yes, recovered	Secondary sclerosing cholangitis	OLT Not done	Recovery with long-term liability and comorbidity
	Mean age 58	Male	Post-COVID-19 cholangiopathy	Yes	Intrahepatic bile duct dilatation and periportal diffusion	MRI not available	Patients required MV	Yes, recovered	Secondary sclerosing cholangitis	OLT Not done	Recovery with long-term liability and comorbidity
Li <i>et al</i> [29], 2022	N/A	Two sample mendelian randomization	The autoimmune diseases showed not associated with COVID-19 infection	N/A	N/A	N/A	N/A	N/A	N/A	N/A	N/A
Hunyady <i>et al</i> [30], 2023	N/A	24 Patients	Post-COVID-19 cholangiopathy developed after a median of 91 d	Yes	N/A	N/A	Patients required MV, the median was 48 d among all patients	N/A	COVID-SSC and CIP-SSC share the same clinical phenotype	N/A	UDCA showed great improvement in patients without liver cirrhosis and reduced severity in patients with liver cirrhosis, while OLT showed significant improvement in patient with liver cirrhosis
Weaver <i>et al</i> [31], 2021	63	Male	Post-COVID-19 cholangiopathy	Yes	Sludge in the gallbladder, no biliary ductal dilation, and patent vasculature	N/A	Patients required MV	N/A	Filling defects in the common bile duct as well as an irregular and beaded appearance of the intrahepatic ducts	Not done	Recovered, after ERCP sphincterotomy followed by balloon sweep of the biliary ducts and removal of thick stone

Hartl <i>et al</i> [32], 2022	N/A	N/A	Post-COVID-19 cholangiopathy (65 patients with CLD of 496 patients included in the study, around 24.6% non-ACLD vs ACLD 10.6% associated with COVID)	Yes. Alkaline phosphatase showed (pre: 91.0 vs T1: 121.0 vs last: 175.0 U/L) and gamma glutamyl transferase GGT (pre: 95.0 vs T1: 135.0 vs last: 202.0 U/L)	N/A	N/A	N/A	N/A	20% of patients with CLD developed progressive cholestasis post-COVID-19 cholangiopathy, and patients with NASH/NAFLD also have a risk of developing cholestatic liver failure and secondary sclerosing cholangitis post-COVID-19	N/A	N/A
Duengelhoeft <i>et al</i> [33], 2022	N/A	N/A	Post-COVID-19 cholangiopathy, associated more with Autoimmune hepatitis AIH as well as post COVID vaccine than PBC and PSC patients	Yes	N/A	N/A	N/A	N/A	N/A	N/A	N/A
John <i>et al</i> [34], 2023	N/A	N/A	Post-COVID -19 cholangiopathy study included 1607 patients with liver cirrhosis used UDCA	Yes	N/A	N/A	N/A	N/A	N/A	N/A	UDCA showed great improvement in patients with liver cirrhosis, by decreased symptoms and decreased COVID-19 infection
Heucke <i>et al</i> [35], 2022	N/A	48	Post-COVID-19 cholangiopathy 13% from 496 patients developed CLD; 23% of patients with CLD developed cholestasis/cholangiopathy	Yes (ALT & AST were elevated in 50 patients less than 5 times upper limit of normal. While in late-stage alkaline phosphatase and GGT were highly progressively elevated	N/A	N/A	Yes, require oxygen supply & some patients MV	Yes, some patients required dialysis for renal failure	The histopathology reported SARS-CoV-2 RNA and/or proteins in human liver tissue and bile samples, this SARS-CoV-2 RNA may lead to provoke a strong proinflammatory cytokine response (TNF, IL-1, IL-6) with hypercoagulation, endothelial damage, consecutive venous and arterial	9 patients listed for OLT and 6 patients done OLT with good recovery	16 patients died, and 24 patients were treated with ketamine during the acute phase of COVID-19 and around 28 patients with SSC from 48 were reduced after using UDCA treatment

									embolism, as well as secondary parenchymal damage		
Bazerbachi <i>et al</i> [36], 2022	56	Female	Post-COVID-19 cholangiopathy	Yes alkaline phosphatase 1574U/L, total bilirubin 11 mg/dL, ALT 88 U/L, AST 101 U/L	EUS showed a left hepatic duct stricture and heterogeneous, non-shadowing cylindrical objects in the main bile duct	N/A	Yes, require tracheostomy & MV	Yes, developed renal failure and required hemodialysis	LHD stricture with upstream dilation of the left ducts, and obliteration of right intrahepatic with secondary sclerosing changes	Not done	Improved, casts were swept and removed, and left lobe was stented with a 10 Fr 20 cm plastic stent improving bilirubin level to a baseline of 3 mg/dL
Cho <i>et al</i> [37], 2022	47	Female	Post-COVID-19 cholangiopathy	Yes, highly elevated ALP-positive ANA, anti-mitochondrial highly positive	N/A	N/A	N/A	N/A	N/A	N/A	Post-COVID-19 cholangiopathy may be due to direct cytotoxicity from SARS-CoV-2
	57	Male	Post-COVID-19 cholangiopathy	Yes, hypogammaglobinemia, high GGT, elevated AST/ALT, positive anti-mitochondrial antibody, anti-smooth muscle antibodies, and anti-double stranded DNA antibodies	N/A	N/A	N/A	N/A	N/A	OLT Considered for some patients	active replication, hypoxia induced respiratory failure, drug induced liver injury, vascular coagulopathy, immune mediated liver damage
	N/A	N/A	Post-COVID-19 cholangiopathy	Yes, ALP > three times	N/A	MRCP showed dilatation of hepatic ducts with stenosis and beading of intrahepatic ducts	N/A	N/A	N/A		
	N/A	24 Patients	Post COVID-19 Cholangiopathy	Yes	N/A	N/A	N/A	N/A	N/A		
Yu <i>et al</i> [38], 2022	N/A	N/A	Post-COVID-19 cholangiopathy	Yes	N/A	N/A	N/A	N/A	N/A	N/A	The patients are not only related to liver disease, but also cholangitis may be due to viral cholangitis, systemic inflammation response, and hypoxic liver injury
Sanders <i>et al</i>	57	Male	Post-COVID-19 cholangiopathy	Yes	Dilated CBD	N/A	Yes, required	Renal	N/A	N/A	Improved,

[39], 2021			giopathy			with a distal CBD stone		MV. (Tracheostomy & gastrostomy)	impairment required fluid resuscitation			biliary cast removed by ERCP, and bile duct stent and patient referred for cholecystectomy
López Romero-Salazar <i>et al</i> [40], 2022	76	Male	Post-COVID-19 cholangiopathy	Yes, elevated ALT & AST developed AIH and complicated to liver cirrhosis secondary to primary biliary cholangitis (PBC) igg positive, ANA	U/S showed hepatic fibrotic inflammation, dilated lobes, and biliary ducts	N/A	N/A	N/A	N/A	Biopsy showed lobular hepatitis, with intense interface, centrilobular necrosis with lymphoplasmacytic inflammation	N/A	The patient has poor prognosis due to liver cirrhosis, the study emphasizes the hypothesis that AIH induced due to or post COVID-19 vaccination. Patient given UDCA and obeticholic acid
Wall <i>et al</i> [41], 2022	N/A	N/A	Post-COVID-19 cholangiopathy	Yes	N/A	N/A	N/A	N/A	N/A	N/A	N/A	The study showed to avoid using SARS-CoV-2-positive donors for liver transplantation unless there is a justifying indicator such as recipient illness severity
Ghafoor <i>et al</i> [42], 2022	Mean Age 60.5	15 Male patients	Post-COVID-19 cholangiopathy	Yes	N/A	All patients had intrahepatic bile duct strictures and 10 patients had associated upstream dilatation. Fourteen patients showed intrahepatic bile duct beading. One patient had extrahepatic bile duct structuring; 9 patients showed high signal on T2 and diffusion weighted images & 7 patients showed	N/A	N/A	N/A	N/A	N/A	The post-COVID-19 cholangiopathy patients showed on MRI/MRCP multiple intrahepatic bile duct strictures with intrahepatic bile duct beading

												patchy arterial phase hyperenhancement; 2 patients showed biliary casts. Vascular complication, and periportal lymphadenopathy were not seen on MRI/MRCP
Singh <i>et al</i> [43], 2021	57	Male	Post-COVID-19 cholangiopathy	Yes, elevated ALT, AST, GGT, hypergammaglobulinemia and anti-mitochondrial antibody, anti-smooth muscle antibody and anti-double stranded DNA antibodies	N/A	N/A	N/A	N/A	N/A	N/A	N/A	The patient diagnosed with auto immune hepatitis with primary biliary cholangitis overlap syndrome triggered by COVID-19
Seifert <i>et al</i> [44], 2023	N/A	7 patients (3 males & 4 females)	Post-COVID-19 cholangiopathy among 7 patients of 544 patients with cholangitis. 4 patients had SSC due to other reasons	Yes, elevated GGT, Alkaline phosphatase ALP among 7 patients more than 4 patients non COVID-19	N/A	N/A	N/A	N/A	N/A	N/A	N/A	The 7 patients with post-COVID-19 cholangiopathy showed more hepatitis and cholangitis than other group non-COVID cholangitis most probably due to direct cytopathologic effect of COVID virus
Lee <i>et al</i> [45], 2021	64	Male	Post-COVID-19 cholangiopathy	Yes	U/S intrahepatic bile ducts loss	MRI not available	Required MV	Yes, Recovered	Diffuse hepatic injury, onion skinning of the bile ducts and bile duct loss in scattered portal tracts	OLT not done; patient need to be stable for the operation	Not recovered	
Cunha-Silva <i>et al</i> [46], 2023	45	Male	Post-COVID-19 cholangiopathy	Yes, elevated in the first 2-wk AST, ALT, GGT, Alkaline phosphatase post SARS-CoV-2 infection: ANA and anti-smooth muscle-positive. Negative viral hepatitis & anti-mitochondrial antibodies	N/A	No dilatation of biliary ducts	N/A	AKI after recovering 2 wk from COVID-19	Numerous foci of lobular necrosis but with no ductopenia or portal biliary reaction. After 2 mo: Biopsy showed: extensive areas of confluent necrosis,	N/A	The patient is given prednisolone in the first phase, then after 2 mo added azathioprine and UDCA to management	



										hepatocytes regenerating into pseudorosettes and numerous plasma cells, non-suppurative cholangitis all these features diagnosed by PARIS Criteria as AIH-PBC-OS		and showed great response and recovery
Hamid <i>et al</i> [47], 2021	N/A	N/A	Post-COVID-19 cholangiopathy	Yes, elevated AST, ALT, low albumin, and low platelet	N/A	N/A	N/A	N/A	N/A	Endoscopy and ERCP are recommended by WGO	N/A	OLT is advised to be postponed till SARS-CoV-2 infection treated and patient recovered
Kroepfl <i>et al</i> [48]	N/A	2 patients	Post-COVID-19; cholangiopathy	Yes	N/A	N/A	N/A	N/A	N/A	ERCP biopsy showed severely destructed biliary mucosa with ischemia and epithelial roughness	N/A	N/A, early cholangioscopy can confirm the diagnosis
Mayorquin-Aguilar <i>et al</i> [24]	3 Cases 45 52 46	Male Male Female	Post-COVID-19 cholangiopathy	Yes	Not available	Mild intrahepatic; Biliary ductal; Dilatation with; Multifocal strictures or; Beading without; Extrahepatic biliary; Dilatation	Yes, required MV	Yes, recovered	SSC-CIP beading of intrahepatic ducts, bile duct wall thickening with enhancement, and peribiliary diffusion high signal	2 Done OLT, 1 Not done	2 males death; 1 female recovered	
Graciolli <i>et al</i> [49]	63	Male	Post-COVID-19 cholangiopathy	Yes	Not available	Dilations with intercalated stenotic segments in intra and extrahepatic bile ducts and edema of the bile ducts corresponding to inflammation of the adjacent parenchyma	Yes	Not available	Intrahepatocellular cholestasis	Not done	Death, infected ulcer, palliative care	
Keta-Cov research group [50]	Median Age 59 (35-65)	Male Male Male Female	Post-COVID-19 cholangiopathy	Yes, elevated AST, ALTGGT, ALP, total bilirubin all elevated	N/A	Aspects of sclerosing cholangitis, with strictures and dilatations of intrahepatic bile ducts, peribiliary	All patients required M/V	All patients developed acute kidney injury required renal replacement therapy	ERCP showed filling defects in the common bile duct and rarefication of the intrahepatic biliary tract and biopsy showed	N/A	Intravenous ketamine is dose dependant and used for maintenance sedation of patients required	

Zdanowicz <i>et al</i> [51], 2022	Paediatric patient	Female	Post-COVID-19 cholangiopathy	Yes	N/A	cysts and multiple biliary casts	N/A	N/A	biliary obstructions, including cholangiolar proliferation, biliary plugs, portal inflammation with neutrophil infiltrates, extensive biliary fibrosis and cirrhosis	N/A	M/V for acute respiratory distress syndrome ARDS, and showed associated with biliary obstructions, cholestatic liver injury, biliary cirrhosis, and end-stage liver disease, that's the reason the new guidelines is not recommend ketamine especially if prolonged or at higher dose
Schwarz <i>et al</i> [52], 2022	N/A	Male	Post-COVID-19 cholangiopathy	Yes, GGT is elevated in 15 patients with SSC-CIP after lung transplantation out of 40 patients in the study. ALP is elevated after lung transplant	N/A	N/A	15 patients out of 40 developed SSC-CIP underwent lung transplant	N/A	N/A	N/A	Patient developed autoimmune hepatobiliary diseases, autoimmune sclerosing cholangitis ASC which required long-term liver function monitoring
Keskin <i>et al</i> [53], 2022	N/A	15 patients	Post-COVID-19 cholangiopathy	Yes	N/A	N/A	N/A	N/A	N/A	N/A	GGT showed to be a sensitive parameter to predict severity in SSC-CIP
Bartoli <i>et al</i> [54], 2021	44	32 patients	Post-COVID-19 cholangiopathy	Yes, AST, ALT elevated and GGT, ALP elevated more ANA positive, anti-mitochondrial-positive, anti-smooth muscle negative	U/S showed slightly enlarged liver with moderate steatosis and a mildly enlarged spleen	N/A	Yes, required intubation and MV	N/A	N/A	Not done	Technical problems with ECRP were more common in biliary patients with delay group than in those without delay, while 7 pancreatic patients showed

											no difference in ERCP with or without delay of intervention. Technical issues considered such as abundant stone sludge in bile duct, stent migration, <i>etc</i>	
Ferreira <i>et al</i> [55], 2022	N/A	Female	Post-COVID-19 cholangiopathy	Yes	N/A	N/A	N/A	N/A	N/A	Florid ductal lesions, moderate peri-portal fibrosis, portal chronic inflammatory infiltrate	N/A	Patient treated with UDCA and discharged and breathing normally, also treated from Guillain barre syndrome GBS by intravenous immunoglobulin
		4 cases				N/A				ERCP showed beaded appearance of intrahepatic bile ducts and bile casts		One patient undergone stone removal, and one patient complicate with liver cirrhosis, the other two progressed to advanced chronic liver disease
Bütikofer <i>et al</i> [56], 2021	N/A	20 Cases	Post-COVID-19 cholangiopathy	Yes 9 patients with severe cholestasis 11 patients with mild cholestasis	N/A	N/A	N/A	N/A	N/A	Ischemic changes to the perihilar bile ducts	N/A	SSC is more common and severe in critically COVID-19 patients, with prolonged ICU period
Zafar <i>et al</i> [57], 2022	N/A	2 Cases	Post-COVID-19 cholangiopathy	Yes	N/A	N/A	N/A	N/A	N/A	N/A	N/A	Both patients developed SSC post-COVID-19 vaccination, which lead to hepatitis and eventually cholangitis
Otani <i>et al</i> [58], 2022	N/A	N/A	Post-COVID-19 cholangiopathy in some cases of	Yes	N/A	N/A	N/A	N/A	N/A	N/A	N/A	166 cases for endoscopic

166 cases												
Cesar Machado <i>et al</i> [59], 2022	66	Male	Post-COVID-19 cholangiopathy	Yes		Ultrasound showed slight hepatomegaly and no bile duct dilatation	MRI showed biliary cast, also revealed. Diffuse irregularity of intra- and extrahepatic bile ducts, with multiple focal strictures alternating with mild focal dilations of the biliary tree, suggesting a sclerosing cholangiopathy	Yes, required MV	Yes, required haemodialysis	Biopsy showed a prominent bile ductular reaction, cholangiocyte injury, inflammatory infiltrate rich in neutrophils, biliary infarctions, marked cholestasis, and portal fibrosis	Not done OLT, due to poor clinical condition	procedures for causes; Cholangitis, GI bleeding, Obstructive jaundice, neoplasia, COVID-19 led to delay in endoscopic procedures which led to delayed diagnosis of cholangitis, cancers, <i>etc.</i>
Steiner <i>et al</i> [60], 2022	33	Female	Post-COVID-19 cholangiopathy	Yes, elevated liver enzymes AST, ALT, marked elevated GGT, ALP	N/A		MRCP done showed cholangiopathy	Yes hypoxia required intubation and MV, patient developed respiratory distress syndrome in which she was given veno-venous extracorporeal membrane oxygenation	Yes renal failure, and went through haemodialysis frequently	ERCP done showed cholangiopathy	OLT not done	Patient passed away, her clinical condition deteriorated, with severe hypoxia, renal failure, and multi-organ failure
Gourjault <i>et al</i> [61], 2021	55	Male	Post-COVID-19 cholangiopathy	Yes, elevated AST, ALT high GGT, ALP, elevated bilirubin, LDH	N/A		Periportal hypersignal without hepatic biliary dilatation	Yes, Required intubation& MV for 20 d with four sessions prone position	N/A	Interlobular biliary lesions with cholestasis	Waiting list for OLT	Discharged home, he had sphincterotomy and stone removal, planned for OLT

	45	Male			Hepatic steatosis without hepatomegaly or biliary dilatation	Diffuse intrahepatic dilatation and liver steatosis without any focal obstructing lesion	MV for 26 d and sedated with ketamine for 24 d then he was on ECMO for 18 d	Fifteen sessions of hemodialysis			Discharged home, improved, not done OLT
	30	Male			US normal	Progressive irregular intrahepatic ductal dilatation	MV for 12 d with ketamine sedation, then replaced by ECMO for 29 d with 6 sessions of prone position	30 sessions of hemodialysis	Biopsy showed cholestatic hepatitis, bile ducts dystrophy	OLT done 11 mo after his admission	Developed liver failure with ascites, prolonged prothrombin, OLT done
Tafreshi <i>et al</i> [62], 2021	38	Male	Post-COVID-19 cholangiopathy	Yes, mildly elevated AST, ALT and GGT mild bilirubin level	Intrahepatic biliary ductal irregularity and a markedly thickened common bile duct	Diffuse mild intrahepatic biliary distention, marked beading and irregularity & mild irregularity of the extra hepatic common bile duct	Required intubation & MV	N/A	Biopsy showed cholestatic hepatitis with cholangiocyte injury, bile ductular proliferation, canalicular cholestasis	Waiting list for OLT	Improved by treatment, waiting list for OLT
Leonhardt <i>et al</i> [63], 2023	N/A	N/A	Post-COVID-19 cholangiopathy	Yes	N/A	N/A	Yes. Intubated on MV	N/A	N/A	N/A	One patient developed SSC-CIP in every 43 invasive ventilated COVID-19 patients (total 1082 patients)
Zengarini <i>et al</i> [64], 2022	30	Female	Post-COVID-19 cholangiopathy	Yes	N/A	N/A	N/A	N/A	N/A	N/A	Patient developed subacute cutaneous lupus erythematosus post COVID-19 vaccination in patient with PBC
Wendel-Garcia <i>et al</i> [65], 2022	N/A	N/A	Post-COVID-19 cholangiopathy	Yes. High total bilirubin	N/A	N/A	N/A	N/A	N/A	N/A	The study showed 243 patients; 170 Patients infused with ketamine developed post-COVID-19 cholangiopathy while other patients received propofol,

											fentanyl were not associated with cholestatic liver injury
Morão <i>et al</i> [66], 2022	46	Female	Post-COVID-19 cholangiopathy	Yes	N/A	MRCP; liver abscesses, intrahepatic bile duct dilation with multiple strictures and some linear repletion defects at the bifurcation of the common hepatic duct	Intubation with MV 12 d	N/A	ERCP Showed; biliary casts	N/A	N/A
Lee <i>et al</i> [67], 2022	56	Female	Post-COVID-19 cholangiopathy	Yes, hepatitis C, AST, 243, ALT 630, ALP 449, GGT 2765	N/A	N/A	N/A	N/A	Granulomatous cholangitis, nonsuppurative with destruction and proliferation of bile ducts with PBC Also immune infiltrations of CD3 T-cells, CD8 T-cells	N/A	Patient improved and discharged after high dose UDCA treatment, liver enzymes become normal
Nikoupour <i>et al</i> [68], 2020	35	Male	Post-COVID-19 cholangiopathy	Yes	N/A	N/A	N/A	N/A	N/A	OLT done before 3 yr from COVID-19 infection	Two identical twins had COVID-19 infection, both developed PSC, one of them who had OLT showed improvement with mild symptoms, while the other twin had more severe symptoms
	35	Male								Did not have OLT	
Arnstadt <i>et al</i> [69], 2021	62	N/A	Post-COVID-19 cholangiopathy	Yes	Echogenic intraductal longitudinal structures characteristic for intraductal casts and for SSC-CIP	MRCP showed irregular intrahepatic bile ducts	Yes, need long-term ventilation	N/A	Necrotic bile ducts	N/A	N/A
Meersseman <i>et al</i> [70], 2021	Mean age 48-68	Male	Post-COVID-19 cholangiopathy	Yes, elevated GGT, ALP, AST, ALT	N/A	MRCP showed focal strictures in intrahepatic bile ducts with	Yes, intubated & MV then VV-ECMO	Yes, required renal support	ERCP: Patient 1 diffuse beading of the intrahepatic biliary system,	OLT done for patient 1 and 2patient 3 & 4 did not	Patient 1 is doing well, patient 2 died due to septic

						intraluminal sludge and casts				patient 2 & 3 diffuse beading of the intrahepatic biliary ducts, patient 4 focal strictures on the right hepatic duct	undergo OLT	shock and pneumonia, patient 3 have mild SSC-CIP, patient 4 died due to lethal liver hemorrhage
Durazo <i>et al</i> [5], 2021	47	Male	Post-COVID cholangiopathy	Yes	Cholelithiasis without evidence of acute cholecystitis	Mild intrahepatic biliary ductal dilatation with multifocal strictures and beading with intrahepatic dilatation but without extrahepatic biliary dilatation	Yes, off MV on day 29	Yes, recovered	Liver abscess; Bile collection associated with bile duct dilatation with vacuolization and neutrophilia. Endothelial hepatic arteries swelling. Severe portal tract inflammation with Obliterative venopathy	OLT done	Recovered	
Raes <i>et al</i> [71], 2022	64	Male	Post-COVID-19 cholangitis	Yes	N/A	N/A	Yes, MV then venovenous ECMO VV-ECMO	N/A	N/A	N/A	Passed away; patient having CAHA, progressive liver failure, secondary to ischemic cholangitis	
Fajardo <i>et al</i> [72], 2021	24	Female	Post-COVID-19 cholangitis	Yes, GGT, ALP, AST, ALT, bilirubin	US: thickening of the gallbladder without stones	MRI: showed normal biliary tree and wall oedema of the gallbladder	N/A	N/A	Cholangitis of the small bile ducts consisting of a mixed inflammatory infiltrate with lymphocytes, plasma cells and neutrophils, accompanied by eosinophils, localized around and within the bile ducts	Not done OLT	Improved, patient discharged after laparoscopic cholecystectomy and liver biopsy	
Pizarro Vega <i>et al</i> [73], 2023	63 66 60 65 44	Male Female Male Male Female	Post-COVID-19 cholangiopathy	Yes, GGT high in all patients especially in patient NO. 3 to 143 U/L then reached to 1130 U/L and patient 4 reached 3550 U/L. AST is high and higher in patient 4 to 82 U/L and patient 5 to 85 U/L then reached	N/A	MRI showed intrahepatic duct dilations, stenosis without lithiasis, no extrahepatic duct alteration	Yes, required intubation, MV. Pronosupination	Yes, impaired renal function, required vasoactive drugs	No liver biopsy	One patient planned for OLT	All patients treated with UDCA and discharge. 3 patients re-admitted due to complication, patient 4 had pleural	

Knooihuizen <i>et al</i> [74], 2021	68	Male	Post-COVID-19 cholangiopathy KISC	maximum 250 and 148, respectively. And patient 1 reached 1520 U/L. High tot. Bilirubin, ALT, ALP	N/A	MRI showed intrahepatic biliary dilatation with a beaded appearance & dilated common bile duct with distal narrowing	Yes	Yes	Liver biopsy showed minimal infiltration of neutrophils in the portal tract and lobule without cholestasis, also showed portal tract with bile duct injury	Not done	empyema. Patient 5 had cholecystectomy, patient 6 readmitted for acute cholangitis without lithiasis, no patients died during follow up
Zhou <i>et al</i> [75], 2022	54	Female	Post-COVID-19 vaccination leading autoimmune hepatitis	Yes, ALP peaked 2239 U/L, GGT 773 U/L, AST 1260 U/L, ALT 1729 U/L	N/A	N/A	N/A	N/A	Liver biopsy showed interface hepatitis with portal infiltration and discrete presence of rosette formation and apoptotic hepatocytes	Not done	Patient have KISC during intensive sedation, then ceased the KISC is transient, patient for repeat MRCP
Muehlenberg <i>et al</i> [76], 2021	36	Female	Post-COVID-19 cholangiopathy	Yes, AST 581, ALT 588 elevated, GGT, ALP slight elevation, bilirubin 1.4	US of liver and bile duct were normal	N/A	Yes, intubation and MV with antibiotics and catecholamine treatment	N/A	N/A	N/A	Patients have Autoimmune hepatitis AIH post vaccination (Moderna mRNA), treatment given after 2 <sup>nd</sup> dose vaccine with prednisolone PSC treated with UDCA and ERCP
Soldera and Salgado[77], 2021	80	Female	Post-COVID-19 cholangiopathy	Yes, AST 100 U/L, ALT 113 U/L, bilirubin 12 mg/dL	Not Available	Diffuse irregularity of the intrahepatic bile ducts associated with sacular dilations suspicious for cholangiolithic abscesses	Yes	Not available	Intense cytoplasmic vacuolization of cholangiocytes and microvascular alterations	OLT done	Patient done ERCP with papillotomy and foreign body extraction
Rojas <i>et al</i> [78], 2021	62	Male	Post-COVID-19 cholangiopathy	Yes	Resemble SSC (secondary sclerosing cholangitis) but no portal inflammation, dilatation, or fibrosis)	MRI is negative	Yes, off MV on day 30	Yes, recovered	Low periportal inflammatory infiltrate without necrosis but with a severe obstructive cholestatic pattern	Not done	Recovery
Dhaliwal <i>et</i>	29	Female	Post-COVID-19 cholan-	Yes	Not Available	Mild intrahepatic	Not required	No	Filling defects	OLT Done	Not recovered



<i>al</i> [23], 2022			giopathy			biliary ductal dilation. With subtle central biliary enhancement concerning for. Cholangitis along with hypodense material in extrahepatic. Biliary system likely representing transiting gallbladder. Sludge	MV			secondary to multiple large biliary casts (Biliary case syndrome)		
	42	Female		Yes								Recovery with long-term liability and comorbidity
Caballero-Alvarado <i>et al</i> [79], 2023	7 cases	7 cases	Post-COVID-19 cholangiopathy	Yes	Not available	Not available	Not available	Yes, recovered	Secondary sclerosing cholangitis	1 done OLT 6 send for consideration of OLT		One recovered, 6 no data available
Soldera <i>et al</i> [26], 2023	50	One male	Post-COVID-19 cholangiopathy	Yes	Not available	MRI showed intrahepatic sclerosing cholangitis and a dilated cholidium, with no signs of lithiasis (11 mm)	Yes, required MV	Yes, required haemodialysis	ERCP which showed a cast in the format of the external biliary tract, which was removed	Not done OLT		Recovered post cast removal
Franzini <i>et al</i> [80], 2022	65	Male	Post-COVID-19 cholangiopathy	Yes	U/S showed no abnormalities	MRI Not available	Yes, required MV; under Fentanyl, Midazolam, and Ketamine sedation	Yes, required haemodialysis	ERCP revealed rarefaction of intrahepatic bile ducts, and removal of biliary casts	OLT Not done		No improvement
Roda <i>et al</i> [81], 2022	63	Male	Post-COVID-19 cholangiopathy	Yes	Ultrasound results was inconclusive	MRI not done	Yes, required MV, and venovenous extracorporeal membrane oxygenation support (VV-ECMO). And eventually done bilateral lung transplant	Acute renal failure (AKI III); chronic illness neuropathy; several episodes of bacterial superinfections and lastly, PLS, characterized by severe haemolysis	Transjugular hepatic biopsy was performed with histopathological evidence of portal and periportal fibrosis, and intraparenchymal cholestasis with cholangiopathy and vasculopathy	OLT not done, patient did bilateral lung transplant		Not recovered, patient passed away due to Multiorgan failure MOF due to septic shock
Tebar <i>et al</i>	43	Male	Post-COVID-19 cholangiopathy	Yes	Ultrasound	MRI not done	Yes, required	Not available	ERCP, MRCP	Not available		Not available

[82], 2022			giopathy		Not available		MV		Shown: Bile cholestatic, toxic. Cause necrosis of cholangiocytes and stenosis, determining persistent and irreversible biliary obstruction, with rapid progression to liver cirrhosis		
Santisteban Arenas <i>et al</i> [83], 2022	6 cases		Post-COVID-19 cholangiopathy	Yes	Ultrasound not available	Destruction and curling of the pathway, beading of the intrahepatic bile duct	Yes, all 6 cases required MV	1 male not having renal failure or haemodialysis. All other 5 cases have renal failure; 2 females not required haemodialysis; 2 males required haemodialysis; 1 male have renal failure but not required haemodialysis	MRCP/ERCP showed destruction of biliary tract. In three of the six patients underwent liver biopsy, the most frequent findings were the presence of a reaction. Ductular, proliferation of cholangioles, infiltrate. Inflammatory associated with the biliary epithelium with component. Lymphoplasmocyte and polymorphonuclear neutrophils	Not available	1 patient died, 5 other survived with severe comorbidities such as pneumonia, tracheal stenosis, pressure ulcers <i>etc.</i>
	55	Male									
	54	Male									
	62	Male									
	56	Female									
	73	Female									
	34	Male									

ACLD: Advanced chronic liver disease; AIH: Autoimmune hepatitis; AIH-PBC-OS: Auto-immune hepatitis-primary biliary cholangitis overlap syndrome; AKI: Acute kidney injury; ALP: Alkaline phosphatase; ALT: Alanine aminotransferase; ANA: Antinuclear antibodies; AST: Aspartate aminotransferase; CAHA: Cold agglutinin hemolytic anemia; CBD: Common bile duct; CIP: Critically ill patients; CLD: Chronic liver disease; COVID-19: Coronavirus disease 2019; EUS: Endoscopic ultrasound; ECMO: Extracorporeal membrane oxygenation; ERCP: Endoscopic retrograde cholangiopancreatography; GI: Gastrointestinal; GGT: Gamma-glutamyl transpeptidase; IL: Interleukin; KISC: Ketamine-induced sclerosing cholangitis; MRI: Magnetic resonance imaging; MRCP: Magnetic resonance cholangiopancreatography; MV: Mechanical ventilation; N/A: Not applicable; NAFLD: Non-alcoholic fatty liver disease; NASH: Non-alcoholic steatohepatitis; OLT: Orthotopic liver transplantation; PBC: Primary biliary cirrhosis; PLS: Passenger lymphocyte syndrome; PSC: Primary sclerosing cholangitis; SARS-CoV-2: Severe acute respiratory syndrome coronavirus 2; SSC: Secondary sclerosing cholangitis; TNF: Tumor necrosis factor; U/S: Ultrasound; UDCA: Ursodeoxycholic acid; WGO: World Gastroenterology Organization.

enzymes particularly alkaline phosphatase and gamma-glutamyl transpeptidase, and signs of liver dysfunction. Radiology showed bile duct thickening and enhancement, beading of the intrahepatic ducts, and peribiliary enhancement on diffusion. Additionally, every patient had severe respiratory distress syndrome and kidney failure reported as complications. Liver transplantation has been suggested as a potential management option for PCC, although its efficacy as a curative treatment requires further validation. Not all PCC patients require liver transplantation, as some may recover without undergoing this procedure. Studies have demonstrated that liver enzymes, especially alkaline phosphatase, total bilirubin, and gamma-glutamyl transferase, decrease after medical treatment of PCC. While liver transplantation is not suitable for all PCC patients, it remains the most effective option for select cases. Further research, clinical studies, and international collaborations are needed to gain a better understanding of this novel disease and

explore potential treatment avenues.

## ARTICLE HIGHLIGHTS

### Research background

The coronavirus disease 2019 (COVID-19) pandemic, declared by the World Health Organization in March 2020, has had devastating global impacts, resulting in millions of deaths and significant economic and humanitarian losses. Despite vaccination efforts, new variants of the virus continue to pose a threat, hindering control measures. While respiratory symptoms are common in COVID-19, extrapulmonary manifestations and derangement of liver enzymes have been observed. One emerging complication is post-COVID-19 cholangiopathy (PCC), characterized by bile duct inflammation and damage in recovered individuals. PCC presents with symptoms such as abdominal pain, fever, and jaundice, affecting both severe and milder cases. The prevalence and potential drug associations with PCC remain uncertain.

### Research motivation

Understanding post-COVID-19 cholangiopathy is crucial due to its novelty and potential impact on recovered patients. Exploring the clinical presentation and management of PCC can provide valuable insights into its diagnosis and treatment. By addressing the knowledge gaps surrounding this condition, future research can develop effective strategies for patient care and improve outcomes in clinical practice. The significance of solving these problems lies in advancing our understanding of this novel disease and facilitating evidence-based approaches to manage post-COVID-19 cholangiopathy.

### Research objectives

The primary objectives of this systematic review were to comprehensively analyze and synthesize existing evidence on post-COVID-19 cholangiopathy, focusing on the clinical presentation and management approaches documented in reported cases. By realizing these objectives, we provide a comprehensive overview of the current understanding of post-COVID-19 cholangiopathy, identify knowledge gaps, and contribute to the development of effective diagnostic and therapeutic strategies for this condition. The findings from this study can guide future research endeavors, leading to improved patient care and outcomes in the field of post-COVID-19 cholangiopathy.

### Research methods

The research methods employed in this study adhered to the guidelines for preferred reporting items for systematic reviews and meta-analyses protocols. A comprehensive search was conducted in electronic databases (Scopus, Web of Science, and Medline/PubMed) using specified search terms. The search was limited to English, Spanish, and Portuguese language publications without any date restrictions. In addition to database searches, the reference lists of identified studies were manually searched. The inclusion criteria encompassed clinical case reports or case series focusing on post-COVID cholangiopathy, with detailed information on clinical presentation, diagnosis, management, and outcomes. Studies that lacked relevant clinical information or were unrelated to the topic were excluded. Two independent reviewers performed data extraction using a standardized form, and any discrepancies were resolved through discussion or consultation with a third reviewer. The extracted data included variables such as age, sex, clinical presentation, liver and renal function tests, imaging findings, histopathology, liver transplantation status, and outcomes. Data analysis involved descriptive techniques, including frequencies, means, and medians.

### Research results

This systematic review identified a total of 540 patients with post-COVID-19 cholangiopathy, predominantly male (12.7%) and over 50-years-old (12.2%). Elevated liver enzymes were observed in nearly all patients during the acute phase (93.8), persisting in the chronic phase. Total bilirubin levels were elevated in 63.5% of cases, while alkaline phosphatase was 488 (90.3%) and gamma-glutamyl transferase levels consistently exceeded 1000 U/L. Imaging findings revealed biliary ductal dilatation with fibrosis on ultrasound in 41.6% of patients and bile duct thickening with contrast enhancement on MRI in 47.7% of patients. Respiratory failure type 2, associated with acute respiratory distress syndrome, was observed in 41.3% of patients, with 1 patient undergoing lung transplantation. Acute renal injury requiring dialysis or renal transplantation was present in 65.7% of cases. Liver biopsy showed sclerosing cholangitis in 74.4% of patients. Sixteen patients (2.96%) underwent orthotopic liver transplantation, with successful outcomes observed in 93.75% of these cases. These findings provide important insights into the clinical characteristics and complications of post-COVID-19 cholangiopathy, highlighting the need for further research to elucidate its pathogenesis and optimal management strategies.

### Research conclusions

This study proposes several new theories and methods in the field PCC. First, the study suggests that PCC is a serious systemic illness that affects not only the lungs but also the liver. It provides evidence that PCC is characterized by elevated liver enzymes, biliary ductal dilatation, and histopathological findings of secondary sclerosing cholangitis. The study highlights the importance of considering the differential diagnosis, as other diseases may present with similar symptoms, such as ketamine-induced cholangiopathy and ischemic cholangitis. The study emphasizes the diagnostic procedures for PCC. It recommends the use of cholangiography, endoscopic retrograde cholangiopancreatography, or

magnetic resonance cholangiopancreatography to visualize the biliary system and identify characteristic features of PCC, such as pruned tree appearance, beaded ducts, and band-like strictures.

### Research perspectives

The future research in the field of PCC should focus on understanding its pathophysiology, including the mechanisms of bile duct paucity and unique microvascular features. Improving diagnostic procedures through novel imaging techniques and biomarkers is essential for early and accurate detection. Comparative studies with other cholangiopathies can enhance treatment approaches. Additionally, investigating the management and treatment of PCC, including the efficacy of liver transplantation, is crucial. Identifying predictive factors for transplantation and determining long-term prognosis are valuable areas of research. Overall, future studies should deepen our understanding, develop improved diagnostics, and explore effective treatments to enhance patient outcomes. Collaboration among researchers and international efforts will play a vital role in advancing knowledge and management of this disease.

## ACKNOWLEDGEMENTS

We would like to extend our sincere appreciation to the Acute Medicine MSc program at the University of South Wales for their invaluable assistance in our work. We acknowledge and commend the University of South Wales for their commitment to providing advanced problem-solving skills and life-long learning opportunities for healthcare professionals.

## FOOTNOTES

**Author contributions:** All authors contributed to the study concept and design, drafting of the manuscript, data acquisition, analysis and interpretation, and critical revision of the manuscript for important intellectual content.

**Conflict-of-interest statement:** All the authors report no relevant conflicts of interest for this article.

**Open-Access:** This article is an open-access article that was selected by an in-house editor and fully peer-reviewed by external reviewers. It is distributed in accordance with the Creative Commons Attribution NonCommercial (CC BY-NC 4.0) license, which permits others to distribute, remix, adapt, build upon this work non-commercially, and license their derivative works on different terms, provided the original work is properly cited and the use is non-commercial. See: <https://creativecommons.org/licenses/by-nc/4.0/>

**Country/Territory of origin:** United Kingdom

**ORCID number:** Vinicius Remus Ballotin 0000-0002-2659-2249; Lucas Goldmann Bigarella 0000-0001-8087-0070; Jonathan Soldera 0000-0001-6055-4783.

**Corresponding Author's Membership in Professional Societies:** Federação Brasileira De Gastroenterologia; Sociedade Brasileira de Hepatologia.

**S-Editor:** Li L

**L-Editor:** Filipodia

**P-Editor:** Chen YX

## REFERENCES

- 1 Cucinotta D, Vanelli M. WHO Declares COVID-19 a Pandemic. *Acta Biomed* 2020; **91**: 157-160 [PMID: 32191675 DOI: 10.23750/abm.v91i1.9397]
- 2 Cascella M, Rajnik M, Aleem A, Dulebohn SC, Di Napoli R. Features, Evaluation, and Treatment of Coronavirus (COVID-19). 2023 Jan 9. In: StatPearls [Internet]. Treasure Island (FL): StatPearls Publishing; 2023 Jan- [PMID: 32150360]
- 3 Sharma O, Sultan AA, Ding H, Triggler CR. A Review of the Progress and Challenges of Developing a Vaccine for COVID-19. *Front Immunol* 2020; **11**: 585354 [PMID: 33163000 DOI: 10.3389/fimmu.2020.585354]
- 4 Chen N, Zhou M, Dong X, Qu J, Gong F, Han Y, Qiu Y, Wang J, Liu Y, Wei Y, Xia J, Yu T, Zhang X, Zhang L. Epidemiological and clinical characteristics of 99 cases of 2019 novel coronavirus pneumonia in Wuhan, China: a descriptive study. *Lancet* 2020; **395**: 507-513 [PMID: 32007143 DOI: 10.1016/S0140-6736(20)30211-7]
- 5 Durazo FA, Nicholas AA, Mahaffey JJ, Sova S, Evans JJ, Trivella JP, Loy V, Kim J, Zimmerman MA, Hong JC. Post-Covid-19 Cholangiopathy-A New Indication for Liver Transplantation: A Case Report. *Transplant Proc* 2021; **53**: 1132-1137 [PMID: 33846012 DOI: 10.1016/j.transproceed.2021.03.007]
- 6 Xu L, Liu J, Lu M, Yang D, Zheng X. Liver injury during highly pathogenic human coronavirus infections. *Liver Int* 2020; **40**: 998-1004 [PMID: 32170806 DOI: 10.1111/liv.14435]
- 7 Johnson KD, Harris C, Cain JK, Hummer C, Goyal H, Perisetti A. Pulmonary and Extra-Pulmonary Clinical Manifestations of COVID-19. *Front Med (Lausanne)* 2020; **7**: 526 [PMID: 32903492 DOI: 10.3389/fmed.2020.00526]
- 8 Wang D, Hu B, Hu C, Zhu F, Liu X, Zhang J, Wang B, Xiang H, Cheng Z, Xiong Y, Zhao Y, Li Y, Wang X, Peng Z. Clinical Characteristics

- of 138 Hospitalized Patients With 2019 Novel Coronavirus-Infected Pneumonia in Wuhan, China. *JAMA* 2020; **323**: 1061-1069 [PMID: 32031570 DOI: 10.1001/jama.2020.1585]
- 9 **Veerankutty FH**, Sengupta K, Vij M, Rammohan A, Jothimani D, Murali A, Rela M. Post-COVID-19 cholangiopathy: Current understanding and management options. *World J Gastrointest Surg* 2023; **15**: 788-798 [PMID: 37342848 DOI: 10.4240/wjgs.v15.i5.788]
  - 10 **Soldera J**, Bosi GR. Haemophagocytic lymphohistiocytosis following a COVID-19 infection: case report. *J Infect Dev Ctries* 2023; **17**: 302-303 [PMID: 37023430 DOI: 10.3855/jidc.16983]
  - 11 **Yanny B**, Alkhero M, Alani M, Stenberg D, Saharan A, Saab S. Post-COVID-19 Cholangiopathy: A Systematic Review. *J Clin Exp Hepatol* 2023; **13**: 489-499 [PMID: 36337085 DOI: 10.1016/j.jceh.2022.10.009]
  - 12 **Bethineedi LD**, Suvvari TK. Post COVID-19 cholangiopathy - A deep dive. *Dig Liver Dis* 2021; **53**: 1235-1236 [PMID: 34412993 DOI: 10.1016/j.dld.2021.08.001]
  - 13 **Faruqui S**, Okoli FC, Olsen SK, Feldman DM, Kalia HS, Park JS, Stanca CM, Figueroa Diaz V, Yuan S, Dagher NN, Sarkar SA, Theise ND, Kim S, Shanhogue K, Jacobson IM. Cholangiopathy After Severe COVID-19: Clinical Features and Prognostic Implications. *Am J Gastroenterol* 2021; **116**: 1414-1425 [PMID: 33993134 DOI: 10.14309/ajg.0000000000001264]
  - 14 **Page MJ**, McKenzie JE, Bossuyt PM, Boutron I, Hoffmann TC, Mulrow CD, Shamseer L, Tetzlaff JM, Akl EA, Brennan SE, Chou R, Glanville J, Grimshaw JM, Hróbjartsson A, Lalu MM, Li T, Loder EW, Mayo-Wilson E, McDonald S, McGuinness LA, Stewart LA, Thomas J, Tricco AC, Welch VA, Whiting P, Moher D. The PRISMA 2020 statement: an updated guideline for reporting systematic reviews. *BMJ* 2021; **372**: n71 [PMID: 33782057 DOI: 10.1136/bmj.n71]
  - 15 **Yu WL**, Cho CC, Lung PF, Hung EH, Hui JW, Chau HH, Chan AW, Ahuja AT. Ketamine-related cholangiopathy: a retrospective study on clinical and imaging findings. *Abdom Imaging* 2014; **39**: 1241-1246 [PMID: 24934474 DOI: 10.1007/s00261-014-0173-2]
  - 16 **de Tymowski C**, Dépret F, Dudoignon E, Legrand M, Mallet V; Keta-Cov Research Group. Ketamine-induced cholangiopathy in ARDS patients. *Intensive Care Med* 2021; **47**: 1173-1174 [PMID: 34313797 DOI: 10.1007/s00134-021-06482-3]
  - 17 **Batts KP**. Ischemic cholangitis. *Mayo Clin Proc* 1998; **73**: 380-385 [PMID: 9559044 DOI: 10.1016/S0025-6196(11)63706-3]
  - 18 **Tanaka A**. IgG4-Related Sclerosing Cholangitis and Primary Sclerosing Cholangitis. *Gut Liver* 2019; **13**: 300-307 [PMID: 30205418 DOI: 10.5009/gnl18085]
  - 19 **Manganis CD**, Chapman RW, Culver EL. Review of primary sclerosing cholangitis with increased IgG4 levels. *World J Gastroenterol* 2020; **26**: 3126-3144 [PMID: 32684731 DOI: 10.3748/wjg.v26.i23.3126]
  - 20 **Ballotin VR**, Bigarella LG, Riva F, Onzi G, Balbinot RA, Balbinot SS, Soldera J. Primary sclerosing cholangitis and autoimmune hepatitis overlap syndrome associated with inflammatory bowel disease: A case report and systematic review. *World J Clin Cases* 2020; **8**: 4075-4093 [PMID: 33024765 DOI: 10.12998/wjcc.v8.i18.4075]
  - 21 **Brambilla B**, Barbosa AM, Scholze CDS, Riva F, Freitas L, Balbinot RA, Balbinot S, Soldera J. Hemophagocytic Lymphohistiocytosis and Inflammatory Bowel Disease: Case Report and Systematic Review. *Inflamm Intest Dis* 2020; **5**: 49-58 [PMID: 32596254 DOI: 10.1159/000506514]
  - 22 **Chai X**, Hu L, Zhang Y, Han W, Lu Z, Ke A, Zhou J, Shi G, Fang N, Fan J. Specific ACE2 expression in cholangiocytes may cause liver damage after 2019-nCoV infection. 2020 Preprint. Available from: bioRxiv:931766 [DOI: 10.1101/2020.02.03.931766]
  - 23 **Dhaliwal A**, Dhindsa BS, Esquivel RG. COVID Bile Duct: Biliary Cast Syndrome as a Complication of SARS-CoV-2 Infection. *J Gastrointest Surg* 2022; **26**: 1806-1807 [PMID: 35296958 DOI: 10.1007/s11605-022-05297-x]
  - 24 **Mayorquin-Aguilar JM**, Lara-Reyes A, Revuelta-Rodríguez LA, Flores-García NC, Ruiz-Margáin A, Jiménez-Ferreira MA, Macías-Rodríguez RU. Secondary sclerosing cholangitis after critical COVID-19: Three case reports. *World J Hepatol* 2022; **14**: 1678-1686 [PMID: 36157873 DOI: 10.4254/wjh.v14.i8.1678]
  - 25 **Gracioli AM**, De Bortoli BR, Maslonek C, Gremelmier EMC, Henrich CF, Salgado K, Balbinot RA, Balbinot SS, Soldera J. Post-COVID-19 cholangiopathy. *Dig Med Res* 2023. In press [DOI: 10.21037/dmr-22-83]
  - 26 **Soldera J**, Balbinot RA, Balbinot SS. Biliary casts in post-COVID-19 cholangiopathy. *Gastroenterol Hepatol* 2023; **46**: 319-320 [PMID: 36116722 DOI: 10.1016/j.gastrohep.2022.08.008]
  - 27 **Kulkarni AV**, Khelgi A, Sekaran A, Reddy R, Sharma M, Tirumalle S, Gora BA, Somireddy A, Reddy J, Menon B, Reddy DN, Rao NP. Post-COVID-19 Cholestasis: A Case Series and Review of Literature. *J Clin Exp Hepatol* 2022; **12**: 1580-1590 [PMID: 35719861 DOI: 10.1016/j.jceh.2022.06.004]
  - 28 **Roth NC**, Kim A, Vitkovski T, Xia J, Ramirez G, Bernstein D, Crawford JM. Post-COVID-19 Cholangiopathy: A Novel Entity. *Am J Gastroenterol* 2021; **116**: 1077-1082 [PMID: 33464757 DOI: 10.14309/ajg.0000000000001154]
  - 29 **Li S**, Yuan S, Schooling CM, Larsson SC. A Mendelian randomization study of genetic predisposition to autoimmune diseases and COVID-19. *Sci Rep* 2022; **12**: 17703 [PMID: 36271292 DOI: 10.1038/s41598-022-22711-1]
  - 30 **Hunyady P**, Streller L, Rütther DF, Groba SR, Bettinger D, Fitting D, Hamesch K, Marquardt JU, Mücke VT, Finkelmeier F, Sekandarzad A, Wengenmayer T, Bounidane A, Weiss F, Peiffer KH, Schlevogt B, Zeuzem S, Waidmann O, Hollenbach M, Kirstein MM, Kluwe J, Kütting F, Mücke MM. Secondary Sclerosing Cholangitis Following Coronavirus Disease 2019 (COVID-19): A Multicenter Retrospective Study. *Clin Infect Dis* 2023; **76**: e179-e187 [PMID: 35809032 DOI: 10.1093/cid/ciac565]
  - 31 **Weaver M**, McHenry S, Das KK. COVID-19 and Jaundice. *Gastroenterology* 2021; **160**: e1-e3 [PMID: 33039462 DOI: 10.1053/j.gastro.2020.10.006]
  - 32 **Hartl L**, Haslinger K, Angerer M, Semmler G, Schneeweiss-Gleixner M, Jachs M, Simbrunner B, Bauer DJM, Eigenbauer E, Strassl R, Breuer M, Kimberger O, Laxar D, Lampichler K, Halilbasic E, Stättermayer AF, Ba-Ssalamah A, Mandorfer M, Scheiner B, Reiberger T, Trauner M. Progressive cholestasis and associated sclerosing cholangitis are frequent complications of COVID-19 in patients with chronic liver disease. *Hepatology* 2022; **76**: 1563-1575 [PMID: 35596929 DOI: 10.1002/hep.32582]
  - 33 **Duengelhof P**, Hartl J, Rütther D, Steinmann S, Brehm TT, Weltzsch JP, Glaser F, Schaub GM, Sterneck M, Sebode M, Weiler-Normann C, Addo MM, Lütgehetmann M, Haag F, Schramm C, Schulze Zur Wiesch J, Lohse AW. SARS-CoV-2 vaccination response in patients with autoimmune hepatitis and autoimmune cholestatic liver disease. *United European Gastroenterol J* 2022; **10**: 319-329 [PMID: 35289983 DOI: 10.1002/ueg2.12218]
  - 34 **John BV**, Bastaich D, Webb G, Brevini T, Moon A, Ferreira RD, Chin AM, Kaplan DE, Taddei TH, Serper M, Mahmud N, Deng Y, Chao HH, Sampaziotis F, Dahman B. Ursodeoxycholic acid is associated with a reduction in SARS-CoV-2 infection and reduced severity of COVID-19 in patients with cirrhosis. *J Intern Med* 2023; **293**: 636-647 [PMID: 37018129 DOI: 10.1111/joim.13630]
  - 35 **Heucke N**, Keitel V. COVID-19-associated cholangiopathy: What is left after the virus has gone? *Hepatology* 2022; **76**: 1560-1562 [PMID: 35822670 DOI: 10.1002/hep.32668]

- 36 **Bazerbachi F**, Servin-Abad LA, Nassani N, Mönkemüller K. Endosonographic and ERCP findings in COVID-19 critical illness cholangiopathy. *Rev Esp Enferm Dig* 2022 [PMID: 36205332 DOI: 10.17235/reed.2022.9218/2022]
- 37 **Cho JY**, Lee YS, Kim SS, Song DS, Lee JH, Kim JH. Forms of cholangitis to be considered after SARS-CoV-2 infection. *Clin Mol Hepatol* 2022; **28**: 929-930 [PMID: 36096495 DOI: 10.3350/cmh.2022.0260]
- 38 **Yu XQ**, Zhang XX. [Concerns about COVID-19-associated liver injury]. *Zhonghua Gan Zang Bing Za Zhi* 2022; **30**: 473-476 [PMID: 35764538 DOI: 10.3760/cma.j.cn501113-20220408-00182]
- 39 **Sanders D**, Bomman S, Irani S. COVID-19-Induced Bile Duct Casts and Cholangitis: A Case Report. *Cureus* 2021; **13**: e14560 [PMID: 33889467 DOI: 10.7759/cureus.14560]
- 40 **López Romero-Salazar F**, Veras Lista M, Gómez-Domínguez E, Ibarrola-Andrés C, Muñoz Gómez R, Fernández Vázquez I. SARS-CoV-2 vaccine, a new autoimmune hepatitis trigger? *Rev Esp Enferm Dig* 2022; **114**: 567-568 [PMID: 35373571 DOI: 10.17235/reed.2022.8820/2022]
- 41 **Wall AE**, McKenna GJ, Onaca N, Ruiz R, Bayer J, Fernandez H, Martinez E, Gupta A, Askar M, Spak CW, Testa G. Utilization of a SARS-CoV-2-positive donor for liver transplantation. *Proc (Bayl Univ Med Cent)* 2022; **35**: 62-63 [PMID: 34970035 DOI: 10.1080/08998280.2021.1985888]
- 42 **Ghafoor S**, Germann M, Jüngst C, Müllhaupt B, Reiner CS, Stocker D. Imaging features of COVID-19-associated secondary sclerosing cholangitis on magnetic resonance cholangiopancreatography: a retrospective analysis. *Insights Imaging* 2022; **13**: 128 [PMID: 35939241 DOI: 10.1186/s13244-022-01266-9]
- 43 **Singh B**, Kaur P, Maroules M. Autoimmune Hepatitis-Primary Biliary Cholangitis Overlap Syndrome Triggered by COVID-19. *Eur J Case Rep Intern Med* 2021; **8**: 002264 [PMID: 33768072 DOI: 10.12890/2021\_002264]
- 44 **Seifert M**, Kneiseler G, Dechene A. Secondary Sclerosing Cholangitis due to Severe COVID-19: An Emerging Disease Entity? *Digestion* 2023; **104**: 306-312 [PMID: 36889285 DOI: 10.1159/000528689]
- 45 **Lee A**, Wein AN, Doyle MBM, Chapman WC. Liver transplantation for post-COVID-19 sclerosing cholangitis. *BMJ Case Rep* 2021; **14** [PMID: 34446515 DOI: 10.1136/bcr-2021-244168]
- 46 **Cunha-Silva M**, de França EVC, Greca RD, Mazo DFC, da Costa LBE, de Moraes PBS, Veiga CT, Assis-Mendonça GR, Boin IFSF, Stucchi RSB, Sevá-Pereira T. Autoimmune hepatitis and primary biliary cholangitis overlap syndrome after COVID-19. *Autops Case Rep* 2023; **13**: e2023422 [PMID: 37034275 DOI: 10.4322/acr.2023.422]
- 47 **Hamid S**, Alvares da Silva MR, Burak KW, Chen T, Drenth JPH, Esmat G, Gaspar R, LaBrecque D, Lee A, Macedo G, McMahon B, Ning Q, Reau N, Sonderup M, van Leeuwen DJ, Armstrong D, Yurdaydin C. WGO Guidance for the Care of Patients With COVID-19 and Liver Disease. *J Clin Gastroenterol* 2021; **55**: 1-11 [PMID: 33230011 DOI: 10.1097/MCG.0000000000001459]
- 48 **Kroepfl V**, Trembl M, Freund MC, Profanter C. Early detection of COVID-19 cholangiopathy using cholangioscopy-a case report of two critically ill patients. *Eur Surg* 2022; **54**: 326-330 [PMID: 36189108 DOI: 10.1007/s10353-022-00776-6]
- 49 **Gracioli AM**, Bortoli BR, Gremelmier EMC, Henrich CF, Salgado K, Balbinot RA, Balbinot SS, Nesello RGF, Soldera J. Post-COVID-19 Cholangiopathy: a novel clinical entity. *Rev AMRIGS* 2021
- 50 **Keta-Cov research group**. Intravenous ketamine and progressive cholangiopathy in COVID-19 patients. *J Hepatol* 2021; **74**: 1243-1244 [PMID: 33617925 DOI: 10.1016/j.jhep.2021.02.007]
- 51 **Zdanowicz K**, Bobrus-Chociej A, Kopiczko A, Uściłowicz M, Tomczuk-Ostapczuk M, Janica J, Łotowska JM, Białokoz-Kalinowska I, Lebensztejn DM. Autoimmune sclerosing cholangitis might be triggered by SARS-CoV-2 infection in a child - a case report. *Cent Eur J Immunol* 2022; **47**: 183-187 [PMID: 36751389 DOI: 10.5114/ceji.2022.116368]
- 52 **Schwarz S**, Lang C, Harlander M, Štupnik T, Slambrouck JV, Ceulemans LJ, Ius F, Gottlieb J, Kuhnert S, Hecker M, Aigner C, Kneidinger N, Verschuuren EA, Smits JM, Tschernko E, Schaden E, Faybik P, Markstaller K, Trauner M, Jaksch P, Hoetzenecker K. Gamma-glutamyltransferase is a strong predictor of secondary sclerosing cholangitis after lung transplantation for COVID-19 ARDS. *J Heart Lung Transplant* 2022; **41**: 1501-1510 [PMID: 35907758 DOI: 10.1016/j.healun.2022.06.020]
- 53 **Keskin O**, Kav T, Vahabov C, Usta B, Sivri B, Parlak E. Clinical and Endoscopic Consequences of Delay in Stent Exchange Procedures With ERCP During the Covid-19 Pandemic. *Surg Laparosc Endosc Percutan Tech* 2022; **32**: 714-719 [PMID: 36044333 DOI: 10.1097/SLE.0000000000001090]
- 54 **Bartoli A**, Gitto S, Sighinolfi P, Cursaro C, Andreone P. Primary biliary cholangitis associated with SARS-CoV-2 infection. *J Hepatol* 2021; **74**: 1245-1246 [PMID: 33610679 DOI: 10.1016/j.jhep.2021.02.006]
- 55 **Ferreira FB**, Mourato M, Bragança S, Paulo JB, Sismeiro R, Pereira A, Mónica AN, Lourenço LC, Cardoso M. COVID-19-associated secondary sclerosing cholangitis - A case series of 4 patients. *Clin Res Hepatol Gastroenterol* 2022; **46**: 102048 [PMID: 36347499 DOI: 10.1016/j.clinre.2022.102048]
- 56 **Bütikofer S**, Lenggenhager D, Wendel Garcia PD, Maggio EM, Haberecker M, Reiner CS, Brüllmann G, Buehler PK, Gubler C, Müllhaupt B, Jüngst C, Morell B. Secondary sclerosing cholangitis as cause of persistent jaundice in patients with severe COVID-19. *Liver Int* 2021; **41**: 2404-2417 [PMID: 34018314 DOI: 10.1111/liv.14971]
- 57 **Zafar M**, Gordon K, Macken L, Parvin J, Heath S, Whibley M, Tibble J. COVID-19 Vaccination-Induced Cholangiopathy and Autoimmune Hepatitis: A Series of Two Cases. *Cureus* 2022; **14**: e30304 [PMID: 36258805 DOI: 10.7759/cureus.30304]
- 58 **Otani K**, Watanabe T, Higashimori A, Suzuki H, Kamiya T, Shiotani A, Sugimoto M, Nagahara A, Fukudo S, Motoya S, Yamaguchi S, Zhu Q, Chan FKL, Hahn KB, Tablante MC, Prachayakul V, Abdullah M, Ang TL, Murakami K; International Gastrointestinal Consensus Symposium Study Group. A Questionnaire-Based Survey on the Impact of the COVID-19 Pandemic on Gastrointestinal Endoscopy in Asia. *Digestion* 2022; **103**: 7-21 [PMID: 34758472 DOI: 10.1159/000520287]
- 59 **Cesar Machado MC**, Filho RK, El Bacha IAH, de Oliveira IS, Ribeiro CMF, de Souza HP, Parise ER. Post-COVID-19 Secondary Sclerosing Cholangitis: A Rare but Severe Condition with no Treatment Besides Liver Transplantation. *Am J Case Rep* 2022; **23**: e936250 [PMID: 35978523 DOI: 10.12659/AJCR.936250]
- 60 **Steiner J**, Kaufmann-Bühler AK, Fuchsjäger M, Schemmer P, Talakić E. Secondary sclerosing cholangitis in a young COVID-19 patient resulting in death: A case report. *World J Gastrointest Surg* 2022; **14**: 1411-1417 [PMID: 36632122 DOI: 10.4240/wjgs.v14.i12.1411]
- 61 **Gourjault C**, Tarhini H, Rahi M, Thy M, Le Pluart D, Rioux C, Parisey M, Ismael S, Aidibi AAR, Paradis V, Ghosn J, Yazdanpanah Y, Lescure FX, Gervais A. Cholangitis in three critically ill patients after a severe CoVID-19 infection. *IDCases* 2021; **26**: e01267 [PMID: 34485077 DOI: 10.1016/j.idcr.2021.e01267]
- 62 **Tafreshi S**, Whiteside I, Levine I, D'Agostino C. A case of secondary sclerosing cholangitis due to COVID-19. *Clin Imaging* 2021; **80**: 239-242 [PMID: 34364072 DOI: 10.1016/j.clinimag.2021.07.017]

- 63 **Leonhardt S**, Jürgensen C, Frohme J, Grajecki D, Adler A, Sigal M, Leonhardt J, Voll JM, Kruse JM, Körner R, Eckardt KU, Janssen HJ, Gebhardt V, Schmittner MD; Pa-COVID-19 collaborative study group, Frey C, Müller-Ide H, Bauer M, Thibeault C, Kurth F, Sander LE, Müller T, Tacke F. Hepatobiliary long-term consequences of COVID-19: dramatically increased rate of secondary sclerosing cholangitis in critically ill COVID-19 patients. *Hepatol Int* 2023; 1-16 [PMID: 37119516 DOI: 10.1007/s12072-023-10521-0]
- 64 **Zengarini C**, Pileri A, Salamone FP, Piraccini BM, Vitale G, La Placa M. Subacute cutaneous lupus erythematosus induction after SARS-CoV-2 vaccine in a patient with primary biliary cholangitis. *J Eur Acad Dermatol Venereol* 2022; 36: e179-e180 [PMID: 34807495 DOI: 10.1111/jdv.17827]
- 65 **Wendel-Garcia PD**, Erlebach R, Hofmaenner DA, Camen G, Schuepbach RA, Jüngst C, Müllhaupt B, Bartussek J, Buehler PK, Andermatt R, David S. Long-term ketamine infusion-induced cholestatic liver injury in COVID-19-associated acute respiratory distress syndrome. *Crit Care* 2022; 26: 148 [PMID: 35606831 DOI: 10.1186/s13054-022-04019-8]
- 66 **Morão B**, Revés JB, Nascimento C, Loureiro R, Glória L, Palmela C. Secondary Sclerosing Cholangitis in a Critically Ill Patient with Severe SARS-CoV-2 Infection: A Possibly Emergent Entity during the Current Global Pandemic. *GE Port J Gastroenterol* 2022; 27: 1-6 [PMID: 35528723 DOI: 10.1159/000521758]
- 67 **Lee SK**, Kwon JH, Yoon N, Nam SW, Sung PS. Autoimmune liver disease represented as primary biliary cholangitis after SARS-CoV-2 infection: A need for population-based cohort study. *Clin Mol Hepatol* 2022; 28: 926-928 [PMID: 36064307 DOI: 10.3350/cmh.2022.0233]
- 68 **Nikoupour H**, Arasteh P, Gholami S, Nikeghbalian S. Liver transplantation and COVID-19: a case report and cross comparison between two identical twins with COVID-19. *BMC Surg* 2020; 20: 181 [PMID: 32770973 DOI: 10.1186/s12893-020-00837-1]
- 69 **Arnstadt B**, Zillinger C, Treitl M, Allescher HD. Corona again? SSC after a severe COVID-disease. *Z Gastroenterol* 2021; 59: 1304-1308 [PMID: 34666402 DOI: 10.1055/a-1647-3785]
- 70 **Meersseman P**, Blondeel J, De Vlioger G, van der Merwe S, Monbaliu D; Collaborators Leuven Liver Transplant program. Secondary sclerosing cholangitis: an emerging complication in critically ill COVID-19 patients. *Intensive Care Med* 2021; 47: 1037-1040 [PMID: 34185115 DOI: 10.1007/s00134-021-06445-8]
- 71 **Raes M**, De Becker A, Blanckaert J, Balthazar T, De Ridder S, Mekeirele M, Verbrugge FH, Poelaert J, Taccone FS. Venovenous extracorporeal membrane oxygenation in a COVID-19 patient with cold-agglutinin haemolytic anaemia: A case report. *Perfusion* 2022; 2676591221127932 [PMID: 36128692 DOI: 10.1177/02676591221127932]
- 72 **Fajardo J**, Núñez E, Szafranska J, Poca M, Lobo D, Martín B, Hernández D, Roig C, Huerta A, Corominas H, Sánchez-Cabús S, Soriano G. We report a patient who presented intrahepatic cholangitis and cholecystitis after SARS-CoV-2 infection. *J Gastroenterol Hepatol* 2021; 36: 2037 [PMID: 34105805 DOI: 10.1111/jgh.15537]
- 73 **Pizarro Vega NM**, Valer Lopez-Fando P, de la Poza Gómez G, Piqueras Alcol B, Gil Santana M, Ruiz Fuentes P, Rodríguez Amado MA, Bermejo San José F. Secondary sclerosing cholangitis: A complication after severe COVID-19 infection. *Gastroenterol Hepatol* 2023; 46: 462-466 [PMID: 35569544 DOI: 10.1016/j.gastrohep.2022.04.003]
- 74 **Knooihuizen SAI**, Aday A, Lee WM. Ketamine-Induced Sclerosing Cholangitis (KISC) in a Critically Ill Patient With COVID-19. *Hepatology* 2021; 74: 519-521 [PMID: 33226658 DOI: 10.1002/hep.31650]
- 75 **Zhou T**, Fronhoffs F, Dold L, Strassburg CP, Weismüller TJ. New-onset autoimmune hepatitis following mRNA COVID-19 vaccination in a 36-year-old woman with primary sclerosing cholangitis - should we be more vigilant? *J Hepatol* 2022; 76: 218-220 [PMID: 34450237 DOI: 10.1016/j.jhep.2021.08.006]
- 76 **Muehlenberg K**, Tannapfel A, Pech O. [80-year-old patient with jaundice after a severe Covid-19 infection]. *Dtsch Med Wochenschr* 2021; 146: 13-14 [PMID: 33395721 DOI: 10.1055/a-1264-4718]
- 77 **Soldera J**, Salgado K. Ischemic Gastropathy in a Covid-19 pneumonia patient. *Revista da AMRIGS* 65: 58-59
- 78 **Rojas M**, Rodríguez Y, Zapata E, Hernández JC, Anaya JM. Cholangiopathy as part of post-COVID syndrome. *J Transl Autoimmun* 2021; 4: 100116 [PMID: 34485887 DOI: 10.1016/j.jtauto.2021.100116]
- 79 **Caballero-Alvarado J**, Zavaleta Corvera C, Merino Bacilio B, Ruiz Caballero C, Lozano-Peralta K. Post-COVID cholangiopathy: A narrative review. *Gastroenterol Hepatol* 2023; 46: 474-482 [PMID: 36174796 DOI: 10.1016/j.gastrohep.2022.09.004]
- 80 **Franzini TAP**, Guedes MMF, Rocha HLOG, Fleury CA, Bestetti AM, Moura EGH. Cholangioscopy in a post-COVID-19 cholangiopathy patient. *Arq Gastroenterol* 2022; 59: 321-323 [PMID: 35830050 DOI: 10.1590/S0004-2803.202202000-58]
- 81 **Roda S**, Ricciardi A, Maria Di Matteo A, Zecca M, Morbini P, Vecchia M, Chiara Pieri T, Giordani P, Tavano A, Bruno R. Post-acute coronavirus disease 2019 (COVID 19) syndrome: HLH and cholangiopathy in a lung transplant recipient. *Clin Infect Pract* 2022; 15: 100144 [PMID: 35498053 DOI: 10.1016/j.clinpr.2022.100144]
- 82 **Tebar DMCE**, Reis LS, Mineiro GN, Pereira MLDeM, Piassa MLP, Salvajolli RR. Secondary Sclerosing Cholangitis after severe COVID-19: a new possibility in the critically ill patient. *Brazilian Journal of Health Review* 2022; 5: 20-26 [DOI: 10.34119/bjhrv5n1-002]
- 83 **Santisteban Arenas MT**, Osorio Castrillón LM, Guevara Casallas LG, Niño Ramírez SF. [Post-COVID-19 severe cholangiopathy: report of 6 cases]. *Rev Gastroenterol Peru* 2022; 42: 53-57 [PMID: 35896075]



Published by **Baishideng Publishing Group Inc**  
7041 Koll Center Parkway, Suite 160, Pleasanton, CA 94566, USA  
**Telephone:** +1-925-3991568  
**E-mail:** [bpgoffice@wjgnet.com](mailto:bpgoffice@wjgnet.com)  
**Help Desk:** <https://www.f6publishing.com/helpdesk>  
<https://www.wjgnet.com>

