



Retrospective Study

Retrospective analysis of discordant results between histology and other clinical diagnostic tests on *helicobacter pylori* infection

Xiaohua Qi, Kevin Kuan, Tony El Jabbour, Yungtai Lo, Qiang Liu, Yanan Fang

Specialty type: Gastroenterology and hepatology

Provenance and peer review: Unsolicited article; Externally peer reviewed.

Peer-review model: Single blind

Peer-review report's scientific quality classification

Grade A (Excellent): A
Grade B (Very good): 0
Grade C (Good): 0
Grade D (Fair): D
Grade E (Poor): 0

P-Reviewer: Li XB, China

Received: November 14, 2023

Peer-review started: November 14, 2023

First decision: December 5, 2023

Revised: December 24, 2024

Accepted: January 11, 2024

Article in press: January 11, 2024

Published online: February 16, 2024



Xiaohua Qi, Kevin Kuan, Qiang Liu, Department of Pathology, Albert Einstein College of Medicine/Montefiore Medical Center, Bronx, NY 10467, United States

Tony El Jabbour, Department of Pathology, Albert Einstein College of Medicine/Montefiore Medical Center, New York, NY 10467, United States

Yungtai Lo, Department of Epidemiology & Population Health, Albert Einstein College of Medicine, Bronx, NY 10461, United States

Yanan Fang, Department of Pathology, Montefiore Medical Center/Albert Einstein College of Medicine, Bronx, NY 10467, United States

Corresponding author: Yanan Fang, MD, PhD, Associate Professor, Department of Pathology, Montefiore Medical Center/Albert Einstein College of Medicine, 111 East 210th St., Bronx, NY 10467, United States. yfang@montefiore.org

Abstract

BACKGROUND

A reliable test is essential for diagnosing *Helicobacter pylori* (*H. pylori*) infection, and crucial for managing *H. pylori*-related diseases. Serving as an excellent method for detecting *H. pylori* infection, histologic examination is a test that clinicians heavily rely on, especially when complemented with immunohistochemistry (IHC). Additionally, other diagnostic tests for *H. pylori*, such as the rapid urease test (CLO test) and stool antigen test (SA), are also highly sensitive and specific. Typically, the results of histology and other tests align with each other. However, on rare occasions, discrepancy between histopathology and other *H. pylori* diagnostic tests occurs.

AIM

To investigate the discordance between histology and other *H. pylori* tests, the underlying causes, and the impact on clinical management.

METHODS

Pathology reports of gastric biopsies were retrieved spanning August 2013 and July 2018. Reports were included in the study only if there were other *H. pylori* tests within seven days of the biopsy. These additional tests include CLO test, SA, and *H. pylori* culture. Concordance between histopathology and other tests was determined based on the consistency of results. In instances where histology re-

sults were negative while other tests were positive, the slides were retrieved for re-assessment, and the clinical chart was reviewed.

RESULTS

Of 1396 pathology reports were identified, each accompanied by one additional *H. pylori* test. The concordance rates in detecting *H. pylori* infection between biopsy and other tests did not exhibit significant differences based on the number of biopsy fragments. 117 discrepant cases were identified. Only 20 cases (9 with CLO test and 11 with SA) had negative biopsy but positive results in other tests. Four cases initially stained with Warthin-Starry turned out to be positive for *H. pylori* with subsequent IHC staining. Among the remaining 16 true discrepant cases, 10 patients were on proton pump inhibitors before the biopsy and/or other tests. Most patients underwent treatment, except for two who were untreated, and two patients who were lost to follow-up.

CONCLUSION

There are rare discrepant cases with negative biopsy but positive in SA or CLO test. Various factors may contribute to this inconsistency. Most patients in such cases had undergone treatment.

Key Words: *Helicobacter pylori*; Discordance; Gastric biopsy; Histology; Rapid urease test; Stool antigen test; *Helicobacter pylori* culture

©The Author(s) 2024. Published by Baishideng Publishing Group Inc. All rights reserved.

Core Tip: The concordance between histopathology and rapid urease test (CLO test) or stool antigen test (SA) for detecting *Helicobacter pylori* (*H. pylori*) detection is excellent. The agreement between histology and *H. pylori* culture is good. Concordance between histopathology and other tests shows no significant differences based on the number of biopsy fragments. Occasionally, there are rare cases where histology is negative for *H. pylori*, while the CLO test or SA is positive. The causes of such discrepancies may be multifactorial, necessitating a separate analysis for each case with clinical correlation. Most of these cases were subsequently treated for *H. pylori* infection.

Citation: Qi X, Kuan K, El Jabbour T, Lo Y, Liu Q, Fang Y. Retrospective analysis of discordant results between histology and other clinical diagnostic tests on *helicobacter pylori* infection. *World J Gastrointest Endosc* 2024; 16(2): 64-71

URL: <https://www.wjgnet.com/1948-5190/full/v16/i2/64.htm>

DOI: <https://dx.doi.org/10.4253/wjge.v16.i2.64>

INTRODUCTION

Helicobacter pylori (*H. pylori*) infection is directly associated with chronic gastritis, gastric/duodenal ulcer, MALT lymphoma, and gastric adenocarcinoma[1-4]. It is crucial to diagnose *H. pylori* infection accurately and promptly for the clinical management of associated diseases[1]. Various methods for *H. pylori* detection, both invasive and noninvasive, have been developed[1,5]. Invasive tests include histological examination, rapid urease test (CLO test), and *H. pylori* culture. Noninvasive tests include urease breath test (UBT), stool antigen test (SA), and serology testing for *H. pylori* antibody[1,5].

Each diagnostic method has its advantages and disadvantages. No single test is universally acknowledged as a gold standard for detecting *H. pylori* infection[4]. A well accepted approach is combining two or more detection methods[4]. The selection of diagnostic tests depends on various factors, including test availability, sensitivity, specificity, cost, and turnaround time. Although non-invasive tests like UBT offer high sensitivity and specificity for detecting *H. pylori*, upper gastrointestinal (GI) endoscopy with biopsy remains the preferred method, particularly for individuals over 60 or those with alarming symptoms, as recommended by the American College of Gastroenterology[6]. In our hospital, the initial evaluation for symptomatic patients typically involves gastric biopsy and another method. Commonly employed other tests include SA, CLO test, and *H. pylori* culture. Clinicians place particular emphasis on the morphological assessment of gastric biopsy, especially when combined with immunohistochemistry (IHC), considering it one of the most accurate methods. While the results of other clinical tests generally align with biopsy findings, occasional rare discrepancies may pose challenges for clinicians, especially in cases where biopsy results are negative but other clinical tests are positive.

This study aims to clarify and characterize the discrepancies between various diagnostic tests and histological interpretations. A retrospective study is conducted to compare the results of gastric biopsy diagnoses with other *H. pylori* diagnostic tests. Additionally, ancillary tests used for the histologic diagnosis of *H. pylori*-associated gastritis are evaluated.

Table 1 Gastric biopsy cases with ancillary stains

Ancillary stains	Total cases	<i>H. pylori</i> positive	<i>H. pylori</i> negative
WS only	1199	333	866
IHC only	81	20	61
WC/IHC	60	13	47
H&E only	56	26	30
Total	1396	392	1004

WS: Warthin-Starry stain; IHC: Immunohistochemistry stain; *H. pylori*: *Helicobacter pylori*; H&E: Hematoxylin and eosin stain.

MATERIALS AND METHODS

Data collection

The research received approval from the Institutional Review Board of the hospital (2016-6957). Pathology reports of gastric biopsies were extracted from the hospital's in-house database using Clinical Looking Glass (version 4.4.2) spanning from August 2013 to July 2018. Reports were chosen based on specimens originating from the stomach, with comments indicating the presence or absence of *H. pylori* organism. Inclusion criteria mandated the presence of other *H. pylori* diagnostic tests conducted within seven days of the biopsy. Other clinical tests included in the study were: (1) Rapid urease test (CLO test); (2) stool antigen test (SA); and (3) *H. pylori* culture. In instances of multiple tests within a two-week window, the result closest to the biopsy date was considered. Data extracted from the reports included the number of stomach biopsy fragments collected during endoscopy, procedure dates, *H. pylori* status, and the stains used for histologic diagnosis. Test results were considered concordant when both biopsy and clinical tests provided the same diagnosis for *H. pylori* infection; otherwise, they were labeled as discordant. In cases where a negative biopsy with a positive clinical test were identified, histologic slides were retrieved for re-assessment, and the patient's chart was reviewed.

Statistical analysis

The inter-test agreement between histology and another diagnostic test (CLO test, *H. pylori* culture, or stool test) for detecting *H. pylori* infection was assessed utilizing the kappa statistic. An excellent agreement was defined as a kappa value ≥ 0.75 , fair to good agreement as a kappa value between 0.4 and 0.75, and poor agreement as a kappa value < 0.4 . Concordance referred to the alignment between histology and another diagnostic test on *H. pylori* detection, with the concordance rate calculated as the number of concordant cases divided by the total number of cases. Differences in concordance rates among various diagnostic tests with histology in detecting *H. pylori* infection were assessed using chi-square tests. Statistical analyses were conducted using SAS version 9.4 (SAS Inc., Cary, NC, United States), and p-values of 0.05 or less were deemed statistically significant.

RESULTS

A total of 1396 pathology reports were identified. The majority of biopsies ($n = 1199$) were stained solely with Warthin-Starry (WS) stain. Only a small number of cases were reported with *H. pylori* IHC stain only ($n = 81$), both WS and IHC stains ($n = 60$), or no special stain used ($n = 56$) (Table 1). Among them, 392 cases tested positive for *H. pylori* through morphological examination, with WS stain, and/or with IHC. Each biopsy was accompanied by only one additional *H. pylori* test (CLO test, SA, or *H. pylori* culture). Both CLO test and *H. pylori* culture were invasive, conducted on the day of the biopsy. SA was performed within seven days of the biopsy. The summary of additional test results (CLO test, SA, or *H. pylori* culture) is presented in Table 2.

The overall concordance rate between histology and other diagnostic tests was high ($n = 1279$; 91.6%). CLO test and stool antigen tests demonstrated significantly higher concordance rates with biopsy in detecting *H. pylori* infection compared to *H. pylori* culture (95.6% for CLO test vs 92.2% for SA vs 87.5% for culture; $P < 0.001$) (Table 2). The estimated kappa statistic for assessing agreement in identifying *H. pylori* infection between histology and other diagnostics were 0.86 for CLO test (95% CI: 0.81–0.92; Table 3), 0.77 for stool antigen test (95% CI: 0.68–0.86; Table 4), and 0.72 for culture (95% CI: 0.66–0.78; Table 5) respectively.

The correlation between concordance rates and the number of biopsy fragments was also examined (Figure 1). The number of biopsy fragments exhibited considerable variation across cases, ranging from 1 to 6 or more: 83 cases (1 fragment), 321 cases (2 fragments), 229 cases (3 fragments), 262 cases (4 fragments), 132 cases (5 fragments), and 364 cases (6 fragments and above). Additionally, 5 cases lacked information on fragment numbers. Notably, the concordance rates in detecting *H. pylori* infection between biopsy and other clinical diagnostic tests did not differ significantly by the number of fragments (88.0% vs 93.5% vs 92.1% vs 92.7% vs 93.2% vs 89.2%, $P = 0.268$; Figure 1).

The majority of cases exhibiting discordance were those with a positive biopsy but negative results in other *H. pylori* tests (97 cases). Among these cases, a significant proportion involved bacterial culture (70 cases). Additionally, there were

Table 2 Concordance rate between histology and three other *Helicobacter pylori* tests

Other <i>H. pylori</i> test	CLO test	SA test	<i>H. pylori</i> culture
Total cases	528	306	562
<i>H. pylori</i> positive cases	104	66	145
<i>H. pylori</i> negative cases	424	240	417
<i>H. pylori</i> positivity rate	19.8%	21.5%	25.8%
Concordance cases	505	282	492
Discordance cases	23	24	70
Concordance rate with histology	95.6%	92.1%	87.5%

H. pylori: *Helicobacter pylori*; CLO test: Campylobacter-like organism (rapid urease test); *H. pylori* culture: *Helicobacter pylori* culture.

Table 3 Assessment of concordance between histology and rapid urease test

	CLO test positive	CLO test negative	Total
Histology positive	95	14	109
Histology negative	9	410	419
Total	104	424	528

CLO test: Campylobacter-like organism (rapid urease test).

Table 4 Assessment of concordance between histology and stool antigen test

	SA positive	SA negative	Total
Histology positive	55	13	68
Histology negative	11	227	238
Total	66	240	306

SA: Stool antigen test.

Table 5 Assessment of concordance between histology and *Helicobacter pylori* culture

	<i>H. pylori</i> Culture positive	<i>H. pylori</i> Culture negative	Total
Histology positive	145	70	215
Histology negative	0	347	347
Total	145	417	562

H. pylori culture: *Helicobacter pylori* culture.

14 instances of negative CLO tests and 13 cases with negative SA tests, despite a positive histological diagnosis. Conversely, there were only 20 cases with negative biopsy results but positive results in other tests (SA or CLO test; Tables 3-5). All 20 cases were reported to exhibit chronic inactive inflammation on histological examination, with one case also displaying focal active gastritis. No atrophy was observed in any case. Sixteen cases were available for reassessment, with IHC staining performed on those cases not previously tested. In this reevaluation, four cases were found to be positive for *H. pylori* by IHC, despite previous reports indicating negativity. A review of the original H&E slides and WS stains for these four cases revealed the presence of rare and/or morphologically atypical *H. pylori* organisms. Among them, all four cases showed inactive chronic gastritis, and one exhibited focal chronic active gastritis. Additionally, it was observed that three of these patients were under proton pump inhibitor (PPI) treatment at the time of biopsy. Consequently, these four cases were excluded from subsequent assessment. Among the remaining 16 'true' discrepant cases, only four cases had four or more fragments from gastric biopsy, while 12 had three fragments or fewer submitted for histologic examination.

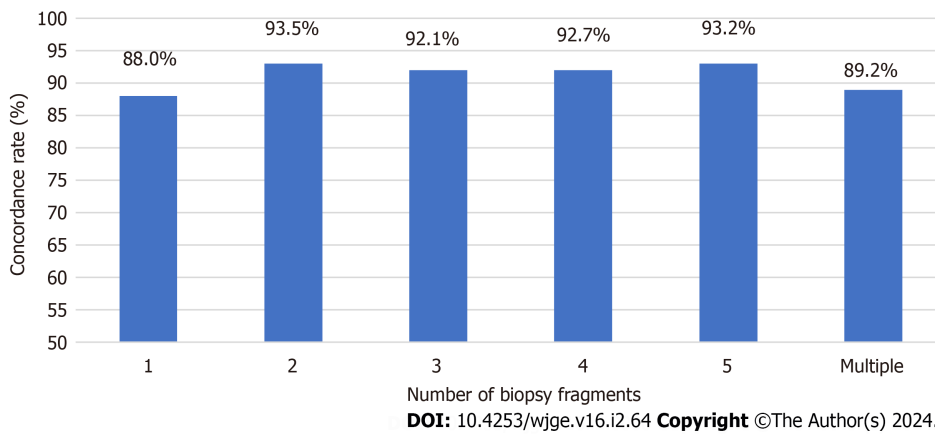


Figure 1 Concordance rate between histology and other *Helicobacter pylori* tests based on numbers of biopsy fragments. Multiple: 6 fragments and up. Concordance rate is labeled on top of each column.

Ten cases were on PPI either when biopsied and/or tested for SA (Table 6); six were on PPI when biopsied but not tested for SA; three were on PPI when biopsied and tested; while one was on PPI only when tested for SA but not biopsied. Additionally, three cases (case 8, 9, and 15) were on antibiotics in addition to PPI when biopsied, as the treatment (triple or quadruple therapy) was initiated after a positive SA result a few days before the biopsy procedure. The majority of patients received treatment for *H. pylori* infection, with the exception of two patients who were untreated, and two patients who were lost to follow-up (Table 6). According to the clinical chart, the decision for treatment was determined by various factors, including clinical presentation, endoscopy findings, pathology results other than *H. pylori* infection status, and occasionally repeated biopsy or other *H. pylori* tests (as observed in cases 13 and 15).

DISCUSSION

While histology is commonly regarded as the preferred method for symptomatic patients[6,7], other *H. pylori* diagnostic tests are equally crucial, often being more convenient, less invasive, and cost-effective, yet maintaining high sensitivity and specificity[4]. Discrepancies between biopsies and the results of other *H. pylori* diagnostic tests can occasionally arise. No single test is considered the gold standard alone[4]. Nevertheless, clinicians prioritize the morphological assessment of gastric biopsies, especially when augmented with immunohistochemistry, considering it as one of the most accurate approaches. Negative clinical test results may be deemed false negatives when the corresponding biopsy is positive. However, the discrepancy between a negative biopsy and a positive clinical test result can pose a challenge for physicians. This study's objective is to elucidate and characterize the discordance between histopathology and other clinical diagnostic tests in determining *H. pylori* status.

The CLO test, SA test, and *H. pylori* bacterial culture were selected for comparison with histology, as they are the most employed tests in conjunction with upper GI endoscopy at our hospital. Both the CLO test and SA test exhibit high sensitivity and specificity, while *H. pylori* culture has nearly 100% specificity with slightly lower sensitivity[4]. Our findings indicate excellent agreement between histology and the CLO test and stool antigen test (with Kappa values exceeding 0.75). *H. pylori* culture demonstrates a slightly lower but still commendable concordance rate (Kappa value of 0.72) mainly due to its higher false negative rate.

The sensitivity and diagnostic accuracy of *H. pylori* are impacted by the sampling during biopsy. It is recommended by the Sydney protocol[8] to submit four biopsy samples for *H. pylori* detection: Two from the antrum and two from the body. An additional sample from incisura angularis is advised for gastritis characterization[3,8]. In our study, most cases have less than five biopsy fragments submitted (Figure 1), and there is no available data regarding the origin of these fragments. Interestingly, the number of gastric samples obtained during each endoscopy did not significantly influence the concordance rate between histological diagnosis and other *H. pylori* tests in our study. However, it is essential to note that concordance does not equate to test accuracy, as concordant results can be either false positives or false negatives. Treatment status at the time of testing is unknown, and both results could be affected by PPI or antibiotics, even if they are concordant.

Most cases have WS stain for histologic diagnosis, as WS stains were automatically ordered from 2013 to 2015 at our hospital. WS stain was preferred over *H. pylori* IHC stain due to its lower cost and quicker turnaround time. Recent studies indicate that ancillary stains provide little additional benefits to H&E stains for *H. pylori* detection[2,9], particularly in cases without inflammation. Since 2016, there have been no further automated orders for special stains on GI biopsy in our laboratory, informed by both literature findings and our own experiences. In our investigation of discrepant cases, four biopsy cases initially reported as negative for *H. pylori* later revealed *H. pylori* organisms through IHC. All four cases exhibited inactive chronic gastritis with one displayed focal active chronic gastritis. Upon re-examination of the H&E slides and WS stains, rare and/or morphologically atypical *H. pylori* organisms were identified. Notably, three patients were noted to be on PPI, potentially altering bacterial appearance and making identification challenging with H&E and

Table 6 Discrepant cases with negative histology but positive rapid urease test or stool antigen test

Cases #	No. of biopsy specimens	Histology test results		Clinical tests		Treated for <i>H. pylori</i>
		WS/IHC	On PPI/Antibiotics when biopsied	Pos. Clinical Tested	On PPI/Antibiotics when tested	
1	3	Neg/Neg	NA	CLO	NA	Yes
2	2	Neg/Neg	NA	CLO	NA	Yes
3	3	Neg/Neg	NA	CLO	NA	NA
4	2	Neg/Neg	NA	CLO	NA	NA
5	2	Neg/Pos	No	CLO	No	No
6	2	Neg/Neg	Yes ¹	SA	Yes ¹	Yes
7	1	Neg/Neg	No	SA	Yes ¹	Yes
8	M	NP/Neg	Yes ²	SA	No	Yes
9	3	Neg/Neg	Yes ²	SA	No	Yes
10	M	Neg/Pos	Yes ¹	SA	Yes ¹	Yes
11	4	Neg/Pos	Yes ¹	SA	Yes ¹	Yes
12	3	NP/Neg	No	SA	No	No
13	M	Neg/Neg	Yes ¹	SA	No	No
14	2	NP/Neg	Yes ¹	SA	No	Yes
15	1	NP/Neg	Yes ²	SA	No	Yes
16	2	Neg/Pos	Yes ¹	SA	No	Yes

¹PPI only.²PPI and antibiotics.

WS: Warthin-Starry stain; IHC: Immunohistochemistry; *H. pylori*: *Helicobacter pylori*; CLO: Campylobacter-like organism (rapid urease test); SA: Stool antigen test; PPI: Proton pump inhibitor; NA: Not available; Neg: Negative; Pos: Positive; M: Multiple (6 fragments and up).

special stains[10,11]. In this case, immunohistochemistry would help identify rare and/or morphological atypical *H. pylori* organisms in cases with other evidence of *H. pylori* and inflammatory mucosa.

There are 16 discrepant cases, excluding 4 instances where *H. pylori* was detected by IHC after initially being negative by H&E and WS. Several factors may contribute to the disparity between a negative biopsy and a positive CLO test or SA test. Firstly, the presence of organisms may be reduced or absent due to medications such as PPI and/or antibiotics[12]. Additionally, these medications can alter the appearance of bacteria, making recognition challenging[3,11]. Among the patients, 10 were on PPI before the biopsy procedure and/or other *H. pylori* tests, with the majority (6 cases) only taking PPI before biopsy, not before other *H. pylori* tests. For these 6 cases, results from other *H. pylori* tests are more likely reliable than histology. Secondly, sampling may contribute to the discrepancy, with 12 out of 16 cases having three fragments or fewer. Although the overall number of gastric samples does not significantly affect the concordance rate, as discussed previously, this may differ when patients are on PPI, particularly if they were on PPI for one test but not for another. Lastly, some results could be false positives from CLO test or SA tests, as both can yield false positive results[13-16].

It is important to note that despite conflicting results presented to clinicians, most patients received treatment without additional testing, except in two cases. This could be attributed to multiple factors, including limited test availability, insurance coverage constraints, challenges in discontinuing medications to minimize testing interference, or delays in treatment. The choice to pursue treatment is influenced by various factors, including clinical symptoms, endoscopic observations, pathology findings other than *H. pylori* infection status, and occasionally the repetition of biopsies or other *H. pylori* tests.

CONCLUSION

Our findings demonstrated that both CLO test and SA tests exhibit high concordance rates with histological diagnoses. The concordance rate between histology and *H. pylori* culture is slightly lower, primarily attributed to the lower sensitivity of the *H. pylori* culture assay. Importantly, the concordance rate shows no significant difference by the number of fragments obtained during the biopsy procedure. There are rare instances of discrepancies, where *H. pylori* diagnosis is negative by histology but positive by CLO test or stool antigen test. Multiple factors may contribute to these discrep-

ancies. Even though histological examination showed negative results for *H. pylori* in these cases with discrepancies, most patients still received treatment. Correlating with clinical history, past laboratory results, and follow-up testing may assist in clinical management.

ARTICLE HIGHLIGHTS

Research background

Determining *Helicobacter pylori* (*H. pylori*) status is essential in the management of *H. pylori*-related diseases. No single test is universally recognized as the gold standard alone. Typically, symptomatic patients at our hospital undergo upper GI endo-scopy with biopsy, often accompanied by an additional *H. pylori* test. The results generally align with each other, although discrepancies arise occasionally.

Research motivation

The clinician places particular emphasis on gastric biopsy results, especially when supplemented with immunohistochemistry (IHC), often considering it the most accurate. Rare cases where biopsy results are negative while other clinical tests show positivity can present challenges for clinicians.

Research objectives

The goal of this retrospective study is to examine the discordance between histopathology and alternative *H. pylori* tests, explore the underlying causes, and assess the implications for clinical management.

Research methods

Pathology reports of gastric biopsies were retrospectively retrieved from August 2013 to July 2018. Inclusion in the study required the presence of other *H. pylori* tests within seven days of the biopsy, including rapid urease test (CLO test), stool antigen test (SA), and *H. pylori* culture. The concordance between histopathology and other tests was evaluated based on result consistency. In cases where histology was negative while other tests showed positivity, the slides underwent reassessment, and the clinical chart was examined.

Research results

1396 pathology reports were identified, each accompanied by one additional *H. pylori* test. The concordance rates between biopsy and other tests did not show significant differences based on the number of biopsy fragments. 117 discrepant cases were identified. Only 20 cases (9 with CLO test and 11 with SA) had negative biopsy but positive results in other tests. Four cases initially stained with Warthin-Starry stain turned out to be positive for *H. pylori* with subsequent IHC staining. Among the remaining 16 true discrepant cases, 10 patients were on proton pump inhibitors before the biopsy and/or other tests. Most patients underwent treatment, except for two who were untreated, and two patients who were lost to follow-up.

Research conclusions

Our findings reveal that both SA and CLO test demonstrate high concordance rates with histological diagnoses. The concordance rate between histology and *H. pylori* culture is slightly lower, mainly due to the lower sensitivity of the *H. pylori* culture assay. Importantly, the concordance rate remains consistent regardless of the number of gastric biopsy fragments. Rare instances of discrepancies exist, where *H. pylori* diagnosis is negative by histology but positive by SA or CLO test. Multiple factors may contribute to the discordance. Despite histological examination showing negative results for *H. pylori* in these cases with discrepancies, most patients still received treatment. Correlation with clinical history, past laboratory results, and follow-up testing may aid in clinical management.

Research perspectives

This retrospective study was conducted at a singular tertiary medical center. It would be intriguing to conduct similar retrospective research in other hospitals to compare discordance rates between histology and other *H. pylori* tests and variations in clinical management.

FOOTNOTES

Co-first authors: Xiaohua Qi and Kevin Kuan.

Author contributions: Qi X and Kuan K contributed equally to this work; Fang Y and Liu Q designed the research study; Qi X and Kuan K performed the data extraction; Kuan K, Qi X, Jabbour T, Liu Y, and Fang Y performed the data analysis and interpretation of the results; Fang Y, Kuan K, and Qi X wrote the manuscript, Lo Y is a Biostatistics professor and performed the statistical analysis; Fang Y, Kuan K and Qi X revised the manuscript; and all authors read and approved the final version.

Institutional review board statement: This study was reviewed and approved by the Albert Einstein College of Medicine Institutional Review Board (IRB No: 2016-6957).

Informed consent statement: This is a retrospective study with a focus on quality assurance (QA). The institutional review board (IRB) granted a waiver of consent.

Conflict-of-interest statement: All the authors declare no conflicts of interest for this article.

Data sharing statement: De-identified dataset available from the corresponding author at yfang@montefiore.org. Participants gave informed consent for data sharing.

Open-Access: This article is an open-access article that was selected by an in-house editor and fully peer-reviewed by external reviewers. It is distributed in accordance with the Creative Commons Attribution NonCommercial (CC BY-NC 4.0) license, which permits others to distribute, remix, adapt, build upon this work non-commercially, and license their derivative works on different terms, provided the original work is properly cited and the use is non-commercial. See: <https://creativecommons.org/licenses/by-nc/4.0/>

Country/Territory of origin: United States

ORCID number: Xiaohua Qi 0000-0003-3706-7586; Kevin Kuan 0000-0001-6818-2179; Tony El Jabbour 0000-0002-6823-1919; Yungtai Lo 0000-0002-2694-4830; Qiang Liu 0009-0001-5769-1397; Yanan Fang 0000-0002-1112-9569.

Corresponding Author's Membership in Professional Societies: College of American Pathologists, 1231720.

S-Editor: Liu JH

L-Editor: A

P-Editor: Xu ZH

REFERENCES

- 1 Wang YK, Kuo FC, Liu CJ, Wu MC, Shih HY, Wang SS, Wu JY, Kuo CH, Huang YK, Wu DC. Diagnosis of *Helicobacter pylori* infection: Current options and developments. *World J Gastroenterol* 2015; **21**: 11221-11235 [PMID: 26523098 DOI: 10.3748/wjg.v21.i40.11221]
- 2 Batts KP, Ketover S, Kakar S, Krasinskas AM, Mitchell KA, Wilcox R, Westerhoff M, Rank J, Gibson J, Mattia AR, Cummings OW, Davison JM, Naini BV, Dry SM, Yantiss RK; Rodger C Haggitt Gastrointestinal Pathology Society. Appropriate use of special stains for identifying *Helicobacter pylori*: Recommendations from the Rodger C. Haggitt Gastrointestinal Pathology Society. *Am J Surg Pathol* 2013; **37**: e12-e22 [PMID: 24141174 DOI: 10.1097/PAS.0000000000000097]
- 3 Lee JY, Kim N. Diagnosis of *Helicobacter pylori* by invasive test: histology. *Ann Transl Med* 2015; **3**: 10 [PMID: 25705642 DOI: 10.3978/j.issn.2305-5839.2014.11.03]
- 4 Patel SK, Pratap CB, Jain AK, Gulati AK, Nath G. Diagnosis of *Helicobacter pylori*: what should be the gold standard? *World J Gastroenterol* 2014; **20**: 12847-12859 [PMID: 25278682 DOI: 10.3748/wjg.v20.i36.12847]
- 5 Ricci C, Holton J, Vaira D. Diagnosis of *Helicobacter pylori*: invasive and non-invasive tests. *Best Pract Res Clin Gastroenterol* 2007; **21**: 299-313 [PMID: 17382278 DOI: 10.1016/j.bpg.2006.11.002]
- 6 Chey WD, Leontiadis GI, Howden CW, Moss SF. ACG Clinical Guideline: Treatment of *Helicobacter pylori* Infection. *Am J Gastroenterol* 2017; **112**: 212-239 [PMID: 28071659 DOI: 10.1038/ajg.2016.563]
- 7 Malik GM, Mubarak M, Kadla SA. *Helicobacter pylori* Infection in Endoscopic Biopsy Specimens of Gastric Antrum: Laboratory Diagnosis and Comparative Efficacy of Three Diagnostic Tests. *Diagn Ther Endosc* 1999; **6**: 25-29 [PMID: 18493521 DOI: 10.1155/DTE.6.25]
- 8 Dixon MF, Genta RM, Yardley JH, Correa P. Classification and grading of gastritis. The updated Sydney System. International Workshop on the Histopathology of Gastritis, Houston 1994. *Am J Surg Pathol* 1996; **20**: 1161-1181 [PMID: 8827022 DOI: 10.1097/0000478-199610000-00001]
- 9 Panarelli NC, Ross DS, Bernheim OE, Landzberg ZB, Schuetz AN, Jenkins SG, Landzberg BR, Jessurun J, Yantiss RK. Utility of ancillary stains for *Helicobacter pylori* in near-normal gastric biopsies. *Hum Pathol* 2015; **46**: 397-403 [PMID: 25582501 DOI: 10.1016/j.humpath.2014.11.014]
- 10 Goldstein NS. Chronic inactive gastritis and coccoid *Helicobacter pylori* in patients treated for gastroesophageal reflux disease or with *H. pylori* eradication therapy. *Am J Clin Pathol* 2002; **118**: 719-726 [PMID: 12428792 DOI: 10.1309/LJ4D-E2LX-7UMR-YMTH]
- 11 Chan WY, Hui PK, Leung KM, Chow J, Kwok F, Ng CS. Coccoid forms of *Helicobacter pylori* in the human stomach. *Am J Clin Pathol* 1994; **102**: 503-507 [PMID: 7524304 DOI: 10.1093/ajcp/102.4.503]
- 12 Graham DY, Genta R, Evans DG, Reddy R, Clarridge JE, Olson CA, Edmonds AL, Siepman N. *Helicobacter pylori* does not migrate from the antrum to the corpus in response to omeprazole. *Am J Gastroenterol* 1996; **91**: 2120-2124 [PMID: 8855733]
- 13 Gisbert JP, Pajares JM. Stool antigen test for the diagnosis of *Helicobacter pylori* infection: a systematic review. *Helicobacter* 2004; **9**: 347-368 [PMID: 15270750 DOI: 10.1111/j.1083-4389.2004.00235.x]
- 14 Kodama M, Murakami K, Okimoto T, Fukuda Y, Shimoyama T, Okuda M, Kato C, Kobayashi I, Fujioka T. Influence of proton pump inhibitor treatment on *Helicobacter pylori* stool antigen test. *World J Gastroenterol* 2012; **18**: 44-48 [PMID: 22228969 DOI: 10.3748/wjg.v18.i1.44]
- 15 Tepes B. Comparison of two invasive diagnostic tests for *Helicobacter pylori* after antimicrobial therapy. *Scand J Gastroenterol* 2007; **42**: 330-332 [PMID: 17354112 DOI: 10.1080/00365520601009778]
- 16 Uotani T, Graham DY. Diagnosis of *Helicobacter pylori* using the rapid urease test. *Ann Transl Med* 2015; **3**: 9 [PMID: 25705641 DOI: 10.3978/j.issn.2305-5839.2014.12.04]



Published by **Baishideng Publishing Group Inc**
7041 Koll Center Parkway, Suite 160, Pleasanton, CA 94566, USA
Telephone: +1-925-3991568
E-mail: office@baishideng.com
Help Desk: <https://www.f6publishing.com/helpdesk>
<https://www.wjgnet.com>

