

Prediction of lymph node metastasis and sentinel node navigation surgery for patients with early-stage gastric cancer

Atsuo Shida, Norio Mitsumori, Hiroshi Nimura, Yuta Takano, Taizou Iwasaki, Muneharu Fujisaki, Naoto Takahashi, Katsuhiko Yanaga

Atsuo Shida, Norio Mitsumori, Hiroshi Nimura, Yuta Takano, Taizou Iwasaki, Muneharu Fujisaki, Naoto Takahashi, Katsuhiko Yanaga, Department of Surgery, Jikei University School of Medicine, Tokyo 105-8461, Japan

Author contributions: Shida A wrote the paper; Mitsumori N, Nimura H, Iwasaki T, Fujisaki M, Takahashi N and Yanaga K performed the collected the data; all the authors contributed to this manuscript.

Conflict-of-interest statement: Authors declare no conflict of interests for this article.

Open-Access: This article is an open-access article which was selected by an in-house editor and fully peer-reviewed by external reviewers. It is distributed in accordance with the Creative Commons Attribution Non Commercial (CC BY-NC 4.0) license, which permits others to distribute, remix, adapt, build upon this work non-commercially, and license their derivative works on different terms, provided the original work is properly cited and the use is non-commercial. See: <http://creativecommons.org/licenses/by-nc/4.0/>

Manuscript source: Invited manuscript

Correspondence to: Atsuo Shida, MD, PhD, Department of Surgery, Jikei University School of Medicine, 3-25-8, Nishi-shinbashi, Minato-ku, Tokyo 105-8461, Japan. atsuoshida@ybb.ne.jp
Telephone: +81-3-34331111
Fax: +81-3-54724140

Received: March 26, 2016
Peer-review started: March 29, 2016
First decision: May 12, 2016
Revised: May 22, 2016
Accepted: July 6, 2016
Article in press: July 6, 2016
Published online: September 7, 2016

Abstract

Accurate prediction of lymph node (LN) status is crucially important for appropriate treatment planning in patients with early gastric cancer (EGC). However, consensus on patient and tumor characteristics associated with LN metastasis are yet to be reached. Through systematic search, we identified several independent variables associated with LN metastasis in EGC, which should be included in future research to assess which of these variables remain as significant predictors of LN metastasis. On the other hand, even if we use these promising parameters, we should realize the limitation and the difficulty of predicting LN metastasis accurately. The sentinel LN (SLN) is defined as first possible site to receive cancer cells along the route of lymphatic drainage from the primary tumor. The absence of metastasis in SLN is believed to correlate with the absence of metastasis in downstream LNs. In this review, we have attempted to focus on several independent parameters which have close relationship between tumor and LN metastasis in EGC. In addition, we evaluated the history of sentinel node navigation surgery and the usefulness for EGC.

Key words: Early-stage gastric cancer; Sentinel node navigation surgery; Prediction of lymph node metastasis

© **The Author(s) 2016.** Published by Baishideng Publishing Group Inc. All rights reserved.

Core tip: In this review, we have attempted to focus on several independent parameters which have close relationship between tumor and lymph node metastasis in early gastric cancer. In addition, we evaluated the usefulness of sentinel node navigation surgery (SNNS)

for patients with gastric cancer, in particular technical procedure of SNNS using Infrared Ray Electronic Endoscopes combined with Indocyanine Green injection.

Shida A, Mitsumori N, Nimura H, Takano Y, Iwasaki T, Fujisaki M, Takahashi N, Yanaga K. Prediction of lymph node metastasis and sentinel node navigation surgery for patients with early-stage gastric cancer. *World J Gastroenterol* 2016; 22(33): 7431-7439 Available from: URL: <http://www.wjgnet.com/1007-9327/full/v22/i33/7431.htm> DOI: <http://dx.doi.org/10.3748/wjg.v22.i33.7431>

INTRODUCTION

Newly developing patients with gastric cancer are estimated as 951000 per year and is the fifth most common cancer in the world^[1]. The chance of detecting early gastric cancer (EGC) is increasing especially in South Korea and Japan thanks to development in function of endoscopy and the national screening systems^[2-5]. In Japan and South Korea, patients with EGC has been blessed with superior prognosis after surgical treatment^[5]. In general, lymph node (LN) metastasis in patients with EGC has been reported about 10%-15%, and it is one of the strongest prognostic parameters^[1,6-8]. Gastrectomy with D2 lymphadenectomy is recognized as a standard surgical procedure for patients with advanced gastric cancer according to the Dutch trial^[9]. Standard D2 lymphadenectomy is appropriate procedure for patients with advanced gastric cancer. On the other hand, more limited lymphadenectomy such as D1 or D1+ for patients with EGC is also available according to the Japanese Gastric Cancer Association^[10]. The relationship between pathological parameters and LN metastasis for patients with EGC has been deeply inquired. Meanwhile, the connection between preoperative parameters and LN metastasis of EGC has not been fully investigated^[11-14]. Furthermore, the involvement between preoperative and postoperative diagnostic parameters has not been widely evaluated.

The "less invasive" theory behind sentinel LN (SLN) biopsy concept has benefits based on the limitation of morbidity because of avoiding unnecessary LN dissection. At least theoretically, combination of SLN and less invasive surgical procedures such as laparoscopic surgery seems attractive. SNNS has potential to change the current surgical treatment of gastric cancer.

The aim of this review is to clarify the reliability of preoperative prediction of LN metastasis for patients with EGC and evaluate the clinical usefulness of SNNS.

PREOPERATIVE PREDICTION OF LN METASTASIS OF EGC

Mönig *et al*^[15] investigated 1253 LNs of 31 specimens

and reported that the mean diameter of the LNs which is negative for metastasis was 4.1 mm. On the contrary, mean diameter of LNs which is positive for metastasis was 6.0 mm. Eighty percent of LNs which is negative for metastasis were less than 5 mm in diameter. However 55% of LNs which is positive for metastasis were less than 5 mm in diameter. In addition, 71% of patients who had LN metastasis had at least one node that was 10 mm or greater in diameter. Furthermore, 70% of patients who were free for LN metastasis had at least one node that was 10 mm or greater in diameter. According to these results, they concluded that size of LN is not a reliable parameter for LN metastasis in patients with gastric cancer. In this point, prediction of LN metastasis using CT can't be trustworthy examination for EGC. Fluorodeoxyglucose positron emission tomography (FDG-PET) and EUS are alternative methods for detecting LN metastasis. FDG-PET is a useful preoperative diagnostic instrument to investigate metastasis. However, it has been reported that FDG-PET is not reliable tool to predict LN metastasis because of the low sensitivity^[16-18]. In addition, accuracy of prediction for LN presence by EUS was only 64%^[19]. These reports suggest that FDG-PET and EUS are not credible tool to predict LN metastasis up to now. Nakagawa *et al*^[20] analyzed 1042 patients with EGC who underwent gastrectomy with standard LN dissection. They constructed two receiver operating characteristics (ROC) curves consisting of postoperative independent factors and preoperative independent factors to predict LN metastasis. Comparing with areas produced by the two ROC curves, they investigated which is more reliable factors to predict LN metastasis. As a result, produced areas under the ROC curve made of postoperative parameters including pathological data was 0.824. However, the area under the ROC curve made of preoperative factors obtained from CT or endoscopic examination was 0.660. Hence, they concluded that prediction of LN metastasis for EGC using preoperative parameters is not credible as compared with using postoperative factors^[20].

RELATIONSHIP BETWEEN PATHOLOGICAL PARAMETERS AND LN METASTASIS

Many studies have been carried out to evaluate relationship between pathological parameters and LN metastasis in EGC. We have surveyed numerous published articles which describe an association between pathological parameters and LN metastasis in EGC after year 2001. From these articles, we selected 28 articles (Table 1), which investigated relationships between pathological risk factors and LN metastasis in EGC at least using multiple variate analysis. Song *et al*^[21] have demonstrated that increased submucosal vascularity, histological differentiation, invasion of tumor cells into the muscularis mucosae had signifi-

Table 1 Published articles which refer to independent risk factors for lymph node metastasis of early gastric cancer after 2001

Ref.	Year	Country	Number of patients	Independent parameters which affect LN metastasis	Odds ratio	95%CI
Folli <i>et al</i> ^[40]	2001	Japan	m: 285, sm: 215	Tumor size	1.34	1.13-1.59
				Tumor depth (pT1b <i>vs</i> pT1a)	2.29	1.56-3.36
				Histological differentiation (Diffuse <i>vs</i> Intestinal)	5.70	2.88-11.31
				Histological differentiation (Mixed <i>vs</i> Intestinal)	4.19	1.89-9.32
				Kodama Type (Pen A <i>vs</i> Not Pen A)	1.36	1.17-1.58
Amioka <i>et al</i> ^[26]	2002	Japan	sm: 139	Lymphatic invasion	3.48	1.17-10.40
				VEGF-C (positive <i>vs</i> negative)	4.18	1.38-12.70
Abe <i>et al</i> ^[41]	2002	Japan	m: 136, sm: 178	Gender (female <i>vs</i> male)	3.23	1.33-7.88
				Tumor size (≥ 20 mm <i>vs</i> < 20 mm)	3.39	1.26-9.13
				Tumor depth (pT1b <i>vs</i> pT1a)	4.94	1.49-16.27
				Lymphovascular invasion	7.54	3.01-19.04
Matsuzaki <i>et al</i> ^[42]	2003	Japan	sm: 92	Volume of lesions	1.27	2.49-13.51
				Abe <i>et al</i> ^[43]	2003	Japan
Tumor depth (pT1b <i>vs</i> pT1a)	29.20	3.9-216.3				
Song <i>et al</i> ^[21]	2004	South Korea	m: 120	Lymphatic invasion	50.80	8.1-317.3
				Lymphatic invasion	21.39	10.41-43.95
Park <i>et al</i> ^[22]	2004	South Korea	sm: 105	Tumor depth (sm massive <i>vs</i> sm shallow)	2.56	1.30-5.03
				Tumor size (> 40 mm)	4.80	1.05-22.06
Hyung <i>et al</i> ^[44]	2004	South Korea	m: 295, sm: 271	Tumor depth (> 2000 μ m)	6.81	1.36-34.17
				Histological differentiation (Undifferentiated <i>vs</i> Differentiated)	2.28	1.14-4.56
				Tumor size (≥ 20 mm <i>vs</i> < 20 mm)	1.045	1.36-5.93
				Tumor depth (pT1b <i>vs</i> pT1a)	3.68	1.67-8.13
Son <i>et al</i> ^[45]	2005	South Korea	sm: 248	Lymphovascular invasion	26.56	12.77-55.23
				Lymphatic invasion	21.39	10.41-43.96
				Tumor depth (sm massive <i>vs</i> sm shallow)	2.56	1.30-5.03
Lo <i>et al</i> ^[46]	2007	Taiwan	m: 272, sm: 203	Lymphovascular invasion	8.61	4.43-16.72
				Tumor depth (pT1b <i>vs</i> pT1a)	3.05	1.47-6.33
				Tumor size	1.68	1.13-2.51
Kunisaki <i>et al</i> ^[47]	2007	Japan	sm: 615	Tumor size (40 mm < 80 mm <i>vs</i> < 20 mm)	2.71	1.31-5.61
				Tumor size (≥ 80 mm <i>vs</i> < 20 mm)	3.20	1.02-10.09
				Lymphatic invasion	15.92	9.52-26.63
An <i>et al</i> ^[6]	2007	South Korea	sm: 1043	Tumor size (20 mm < 40 mm <i>vs</i> < 10 mm)	1.88	1.03-3.45
				Tumor size (≥ 40 mm <i>vs</i> < 10 mm)	1.96	1.34-2.88
				Lymphatic invasion	8.41	5.76-12.29
Yi Kim <i>et al</i> ^[24]	2007	South Korea	m: 9, sm: 51	Lymphatic invasion	8.11	1.61-40.77
				E-Cadherin (abnormal expression <i>vs</i> normal expression)	2.62	0.917-7.457
Li <i>et al</i> ^[48]	2008	South Korea	m: 356, sm: 270	Tumor size (≥ 20 mm <i>vs</i> < 20 mm)	2.04	1.12-3.73
				Tumor depth (pT1b <i>vs</i> pT1a)	2.84	1.48-5.44
				Lymphovascular invasion	15.11	7.41-30.80
				Tumor depth (500-1000 μ m invasion to submucosa)	14.69	2.54-85.09
Park <i>et al</i> ^[49]	2008	South Korea	Only poorly diff. adenocarcinoma m: 118, sm: 116	Tumor depth (1000-2000 μ m invasion to submucosa)	6.20	1.57-24.52
				Tumor depth (> 2000 μ m invasion to submucosa)	6.37	1.35-30.14
				Tumor size (> 30 mm in diameter)	4.53	1.13-18.20
				Lymphovascular invasion	12.63	4.05-39.37
Shen <i>et al</i> ^[50]	2009	China	sm: 144	Histological differentiation (Undifferentiated <i>vs</i> Differentiated)	2.70	1.18-6.17
				Tumor size (≥ 20 mm <i>vs</i> < 20 mm)	2.93	1.32-6.54
Morita <i>et al</i> ^[51]	2009	Japan	sm: 70	Tumor size	1.04	1.01-1.08
				Lymphatic invasion	5.22	1.84-20.74
				VEGF-C (positive <i>vs</i> negative)	3.31	1.00-9.95
Kunisaki <i>et al</i> ^[52]	2009	Japan	m: 269, sm: 304	Tumor size (≥ 20 mm <i>vs</i> < 20 mm)	3.34	1.39-8.01
				Tumor depth (SM1 <i>vs</i> M)	2.96	1.03-8.52
				Tumor depth (SM2 <i>vs</i> M)	4.53	1.69-12.18
				Lymphovascular invasion	9.37	4.78-18.37
Sung <i>et al</i> ^[53]	2010	Taiwan	m: 293, sm: 263	Tumor size (≥ 2 mm in diameter <i>vs</i> < 2 cm)	2.28	1.20-4.17
				Lymphatic invasion	27.20	10.3-74.8
Lee <i>et al</i> ^[54]	2010	South Korea	m: 39, sm: 85	Tumor depth (pT1b <i>vs</i> pT1a)	4.91	2.44-9.89
				Lymphatic invasion	15.33	5.06-46.44
				Tumor size (≥ 30 mm <i>vs</i> < 30 mm)	4.16	1.52-11.45
				Tumor depth (M/SM1 <i>vs</i> SM2/SM3)	3.11	1.21-7.98
Lim <i>et al</i> ^[55]	2011	South Korea	sm: 163	Intratatumoral vessel density	3.57	1.20-10.64
				Lymphovascular invasion	4.57	1.74-12.24
				Macroscopic type (elevated <i>vs</i> flat)	9.09	1.75-50.0
				Macroscopic type (elevated <i>vs</i> depressed)	5.89	1.69-20.0
				Macroscopic type (elevated <i>vs</i> mixed)	20.00	0.00-2.70

Lee <i>et al</i> ^[56]	2012	South Korea	Only poorly diff. adenocarcinoma m: 510, sm: 495	Tumor size (≥ 20 mm <i>vs</i> < 20 mm)	2.47	1.39-4.40
				Tumor depth (pT1b <i>vs</i> pT1a)	2.42	1.46-3.99
Ren <i>et al</i> ^[57]	2013	China	m: 122, sm: 80	Lymphatic invasion	6.50	4.14-10.19
Fujii <i>et al</i> ^[23]	2013	Japan	sm: 130	Tumor depth (pT1b <i>vs</i> pT1a)	2.74	2.32-3.17
				Lymphatic invasion	8.07	NA
Shida <i>et al</i> ^[27]	2014	Japan	sm: 145	Lymphocytic infiltration (absent <i>vs</i> present)	7.94	NA
				Lymphatic invasion	3.11	1.71-5.67
				Vascular invasion	2.44	1.05-5.67
Lee <i>et al</i> ^[12]	2015	South Korea	m: 847	Tumor size	1.36	1.10-1.69
				Lymphovascular invasion	27.52	7.40-102.20
				Ulceration (present <i>vs</i> absent)	7.54	1.90-29.90
Park <i>et al</i> ^[25]	2015	South Korea	sm: 756	Undifferentiated type of component (present <i>vs</i> absent)	4.39	1.08-17.89
				Tumor size (≥ 2 cm in diameter <i>vs</i> < 2 cm)	1.57	1.04-2.36
				Tumor depth (sm2 <i>vs</i> sm1)	2.96	1.55-5.64
				Tumor depth (sm3 <i>vs</i> sm1)	2.91	1.61-5.29
				Lymphovascular invasion,	7.45	4.93-11.25
				Negative for EB virus	4.24	1.26-14.32
Feng <i>et al</i> ^[58]	2016	China	m: 339, sm: 237	Tumor depth	2.94	1.82-4.77
				Ulceration (present <i>vs</i> absent)	2.55	1.21-5.38
				Lymphovascular invasion	4.40	1.19-16.3

cant relation to LN metastasis in intramucosal gastric carcinoma. Depth of tumor invasion and tumor size had also significant correlation with LN metastasis in EGC^[22]. Furthermore, An *et al*^[6] also demonstrated that lymphatic system invasion and tumor size had strong relationship to LN metastasis in submucosa invading EGC with submucosal invasion. Of the 28 articles, 23 (82.1%) authors concluded lymphatic invasion or lymphovascular invasion as independent risk factors for LN metastasis and tumor depth and tumor size were also confirmed as LN risk factors in 17 (60.7%) articles, respectively. These results are suggesting that lymphovascular invasion, tumor depth and tumor size are strong predictors of LN metastasis for EGC. Furthermore, Fujii *et al*^[23] described that lymphatic invasion and absence of clear lymphoid follicle formation at the site of submucosal invasion (lymphocystic infiltration) were independent risk factors for LN metastasis. Immunohistochemical (IH) research is also useful for predicting LN metastasis. Yi Kim *et al*^[24] demonstrated that abnormal expression of E-cadherin and lymphatic invasion were independent, statistically significant parameters which is associated with LN metastasis for patients with EGC. Recently, Park *et al*^[25] revealed not only larger tumor size (greater than 2 cm), deeper level of submucosal invasion, lymphovascular invasion but also Epstein-Barr virus negativity were independent risk factors for LNM in submucosa invaded EGC using a large series ($n = 756$) of patients with EGC. In addition, Amioka *et al*^[26] investigated clinicopathological relationship between Vascular Endothelial Growth Factor (VEGF) - C expression in submucosa-invading gastric carcinoma and LN metastasis. They demonstrated VEGF-C expression in submucosa-invading gastric carcinoma had significant correlation to LN metastasis.

LN METASTASIS PREDICTING SCORE

One hundred forty-five consecutive patients with submu-

cosa-invaded EGC were analyzed using multivariate analysis, and a formula which predicts LN metastasis was developed by linear discriminant analysis. Additionally, prospective validation study was carried out to estimate if the formula is reliable to predict LN metastasis. Lymphatic system invasion and venous system invasion were selected as independent parameters correlated with LN metastasis for EGC. The LN metastasis predicting formula was developed using these two factors by linear discriminant analysis. The formula is as follows: $Y = 0.12 \times (\text{venous system invasion: } 0, 1, 2 \text{ or } 3) + 0.19 \times (\text{lymphatic system invasion: } 0, 1, 2, \text{ or } 3) - 0.14$. If $Y > 0$, we judge that a patient with gastric cancer is susceptible LN metastasis. Prospective study demonstrated that sensitivity and specificity rates of this formula were 70% and 61.6%, respectively^[27]. Flow chart for submucosa-invading gastric cancer after ESD is shown in Figure 1. This flow chart is indicating that if resected tumor through ESD invaded 500 μm below the muscularis mucosae, the LN metastasis predicting score is available. $Y > 0$ indicates that the tumor in question would be prone to LN metastasis. We defined patients who are satisfied with $Y > 0$ as a high-risk group (HRG) for LN metastasis and $Y < 0$ patients as a low-risk group (LRG) for LN metastasis. The flow chart means patients with HRG should undergo additional conventional gastrectomy. However, we think that less invasive treatment like as SNNS is more desirable for patients with LRG.

Fujii *et al*^[23] investigated 130 submucosa-invaded gastric cancer. Absence of lymphoid infiltration and lymphatic system invasion were selected as independent significant factors which affect LN metastasis. They also developed LN metastasis predicting score and advocated a scoring system for additional gastrectomy following ESD based on prediction of LN metastasis (Figure 2). Lymphoid infiltration and the presence of lymphatic system invasion were scored as follows: +2 for lymphatic system invasion and -2 for involvement of lymphocystic infiltration, which was considered as a LN

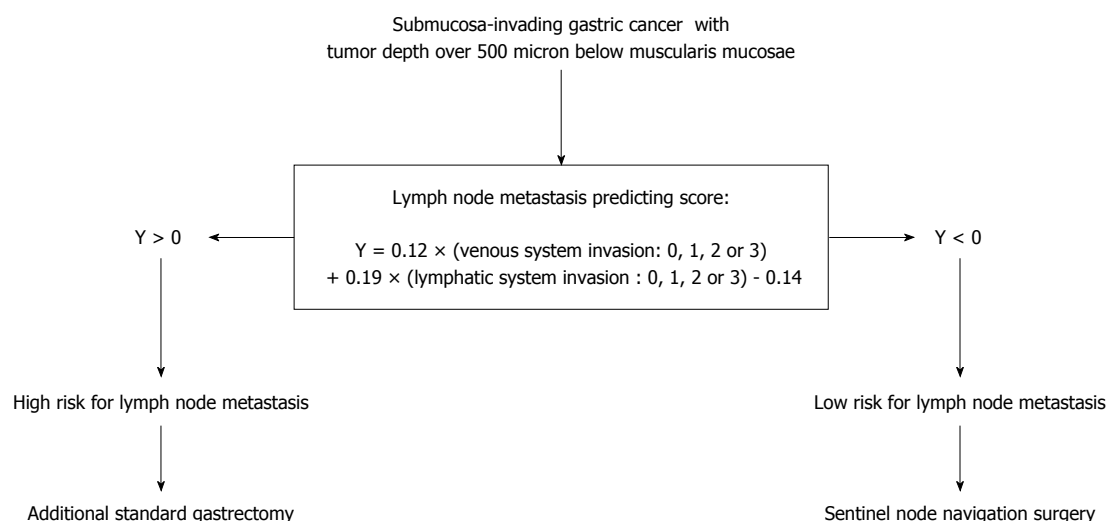


Figure 1 Flow chart for submucosa-invading gastric cancer after ESD. Quoted from Prediction of lymph node metastasis in patients with submucosa-invading early gastric cancer. Adapted from Ref. [27].

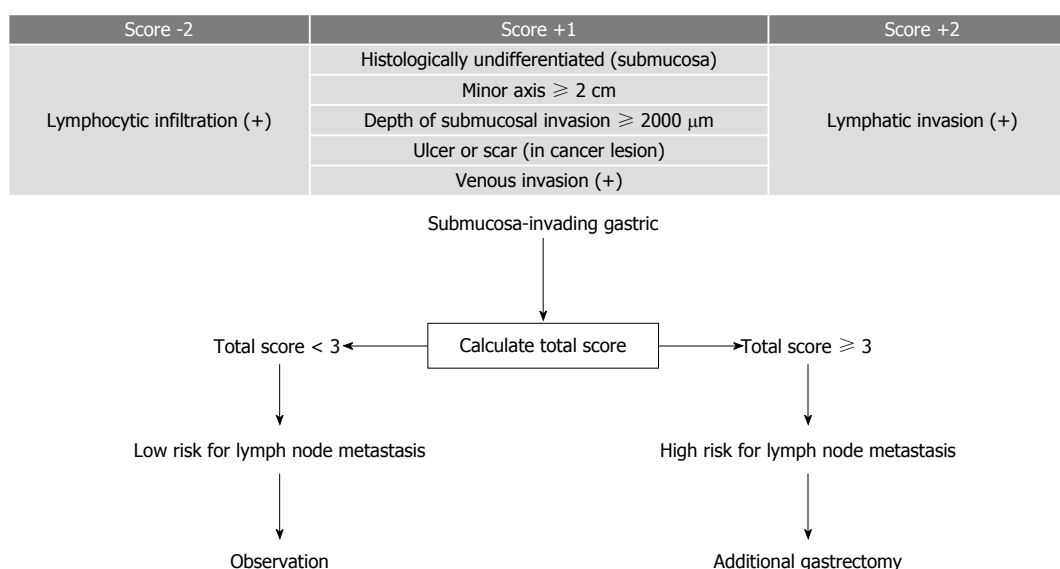


Figure 2 Scoring to predict lymph node metastasis and scoring system for additional gastrectomy following endoscopic resection based on prediction of lymph node metastasis. Quoted from Pathological factors related to lymph node metastasis of submucosally invasive gastric cancer: criteria for additional gastrectomy after endoscopic resection. Adapted from Ref. [23].

metastasis-inhibiting parameter. Next five pathological factors [minor axis length ≥ 2 cm, submucosal invasion depth $\geq 2000 \mu\text{m}$, histological classification (undifferentiated) of submucosal cancer at the site of invasion, ulceration or scar in the lesion, and venous invasion] were scored +1 each when present. They concluded that a patient with total score 3 and more should be treated as high risk for LN metastasis and such patients are recommended to undergo additional gastrectomy. On the other hand, patients with total score less than 3 should be considered as low risk for LN metastasis and they don't need to undergo additional gastrectomy.

These predictive scores and treatment of flow chart after ESD seem innovative and original strategy for EGC. However, we need further additional clinical trials

to validate clinical usefulness of the flow charts.

SNNS AS A SOLUTION TO PREDICT LN METASTASIS OF EGC

In spite of these constant efforts to predict LN metastasis using pathological parameters, it has been still difficult to predict LN metastasis accurately. Meanwhile, SNNS for EGC may become another possible and promising solution to resolve this problem. From early 2000s, articles which focused on SNNS for EGC have been published. Hiratsuka *et al.*^[28] demonstrated the usefulness of indocyanine green (ICG) for SNNS in particular T1 gastric cancer because of the high successful rate to predict SLNs. Kitagawa *et al.*^[29]

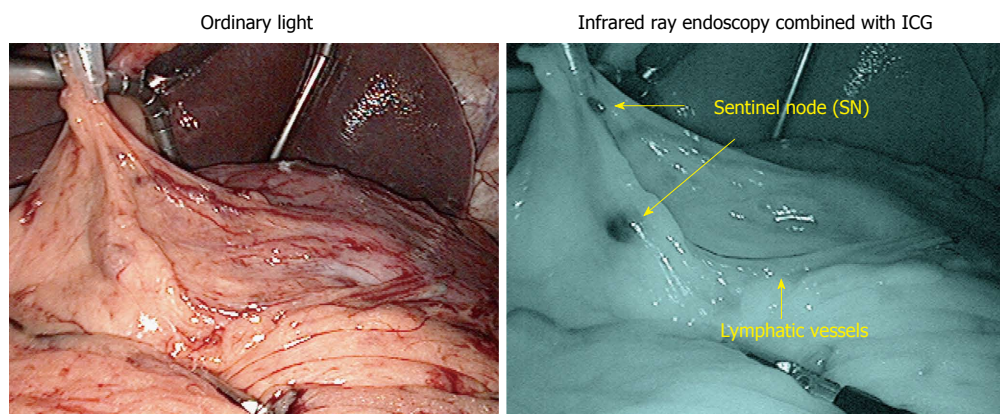


Figure 3 Sentinel node navigation surgery using infrared ray electronic endoscopy. ICG: Indocyanine green.

showed the effectiveness of radio-guided surgery using gamma detection probe technology for SNNS. Technetium-99m-radiolabelled tin colloid was injected endoscopically before the surgery, and radioactive SNs were identified with a gamma probe. They concluded that the radioisotope is useful even for obese patients because it remains for enough time in the SNs after injection. In addition, Miwa *et al.*^[30] demonstrated the results of a regional multicenter clinical trial of SN mapping for gastric cancer using the dye-guided method. This was the first multicenter trial of SN mapping for gastric cancer. Miwa demonstrated that sentinel lymphatic basins contain truly positive nodes, even in cases with a false negative SN biopsy. Hence, they concluded that the sentinel lymphatic basins dissection are adequate procedure for LN dissection in patients with EGC.

We have reported the clinical usefulness of infrared ray electronic endoscopy (IREE) combined with ICG to detect illuminated SLN in patients with gastric cancer and duodenal tumors as compared with dye alone (Figure 3)^[31-37]. Infrared ray has a wave length of around 805 nm. It is able to penetrate fatty tissues up to a depth from 3 to 5 mm. In brief, before the ICG injection, the gastrocolic ligament is opened using ultrasonic coagulation incision device without disrupting the gastro-epiploic vessels. After that 0.5 mL ICG (5 mg/mL; Diagnogreen; Daiichi Pharmaceutical, Tokyo, Japan) is injected endoscopically in four points of the submucosa surrounding the tumor with an endoscopic puncture needle. Twenty minutes after the injection, SN's stained with ICG were observed with the naked eye and with IREE (Olympus Optical, Tokyo, Japan).

Nimura *et al.*^[31] reported SNNS for gastric cancer by IREE with ICG injection for the first time. They investigated 84 patients with gastric cancer and 11 of the 84 patients had LN metastasis. All of the 11 patients were detected by IREE with ICG injection. However, SLNs detected by ICG injection alone did not include metastasis in 4 of the 11 patients. This result seems to support the usefulness of IREE with ICG injection as compared to ICG injection alone.

In addition, Kelder *et al.*^[33] investigated 212 patients with gastric cancer who underwent SNNS by IREE with ICG injection. The detection rate and sensitivity of SLNs by IREE with ICG injection were 99.5% and 97%, respectively. Meanwhile, those of SLNs with ICG injection alone were 85.8% and 48.4%. Predominance of SLNs by IREE with ICG injection over ICG injection alone is supported by these results.

Ohdaira *et al.*^[32] focused on lymphatic drainage using IREE with ICG. One of the advantage of this procedure is that SNNS by IREE with ICG injection enables us to detect lymphatic vessels from the tumor easily. They investigated 161 patients with gastric cancer using IREE with ICG and revealed that the most common locations of the SNs, in each of the upper, middle and lower thirds of the stomach, were station No. 7 which is defined as LNs along the trunk of left gastric artery between its root and the origin of its ascending branch by Japanese Gastric Cancer Association. Yano *et al.*^[34] investigated 130 patients with gastric cancer (3381 LNs) who underwent SNNS by IREE with ICG injection and evaluated LNs by immunohistochemistry (IH) with anti-cytokeratin antibody staining. They reported that 15 patients (27 nodes) were diagnosed without metastasis by hematoxylin and eosin (HE) staining, which turned to metastatic by IH staining. However, all the 27 nodes with micrometastasis were inside the lymphatic basins. They concluded that even if LN micrometastasis is overlooked by intraoperative frozen section with HE staining, micrometastasis can be completely removed by lymphatic basins dissection.

Benefit of SNNS is not only to avoid unnecessary LN dissection but also to enable us performing local resection (LR) of stomach for patients with EGC with curability. Kitaoka *et al.*^[36], was the first to report the use of LR for treating early gastric cancer. Maintenance of curability and quality of life are essential to introducing LR for early gastric cancer clinically. Kawamura *et al.*^[39] described the usefulness of partial resection of stomach as compared to conventional gastrectomy. They assessed gastric emptying by 13C-acetate breath

test in 60 patients who underwent distal gastrectomy with Billroth I reconstruction (DGBI) in 26 patients, LR in 34 patients. For the 13C breath test, 100 mg of 13C-acetate sodium salt was mixed in a test meal. Dietary intake and body weight change were significantly more reduced in the DGBI group than the LR group. In addition, significant acceleration of gastric emptying was observed in the DGBI group compared to that in the LR group by 13C breath test. They concluded that LR is an option for selected patients with EGC.

SN mapping concept seems reasonable approach to determine appropriate indications including pylorus-preserving gastrectomy, proximal gastrectomy and LR for cT1N0 gastric cancer. In particular, laparoscopic function-preserving surgeries should be performed for patients with negative for LN metastasis confirmed by SNNS. Earlier recovery after surgery and preservation of quality of life in the late disease phases can be achieved by limited laparoscopic gastrectomy with SNNS.

CONCLUSION

When we predict LN metastasis for ECG, we need at least pathological information derived from resected tumor through ESD. In particular, lymphovascular invasion, tumor depth and tumor size are the strongest LN metastasis predicting parameters for EGC. Basic strategy of additional treatment after ESD for patients with EGC is conventional gastrectomy. However, providing less invasive surgery such as SNNS for patients with EGC has potentiality to improve the quality of life of patients after surgery by preserving gastric function as compared to conventional gastrectomy.

REFERENCES

- 1 **Ferlay J**, Soerjomataram I, Dikshit R, Eser S, Mathers C, Rebelo M, Parkin DM, Forman D, Bray F. Cancer incidence and mortality worldwide: sources, methods and major patterns in GLOBOCAN 2012. *Int J Cancer* 2015; **136**: E359-E386 [PMID: 25220842 DOI: 10.1002/ijc.29210]
- 2 **Hamashima C**, Shibuya D, Yamazaki H, Inoue K, Fukao A, Saito H, Sobue T. The Japanese guidelines for gastric cancer screening. *Jpn J Clin Oncol* 2008; **38**: 259-267 [PMID: 18344316 DOI: 10.1093/jjco/hyn017]
- 3 **Choi KS**, Jun JK, Lee HY, Park S, Jung KW, Han MA, Choi IJ, Park EC. Performance of gastric cancer screening by endoscopy testing through the National Cancer Screening Program of Korea. *Cancer Sci* 2011; **102**: 1559-1564 [PMID: 21564421 DOI: 10.1111/j.1349-7006]
- 4 **Pasechnikov V**, Chukov S, Fedorov E, Kikuste I, Leja M. Gastric cancer: prevention, screening and early diagnosis. *World J Gastroenterol* 2014; **20**: 13842-13862 [PMID: 25320521 DOI: 10.3748/wjg.v20.i38.13842]
- 5 **Nashimoto A**, Akazawa K, Isobe Y, Miyashiro I, Katai H, Kodera Y, Tsujitani S, Seto Y, Furukawa H, Oda I, Ono H, Tanabe S, Kaminishi M. Gastric cancer treated in 2002 in Japan: 2009 annual report of the JGCA nationwide registry. *Gastric Cancer* 2013; **16**: 1-27 [PMID: 22729699 DOI: 10.1007/s10120-012-0163-4]
- 6 **An JY**, Baik YH, Choi MG, Noh JH, Sohn TS, Kim S. Predictive factors for lymph node metastasis in early gastric cancer with submucosal invasion: analysis of a single institutional experience. *Ann Surg* 2007; **246**: 749-753 [PMID: 17968165]
- 7 **Roviello F**, Rossi S, Marrelli D, Pedrazzani C, Corso G, Vindigni C, Morgagni P, Saragoni L, de Manzoni G, Tomezzoli A. Number of lymph node metastases and its prognostic significance in early gastric cancer: a multicenter Italian study. *J Surg Oncol* 2006; **94**: 275-280; discussion 274 [PMID: 16917863]
- 8 **Pelz J**, Merkel S, Horbach T, Papadopoulos T, Hohenberger W. Determination of nodal status and treatment in early gastric cancer. *Eur J Surg Oncol* 2004; **30**: 935-941 [PMID: 15498637]
- 9 **Songun I**, Putter H, Kranenbarg EM, Sasako M, van de Velde CJ. Surgical treatment of gastric cancer: 15-year follow-up results of the randomised nationwide Dutch D1D2 trial. *Lancet Oncol* 2010; **11**: 439-449 [PMID: 20409751 DOI: 10.1016/S1470-2045(10)70070-X]
- 10 **Japanese Gastric Cancer Association**. Japanese gastric cancer treatment guidelines 2010 (ver. 3). *Gastric Cancer* 2011; **14**: 113-123 [PMID: 21573742 DOI: 10.1007/s10120-011-0042-4]
- 11 **Gotoda T**, Yanagisawa A, Sasako M, Ono H, Nakanishi Y, Shimoda T, Kato Y. Incidence of lymph node metastasis from early gastric cancer: estimation with a large number of cases at two large centers. *Gastric Cancer* 2000; **3**: 219-225 [PMID: 11984739]
- 12 **Lee JH**, Choi IJ, Han HS, Kim YW, Ryu KW, Yoon HM, Eom BW, Kim CG, Lee JY, Cho SJ, Kim YI, Nam BH, Kook MC. Risk of lymph node metastasis in differentiated type mucosal early gastric cancer mixed with minor undifferentiated type histology. *Ann Surg Oncol* 2015; **22**: 1813-1819 [PMID: 25344305 DOI: 10.1245/s10434-014-4167-7]
- 13 **Kim BS**, Oh ST, Yook JH, Kim BS. Signet ring cell type and other histologic types: differing clinical course and prognosis in T1 gastric cancer. *Surgery* 2014; **155**: 1030-1035 [PMID: 24792508 DOI: 10.1016/j.surg.2013.08.016]
- 14 **Son SY**, Park JY, Ryu KW, Eom BW, Yoon HM, Cho SJ, Lee JY, Kim CG, Lee JH, Kook MC, Choi IJ, Kim YW. The risk factors for lymph node metastasis in early gastric cancer patients who underwent endoscopic resection: is the minimal lymph node dissection applicable? A retrospective study. *Surg Endosc* 2013; **27**: 3247-3253 [PMID: 23508816 DOI: 10.1007/s00464-013-2901-Z]
- 15 **Mönig SP**, Zirbes TK, Schröder W, Baldus SE, Lindemann DG, Dienes HP, Hölscher AH. Staging of gastric cancer: correlation of lymph node size and metastatic infiltration. *AJR Am J Roentgenol* 1999; **173**: 365-367 [PMID: 10430138]
- 16 **Dassen AE**, Lips DJ, Hoekstra CJ, Pruijt JF, Bosscha K. FDG-PET has no definite role in preoperative imaging in gastric cancer. *Eur J Surg Oncol* 2009; **35**: 449-455 [PMID: 19147324 DOI: 10.1016/j.ejso.2008.11.010]
- 17 **Mochiki E**, Kuwano H, Katoh H, Asao T, Oriuchi N, Endo K. Evaluation of 18F-2-deoxy-2-fluoro-D-glucose positron emission tomography for gastric cancer. *World J Surg* 2004; **28**: 247-253 [PMID: 14961197]
- 18 **Mukai K**, Ishida Y, Okajima K, Isozaki H, Morimoto T, Nishiyama S. Usefulness of preoperative FDG-PET for detection of gastric cancer. *Gastric Cancer* 2006; **9**: 192-196 [PMID: 16952037]
- 19 **Cardoso R**, Coburn N, Seevaratnam R, Sutradhar R, Lourenco LG, Mahar A, Law C, Yong E, Timmouth J. A systematic review and meta-analysis of the utility of EUS for preoperative staging for gastric cancer. *Gastric Cancer* 2012; **15** Suppl 1: S19-S26 [PMID: 22237654 DOI: 10.1007/s10120-011-0115-4]
- 20 **Nakagawa M**, Choi YY, An JY, Chung H, Seo SH, Shin HB, Bang HJ, Li S, Kim HI, Cheong JH, Hyung WJ, Noh SH. Difficulty of predicting the presence of lymph node metastases in patients with clinical early stage gastric cancer: a case control study. *BMC Cancer* 2015; **15**: 943 [PMID: 26625983 DOI: 10.1186/s12885-015-1940-3]
- 21 **Song SY**, Park S, Kim S, Son HJ, Rhee JC. Characteristics of intramucosal gastric carcinoma with lymph node metastatic disease. *Histopathology* 2004; **44**: 437-444 [PMID: 15139991 DOI: 10.1111/j.1365-2559.2004.01870]
- 22 **Park DJ**, Lee HK, Lee HJ, Lee HS, Kim WH, Yang HK, Lee KU, Choe KJ. Lymph node metastasis in early gastric cancer with submucosal invasion: feasibility of minimally invasive surgery.

- World J Gastroenterol* 2004; **10**: 3549-3552 [PMID: 15534904]
- 23 **Fujii M**, Egashira Y, Akutagawa H, Nishida T, Nitta T, Edagawa G, Kurisu Y, Shibayama Y. Pathological factors related to lymph node metastasis of submucosally invasive gastric cancer: criteria for additional gastrectomy after endoscopic resection. *Gastric Cancer* 2013; **16**: 521-530 [PMID: 23179370 DOI: 10.1007/s10120-012-0215-9]
 - 24 **Yi Kim D**, Kyoong Joo J, Kyu Park Y, Yeob Ryu S, Soo Kim H, Kyun Noh B, Hwa Lee K, Hyuk Lee J. E-cadherin expression in early gastric carcinoma and correlation with lymph node metastasis. *J Surg Oncol* 2007; **96**: 429-435 [PMID: 17786966]
 - 25 **Park JH**, Kim EK, Kim YH, Kim JH, Bae YS, Lee YC, Cheong JH, Noh SH, Kim H. Epstein-Barr virus positivity, not mismatch repair-deficiency, is a favorable risk factor for lymph node metastasis in submucosa-invasive early gastric cancer. *Gastric Cancer* 2015; Epub ahead of print [PMID: 26573601]
 - 26 **Amioka T**, Kitadai Y, Tanaka S, Haruma K, Yoshihara M, Yasui W, Chayama K. Vascular endothelial growth factor-C expression predicts lymph node metastasis of human gastric carcinomas invading the submucosa. *Eur J Cancer* 2002; **38**: 1413-1419 [PMID: 12091074]
 - 27 **Shida A**, Fujioka S, Kawamura M, Takahashi N, Ishibashi Y, Nakada K, Mitsumori N, Omura N, Yanaga K. Prediction of lymph node metastasis in patients with submucosa-invading early gastric cancer. *Anticancer Res* 2014; **34**: 4471-4474 [PMID: 25075087]
 - 28 **Hiratsuka M**, Miyashiro I, Ishikawa O, Furukawa H, Motomura K, Ohigashi H, Kameyama M, Sasaki Y, Kabuto T, Ishiguro S, Imaoka S, Koyama H. Application of sentinel node biopsy to gastric cancer surgery. *Surgery* 2001; **129**: 335-340 [PMID: 11231462]
 - 29 **Kitagawa Y**, Fujii H, Mukai M, Kubota T, Otani Y, Kitajima M. Radio-guided sentinel node detection for gastric cancer. *Br J Surg* 2002; **89**: 604-608 [PMID: 11972551 DOI: 10.1046/j.1365-2168.2002.02065]
 - 30 **Miwa K**, Kinami S, Taniguchi K, Fushida S, Fujimura T, Nonomura A. Mapping sentinel nodes in patients with early-stage gastric carcinoma. *Br J Surg* 2003; **90**: 178-182 [PMID: 12555293 DOI: 10.1002/bjs.4031]
 - 31 **Nimura H**, Narimiya N, Mitsumori N, Yamazaki Y, Yanaga K, Urashima M. Infrared ray electronic endoscopy combined with indocyanine green injection for detection of sentinel nodes of patients with gastric cancer. *Br J Surg* 2004; **91**: 575-579 [PMID: 15122608 DOI: 10.1002/bjs.4470]
 - 32 **Ohdaira H**, Nimura H, Mitsumori N, Takahashi N, Kashiwagi H, Yanaga K. Validity of modified gastrectomy combined with sentinel node navigation surgery for early gastric cancer. *Gastric Cancer* 2007; **10**: 117-122 [PMID: 17577622 DOI: 10.1007/s10120-007-0419-6]
 - 33 **Kelder W**, Nimura H, Takahashi N, Mitsumori N, van Dam GM, Yanaga K. Sentinel node mapping with indocyanine green (ICG) and infrared ray detection in early gastric cancer: an accurate method that enables a limited lymphadenectomy. *Eur J Surg Oncol* 2010; **36**: 552-558 [PMID: 20452171 DOI: 10.1016/j.ejso.2010.04.007]
 - 34 **Yano K**, Nimura H, Mitsumori N, Takahashi N, Kashiwagi H, Yanaga K. The efficiency of micrometastasis by sentinel node navigation surgery using indocyanine green and infrared ray laparoscopy system for gastric cancer. *Gastric Cancer* 2012; **15**: 287-291 [PMID: 22041868 DOI: 10.1007/s10120-011-0105-6]
 - 35 **Mitsumori N**, Nimura H, Takahashi N. Sentinel node navigation surgery for early malignant tumor of the duodenum. *Jikeikai Med J* 2009; **56**: 11-17
 - 36 **Ryu KW**, Eom BW, Nam BH, Lee JH, Kook MC, Choi IJ, Kim YW. Is the sentinel node biopsy clinically applicable for limited lymphadenectomy and modified gastric resection in gastric cancer? A meta-analysis of feasibility studies. *J Surg Oncol* 2011; **104**: 578-584 [PMID: 21695700 DOI: 10.1002/jso.21995]
 - 37 **Mitsumori N**, Nimura H, Takahashi N, Kawamura M, Aoki H, Shida A, Omura N, Yanaga K. Sentinel lymph node navigation surgery for early stage gastric cancer. *World J Gastroenterol* 2014; **20**: 5685-5693 [PMID: 24914329 DOI: 10.3748/wjg.v20.i19]
 - 38 **Kitaoka H**, Yoshikawa K, Hirota T, Itabashi M. Surgical treatment of early gastric cancer. *Jpn J Clin Oncol* 1984; **14**: 283-293 [PMID: 6737715]
 - 39 **Kawamura M**, Nakada K, Konishi H, Iwasaki T, Murakami K, Mitsumori N, Hanyu N, Omura N, Yanaga K. Assessment of motor function of the remnant stomach by ¹³C breath test with special reference to gastric local resection. *World J Surg* 2014; **38**: 2898-2903 [PMID: 24934641]
 - 40 **Folli S**, Morgagni P, Roviello F, De Manzoni G, Marrelli D, Saragoni L, Di Leo A, Gaudio M, Nanni O, Carli A, Cordiano C, Dell'Amore D, Vio A. Risk factors for lymph node metastases and their prognostic significance in early gastric cancer (EGC) for the Italian Research Group for Gastric Cancer (IRGGC). *Jpn J Clin Oncol* 2001; **31**: 495-499 [PMID: 11696619 DOI: 10.1093/jjco/hye107]
 - 41 **Abe N**, Watanabe T, Suzuki K, Machida H, Toda H, Nakaya Y, Masaki T, Mori T, Sugiyama M, Atomi Y. Risk factors predictive of lymph node metastasis in depressed early gastric cancer. *Am J Surg* 2002; **183**: 168-172 [PMID: 11918883 DOI: 10.1016/S0002-9610(01)00860-1]
 - 42 **Matsuzaki H**, Kikuchi S, Kakita A. Evaluation of the morphology of submucosal tumor invasion and its volume in early gastric cancer. *In Vivo* 2003; **17**: 41-44 [PMID: 12655788]
 - 43 **Abe N**, Sugiyama M, Masaki T, Ueki H, Yanagida O, Mori T, Watanabe T, Atomi Y. Predictive factors for lymph node metastasis of differentiated submucosally invasive gastric cancer. *Gastrointest Endosc* 2004; **60**: 242-245 [PMID: 15278052 DOI: 10.1016/S0016-5107(04)01682-7]
 - 44 **Hyung WJ**, Cheong JH, Kim J, Chen J, Choi SH, Noh SH. Application of minimally invasive treatment for early gastric cancer. *J Surg Oncol* 2004; **85**: 181-185; discussion 186 [PMID: 14991872 DOI: 10.1002/jso.20018]
 - 45 **Son HJ**, Song SY, Kim S, Noh JH, Sohn TS, Kim DS, Rhee JC. Characteristics of submucosal gastric carcinoma with lymph node metastatic disease. *Histopathology* 2005; **46**: 158-165 [PMID: 15693888 DOI: 10.1111/j.1365-2559.2005.02049]
 - 46 **Lo SS**, Wu CW, Chen JH, Li AF, Hsieh MC, Shen KH, Lin HJ, Lui WY. Surgical results of early gastric cancer and proposing a treatment strategy. *Ann Surg Oncol* 2007; **14**: 340-347 [PMID: 17094028 DOI: 10.1245/s10434-006-9077-x]
 - 47 **Kunisaki C**, Akiyama H, Nomura M, Matsuda G, Otsuka Y, Ono HA, Takagawa R, Nagahori Y, Takahashi M, Kito F, Moriwaki Y, Nakano A, Shimada H. Lymph node status in patients with submucosal gastric cancer. *Ann Surg Oncol* 2006; **13**: 1364-1371 [PMID: 16957964 DOI: 10.1245/s10434-006-9061-5]
 - 48 **Li C**, Kim S, Lai JF, Oh SJ, Hyung WJ, Choi WH, Choi SH, Zhu ZG, Noh SH. Risk factors for lymph node metastasis in undifferentiated early gastric cancer. *Ann Surg Oncol* 2008; **15**: 764-769 [PMID: 18043971 DOI: 10.1245/s10434-007-9707-y]
 - 49 **Park YD**, Chung YJ, Chung HY, Yu W, Bae HI, Jeon SW, Cho CM, Tak WY, Kweon YO. Factors related to lymph node metastasis and the feasibility of endoscopic mucosal resection for treating poorly differentiated adenocarcinoma of the stomach. *Endoscopy* 2008; **40**: 7-10 [PMID: 18210339 DOI: 10.1055/s-2007-966750]
 - 50 **Shen L**, Huang Y, Sun M, Xu H, Wei W, Wu W. Clinicopathological features associated with lymph node metastasis in early gastric cancer: analysis of a single-institution experience in China. *Can J Gastroenterol* 2009; **23**: 353-356 [PMID: 19440566]
 - 51 **Morita H**, Ishikawa Y, Akishima-Fukasawa Y, Ito K, Akasaka Y, Nishimura C, Igarashi Y, Miki K, Ishii T. Histopathological predictor for regional lymph node metastasis in gastric cancer. *Virchows Arch* 2009; **454**: 143-151 [PMID: 19104832 DOI: 10.1007/s00428-008-0717-3]
 - 52 **Kunisaki C**, Takahashi M, Nagahori Y, Fukushima T, Makino H, Takagawa R, Kosaka T, Ono HA, Akiyama H, Moriwaki Y, Nakano A. Risk factors for lymph node metastasis in histologically poorly differentiated type early gastric cancer. *Endoscopy* 2009; **41**: 498-503 [PMID: 19533552 DOI: 10.1055/s-0029-1214758]
 - 53 **Sung CM**, Hsu CM, Hsu JT, Yeh TS, Lin CJ, Chen TC, Su MY, Chiu CT. Predictive factors for lymph node metastasis in early

- gastric cancer. *World J Gastroenterol* 2010; **16**: 5252-5256 [PMID: 21049560 DOI: 10.3748/wjg.v16.i41.5252]
- 54 **Lee K**, Park DJ, Choe G, Kim HH, Kim WH, Lee HS. Increased intratumoral lymphatic vessel density correlates with lymph node metastasis in early gastric carcinoma. *Ann Surg Oncol* 2010; **17**: 73-80 [PMID: 19777179 DOI: 10.1245/s10434-009-0707-y]
- 55 **Lim MS**, Lee HW, Im H, Kim BS, Lee MY, Jeon JY, Yang DH, Lee BH. Predictable factors for lymph node metastasis in early gastric cancer-analysis of single institutional experience. *J Gastrointest Surg* 2011; **15**: 1783-1788 [PMID: 21796460 DOI: 10.1007/s11605-011-1624-5]
- 56 **Lee JH**, Choi MG, Min BH, Noh JH, Sohn TS, Bae JM, Kim S. Predictive factors for lymph node metastasis in patients with poorly differentiated early gastric cancer. *Br J Surg* 2012; **99**: 1688-1692 [PMID: 23023388]
- 57 **Ren G**, Cai R, Zhang WJ, Ou JM, Jin YN, Li WH. Prediction of risk factors for lymph node metastasis in early gastric cancer. *World J Gastroenterol* 2013; **19**: 3096-3107 [PMID: 23716990 DOI: 10.3748/wjg.v19.i20.3096]
- 58 **Feng H**, Wang Y, Cao L, Zhang C, Sun B, Zhao Y, Xu J. Lymph node metastasis in differentiated-type early gastric cancer: a single-center retrospective analysis of surgically resected cases. *Scand J Gastroenterol* 2016; **51**: 48-54 [PMID: 26200504 DOI: 10.3109/00365521.2015.1054425]

P- Reviewer: Coccolini F, Ilson DH, Sendur MAN **S- Editor:** Ma YJ
L- Editor: A **E- Editor:** Ma S





Published by **Baishideng Publishing Group Inc**

8226 Regency Drive, Pleasanton, CA 94588, USA

Telephone: +1-925-223-8242

Fax: +1-925-223-8243

E-mail: bpgoffice@wjgnet.com

Help Desk: <http://www.wjgnet.com/esps/helpdesk.aspx>

<http://www.wjgnet.com>



ISSN 1007-9327

