

# World Journal of *Clinical Cases*

*World J Clin Cases* 2022 June 26; 10(18): 5934-6340



**MINIREVIEWS**

- 5934 Development of clustered regularly interspaced short palindromic repeats/CRISPR-associated technology for potential clinical applications  
*Huang YY, Zhang XY, Zhu P, Ji L*
- 5946 Strategies and challenges in treatment of varicose veins and venous insufficiency  
*Gao RD, Qian SY, Wang HH, Liu YS, Ren SY*
- 5957 Diabetes mellitus susceptibility with varied diseased phenotypes and its comparison with phenome interactome networks  
*Rout M, Kour B, Vuree S, Lulu SS, Medicherla KM, Suravajhala P*

**ORIGINAL ARTICLE****Clinical and Translational Research**

- 5965 Identification of potential key molecules and signaling pathways for psoriasis based on weighted gene co-expression network analysis  
*Shu X, Chen XX, Kang XD, Ran M, Wang YL, Zhao ZK, Li CX*
- 5984 Construction and validation of a novel prediction system for detection of overall survival in lung cancer patients  
*Zhong C, Liang Y, Wang Q, Tan HW, Liang Y*

**Case Control Study**

- 6001 Effectiveness and postoperative rehabilitation of one-stage combined anterior-posterior surgery for severe thoracolumbar fractures with spinal cord injury  
*Zhang B, Wang JC, Jiang YZ, Song QP, An Y*

**Retrospective Study**

- 6009 Prostate sclerosing adenopathy: A clinicopathological and immunohistochemical study of twelve patients  
*Feng RL, Tao YP, Tan ZY, Fu S, Wang HF*
- 6021 Value of magnetic resonance diffusion combined with perfusion imaging techniques for diagnosing potentially malignant breast lesions  
*Zhang H, Zhang XY, Wang Y*
- 6032 Scar-centered dilation in the treatment of large keloids  
*Wu M, Gu JY, Duan R, Wei BX, Xie F*
- 6039 Application of a novel computer-assisted surgery system in percutaneous nephrolithotomy: A controlled study  
*Qin F, Sun YF, Wang XN, Li B, Zhang ZL, Zhang MX, Xie F, Liu SH, Wang ZJ, Cao YC, Jiao W*

- 6050** Influences of etiology and endoscopic appearance on the long-term outcomes of gastric antral vascular ectasia

*Kwon HJ, Lee SH, Cho JH*

#### Randomized Controlled Trial

- 6060** Evaluation of the clinical efficacy and safety of TST33 mega hemorrhoidectomy for severe prolapsed hemorrhoids

*Tao L, Wei J, Ding XF, Ji LJ*

- 6069** Sequential chemotherapy and icotinib as first-line treatment for advanced epidermal growth factor receptor-mutated non-small cell lung cancer

*Sun SJ, Han JD, Liu W, Wu ZY, Zhao X, Yan X, Jiao SC, Fang J*

#### Randomized Clinical Trial

- 6082** Impact of preoperative carbohydrate loading on gastric volume in patients with type 2 diabetes

*Lin XQ, Chen YR, Chen X, Cai YP, Lin JX, Xu DM, Zheng XC*

#### META-ANALYSIS

- 6091** Efficacy and safety of adalimumab in comparison to infliximab for Crohn's disease: A systematic review and meta-analysis

*Yang HH, Huang Y, Zhou XC, Wang RN*

#### CASE REPORT

- 6105** Successful treatment of acute relapse of chronic eosinophilic pneumonia with benralizumab and without corticosteroids: A case report

*Izhakian S, Pertzov B, Rosengarten D, Kramer MR*

- 6110** Pembrolizumab-induced Stevens-Johnson syndrome in advanced squamous cell carcinoma of the lung: A case report and review of literature

*Wu JY, Kang K, Yi J, Yang B*

- 6119** Hepatic epithelioid hemangioendothelioma after thirteen years' follow-up: A case report and review of literature

*Mo WF, Tong YL*

- 6128** Effectiveness and safety of ultrasound-guided intramuscular lauromacrogol injection combined with hysteroscopy in cervical pregnancy treatment: A case report

*Ye JP, Gao Y, Lu LW, Ye YJ*

- 6136** Carcinoma located in a right-sided sigmoid colon: A case report

*Lyu LJ, Yao WW*

- 6141** Subcutaneous infection caused by *Mycobacterium abscessus* following cosmetic injections of botulinum toxin: A case report

*Deng L, Luo YZ, Liu F, Yu XH*

- 6148** Overlapping syndrome of recurrent anti-N-methyl-D-aspartate receptor encephalitis and anti-myelin oligodendrocyte glycoprotein demyelinating diseases: A case report  
*Yin XJ, Zhang LF, Bao LH, Feng ZC, Chen JH, Li BX, Zhang J*
- 6156** Liver transplantation for late-onset ornithine transcarbamylase deficiency: A case report  
*Fu XH, Hu YH, Liao JX, Chen L, Hu ZQ, Wen JL, Chen SL*
- 6163** Disseminated strongyloidiasis in a patient with rheumatoid arthritis: A case report  
*Zheng JH, Xue LY*
- 6168** CYP27A1 mutation in a case of cerebrotendinous xanthomatosis: A case report  
*Li ZR, Zhou YL, Jin Q, Xie YY, Meng HM*
- 6175** Postoperative multiple metastasis of clear cell sarcoma-like tumor of the gastrointestinal tract in adolescent: A case report  
*Huang WP, Li LM, Gao JB*
- 6184** Toripalimab combined with targeted therapy and chemotherapy achieves pathologic complete response in gastric carcinoma: A case report  
*Liu R, Wang X, Ji Z, Deng T, Li HL, Zhang YH, Yang YC, Ge SH, Zhang L, Bai M, Ning T, Ba Y*
- 6192** Presentation of Boerhaave's syndrome as an upper-esophageal perforation associated with a right-sided pleural effusion: A case report  
*Tan N, Luo YH, Li GC, Chen YL, Tan W, Xiang YH, Ge L, Yao D, Zhang MH*
- 6198** Camrelizumab-induced anaphylactic shock in an esophageal squamous cell carcinoma patient: A case report and review of literature  
*Liu K, Bao JF, Wang T, Yang H, Xu BP*
- 6205** Nontraumatic convexal subarachnoid hemorrhage: A case report  
*Chen HL, Li B, Chen C, Fan XX, Ma WB*
- 6211** Growth hormone ameliorates hepatopulmonary syndrome and nonalcoholic steatohepatitis secondary to hypopituitarism in a child: A case report  
*Zhang XY, Yuan K, Fang YL, Wang CL*
- 6218** Vancomycin dosing in an obese patient with acute renal failure: A case report and review of literature  
*Xu KY, Li D, Hu ZJ, Zhao CC, Bai J, Du WL*
- 6227** Insulinoma after sleeve gastrectomy: A case report  
*Lobaton-Ginsberg M, Sotelo-González P, Ramirez-Renteria C, Juárez-Aguilar FG, Ferreira-Hermosillo A*
- 6234** Primary intestinal lymphangiectasia presenting as limb convulsions: A case report  
*Cao Y, Feng XH, Ni HX*
- 6241** Esophagogastric junctional neuroendocrine tumor with adenocarcinoma: A case report  
*Kong ZZ, Zhang L*

- 6247** Foreign body granuloma in the tongue differentiated from tongue cancer: A case report  
*Jiang ZH, Xu R, Xia L*
- 6254** Modified endoscopic ultrasound-guided selective N-butyl-2-cyanoacrylate injections for gastric variceal hemorrhage in left-sided portal hypertension: A case report  
*Yang J, Zeng Y, Zhang JW*
- 6261** Management of type IIIb dens invaginatus using a combination of root canal treatment, intentional replantation, and surgical therapy: A case report  
*Zhang J, Li N, Li WL, Zheng XY, Li S*
- 6269** Clivus-involved immunoglobulin G4 related hypertrophic pachymeningitis mimicking meningioma: A case report  
*Yu Y, Lv L, Yin SL, Chen C, Jiang S, Zhou PZ*
- 6277** *De novo* brain arteriovenous malformation formation and development: A case report  
*Huang H, Wang X, Guo AN, Li W, Duan RH, Fang JH, Yin B, Li DD*
- 6283** Coinfection of *Streptococcus suis* and *Nocardia asiatica* in the human central nervous system: A case report  
*Chen YY, Xue XH*
- 6289** Dilated left ventricle with multiple outpouchings – a severe congenital ventricular diverticulum or left-dominant arrhythmogenic cardiomyopathy: A case report  
*Zhang X, Ye RY, Chen XP*
- 6298** Spontaneous healing of complicated crown-root fractures in children: Two case reports  
*Zhou ZL, Gao L, Sun SK, Li HS, Zhang CD, Kou WW, Xu Z, Wu LA*
- 6307** Thyroid follicular renal cell carcinoma excluding thyroid metastases: A case report  
*Wu SC, Li XY, Liao BJ, Xie K, Chen WM*
- 6314** Appendiceal bleeding: A case report  
*Zhou SY, Guo MD, Ye XH*
- 6319** Spontaneous healing after conservative treatment of isolated grade IV pancreatic duct disruption caused by trauma: A case report  
*Mei MZ, Ren YF, Mou YP, Wang YY, Jin WW, Lu C, Zhu QC*
- 6325** Pneumonia and seizures due to hypereosinophilic syndrome – organ damage and eosinophilia without synchronisation: A case report  
*Ishida T, Murayama T, Kobayashi S*
- 6333** Creutzfeldt-Jakob disease presenting with bilateral hearing loss: A case report  
*Na S, Lee SA, Lee JD, Lee ES, Lee TK*

**LETTER TO THE EDITOR**

- 6338** Stem cells as an option for the treatment of COVID-19  
*Cuevas-González MV, Cuevas-González JC*

**ABOUT COVER**

Editorial Board Member of *World Journal of Clinical Cases*, Cristina Tudoran, PhD, Assistant Professor, Department VII, Internal Medicine II, Discipline of Cardiology, "Victor Babes" University of Medicine and Pharmacy Timisoara, Timisoara 300041, Timis, Romania. cristina13.tudoran@gmail.com

**AIMS AND SCOPE**

The primary aim of *World Journal of Clinical Cases* (*WJCC*, *World J Clin Cases*) is to provide scholars and readers from various fields of clinical medicine with a platform to publish high-quality clinical research articles and communicate their research findings online.

*WJCC* mainly publishes articles reporting research results and findings obtained in the field of clinical medicine and covering a wide range of topics, including case control studies, retrospective cohort studies, retrospective studies, clinical trials studies, observational studies, prospective studies, randomized controlled trials, randomized clinical trials, systematic reviews, meta-analysis, and case reports.

**INDEXING/ABSTRACTING**

The *WJCC* is now indexed in Science Citation Index Expanded (also known as SciSearch®), Journal Citation Reports/Science Edition, Scopus, PubMed, and PubMed Central. The 2021 Edition of Journal Citation Reports® cites the 2020 impact factor (IF) for *WJCC* as 1.337; IF without journal self cites: 1.301; 5-year IF: 1.742; Journal Citation Indicator: 0.33; Ranking: 119 among 169 journals in medicine, general and internal; and Quartile category: Q3. The *WJCC*'s CiteScore for 2020 is 0.8 and Scopus CiteScore rank 2020: General Medicine is 493/793.

**RESPONSIBLE EDITORS FOR THIS ISSUE**

Production Editor: *Ying-Yi Yuan*, Production Department Director: *Xu Guo*, Editorial Office Director: *Jin-Lei Wang*.

**NAME OF JOURNAL**

*World Journal of Clinical Cases*

**ISSN**

ISSN 2307-8960 (online)

**LAUNCH DATE**

April 16, 2013

**FREQUENCY**

Thrice Monthly

**EDITORS-IN-CHIEF**

Bao-Gan Peng, Jerzy Tadeusz Chudek, George Kontogeorgos, Maurizio Serati, Ja Hyeon Ku

**EDITORIAL BOARD MEMBERS**

<https://www.wjgnet.com/2307-8960/editorialboard.htm>

**PUBLICATION DATE**

June 26, 2022

**COPYRIGHT**

© 2022 Baishideng Publishing Group Inc

**INSTRUCTIONS TO AUTHORS**

<https://www.wjgnet.com/bpg/gerinfo/204>

**GUIDELINES FOR ETHICS DOCUMENTS**

<https://www.wjgnet.com/bpg/GerInfo/287>

**GUIDELINES FOR NON-NATIVE SPEAKERS OF ENGLISH**

<https://www.wjgnet.com/bpg/gerinfo/240>

**PUBLICATION ETHICS**

<https://www.wjgnet.com/bpg/GerInfo/288>

**PUBLICATION MISCONDUCT**

<https://www.wjgnet.com/bpg/gerinfo/208>

**ARTICLE PROCESSING CHARGE**

<https://www.wjgnet.com/bpg/gerinfo/242>

**STEPS FOR SUBMITTING MANUSCRIPTS**

<https://www.wjgnet.com/bpg/GerInfo/239>

**ONLINE SUBMISSION**

<https://www.f6publishing.com>

# Growth hormone ameliorates hepatopulmonary syndrome and nonalcoholic steatohepatitis secondary to hypopituitarism in a child: A case report

Xiao-Yuan Zhang, Ke Yuan, Yan-Lan Fang, Chun-Lin Wang

**Specialty type:** Medicine, research and experimental

**Provenance and peer review:**

Unsolicited article; Externally peer reviewed.

**Peer-review model:** Single blind

**Peer-review report's scientific quality classification**

Grade A (Excellent): 0  
Grade B (Very good): 0  
Grade C (Good): C, C, C  
Grade D (Fair): 0  
Grade E (Poor): 0

**P-Reviewer:** Aktas S, Turkey; Govindarajan KK, India; Soresi M, Italy

**Received:** November 13, 2021

**Peer-review started:** November 13, 2021

**First decision:** March 7, 2022

**Revised:** March 25, 2022

**Accepted:** April 22, 2022

**Article in press:** April 22, 2022

**Published online:** June 26, 2022



**Xiao-Yuan Zhang, Ke Yuan, Yan-Lan Fang, Chun-Lin Wang**, Department of Pediatrics, The First Affiliated Hospital, Zhejiang University School of Medicine, Hangzhou 310003, Zhejiang Province, China

**Corresponding author:** Chun-Lin Wang, Doctor, PhD, Chief Doctor, Professor, Department of Pediatrics, The First Affiliated Hospital, Zhejiang University School of Medicine, No. 79 Qingchun Road, Hangzhou 310003, Zhejiang Province, China. [hzwangcl@zju.edu.cn](mailto:hzwangcl@zju.edu.cn)

## Abstract

### BACKGROUND

Craniopharyngioma is a benign tumor that usually develops in children; however, it is located in the center and close to sensitive structures, such as the pituitary gland and hypothalamus. As the hypothalamus plays a crucial role in the homeostasis of anterior pituitary hormone synthesis, damage to the hypothalamus leads to multiple pituitary hormone deficiencies and non-alcoholic fatty liver disease, including hepatopulmonary syndrome (HPS). HPS has limited treatment and poor prognosis.

### CASE SUMMARY

A girl aged 13 years and 6 mo underwent surgery for craniopharyngioma 6 years prior. Right craniotomy was performed with total resection *via* the corpus callosum approach, and the tumor at the base was approximately 3.5 cm × 3.5 cm × 4.0 cm. At 1 year postoperatively, she exhibited abdominal distension and weakness, and the laboratory tests revealed fatty liver disease. Thereafter, she had not visited the outpatient clinic for 2 years. Two years ago, she developed decreased activity endurance, severe cyanosis, chest tightness, wheezing, and intermittent and recurrent low fever after mild physical labor. Hepatobiliary ultrasonography, liver biopsy, and contrast echocardiography of the right heart showed cirrhosis and multiple pituitary hormone deficiencies, indicating HPS. After 1 year of treatment with recombinant human growth hormone, the liver function and oxygenation improved; she did not undergo liver transplantation.

### CONCLUSION

Craniopharyngioma surgery can easily cause hypopituitarism, which can lead to nonalcoholic steatohepatitis and HPS in children. Early growth hormone therapy is important to improve the prognosis of these diseases.

**Key Words:** Craniopharyngioma; Nonalcoholic fatty liver disease; Hypopituitarism; Hepatopulmonary syndrome; Growth hormone; Children; Case report

©The Author(s) 2022. Published by Baishideng Publishing Group Inc. All rights reserved.

**Core Tip:** Hepatopulmonary syndrome (HPS) is a serious complication of chronic liver disease with a poor prognosis. Currently, liver transplantation is the only available treatment; however, severe hypoxemia before transplantation is a high risk factor for postoperative death. We present a case of postoperative craniopharyngioma in a child with nonalcoholic steatohepatitis and HPS secondary to hypopituitarism. The patient's liver function and hypoxemia were improved by growth hormone replacement therapy, and liver transplantation was expected to be avoided.

**Citation:** Zhang XY, Yuan K, Fang YL, Wang CL. Growth hormone ameliorates hepatopulmonary syndrome and nonalcoholic steatohepatitis secondary to hypopituitarism in a child: A case report. *World J Clin Cases* 2022; 10(18): 6211-6217

**URL:** <https://www.wjgnet.com/2307-8960/full/v10/i18/6211.htm>

**DOI:** <https://dx.doi.org/10.12998/wjcc.v10.i18.6211>

## INTRODUCTION

Nonalcoholic steatohepatitis and hepatopulmonary syndrome (HPS) are rare in children with secondary pituitary insufficiency after surgery for craniopharyngioma. Craniopharyngioma and treatment sequelae may lead to polypituitary insufficiency, which further affects the hormone secretion in the body. Endocrine diseases also cause nonalcoholic fatty liver disease (NAFLD)[1]. This report aims to further elucidate the clinical characteristics of nonalcoholic steatohepatitis (NASH) and HPS caused by hypothalamic-pituitary dysfunction after surgery for craniopharyngioma and the improvement of this disease after hormone replacement therapy, which has great significance in the clinical prognosis.

## CASE PRESENTATION

### Chief complaints

The chief complaints were liver enlargement for 4 years, activity loss for 2 years, and cyanosis for more than 1 year.

### History of present illness

A female patient aged 13 years and 6 mo was diagnosed with craniopharyngioma 6 years prior and underwent surgical resection without postoperative hormone replacement therapy. She had weakness after the surgery, and multiple laboratory tests revealed hypernatremia and hyperchloremia. The maximum serum sodium level was 176 mmol/L, which was improved by infusion of glucose, and the lowest sodium level was reduced to approximately 155 mmol/L. Four years ago, abdominal distension due to liver enlargement was noted, and B-ultrasound examination suggested fatty liver disease. The patient had severe cyanosis, chest tightness, wheezing, intermittent fever, and progressive exacerbation after mild physical labor for more than 1 year. Oxygen saturation fluctuated around 85% under high-flow oxygen inhalation. Hepatobiliary ultrasonography, liver biopsy, and contrast echocardiography of the right heart revealed cirrhosis and HPS.

### History of past illness

The patient had no history of hypertension, diabetes, or heart disease. She had undergone surgery for craniopharyngioma 6 years ago.

### Personal and family history

The patient was born to a G1P1 mother at full term. The patient's parents are alive, healthy, and divorced. The patient does not have siblings.

### Physical examination

Under atmospheric inhalation, oxygen saturation (SpO<sub>2</sub>) mostly fluctuated at around 70%. Cyanosis of the face and lips was noted. The heart rate was 124 beats/min, respiration was 26 breaths/min, blood



pressure was 96/46 mmHg, height was 141.5 cm (-2.5 SD), and weight was 41.85 kg (-0.5 SD). The skin sclera did not have obvious yellow staining, and acanthosis nigricans was noted around the neck and axillae. No abnormality was found during cardiopulmonary auscultation, and the abdomen was soft but enlarged with palpable spleen and liver. Examination of the nervous system was negative, double breasts were in stage B1, pubic hair was in stage PH1, and no axillary hair was found.

### Laboratory examinations

The patient exhibited hypernatremia (serum sodium level, 167 mmol/L; normal range, 135–145 mmol/L), mild liver function abnormality (alanine aminotransferase level, 67 U/L, normal range, 7–40 U/L; aspartate aminotransferase level, 93 U/L, normal range, 13–40 U/L;  $\gamma$ -glutamyltranspeptidase, 107 U/L, normal range, 7–45 U/L; total bilirubin level, 45.1  $\mu$ mol/L, normal range, 0.0–21  $\mu$ mol/L; total biliary acid level, 22.3  $\mu$ mol/L, normal range, 0.0–10.0  $\mu$ mol/L; indirect bilirubin level, 33.6  $\mu$ mol/L, normal range, 3–14  $\mu$ mol/L; triglyceride level, 2.53 mmol/L, normal range, 0.3–1.7 mmol/L), abnormal renal function (creatinine level, 79  $\mu$ mol/L; normal range, 15–77  $\mu$ mol/L), and high blood ammonia level (94  $\mu$ mol/L; normal range, 10–47  $\mu$ mol/L). The patient had hypopituitarism and multiple pituitary hormone deficiencies (Table 1). However, the coagulation function, immune function, and Epstein-Barr virus and cytomegalovirus levels were normal. The hepatitis series, including hepatitis A virus, hepatitis B virus, hepatitis C virus, hepatitis D virus, and hepatitis E virus, were normal.

### Imaging examinations

Echocardiography of the right heart revealed a diffuse arteriovenous shunt in the lung (grade III > 100/frame), which was consistent with HPS (Figure 1A). Abdominal ultrasonography revealed bile duct dilatation, cirrhosis, and splenomegaly (Figure 1B). Biopsy of the liver parenchyma showed loss of lobular structure, formation of regenerated nodules, swelling of the hepatocytes, mild steatosis (20%), fibroseptal bile duct hyperplasia, and fibrous tissue hyperplasia. The diagnostic view showed nodular cirrhosis (considering the origin of NASH) (Figure 2). The liver vasculature of computed tomography angiography revealed cirrhotic hepatosplenomegaly and portal hypertension, spongiform changes in the left portal artery, mild varicose veins in the lower esophagus, and splenic-renal shunt. Magnetic resonance cholangiopancreatography did not show abnormal changes in the pancreatic duct. The pituitary magnetic resonance imaging that included the conventional plain scan and dynamic contrast-enhanced scan showed postoperative changes in craniopharyngioma.

## FINAL DIAGNOSIS

The final diagnoses were liver cirrhosis, HPS, hypopituitarism, and electrolyte imbalance.

## TREATMENT

The patient received multiple hormone replacement and desmopressin therapies: Growth hormone (GH) (4 IU qn), thyroid hormone (levothyroxine sodium hydrate, 50  $\mu$ g/d), corticosteroid (hydrocortisone, 15 mg/d), and desmopressin (Minirin, 0.05 mg/d). Moreover, the patient received symptomatic oxygen inhalation and calcium and potassium supplementation.

## OUTCOME AND FOLLOW-UP

Oxygen saturation improved significantly after 1 mo of GH treatment and currently fluctuated at around 92% for low-flow nasal catheter oxygen. Liver function was reduced to the normal range, hypernatremia improved, and total bilirubin, indirect bilirubin, total bile acid, and lipid levels were significantly improved. During regular follow-up, it was found that liver transplantation was not required.

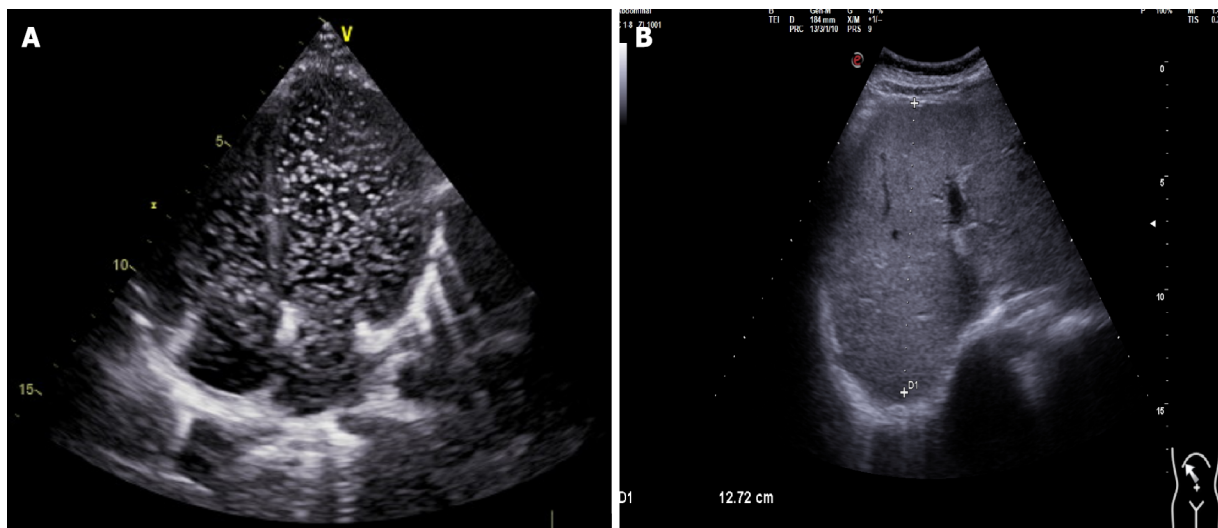
## DISCUSSION

Craniopharyngioma is a rare primary brain tumor that originates from ectopic embryonic remnants of the craniopharyngeal duct or squamous epithelial cells. Its incidence is 0.5–2 cases *per million persons per year*, with peaks in childhood/adolescence (8 years) and adulthood (40–50 years)[2,3]. Although histologically defined as a benign tumor, craniopharyngioma often compresses nearby key structures, such as the optic neurohypophysis or hypothalamus[4,5]. Postoperative complications of craniopharyngioma, especially endocrine dysfunction, have a high incidence and mainly manifest as

**Table 1 Laboratory examinations results**

Variable	Value
IGF-1 (220.0-972.0 ng/mL)	170
TSH (0.35-4.94 mIU/L)	1.05
FT3 (2.43-6.01 pmol/L)	3.9
FT4 (9.01-19.05 pmol/L)	7.94
ACTH (8 am, pg/mL)	< 5.00
Cortisol (8 am, 5-25 µg/dL)	< 1.00
LH (1.8-11.78 mIU/mL)	0.09
FSH (3.03-8.08 mIU/mL)	< 0.05
Testosterone (10.83-56.94 ng/dL)	< 3.82
Estradiol (21-251 pg/mL)	< 10.00
Progesterone (0.00-0.30 ng/mL)	< 0.10
Prolactin (5.18-26.53 ng/mL)	44.60

IGF-1: Insulin-like growth factor-I; TSH: Thyroid stimulating hormone; FT3: Free triiodothyronine; FT4: Free thyroxine; ACTH: Adrenocorticotropic hormone; LH: Luteinizing hormone; FSH: Follicle stimulating hormone.

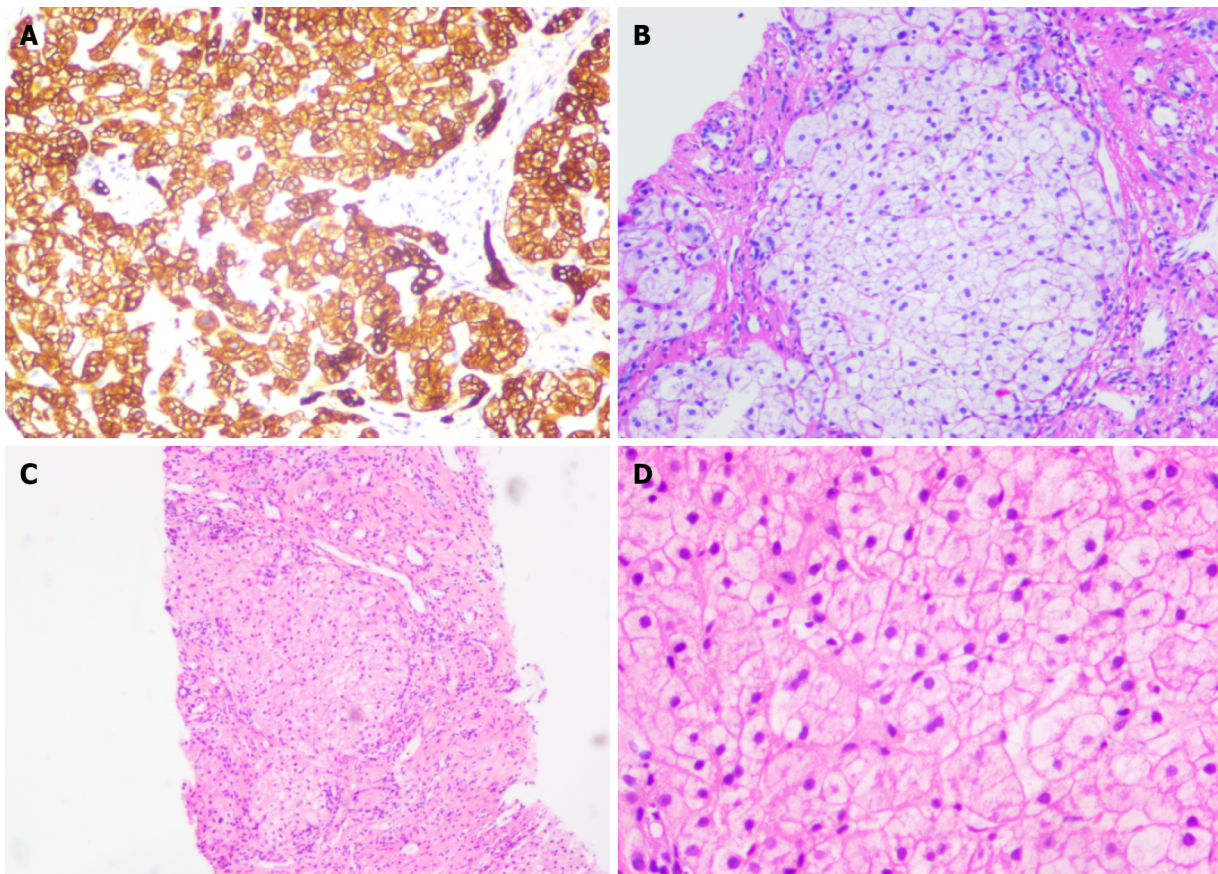


DOI: 10.12998/wjcc.v10.i18.6211 Copyright ©The Author(s) 2022.

**Figure 1 Ultrasonography.** A: Right echocardiography revealed diffuse arteriovenous shunt in the lung (grade III > 100/frame), consistent with hepatopulmonary syndrome; B: Abdominal ultrasound displayed bile duct dilatation, cirrhosis, and splenomegaly.

intractable diabetes insipidus hypothalamic-pituitary insufficiency, severe electrolyte disorder, and neuropsychological defects, which seriously affect the quality of life of children.

NAFLD is a chronic liver disease worldwide, and its incidence is increasing with the prevalence of obesity, diabetes, and metabolic syndrome. Statistically, the global incidence is 25% [6]. NAFLD is histologically classified into NAFLD and NASH, cirrhosis, and hepatocellular carcinoma. NAFLD and NASH are associated with hypothalamic hypopituitarism, but their pathogeneses remain unclear, and an increasing number of studies have found that the development of NASH is closely related to endocrine hormone abnormalities [7]. In children, it is caused by craniopharyngioma or pituitary adenoma and sequelae of treatment, leading to hypothyroidism, adrenal insufficiency, hypogonadotropism, and GH deficiency [8]. Adams *et al* [9] reported 21 cases of NAFLD, among which 15 were secondary after brain tumor surgery (approximately 71%), suggesting that brain tumor near the pituitary hypothalamus is an important cause of NAFLD. More than 50% (eight cases) of these tumors were craniopharyngiomas, suggesting the importance of careful diagnosis and exclusion of this type of tumor in the presence of clinically unexplained NAFLD [9]. Jung *et al* [10] reported the case of a 19-year-old girl diagnosed with craniopharyngioma who developed hypothalamic obesity, NAFLD, and



DOI: 10.12998/wjcc.v10.i18.6211 Copyright ©The Author(s) 2022.

**Figure 2** Pathological images of liver biopsy. A: Immunohistochemical staining for CK818 ( $\times 200$ ); B: dPAS staining ( $\times 200$ ); C: HE staining ( $\times 50$ ); D: HE staining ( $\times 200$ ). Nodular cirrhosis (consider the origin of nonalcoholic steatohepatitis).

progression to HPS after tumor resection[10]. Recently, studies on patients with hypothalamic-pituitary involvement after craniopharyngioma have found that the prevalence of NAFLD in children is approximately 3%–10%, while the incidence of NAFLD caused by hypothalamic-pituitary damage after craniopharyngioma has increased to approximately 50% [11,12]. Previously, it was generally believed that the risk factors for NAFLD were excessive fructose intake, insulin resistance, and metabolic syndrome, followed by oxidative stress injury and endoplasmic reticulum stress, adipocytokine, mitochondrial dysfunction, and bisphenol A intake[13,14].

In a retrospective study that reported the association between hypopituitarism, hypothalamic dysfunction, and NAFLD, NAFLD was found in 2.3% of patients with hypopituitarism and hypothalamic obesity[15]. Moreover, a recent analysis of long-term outcomes after childhood-onset craniopharyngioma found that 1 of 32 patients (3%) died of cirrhosis[16].

The risk of progression from childhood simple fatty liver to adult cirrhosis and liver failure is low, and the natural course of NAFLD in patients with hypothalamic and pituitary dysfunction may be more aggressive than that in the general population. Therefore, children with craniopharyngioma should be closely followed postoperatively, especially for liver function and pituitary hormone levels. Some scholars have reported NASH 4 years after pituitary tumor resection, accompanied by dyspnea and hypoxemia, which eventually developed into HPS[17]. HPS is a serious complication of chronic liver disease, which includes three main characteristics: Abnormal liver function, pulmonary telangiectasia (shunt), and hypoxemia[18]. It is a progressive disease that is a complication of cirrhosis or portal hypertension. The main clinical manifestations are dyspnea and cyanosis. At this point, the exact pathogenesis of HPS is still unclear, and is most likely thought to occur due to vasodilatation caused by nitric oxide[19], which increases pulmonary blood flow and cardiac output, leading to pulmonary ventilation-perfusion mismatch and arteriovenous shunts, ultimately making it difficult for oxygen molecules to bind with hemoglobin, and resulting in hypoxemia[20,21]. Currently, liver transplantation is the accepted treatment. Despite successful liver transplantation, NAFLD has a high recurrence rate. Therefore, the prospects for the treatment of NAFLD and HPS secondary to craniopharyngioma are not optimistic, and the need for liver transplantation should be carefully considered. We present the case of a 13-year-old girl with hypopituitarism following surgery for craniopharyngioma; particularly, GH deficiency resulted in slow-progressive NASH, which progressed to cirrhosis, and HPS was eventually diagnosed. After GH replacement therapy, liver biochemical indexes and hypoxemia were significantly

improved. Therefore, it is speculated that GH may provide a new approach for the treatment of HPS in the future. An 11-year-old boy from Japan was reported to have developed hypopituitarism after surgical resection of a pituitary tumor and subsequently progressed to NASH and HPS. He underwent living-donor liver transplantation at 15 years of age and developed NAFLD again 1 year after transplantation; GH replacement therapy improved liver function, which stabilized to the normal range during 10 years of follow-up[17]. Kodama *et al*[22] and Torii *et al*[23] reported that GH replacement therapy improved NASH and HPS[22,23]. A 29-year-old man with pituitary stalk interruption syndrome progressed slowly to HPS, and after 14 mo of treatment with recombinant human GH, the liver function and hypoxemia improved, and liver fibrosis did not progress[24].

Recent studies have demonstrated an increased prevalence of NASH in adult patients with GH deficiency and improvement in liver function impairment after GH replacement therapy. Although it is unclear whether GH replacement therapy directly or indirectly reduces oxidative stress in the liver, GH has antioxidant stress effects *in vivo*. GH can directly reduce adipogenesis in liver cells and simultaneously regulate the production of IGF1, which can induce cell senescence and inactivate hepatic stellate cells, thus improving liver fibrosis[25].

---

## CONCLUSION

Craniopharyngioma in children likely damages the pituitary gland and leads to hypopituitarism, regardless of its unique location or treatment with surgery or radiotherapy. Hypopituitarism in children is likely to develop into NASH, cirrhosis, and even HPS. In this study, GH replacement therapy significantly improved liver function, metabolic status, and hypoxemia, providing new clinical support for the early diagnosis and treatment of NASH and HPS in children with hypopituitarism.

---

## FOOTNOTES

**Author contributions:** Zhang XY and Wang CL conceived and designed the study; Zhang XY and Yuan K provided clinical research; Zhang XY wrote the paper; Zhang XY, Yuan K, Fang YL, and Wang CL reviewed and edited the manuscript; all authors read and approved the manuscript.

**Informed consent statement:** Informed written consent was obtained from the patient for the publication of this report and any accompanying images.

**Conflict-of-interest statement:** The authors declare that they have no conflicts of interest related to this manuscript.

**CARE Checklist (2016) statement:** The authors have read the CARE Checklist (2016), and the manuscript was prepared and revised according to the CARE Checklist (2016).

**Open-Access:** This article is an open-access article that was selected by an in-house editor and fully peer-reviewed by external reviewers. It is distributed in accordance with the Creative Commons Attribution NonCommercial (CC BY-NC 4.0) license, which permits others to distribute, remix, adapt, build upon this work non-commercially, and license their derivative works on different terms, provided the original work is properly cited and the use is non-commercial. See: <https://creativecommons.org/licenses/by-nc/4.0/>

**Country/Territory of origin:** China

**ORCID number:** Xiao-Yuan Zhang 0000-0003-1607-2490; Ke Yuan 0000-0002-0458-3683; Yan-Lan Fang 0000-0001-6579-417X; Chun-Lin Wang 0000-0002-4273-1341.

**S-Editor:** Fan JR

**L-Editor:** Wang TQ

**P-Editor:** Fan JR

---

## REFERENCES

- 1 Marino L, Jornayvaz FR. Endocrine causes of nonalcoholic fatty liver disease. *World J Gastroenterol* 2015; **21**: 11053-11076 [PMID: 26494962 DOI: 10.3748/wjg.v21.i39.11053]
- 2 Lustig RH. Hypothalamic obesity after craniopharyngioma: mechanisms, diagnosis, and treatment. *Front Endocrinol (Lausanne)* 2011; **2**: 60 [PMID: 22654817 DOI: 10.3389/fendo.2011.00060]
- 3 Eveslage M, Calaminus G, Warmuth-Metz M, Kortmann RD, Pohl F, Timmermann B, Schuhmann MU, Flitsch J, Faldum A, Müller HL. The Postoperative Quality of Life in Children and Adolescents with Craniopharyngioma. *Dtsch Arztebl Int* 2019; **116**: 321-328 [PMID: 31219033 DOI: 10.3238/arztebl.2019.0321]

- 4 Müller HL. Craniopharyngioma. *Endocr Rev* 2014; **35**: 513-543 [PMID: 24467716 DOI: 10.1210/er.2013-1115]
- 5 Chen X, Tong Y, Shi Z, Chen H, Yang Z, Wang Y, Chen L, Yu J. Noninvasive molecular diagnosis of craniopharyngioma with MRI-based radiomics approach. *BMC Neurol* 2019; **19**: 6 [PMID: 30616515 DOI: 10.1186/s12883-018-1216-z]
- 6 Kim U, Kim N, Shin HY. Modeling Non-Alcoholic Fatty Liver Disease (NAFLD) Using "Good-Fit" Genome-Editing Tools. *Cells* 2020; **9** [PMID: 33271878 DOI: 10.3390/cells9122572]
- 7 Singeap AM, Stanciu C, Huiban L, Muzica CM, Cuciureanu T, Girleanu I, Chiriac S, Zenovia S, Nastasa R, Sfarti C, Cojocariu C, Trifan A. Association between Nonalcoholic Fatty Liver Disease and Endocrinopathies: Clinical Implications. *Can J Gastroenterol Hepatol* 2021; **2021**: 6678142 [PMID: 33505943 DOI: 10.1155/2021/6678142]
- 8 Gilliland T, Dufour S, Shulman GI, Petersen KF, Emre SH. Resolution of non-alcoholic steatohepatitis after growth hormone replacement in a pediatric liver transplant patient with panhypopituitarism. *Pediatr Transplant* 2016; **20**: 1157-1163 [PMID: 27762491 DOI: 10.1111/ptr.12819]
- 9 Adams LA, Feldstein A, Lindor KD, Angulo P. Nonalcoholic fatty liver disease among patients with hypothalamic and pituitary dysfunction. *Hepatology* 2004; **39**: 909-914 [PMID: 15057893 DOI: 10.1002/hep.20140]
- 10 Jung D, Seo GH, Kim YM, Choi JH, Yoo HW. Hepatopulmonary syndrome caused by hypothalamic obesity and nonalcoholic fatty liver disease after surgery for craniopharyngioma: a case report. *Ann Pediatr Endocrinol Metab* 2018; **23**: 51-55 [PMID: 29609450 DOI: 10.6065/apem.2018.23.1.51]
- 11 Hoffmann A, Bootsveld K, Gebhardt U, Daubenbüchel AM, Sterkenburg AS, Müller HL. Nonalcoholic fatty liver disease and fatigue in long-term survivors of childhood-onset craniopharyngioma. *Eur J Endocrinol* 2015; **173**: 389-397 [PMID: 26088821 DOI: 10.1530/EJE-15-0422]
- 12 Della Corte C, Mazzotta AR, Nobili V. Fatty liver disease and obesity in youth. *Curr Opin Endocrinol Diabetes Obes* 2016; **23**: 66-71 [PMID: 26702852 DOI: 10.1097/MED.0000000000000221]
- 13 Sandlers Y, Shah RR, Pearce RW, Dasarathy J, McCullough AJ, Dasarathy S. Plasma Krebs Cycle Intermediates in Nonalcoholic Fatty Liver Disease. *J Clin Med* 2020; **9** [PMID: 31979094 DOI: 10.3390/jcm9020314]
- 14 Paradies G, Paradies V, Ruggiero FM, Petrosillo G. Oxidative stress, cardiolipin and mitochondrial dysfunction in nonalcoholic fatty liver disease. *World J Gastroenterol* 2014; **20**: 14205-14218 [PMID: 25339807 DOI: 10.3748/wjg.v20.i39.14205]
- 15 Simoneau-Roy J, O'Gorman C, Pencharz P, Adeli K, Daneman D, Hamilton J. Insulin sensitivity and secretion in children and adolescents with hypothalamic obesity following treatment for craniopharyngioma. *Clin Endocrinol (Oxf)* 2010; **72**: 364-370 [PMID: 19486023 DOI: 10.1111/j.1365-2265.2009.03639.x]
- 16 Sterkenburg AS, Hoffmann A, Gebhardt U, Warmuth-Metz M, Daubenbüchel AM, Müller HL. Survival, hypothalamic obesity, and neuropsychological/psychosocial status after childhood-onset craniopharyngioma: newly reported long-term outcomes. *Neuro Oncol* 2015; **17**: 1029-1038 [PMID: 25838139 DOI: 10.1093/neuonc/nov044]
- 17 Fujio A, Kawagishi N, Echizenya T, Tokodai K, Nakanishi C, Miyagi S, Sato K, Fujimori K, Ohuchi N. Long-term survival with growth hormone replacement after liver transplantation of pediatric nonalcoholic steatohepatitis complicating acquired hypopituitarism. *Tohoku J Exp Med* 2015; **235**: 61-67 [PMID: 25744617 DOI: 10.1620/tjem.235.61]
- 18 Kim KY, Kim TH, Lee JM, Yi NJ, Kim HY, Moon JS, Ko JS. Clinical outcomes and risk factors of hepatopulmonary syndrome in children. *Sci Rep* 2021; **11**: 4134 [PMID: 33603173 DOI: 10.1038/s41598-021-83785-x]
- 19 Fallon MB. Mechanisms of pulmonary vascular complications of liver disease: hepatopulmonary syndrome. *J Clin Gastroenterol* 2005; **39**: S138-S142 [PMID: 15758649]
- 20 Lv Y, Fan D. Hepatopulmonary Syndrome. *Dig Dis Sci* 2015; **60**: 1914-1923 [PMID: 25732713 DOI: 10.1007/s10620-015-3593-0]
- 21 Ikubo Y, Kasai H, Sugiura T, Saito T, Shoji H, Sakao S, Kasahara Y, Tanabe N, Tatsumi K. Pulmonary Hypertension that Developed During Treatment for Hepatopulmonary Syndrome and Pulmonary Arteriovenous Malformation. *Intern Med* 2019; **58**: 1765-1769 [PMID: 30799344 DOI: 10.2169/internalmedicine.1993-18]
- 22 Kodama K, Ichihara A, Seki Y, Ikarashi Y, Sagawa T, Kogiso T, Taniyai M, Tokushige K. Characteristics of NAFLD Based on Hypopituitarism. *Can J Gastroenterol Hepatol* 2020; **2020**: 8814435 [PMID: 33102399 DOI: 10.1155/2020/8814435]
- 23 Torii N, Ichihara A, Mizuguchi Y, Seki Y, Hashimoto E, Tokushige K. Hormone-replacement Therapy for Hepatopulmonary Syndrome and NASH Associated with Hypopituitarism. *Intern Med* 2018; **57**: 1741-1745 [PMID: 29910217 DOI: 10.2169/internalmedicine.0027-17]
- 24 Ji W, Nie M, Mao JF, Zhang HB, Wang X, Wu XY. Growth hormone cocktail improves hepatopulmonary syndrome secondary to hypopituitarism: A case report. *World J Clin Cases* 2021; **9**: 4852-4858 [PMID: 34222458 DOI: 10.12998/wjcc.v9.i18.4852]
- 25 Takahashi Y. The Role of Growth Hormone and Insulin-Like Growth Factor-I in the Liver. *Int J Mol Sci* 2017; **18** [PMID: 28678199 DOI: 10.3390/ijms18071447]



Published by **Baishideng Publishing Group Inc**  
7041 Koll Center Parkway, Suite 160, Pleasanton, CA 94566, USA  
**Telephone:** +1-925-3991568  
**E-mail:** [bpgoffice@wjgnet.com](mailto:bpgoffice@wjgnet.com)  
**Help Desk:** <https://www.f6publishing.com/helpdesk>  
<https://www.wjgnet.com>

