

Migration of a biliary stent causing duodenal perforation and biliary peritonitis

Hussain Issa, Mamdouh Nahawi, Bahaa Bseiso, Ahmed Al-Salem

Hussain Issa, Baha Bseiso, Department of Internal Medicine, King Fahad Specialist Hospital, Dammam 32253-3202, Saudi Arabia

Mamdouh Nahawi, Department of Surgery, King Fahad Specialist Hospital, Dammam 32253-3202, Saudi Arabia

Ahmed Al-Salem, Department of Pediatric Surgery, Maternity and Children Hospital, Dammam 32253-3202, Saudi Arabia

Author contributions: Issa H, Nahawi M and Beseiso B collected the data and reviewed the manuscript; Issa H and Al-Salem A revised the manuscript; Issa H managed the patient; Nahawi M operated on the patient; Al-Salem A wrote the manuscript.

Correspondence to: Dr. Ahmed Al-Salem, Department of Pediatric Surgery, Maternity and Children Hospital, PO Box 61015, Qatif 31911, Saudi Arabia. ahsalsalem@hotmail.com

Telephone: +966-5-46102999 Fax: +966-1-38630009

Received: July 15, 2013 Revised: August 26, 2013

Accepted: September 3, 2013

Published online: October 16, 2013

Abstract

Migration of endoscopically placed biliary stents is a well-recognized complication of endoscopic retrograde cholangiopancreatography. Less than 1% of migrated stents however cause intestinal perforation. We present a case of a migrated biliary stent that resulted in duodenal perforation and biliary peritonitis.

© 2013 Baishideng. All rights reserved.

Key words: Biliary stents; Migration; Duodenal perforation; Biliary peritonitis

Core tip: Biliary stent migration complicated by duodenal perforation is rare and should be included in the differential diagnosis of those presenting with abdominal pain after endoscopic retrograde cholangiopancreatography with stent placement and physicians caring for these patients should be aware of such complication. To reduce the chance of stent migration, endoscopists should assess for the size and shape of

the stent in each patient.

Issa H, Nahawi M, Bseiso B, Al-Salem A. Migration of a biliary stent causing duodenal perforation and biliary peritonitis. *World J Gastrointest Endosc* 2013; 5(10): 523-526 Available from: URL: <http://www.wjgnet.com/1948-5190/full/v5/i10/523.htm> DOI: <http://dx.doi.org/10.4253/wjge.v5.i10.523>

INTRODUCTION

The use of biliary stents was introduced in the late 1970s, and since then endoscopic and percutaneous insertion of biliary stents is the treatment of choice as a palliative measure for patients suffering from obstructive jaundice secondary to unresectable malignant hepatobiliary tract tumors and to relieve obstruction of the bile ducts secondary to benign stricture or choledocholithiasis^[1,2].

Biliary stents however are not without complications. The complication rate ranges between 8% and 10%, with a mortality rate below 1%^[3-5]. Complications specific to the stents include migration, occlusion, and intestinal perforation. Migration of endoscopically placed biliary stents is a well-recognized complication of endoscopic retrograde cholangiopancreatography (ERCP). Serious complications can result from stent migration but fortunately less than 1% of migrated stents cause intestinal perforation. Of those that do perforate the bowel, the vast majority occur in the duodenum^[5-7]. There have been several case reports of intestinal perforation distal to the duodenum including the small intestines, cecum, right side of colon and sigmoid colon^[8-15]. Although the majority of migrated stents pass spontaneously or can be retrieved using endoscopy and fluoroscopy, few of them can cause biliary peritonitis necessitating an emergency laparotomy. This report describes an unusual case of biliary stent migration where part of the stent remained in the common bile duct and the rest perforated the

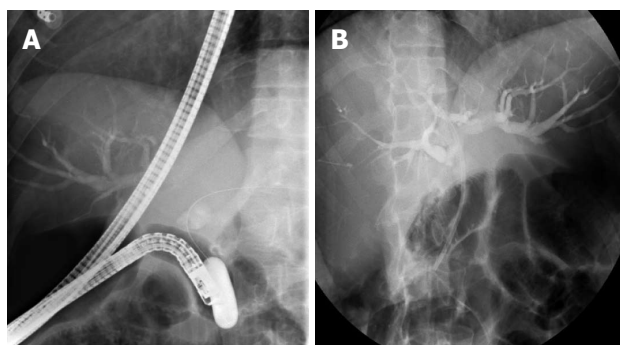


Figure 1 Endoscopic retrograde cholangiopancreatography which showed dilated common bile duct (A) and intra hepatic biliary radicles dilation (B) followed by insertion of 10 Fr × 10 cm endobiliary plastic stent.

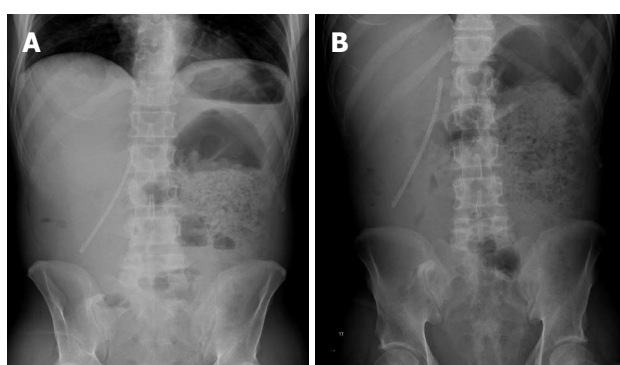


Figure 2 Abdominal X-rays showing an abnormal position of the biliary stent highly suspicious of distal migration with free air (A) and markedly dilated left side of colon and retained fecal material (B).

duodenum causing biliary peritonitis.

CASE REPORT

A 51-year-old male presented to the emergency department complaining of severe abdominal pain, constipation, vomiting and progressive jaundice over a period of 3 d. He underwent an abdominal ultrasound and computed tomography (CT) scan which showed distended gallbladder with no stones, dilated common bile duct up to 17.5 mm with a 9 mm stone in the distal common bile duct (CBD) and intra hepatic biliary radicles dilation. He underwent an ERCP in his primary hospital which failed due to an abnormal anatomy as reported. A second ERCP two weeks prior to his presentation was technically difficult, prolonged with a lot of manipulation and maneuvers to gain a biliary access. Sphincterotomy was done and there was a suspicious distal biliary stricture for which controlled radial expansion balloon dilation up to 15 mm was done followed by insertion of 10 French, 10 cm long endobiliary plastic stent (Figure 1). At the time of presentation to our hospital, he was ill looking, in pain, deeply jaundiced. His temperature was 37.3 °C, blood pressure 122/60 mmHg, and pulse 120 per minute. Abdominal examination showing distended abdomen with diffuse tenderness and rigidity, and sluggish bowel

sounds. Cellular blood count showed leucocytosis 21.56×10^9 /L, Hb 14 g/dL, Platelets 368×10^9 /L. Liver panel showed total bilirubin 74.65 $\mu\text{mol/L}$, direct bilirubin 35 $\mu\text{mol/L}$, alkaline phosphatase 269 U/L, γ -glutamyl transpeptidase 417 U/L, alanine aminotransaminase 50 U/L, aspartate aminotransferase 73 U/L. Abdominal X-ray showed an abnormal position of the biliary stent highly suspicious of distal migration with markedly dilated left colon segment (Figure 2). Urgent abdominal CT-scan was done which confirmed the inferior migration of the biliary stent causing perforation of the second part of duodenum, with protrusion of the stent into the peritoneal cavity causing biliary peritonitis (Figure 3). He was covered with antibiotics and underwent an urgent laparotomy which showed the stent penetrating the second part of duodenum and draining bile into the peritoneal cavity causing biliary peritonitis (Figure 4). The perforation was closed and the closure was reinforced using an omental patch. Postoperatively, he did well and was discharged on the 12th postoperative day.

DISCUSSION

In 1980 Soehendra *et al*^[16] introduced transpapillary biliary drainage using plastic biliary stent. Since then biliary stents are often used for the treatment of benign obstructive biliary disease. Biliary stents nevertheless causes serious complications and one of these is stent migration which occurs in up to 10% of patients^[2-4]. This is more so in those with benign pathology without severe stenosis of the bile duct or papilla. Malignant strictures, larger diameter stents, and short stents are known to be associated with proximal biliary stent migration. Stent related factors such as the type of stent, length and caliber of the stent offer potential avenues to minimize the risk of migration. The presence of previous abdominal surgeries is an important factor for endoscopists to ascertain the location of a migrated stent. Fortunately, most of these stents can be retrieved using endoscopy and if the stent migrates to the intestines, then 43% pass spontaneously^[4,5]. Arhan *et al*^[5] in a review of 204 plastic biliary stents for benign biliary disease reported a migration rate of 13.4% with an equal proportion of stents found in the proximal and distal gastrointestinal tract. All of the migrated stents were retrieved without complication. This however is not the case always and occasionally biliary stents impact and perforate the intestines, usually in the fixed parts namely the duodenum and right side of the colon or in other fixed areas of the intestines because of adhesions due to a previous operation. There are also reports of biliary stents causing bowel perforation through bowel loops incarcerated in a hernial sac, in duodenal diverticula, in a colon diverticulum and also in healthy sigmoid colon^[8-10,14,15].

Biliary stent migration is not unusual and may result in intramural or transmural intestinal perforation. The perforation can be retroperitoneal in duodenal perforation causing bilioma or the perforation can be intra-

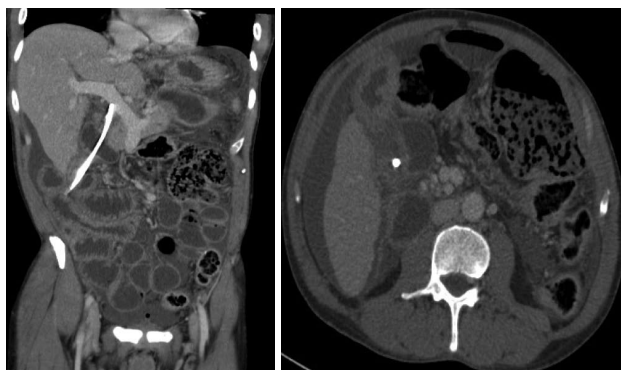


Figure 3 Computed tomography-scan of the abdomen which confirmed the inferior migration of the biliary stent causing perforation of the second part of duodenum, with protrusion of the stent into the peritoneal cavity causing biliary peritonitis.

peritoneal leading to biliary peritonitis^[13,17]. Our case is unique as the stent was found partly in the biliary duct and the rest perforated the duodenum causing bile leak with total bile diversion into the peritoneal cavity and biliary peritonitis. In these patients there are signs of peritonitis and radiological images will show the stent outside the intestinal wall. Ang *et al*^[18] described a case of duodenocolic fistula caused by a stent and Rosés *et al*^[17] described the case of a plastic stent perforating the duodenal wall causing a retroperitoneal duodenal perforation and bilioma. Figueiras *et al*^[19] reported a colocutaneous fistula secondary to the migration of a biliary stent.

The majority of migrating biliary stents pass spontaneously but whenever a perforation is suspected, operative extraction is the treatment of choice. There is a report stressing the successful endoscopic extraction of the migrating stent and clip placement in the duodenal perforation^[17]. This was however in a patient with a biliary stent causing a localized retroperitoneal duodenal perforation and bilioma. Others have reported the successful percutaneous extraction of migrating biliary stents^[20]. In our case, the perforation was in the peritoneal cavity and part of the stent was still in the biliary ducts causing biliary diversion into the peritoneal cavity and although percutaneous retrieval of the stent was possible, the fact that the patient was already having biliary peritonitis made operative extraction and closure of duodenal perforation the appropriate choice.

In conclusion, biliary stent migration complicated by duodenal perforation is rare and should be included in the differential diagnosis of those presenting with abdominal pain after ERCP with stent placement and physicians caring for these patients should be aware of such complication. Radiologically, it is possible to locate the site of stent migration and perforation and in the presence of peritonitis, surgery is the treatment of choice. To reduce the chance of stent migration, endoscopists should assess for the size and shape of the stent in each patient. A straight biliary stent may migrate since there is nothing to hold it in place, even though there are side flaps. Inappropriately long stent may exert pressure on

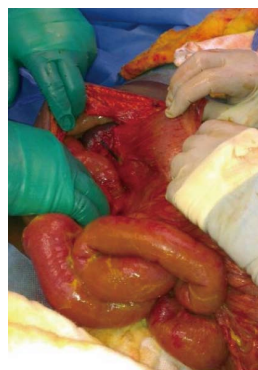

Figure 4 Intraoperative photograph showing the stent perforating the duodenum and protruding into the peritoneal cavity.

the duodenal wall causing tissue necrosis and perforation. Curved (Amsterdam) stent or a double pigtail biliary stent may be associated with less migration and perforation.

REFERENCES

- 1 **Lammer J**, Neumayer K. Biliary drainage endoprosthesis: experience with 201 placements. *Radiology* 1986; **159**: 625-629 [PMID: 2422677]
- 2 **Mueller PR**, Ferrucci JT, Teplick SK, vanSonnenberg E, Haskin PH, Butch RJ, Papanicolaou N. Biliary stent endoprosthesis: analysis of complications in 113 patients. *Radiology* 1985; **156**: 637-639 [PMID: 4023221]
- 3 **Johanson JF**, Schmalz MJ, Geenen JE. Incidence and risk factors for biliary and pancreatic stent migration. *Gastrointest Endosc* 1992; **38**: 341-346 [PMID: 1607087 DOI: 10.1016/S0016-5107(92)70429-5]
- 4 **Chaurasia OP**, Rauws EA, Fockens P, Huibregtse K. Endoscopic techniques for retrieval of proximally migrated biliary stents: the Amsterdam experience. *Gastrointest Endosc* 1999; **50**: 780-785 [PMID: 10570336 DOI: 10.1016/S0016-5107(99)70158-6]
- 5 **Arhan M**, Odemiş B, Parlak E, Ertuğrul I, Başar O. Migration of biliary plastic stents: experience of a tertiary center. *Surg Endosc* 2009; **23**: 769-775 [PMID: 18649099 DOI: 10.1007/s00464-008-0067-x]
- 6 **Diller R**, Senninger N, Kautz G, Tübergen D. Stent migration necessitating surgical intervention. *Surg Endosc* 2003; **17**: 1803-1807 [PMID: 14508668 DOI: 10.1007/s00464-002-9163-5]
- 7 **Saranga Bharathi R**, Rao P, Ghosh K. Iatrogenic duodenal perforations caused by endoscopic biliary stenting and stent migration: an update. *Endoscopy* 2006; **38**: 1271-1274 [PMID: 17163332 DOI: 10.1055/s-2006-944960]
- 8 **Anderson EM**, Phillips-Hughes J, Chapman R. Sigmoid colonic perforation and pelvic abscess complicating biliary stent migration. *Abdom Imaging* 2007; **32**: 317-319 [PMID: 16944034 DOI: 10.1007/s00261-006-9067-2]
- 9 **Elliott M**, Boland S. Sigmoid colon perforation following a migrated biliary stent. *ANZ J Surg* 2003; **73**: 669-670 [PMID: 12887548 DOI: 10.1046/j.1445-2197.2003.02698.x]
- 10 **Akimboye F**, Lloyd T, Hobson S, Garcea G. Migration of endoscopic biliary stent and small bowel perforation within an incisional hernia. *Surg Laparosc Endosc Percutan Tech* 2006; **16**: 39-40 [PMID: 16552378 DOI: 10.1097/01.sle.0000202198.74569.5a]
- 11 **Esterl RM**, St Laurent M, Bay MK, Speeg KV, Half GA. Endoscopic biliary stent migration with small bowel perforation in a liver transplant recipient. *J Clin Gastroenterol* 1997; **24**: 106-110 [PMID: 9077729 DOI: 10.1097/00004836-19970300-00014]
- 12 **Lanteri R**, Naso P, Rapisarda C, Santangelo M, Di Cataldo

- A, Licata A. Jejunal perforation for biliary stent dislocation. *Am J Gastroenterol* 2006; **101**: 908-909 [PMID: 16635240 DOI: 10.1111/j.1572-0241.2006.00509.x]
- 13 **Størkson RH**, Edwin B, Reiertsen O, Faerden AE, Sortland O, Rosseland AR. Gut perforation caused by biliary endoprosthesis. *Endoscopy* 2000; **32**: 87-89 [PMID: 10691280 DOI: 10.1055/s-2000-87]
- 14 **Schaafsma RJ**, Spoelstra P, Pakan J, Huibregtse K. Sigmoid perforation: a rare complication of a migrated biliary endoprosthesis. *Endoscopy* 1996; **28**: 469-470 [PMID: 8858249 DOI: 10.1055/s-2007-1005523]
- 15 **Mastorakos DP**, Milman PJ, Cohen R, Goldenberg SP. An unusual complication of a biliary stent-small bowel perforation of an incarcerated hernia sac. *Am J Gastroenterol* 1998; **93**: 2533-2535 [PMID: 9860420 DOI: 10.1016/S0002-9270(98)00593-0]
- 16 **Soehendra N**, Reynders-Frederix V. Palliative bile duct drainage-a new endoscopic method of introducing a transpapillary drain. *Endoscopy* 1980; **12**: 8-11 [PMID: 7353562 DOI: 10.1055/s-2007-1021702]
- 17 **Rosés LL**, Ramirez AG, Seco AL, Blanco ES, Alonso DI, Avila S, Lopez BU. Clip closure of a duodenal perforation secondary to a biliary stent. *Gastrointest Endosc* 2000; **51**: 487-489 [PMID: 10744829]
- 18 **Ang BK**, Wee SB, Kaushik SP, Low CH. Duodenal-colic fistula resulting from migration of a biliary stent: a case report. *Gastrointest Endosc* 1998; **48**: 80-83 [PMID: 9684673 DOI: 10.1016/S0016-5107(98)70137-3]
- 19 **Figueiras RG**, Echart MO, Figueiras AG, González GP. Colocutaneous fistula relating to the migration of a biliary stent. *Eur J Gastroenterol Hepatol* 2001; **13**: 1251-1253 [PMID: 11711785 DOI: 10.1097/00042737-200110000-00021]
- 20 **Bui BT**, Oliva VL, Ghattas G, Daloz P, Bourdon F, Carignan L. Percutaneous removal of a biliary stent after acute spontaneous duodenal perforation. *Cardiovasc Intervent Radiol* 1995; **18**: 200-202 [PMID: 7648600 DOI: 10.1007/BF00204152]

P- Reviewers Muguruma N, Nakai Y, Tagaya N
S- Editor Wen LL **L- Editor** A **E- Editor** Liu XM





百世登

Baishideng®

Published by **Baishideng Publishing Group Co., Limited**

Flat C, 23/F., Lucky Plaza,

315-321 Lockhart Road, Wan Chai, Hong Kong, China

Fax: +852-65557188

Telephone: +852-31779906

E-mail: bpgoffice@wjgnet.com

<http://www.wjgnet.com>

