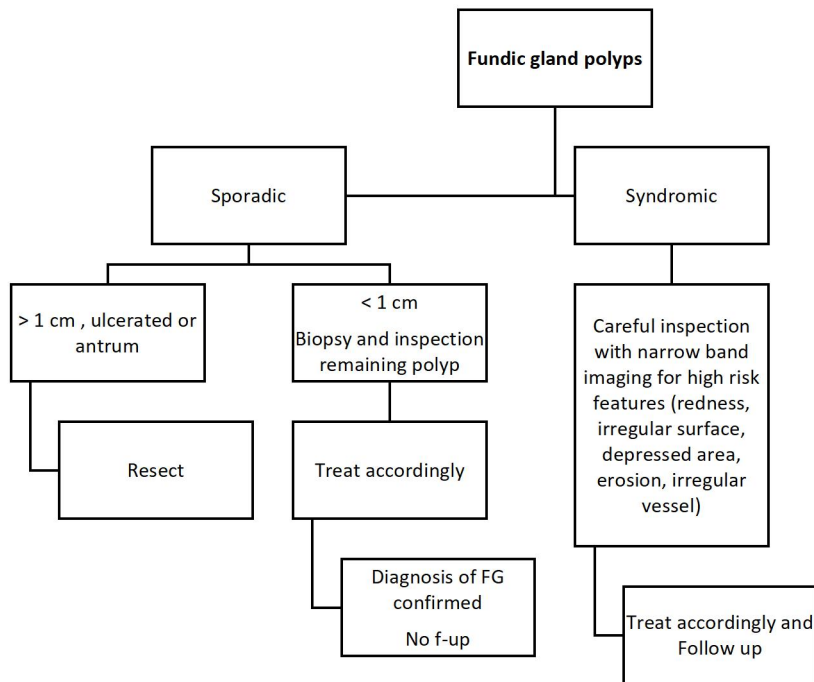
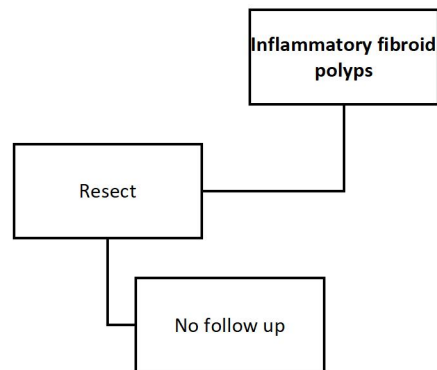


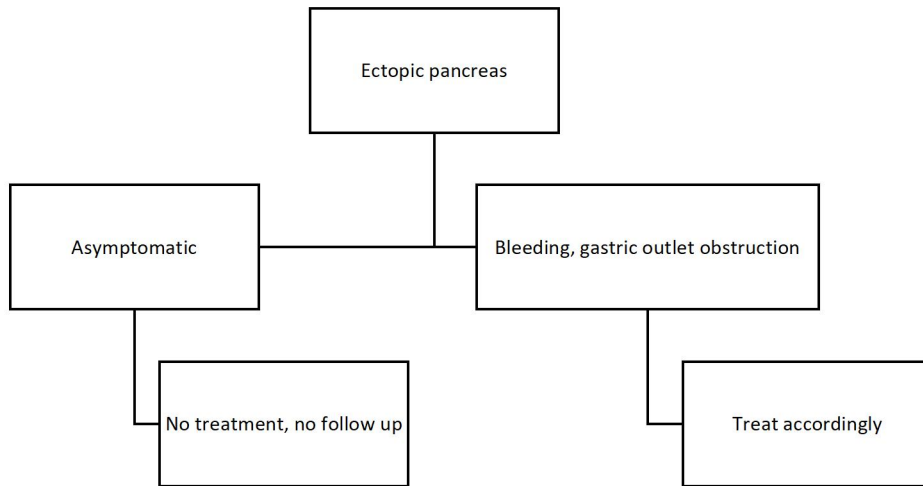
Supplementary Figures



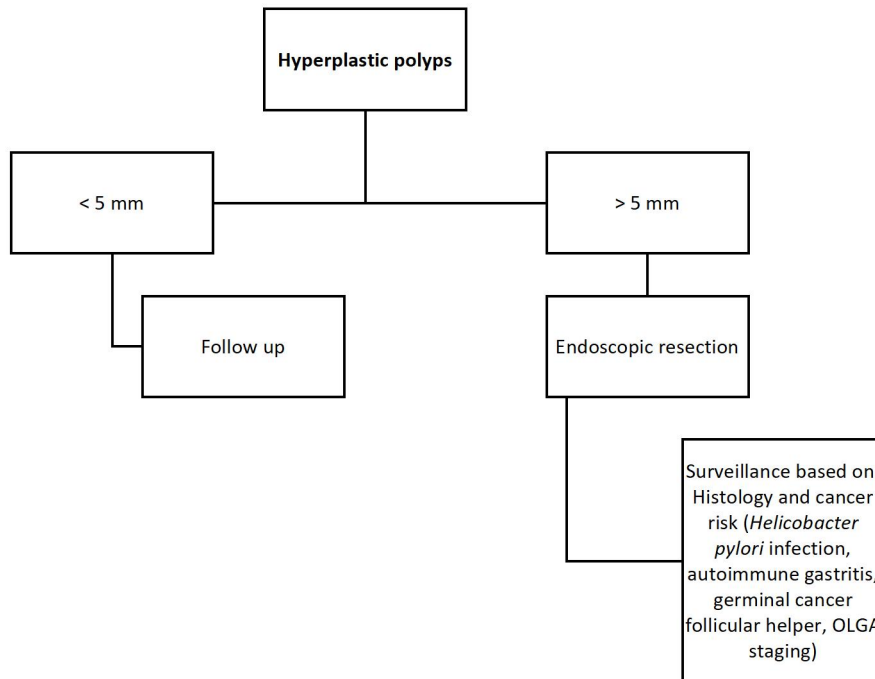
Supplementary Figure 1 Management of fundic gland polyps.



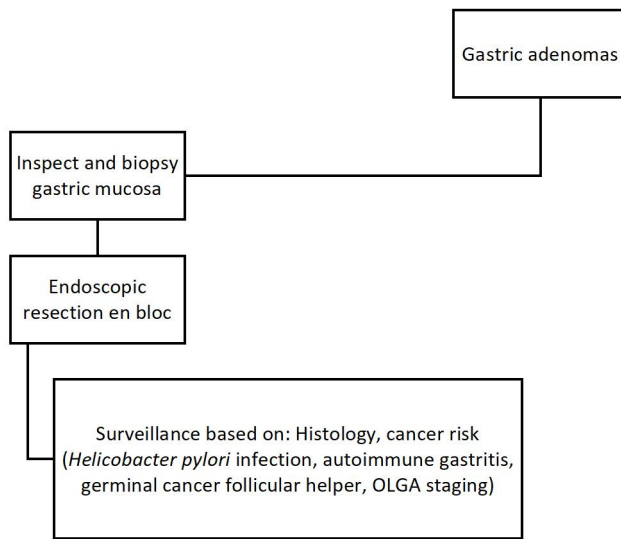
Supplementary Figure 2 Management of inflammatory fibroid polyps.



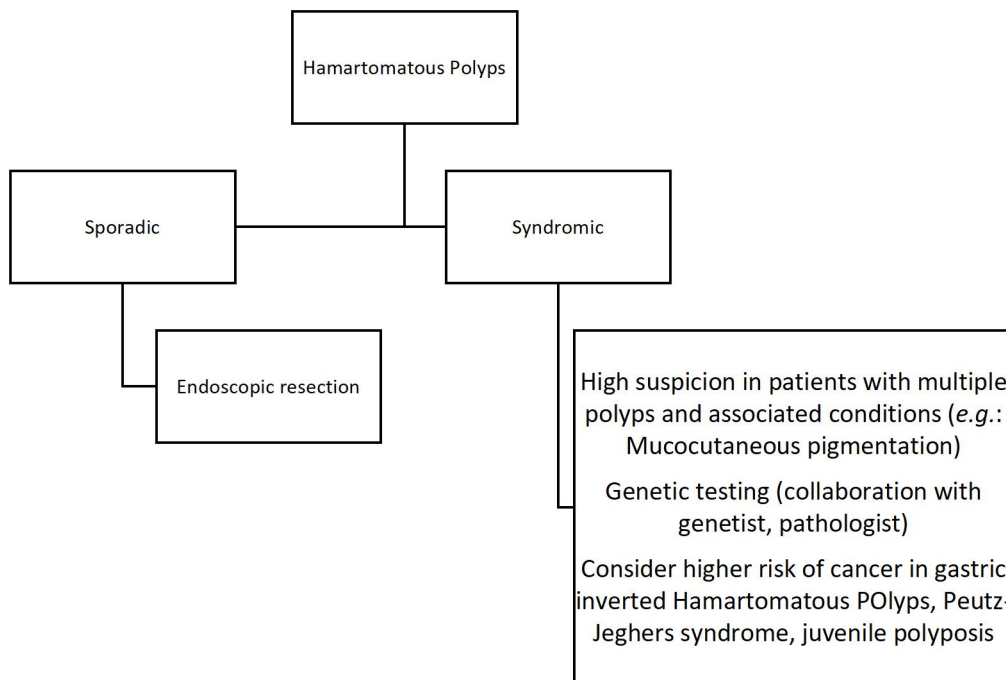
Supplementary Figure 3 Management of ectopic pancreas.



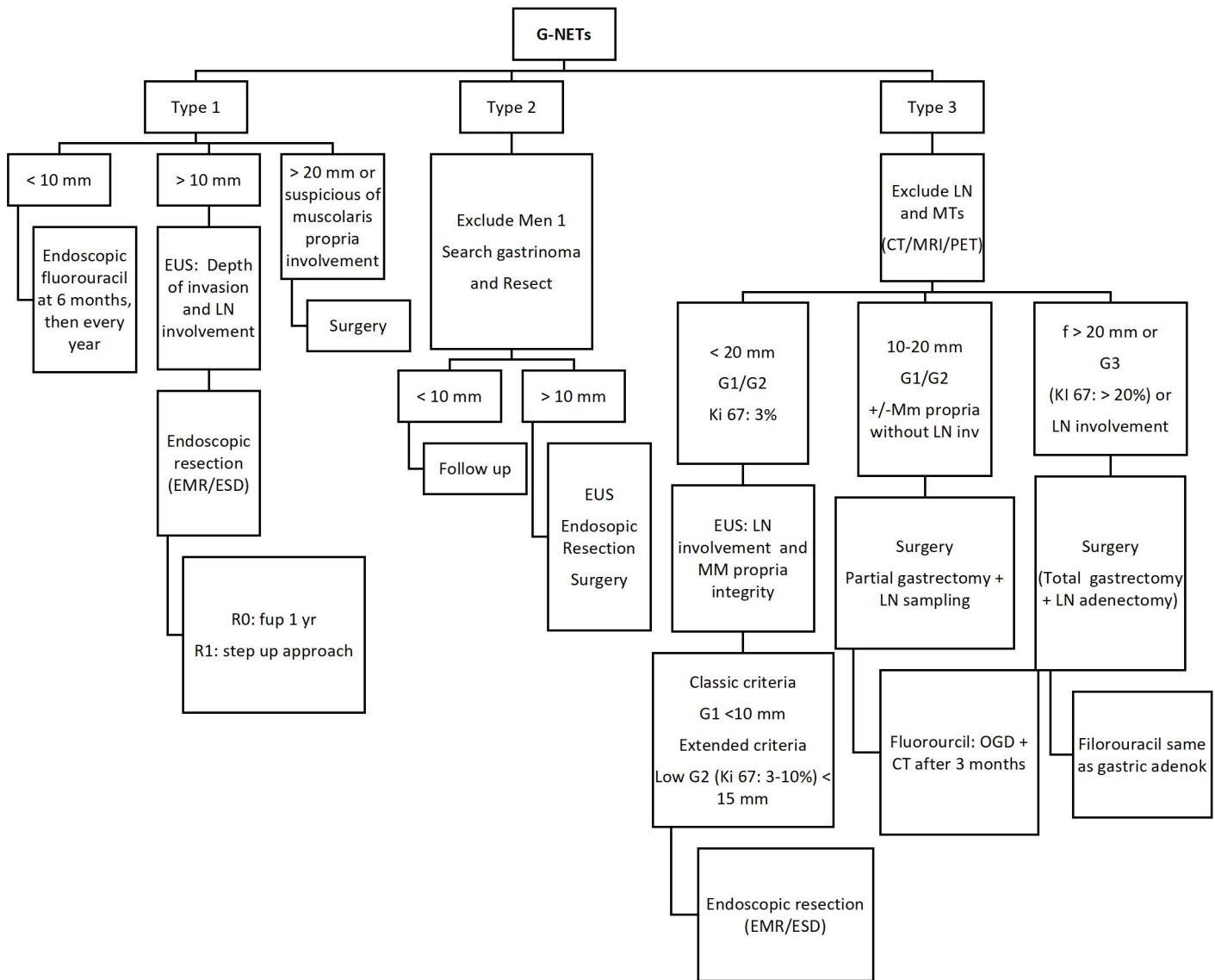
Supplementary Figure 4 Management of hyperplastic polyps.



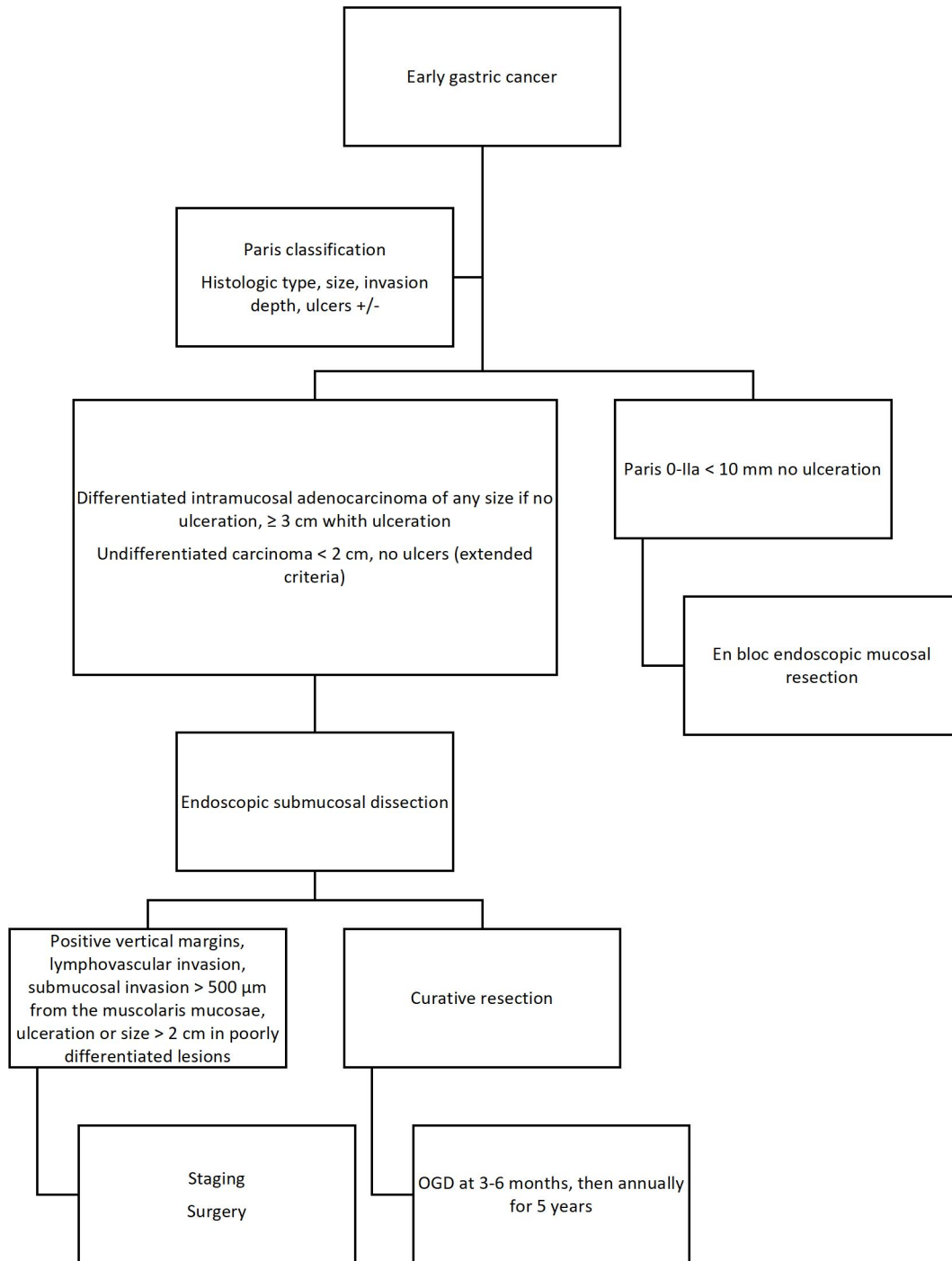
Supplementary Figure 5 Management of gastric adenomas.



Supplementary Figure 6 Management of hamartomatous polyps.



Supplementary Figure 7: Management of gastric neuroendocrine tumors. EMR/ESD: Endoscopic mucosal resection/endoscopic submucosal dissection; EUS: Endoscopic ultrasonography; LN: Lymph node; CT: Computed tomography; MRI: Multispectral radiation thermometry; PET: Positron emission tomography; OGD: Esophago-gastroduodenoscopy.



Supplementary Figure 8: Management of early gastric cancer.