

# World Journal of *Gastrointestinal Endoscopy*

Monthly Volume 17 Number 12 December 16, 2025



**EDITORIAL**

**Bagrodia A, Vaithiyam V, Laguduva Mohan S.** Large colorectal lesions: Expanding the boundaries of endoscopic management. *World J Gastrointest Endosc* 2025; 17(12): 115008 [DOI: [10.4253/wjge.v17.i12.115008](https://doi.org/10.4253/wjge.v17.i12.115008)]

**REVIEW**

**Birda CL, Dhar J, Kumar N, Mishra S, Dell'Anna G, Tandup C, Nagaraj SS, Crinò SF, Mitra V, Nabi Z, Samanta J.** Endoscopic management for gastrointestinal leaks, perforations, and fistulae: Technical tips and outcomes. *World J Gastrointest Endosc* 2025; 17(12): 111782 [DOI: [10.4253/wjge.v17.i12.111782](https://doi.org/10.4253/wjge.v17.i12.111782)]

**MINIREVIEWS**

**Wang YY, Xiang H, Xue F, Wang XQ.** Research progress on intestinal preparation before colonoscopy. *World J Gastrointest Endosc* 2025; 17(12): 109000 [DOI: [10.4253/wjge.v17.i12.109000](https://doi.org/10.4253/wjge.v17.i12.109000)]

**El Dada A, El Khoury M, Stephan P, Nehme F.** Endoscopic ultrasound-guided coil embolization for gastric varices: A promising alternative to traditional therapies. *World J Gastrointest Endosc* 2025; 17(12): 110168 [DOI: [10.4253/wjge.v17.i12.110168](https://doi.org/10.4253/wjge.v17.i12.110168)]

**Restrepo-Rodas G, Rodriguez J.** Mastering the third space: Innovations in intramural endoscopic surgery for gastrointestinal disorders. *World J Gastrointest Endosc* 2025; 17(12): 111206 [DOI: [10.4253/wjge.v17.i12.111206](https://doi.org/10.4253/wjge.v17.i12.111206)]

**Hathagoda W, Rajindrajith S, Devanarayana NM.** Upper gastrointestinal endoscopy in pediatric gastroenterology: Diagnostic and therapeutic applications. *World J Gastrointest Endosc* 2025; 17(12): 111386 [DOI: [10.4253/wjge.v17.i12.111386](https://doi.org/10.4253/wjge.v17.i12.111386)]

**ORIGINAL ARTICLE****Retrospective Cohort Study**

**Sugimoto M, Nakajima Y, Takeda Y, Sato Y, Takagi T, Suzuki R, Asama H, Shimizu H, Sato K, Ohira R, Nakamura J, Kato T, Yanagita T, Otsuka M, Hikichi T, Ohira H.** Efficacy and safety of plastic and metal stents for endoscopic ultrasound guided-biliary drainage in elderly patients. *World J Gastrointest Endosc* 2025; 17(12): 110136 [DOI: [10.4253/wjge.v17.i12.110136](https://doi.org/10.4253/wjge.v17.i12.110136)]

**Pietrzak J, Pertkiewicz J, Koziel S, Babski P, Ligocka J, Przybyłkowski A.** Endoscopic treatment of malignant hilar biliary obstruction: A retrospective cohort study. *World J Gastrointest Endosc* 2025; 17(12): 110432 [DOI: [10.4253/wjge.v17.i12.110432](https://doi.org/10.4253/wjge.v17.i12.110432)]

**Alali AA, Ali N, Hashim A, Alhaqqan D, Aljasser W, Almudaires A, Bastaki S, Alhashmi A, Altaieb A.** Feasibility and safety of endoscopic ultrasound-guided liver biopsy to diagnose parenchymal liver disease: A multi-centre retrospective cohort study. *World J Gastrointest Endosc* 2025; 17(12): 112485 [DOI: [10.4253/wjge.v17.i12.112485](https://doi.org/10.4253/wjge.v17.i12.112485)]

**Gomes A, Barrio E, Gomes G, Souza JHCG, Pinto PCC, Borghesi RA.** Hemorrhoidal elastic band ligation during routine colonoscopy: A comparative study between flexible video endoscopy and rigid proctoscopy. *World J Gastrointest Endosc* 2025; 17(12): 114581 [DOI: [10.4253/wjge.v17.i12.114581](https://doi.org/10.4253/wjge.v17.i12.114581)]

**Retrospective Study**

Iwamuro M, Tanaka T, Hamada K, Kono Y, Kawano S, Kawahara Y, Otsuka M. Endoscopic features of oral and pharyngolaryngeal papillomas and their role in distinguishing squamous cell carcinoma. *World J Gastrointest Endosc* 2025; 17(12): 110594 [DOI: [10.4253/wjge.v17.i12.110594](https://doi.org/10.4253/wjge.v17.i12.110594)]

AlQahtani KM, AlNasser AA, AlQahtani AM, AlTurki AA, Aljaili AK, Alamri AH, Owayed AS, Asiri YW, Bakkari SA, Jaddoh AM, Aldarsouny TA, Semaan TG, Elbayoumy MS, Alruzug IM, Alenezi AA, Bin-Ofaysan MS, Alsager MO, Alshahrani HS, Alhaddad SM, Almuhayzi HN, Almousa RA, Shehada AJ, AlMasri AA, Aldaher MK, Maaly ME, Hafez IM, Alzubide SR. Impact of referral delays on dysphagia outcomes in a Saudi tertiary center. *World J Gastrointest Endosc* 2025; 17(12): 110842 [DOI: [10.4253/wjge.v17.i12.110842](https://doi.org/10.4253/wjge.v17.i12.110842)]

Lone SA, Sonika U, Reddy RT, Vaithiyam V, Aneesh PS, Palli SH, Dalal A, Kumar A, Srivastava S, Sachdeva S. Predictive factors and outcomes of endoscopic necrosectomy in patients with acute pancreatitis and walled-off necrosis. *World J Gastrointest Endosc* 2025; 17(12): 111614 [DOI: [10.4253/wjge.v17.i12.111614](https://doi.org/10.4253/wjge.v17.i12.111614)]

Cooper JA, Statham E, Holyfield A, Shoreibah MG, Peter S. Initial treatment approaches for nodular gastric antral vascular ectasia: A comparison of endoscopic band ligation and thermal therapies. *World J Gastrointest Endosc* 2025; 17(12): 111872 [DOI: [10.4253/wjge.v17.i12.111872](https://doi.org/10.4253/wjge.v17.i12.111872)]

**Observational Study**

Agrawal A, Cadillo Arbaiza A, Blanco Montecino R, Almandoz JP, Messiah SE, Mathew M, Tavakkoli A. Quality of life, dumping symptoms, and weight bias internalization after endoscopic bariatric revisional therapies. *World J Gastrointest Endosc* 2025; 17(12): 113467 [DOI: [10.4253/wjge.v17.i12.113467](https://doi.org/10.4253/wjge.v17.i12.113467)]

**SYSTEMATIC REVIEWS**

Pal P, Kata P, Nabi Z, Ramchandani M, Soma PR, Gupta R, Tandan M, Duvvur NR. Advances in endoscopic dysplasia detection in inflammatory bowel disease. *World J Gastrointest Endosc* 2025; 17(12): 111236 [DOI: [10.4253/wjge.v17.i12.111236](https://doi.org/10.4253/wjge.v17.i12.111236)]

**CASE REPORT**

Wang JY, Liu Y, Xu J, Fan F, You P, Peng T, Liu YL, Chen N. Chronic enteropathy associated with solute carrier organic anion transporter family member 2A1 gene: A case report and review of literature. *World J Gastrointest Endosc* 2025; 17(12): 112344 [DOI: [10.4253/wjge.v17.i12.112344](https://doi.org/10.4253/wjge.v17.i12.112344)]

Saito M, Miyashita K, Ieko M, Yokoyama E, Kanaya M, Izumiyama K, Mori A, Morioka M, Kondo T. Repeated hemorrhagic ulcers of the esophagus associated with acquired hemophilia A: A case report. *World J Gastrointest Endosc* 2025; 17(12): 114836 [DOI: [10.4253/wjge.v17.i12.114836](https://doi.org/10.4253/wjge.v17.i12.114836)]

**ABOUT COVER**

Editorial Board Member of *World Journal of Gastrointestinal Endoscopy*, Saurabh Chawla, MD, Professor, Digestive Diseases, Emory University School of Medicine, Atlanta, GA 30322, United States. saurabh.chawla@emory.edu

**AIMS AND SCOPE**

The primary aim of *World Journal of Gastrointestinal Endoscopy* (*WJGE*, *World J Gastrointest Endosc*) is to provide scholars and readers from various fields of gastrointestinal endoscopy with a platform to publish high-quality basic and clinical research articles and communicate their research findings online.

*WJGE* mainly publishes articles reporting research results and findings obtained in the field of gastrointestinal endoscopy and covering a wide range of topics including capsule endoscopy, colonoscopy, double-balloon enteroscopy, duodenoscopy, endoscopic retrograde cholangiopancreatography, endosonography, esophagoscopy, gastrointestinal endoscopy, gastroscopy, laparoscopy, natural orifice endoscopic surgery, proctoscopy, and sigmoidoscopy.

**INDEXING/ABSTRACTING**

The *WJGE* is now abstracted and indexed in Emerging Sources Citation Index (Web of Science), PubMed, PubMed Central, Reference Citation Analysis, China Science and Technology Journal Database, and Superstar Journals Database. The 2025 Edition of Journal Citation Reports® cites the 2024 journal impact factor (JIF) for *WJGE* as 1.8; JIF without journal self cites: 1.7; 5-year JIF: 1.9; JIF Rank: 98/147 in gastroenterology and hepatology; JIF Quartile: Q3; and 5-year JIF Quartile: Q3.

**RESPONSIBLE EDITORS FOR THIS ISSUE**

Production Editor: *Jiao Xu*; Production Department Director: *Xiao-Mei Zheng*; Cover Editor: *Jia-Ping Yan*.

**NAME OF JOURNAL**

*World Journal of Gastrointestinal Endoscopy*

**ISSN**

ISSN 1948-5190 (online)

**LAUNCH DATE**

October 15, 2009

**FREQUENCY**

Monthly

**EDITORS-IN-CHIEF**

Bing Hu, Joo Young Cho

**EDITORIAL BOARD MEMBERS**

<https://www.wjgnet.com/1948-5190/editorialboard.htm>

**PUBLICATION DATE**

December 16, 2025

**COPYRIGHT**

© 2025 Baishideng Publishing Group Inc

**PUBLISHING PARTNER**

Digestive Endoscopy Center of West China Hospital, SCU

**INSTRUCTIONS TO AUTHORS**

<https://www.wjgnet.com/bpg/gerinfo/204>

**GUIDELINES FOR ETHICS DOCUMENTS**

<https://www.wjgnet.com/bpg/GerInfo/287>

**GUIDELINES FOR NON-NATIVE SPEAKERS OF ENGLISH**

<https://www.wjgnet.com/bpg/gerinfo/240>

**PUBLICATION ETHICS**

<https://www.wjgnet.com/bpg/GerInfo/288>

**PUBLICATION MISCONDUCT**

<https://www.wjgnet.com/bpg/gerinfo/208>

**ARTICLE PROCESSING CHARGE**

<https://www.wjgnet.com/bpg/gerinfo/242>

**STEPS FOR SUBMITTING MANUSCRIPTS**

<https://www.wjgnet.com/bpg/GerInfo/239>

**ONLINE SUBMISSION**

<https://www.f6publishing.com>

**PUBLISHING PARTNER'S OFFICIAL WEBSITE**

<http://www.cd120.com/index.html>



## Upper gastrointestinal endoscopy in pediatric gastroenterology: Diagnostic and therapeutic applications

Wathsala Hathagoda, Shaman Rajindrajith, Niranga Manjuri Devanarayana

**Specialty type:** Gastroenterology and hepatology

**Provenance and peer review:** Invited article; Externally peer reviewed.

**Peer-review model:** Single blind

**Peer-review report's classification**

**Scientific Quality:** Grade B, Grade C

**Novelty:** Grade C, Grade C

**Creativity or Innovation:** Grade C, Grade C

**Scientific Significance:** Grade C, Grade C

**P-Reviewer:** Dharmaraj R, Associate Professor, United States; Lin S, Associate Chief Physician, China

**Received:** June 30, 2025

**Revised:** August 10, 2025

**Accepted:** October 27, 2025

**Published online:** December 16, 2025

**Processing time:** 170 Days and 21.5 Hours



**Wathsala Hathagoda, Shaman Rajindrajith,** Department of Pediatrics, Faculty of Medicine, University of Colombo, Colombo 00800, Western Province, Sri Lanka

**Wathsala Hathagoda, Shaman Rajindrajith,** University Pediatric Unit, Lady Ridgeway Hospital for Children, Colombo 00800, Western Province, Sri Lanka

**Niranga Manjuri Devanarayana,** Department of Physiology, Faculty of Medicine, University of Kelaniya, Ragama 11010, Western Province, Sri Lanka

**Corresponding author:** Niranga Manjuri Devanarayana, MD, PhD, Professor, Department of Physiology, Faculty of Medicine, University of Kelaniya, Thalagolla Road, Ragama 11010, Western Province, Sri Lanka. [niranga@kln.ac.lk](mailto:niranga@kln.ac.lk)

### Abstract

Upper gastrointestinal (GI) endoscopy is considered an essential procedure in pediatric gastroenterology. It has evolved over many decades into a state where it plays a crucial role in providing diagnostic and therapeutic advantages across a broad spectrum of diseases. This review examines its role in diagnosing and managing common pediatric GI conditions, emphasizing notable advancements in techniques, clinical use, and future directions. We conducted a detailed literature survey using PubMed, Scopus, and Google Scholar, and English-language articles were reviewed. This review process included the latest articles, guidelines, and conference papers on pediatric and adult upper GI endoscopy. An upper GI endoscopy is imperative in diagnosing many pediatric GI diseases as it enables visualization of the gut mucosa, obtaining mucosal biopsies from suspicious areas or lesions for histological assessment, and selecting an effective management and follow-up plan. New advancements, including high-resolution endoscopy, narrow-band imaging, and confocal laser endomicroscopy, have revolutionized pediatric endoscopy by improving precision and reducing the need for invasive interventions. Furthermore, recent therapeutic developments in the field, such as endoscopic submucosal dissection and endoscopic mucosal resection, are now being utilized to treat preneoplastic lesions or refractory esophageal strictures. However, despite its usefulness, performing this procedure in children is challenging for various reasons, including the need for sedation, anesthesia, and smaller instrument sizes, the unavailability of trained staff, lack of training facilities, and the absence of dedicated endoscopy suites for children. In conclusion, pediatric upper GI endoscopy plays a pivotal role in pediatric gastroenterology, offering both therapeutic and diagnostic benefits. Progress in the field leads to the

development of novel techniques that improve overall patient care, such as artificial intelligence in pattern recognition, which enhances lesion detection, predicts premalignant or pre-inflammatory areas, and minimizes investigator-related errors. Additionally, refining protocols and guidelines is essential to improve the safety, efficacy, and precision of upper GI endoscopy, ensuring the best possible care for children.

**Key Words:** Child; Endoscopy; Gastroenterology; Gastrointestinal disorder; Pediatric care; Pediatric gastroenterology; Upper gastrointestinal endoscopy

©The Author(s) 2025. Published by Baishideng Publishing Group Inc. All rights reserved.

**Core Tip:** Endoscopy plays an essential role in pediatric gastroenterology by enabling accurate diagnosis and offering therapeutic benefits, particularly for complex conditions such as inflammatory bowel disease, coeliac disease, and eosinophilic esophagitis. Technological progress continues to improve diagnostic accuracy, while therapeutic endoscopy helps reduce the need for invasive surgical procedures. Tailored endoscopy training programs, standardized evaluation methods, and clearly defined benchmarks for competence will enhance patient care. More robust research is vital to determine the clinical outcomes of endoscopy and to explore the techniques used in children. Continued progress through innovation and specialized education is crucial for the future of pediatric endoscopic practice.

**Citation:** Hathagoda W, Rajindrajith S, Devanarayana NM. Upper gastrointestinal endoscopy in pediatric gastroenterology: Diagnostic and therapeutic applications. *World J Gastrointest Endosc* 2025; 17(12): 111386

**URL:** <https://www.wjgnet.com/1948-5190/full/v17/i12/111386.htm>

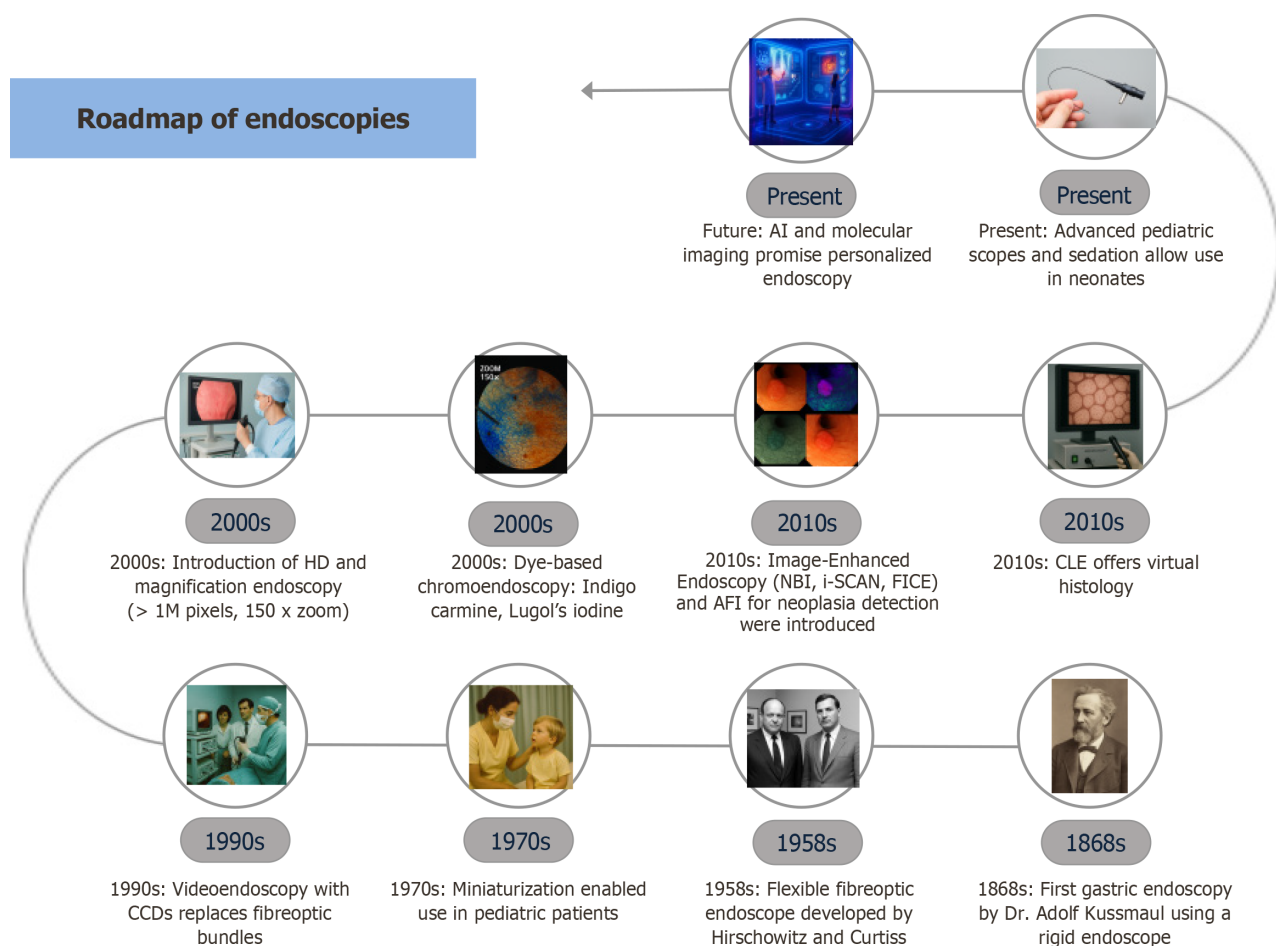
**DOI:** <https://dx.doi.org/10.4253/wjge.v17.i12.111386>

## INTRODUCTION

With the advancement of technology and current management standards in pediatric gastroenterology, upper gastrointestinal (GI) endoscopy has become increasingly important for both diagnostic and therapeutic purposes over the past few decades[1]. It is regarded as one of the most accurate, practical, convenient, and economical diagnostic methods for some GI disorders in children, particularly when other investigations are inconclusive[2]. Moreover, GI endoscopy is crucial in diagnosing and managing pediatric GI disorders[3]. It also provides comprehensive disease evaluation for common pediatric conditions such as allergic, infectious, or peptic esophagitis, infectious or inflammatory gastritis, and celiac disease[4]. Upper GI endoscopy allows not only the direct examination of the gut mucosa but also the taking of biopsies. Coupling endoscopy with histological examination increases the yield and precision of the diagnosis[5]. Beyond diagnosis, endoscopy also plays a crucial role in providing therapeutic opportunities, such as endoscopic hemostasis for both variceal and non-variceal bleeding, foreign body removal, endoscopic dilation, polypectomy, endoscopic retrograde cholangiopancreatography (ERCP), and percutaneous endoscopic gastrostomy for long-term nutritional support[6] that have improved emergency medical care and prevented non-essential invasive procedures.

Endoscopy has evolved over 150 years before becoming a vital investigation in GI disorder diagnosis. Dr. Adolph Kussmaul of Germany was the first to examine the stomach of a living human body in 1868[7]. A landmark advancement in endoscopy came in 1958 with the development of the flexible fiberoptic endoscopy by Larry Curtiss, a physics graduate student, and Basil Hirschowitz, a gastroenterology trainee[8]. In the early 1970s, as the size of the endoscope was reduced, a few pioneering pediatricians began using it to examine the upper digestive tract in children[9,10]. In 1990, the invention of video-endoscopy, utilizing charge-coupled devices, marked another major step forward by replacing fiberoptic systems and resolving problems related to damaged fiberoptic cable bundles[11]. Endoscopy has undergone a substantial technological revolution since then, including the provision of pediatric-sized scopes, which enable a detailed examination of the GI tract. Technical advancements such as fiberoptic and video technology with pediatric-friendly scopes, along with advances in anesthesia, have made it possible to examine even premature infants and severely sick patients[11]. Recent breakthroughs in image-capturing systems, such as magnification endoscopy, autofluorescence imaging, electronic chromoendoscopy (CE) techniques like narrow-band imaging (NBI), i-SCAN, or flexible spectral imaging color enhancement (FICE), and confocal laser microendoscopy, have enabled the endoscopist to view finer mucosal detail and subsurface structures such as the vasculature[11]. The key milestones in the development of the endoscope, along with its prospects, are summarized in Figure 1[7-12].

There is a growing trend in the use of pediatric endoscopy among children without a corresponding rise in the disease burden[13,14]. Several factors may account for this increase. Pediatric gastroenterology is now a well-established specialty with a structured training pathway, leading to a steady rise in the number of pediatricians skilled in endoscopy [15]. Advances in procedural safety and a decline in serious complications, along with improved management when complications occur, have likely contributed to a shift in perception among healthcare providers and the general public regarding the invasiveness of endoscopy[6,16]. This review examines the utility of endoscopy in assessing and managing common pediatric GI disorders, focusing on recent technological advancements and evolving clinical applications.



**Figure 1 Key milestones in endoscope development and prospects.** HD: High-definition; NBI: Narrow-band imaging; FICE: Flexible spectral imaging color enhancement; AFI: Autofluorescence imaging; CLE: Confocal laser endomicroscopy; CCD: Charge-coupled device.

## INDICATIONS FOR UPPER GI ENDOSCOPY IN CHILDREN

Due to its widespread availability, it is one of the commonly recommended investigations for the evaluation of pediatric GI disorders. However, indications for endoscopy are unique in this age group compared to adults and require a tailored approach. In addition, the variability of its indications, the need for anesthesia during the procedure, the importance of routine tissue sampling, and the emotional burden on patients and parents of being subjected to an invasive procedure make pediatric endoscopy more cumbersome than that of adults[17]. In addition to its diagnostic use, upper GI endoscopy has an established therapeutic role. Furthermore, upper GI endoscopy is used in the diagnosis and management of a wide variety of GI disorders in children. The European Society of Gastrointestinal Endoscopy and the European Society for Pediatric Gastroenterology, Hepatology, and Nutrition have issued evidence-based guidelines, outlining the indications and timing of diagnostic and therapeutic endoscopy in pediatric patients[6]. We have summarized diagnostic and therapeutic indications for pediatric endoscopy in Table 1, and the absolute and relative contraindications for this procedure in Table 2, based on available guidelines[6,13].

As clinicians, when there is clinical suspicion of underlying organic pathology, it is essential to consider upper GI endoscopy with biopsy as an investigative tool. For children with weight loss and failure to thrive, it is critical to exclude organic conditions such as coeliac disease, inflammatory bowel disease, allergic enterocolitis, or giardiasis. Upper GI endoscopy facilitates direct visual assessment of the gut lumen and facilitates histological confirmation through biopsy. Endoscopic assessment is also valuable in evaluating suspected causes of GI bleeding, such as polyps, angiodysplasia, arteriovenous malformations, peptic ulcers with or without *Helicobacter pylori* infection, and structural anomalies, including duplication cysts. In dysphagia, odynophagia, chest pain, or feeding difficulties, it is essential to perform an upper GI endoscopy to rule out caustic ingestion or eosinophilic esophagitis[6]. In addition, endoscopy can serve as a valuable tool for troubleshooting some specialized diagnostic procedures. In wireless capsule endoscopy, if the patient cannot swallow the capsule, the capsule can be placed beyond the duodenal bulb using traditional endoscopy with general anesthesia. It is also used in GI physiology assessments, including esophageal manometry and pH impedance testing, for positioning the probe when the routine method fails (*e.g.*, tight achalasia, esophageal strictures or stenosis, severe esophageal dilatation, and structural anomalies)[18].

Although advanced therapeutic procedures are less common in children compared to adults, endoscopic interventions have a well-established therapeutic role in managing several simple as well as life-threatening disorders[6]. The common

**Table 1 Diagnostic and therapeutic indications of upper gastrointestinal endoscopy in children**

Diagnostic indications	Therapeutic indications
Weight loss, failure to thrive	Percutaneous endoscopic gastrostomy (re)placement
Unexplained anemia	Duodenal tube placement
Abdominal pain with suspicion of an organic disease	Foreign body removal
	Food impaction
	Hemostasis
Dysphagia or odynophagia	Esophageal varices
Recurrent vomiting with unknown cause	Percutaneous jejunostomy placement
Hematemesis	Perforation
Hematochezia	Achalasia
Unexplained chronic diarrhea	Dilatation of esophageal or upper GI strictures
Suspicion of graft <i>vs</i> host disease	Polypectomy
Chronic GERD, to exclude other diseases, or surveillance of Barrett's esophagus	

GERD: Gastroesophageal reflux disease; GI: Gastrointestinal.

**Table 2 Absolute and relative contraindications for upper gastrointestinal endoscopy in children**

Absolute contraindications	Relative contraindications
Unstable airway	Bowel obstruction
Cardiovascular collapse	Severe thrombocytopenia
Intestinal perforation	Coagulopathy
Peritonitis	Recent GI surgery
	Respiratory infection
	Recent food intake

GI: Gastrointestinal.

causes of upper GI bleeding are peptic ulcers, varices, Mallory-Weiss tears, Dieulafoy lesions, and angioectasia[19,20]. Endoscopic interventions are categorized into injection (sclerotherapy), mechanical hemostasis, or thermo-coagulation [21]. In variceal bleeding, hemostasis is achieved using band ligation and, if banding is not possible, by sclerotherapy[6]. In contrast, for non-variceal bleeding, namely the treatment of peptic ulcers and Dieulafoy lesions, epinephrine injection cannot be employed alone but rather in combination with thermal or mechanical therapy[6]. In addition to conventional procedures such as dilatation of esophageal or pyloric strictures and foreign body removal, therapies like esophageal stenting are emerging as novel therapeutic endoscopic interventions in children[21]. Botulinum toxin injection and advanced interventions for gastroesophageal reflux disease (GERD), such as endoluminal fundoplication/gastroplication (plicating techniques), can form a controlled stricture (radio frequency). Methods that bulk the gastroesophageal junction by injecting bulking agents[22] and Peroral Endoscopic Myotomy[23] are being performed in children with GERD and achalasia cardia, respectively. All these diagnostic and therapeutic procedures make endoscopy an indispensable procedure in pediatric gastroenterology.

## PRE-PROCEDURAL EVALUATION AND PREPARATION

Preparation for upper GI endoscopy in children should respect their physiology as well as the psychosocial and emotional needs of them and their parents[13]. It is recommended that necessary preparation be made before the procedure. First, informed consent must be obtained from the parents or guardians before the elective/emergency procedure. The potential risks and benefits of the procedure should be explained to parents and children using age-appropriate language. Moreover, the essential details of this discussion should be documented in writing and signed by the legal guardian to serve as legal evidence. Further, the procedure should not be performed without a clear agreement between the clinician and the guardians[13].

A child's ability to control his/her behavior during a procedure depends on both the chronological age and the level of cognitive and emotional development. The capacity to cooperate with a procedure also relies on these factors. Many short procedures, such as suturing a minor laceration, can be performed using distraction and guided imagery techniques, along with the application of topical or local anesthetics and minimal sedation if necessary. However, since upper GI endoscopy can be invasive and could be lengthy, especially during a therapeutic procedure, general anesthesia is mandatory.

According to the guidelines of the American Academy of Pediatrics, the main objectives in procedural sedation in children are to ensure the child's safety, minimize pain and discomfort, control anxiety, avoid psychological trauma, modify behaviors to reduce movements to ensure safety, and return the child to their normal state before discharge[24]. Explaining the need for general anesthesia to parents and obtaining their consent is a major challenge to the endoscopist. Due to multiple risks associated with general anesthesia, parents often express their reluctance for the child to undergo general anesthesia. Parental anxiety is higher when the patient is a neonate or a young child. The endoscopy team needs to educate and reassure parents, provide all relevant information, and take all necessary precautions before the procedure. Sometimes, using visual aids such as photographs, videos, or animations can help alleviate anxiety for both children and their families. It is recommended to engage parents in preprocedural preparation, as it will minimize anxiety in younger patients[25].

Pre-procedure assessment involves a complete physical examination, particularly of the respiratory system. During the examination, documenting special findings such as loose teeth, oral piercings, and enlarged tonsils is vital. Loose teeth can accidentally dislodge and may enter the airways, causing life-threatening complications. Enlarged tonsils can worsen breathing difficulties; therefore, obstructive apnea in sedated patients should be assessed before sedation[13]. Although coagulation and liver function tests are included in blood investigations. However, it is reported that routine coagulation screening in children undergoing GI endoscopy does not predict those at risk of bleeding, and the significance of coagulation screening before the procedure is limited[26]. However, severe coagulopathy is a contraindication for endoscopic procedures in children, and appropriate treatment must be administered when endoscopy is deemed essential[13]. Premedication with oral or nasal application of benzodiazepines has been shown to reduce anxiety and fear before endoscopy[27]. A study showed that midazolam can also reduce the emotional stress of separation from parents and make patients feel more comfortable during the intervention. However, there was no significant difference in the duration of the procedure, surveillance parameters, length of hospital stay, or recovery time between the midazolam group[28].

The fasting required before the procedure and preparation of the intestine depends on the patient's age and the type of procedure. Conventionally, patients are kept fasting from solid foods for six hours and from liquids for two to four hours prior to the procedure[13]. According to the guidelines of the American Academy of Pediatrics, children should be fed clear liquids up to two hours before sedation to prevent dehydration. Breastmilk should be given prior to four hours, whereas formula milk or a light diet should be given six hours before the procedure. Therefore, infants younger than six months may be given infant formula up to six hours and clear liquids up to two hours before sedation[24]. For patients older than six months, fasting from non-clear liquids and solids is recommended for six to eight hours prior to sedation [24,29]. However, some previous studies have recommended a longer fasting time (up to 10 hours) for rice-based diets [30]. Therefore, the fasting guidelines should be tailored based on the diet, especially in older children.

The American Heart Association no longer recommends administering prophylactic antibiotics to patients undergoing GI endoscopy to prevent infective endocarditis[31]. For patients with the cardiac conditions mentioned in Table 3, with proven infections of the GI tract (such as cholangitis) and those set to undergo an endoscopic procedure, such as ERCP, which may increase the risk of bacteremia, prophylactic antibiotics are recommended[32]. In such instances, the antibiotic regimen should include an antimicrobial agent active against enterococci, such as penicillin, ampicillin, piperacillin, or vancomycin[33].

---

## TECHNIQUE AND EQUIPMENT

---

In children, worldwide use of endoscopy faces several challenges, including the lack of appropriately sized scopes, limited expertise among pediatric gastroenterologists in performing advanced endoscopic procedures, and financial constraints in establishing dedicated pediatric endoscopy units[4]. With the invention of different-sized scopes, diagnostic and therapeutic endoscopy has become more safer and less challenging in infants and younger children. However, smaller pediatric scopes have some therapeutic disadvantages. The working channel diameter (also referred to as the auxiliary channel or channel size/diameter) is a crucial component of an endoscope, through which various accessories and tools can be passed during endoscopic procedures. The reduced diameter of the working channel in smaller pediatric scopes can restrict the passage of many useful accessories (*e.g.* hemostatic clipping), limiting their therapeutic applications [4,18].

The selection of an endoscope depends mainly on the patient's size and is designed with a directly proportional auxiliary channel[12]. If the child's weight exceeds 20 kg, they will often accept a standard adult-size gastroscope with a working channel diameter of 2.8 mm[18]. In contrast, patients weighing less than 5 kg may require an ultrathin or neonatal gastroscopes with an outer diameter of less than 6 mm, featuring a working channel of approximately 2 mm. As with neonates, the length of the esophagus is nearly 10 cm, with a diameter of approximately 0.5 cm[21]. For smaller children weighing between 5 kg and 20 kg, a slimmed-down endoscope of less than 9 mm (7.88 mm-9 mm) is preferable with a working channel between 2.28 mm-2.8 mm, and it is advisable to have a more miniature endoscope available in case the preselected endoscope is found to be too large during the procedure[18,34]. Models and specifications of gastro-

**Table 3 Cardiac conditions with a high risk of infective endocarditis during endoscopic procedures****List of cardiac conditions**

- (1) Prosthetic (mechanical or bioprosthetic) cardiac valves
- (2) History of previous IE
- (3) Cardiac transplant recipients who develop cardiac valvulopathy
- (4) Patients with CHD: Unrepaired cyanotic CHD, including palliative shunts and conduits; those with completely repaired CHD with prosthetic material or devices, placed surgically or by catheter, for the first 6 months after the procedure; and those with repaired CHD with residual defects at the site or adjacent to the site of a prosthetic patch or device

CHD: Congenital heart disease; IE: Infective endocarditis.

scopes available for pediatric use are outlined in the Table 4[35,36]. However, when using a smaller auxiliary or working channel of 2 mm to 2.2 mm, it can reduce the suction capacity and limit the number of therapeutic interventions performed with the endoscope, as only a few devices fit through the smaller channel. Therefore, to perform procedures more easily and safely, adult duodenoscopes are sometimes used in children over 10 kg because they have wider auxiliary channels, allowing the passage of accessories required for ERCP or therapeutic interventions such as stenting and applying hemostatic clips[6,16]. Although the techniques of endoscopy in children are the same as those in adults, it can be challenging due to anatomical variations or limited physiological reserves. Neonates have very soft airways that can be easily compressed during endoscopic procedures. Further, the other significant difficulty is the angle between the gastric antrum and the first part of the duodenum, which requires a greater degree of tip deflection to overcome[33]. It is routine to perform tissue biopsies during pediatric endoscopy, even in the absence of obvious macroscopic abnormalities, to minimize the risk of exposing the child to repeated procedures and anesthesia[6]. Abnormal histological findings may be present even when the macroscopic appearance is unremarkable in endoscopy, potentially changing the therapeutic strategies[5]. Porto criteria recommend multiple endoscopic biopsies from the esophagus, stomach, and duodenum for all children with IBD, irrespective of upper GI symptoms[33].

With technological advancements, imaging techniques have revolutionized endoscopy by enhancing mucosal visualization and enabling real-time optical diagnosis[10]. Endoscopic instruments and adaptations for pediatric use have transformed the way gastroenterologists diagnose and treat a wide range of GI disorders in children. Advanced technologies, including computer processing and imaging innovations, are continuously upgrading endoscopic equipment and refining their diagnostic utility in pediatrics. However, modalities used in adult gastroenterology practice, such as endomicroscopy, image-enhanced endoscopy (IEE), and impedance planimetry, are yet to be routinely adopted for pediatric endoscopy[37].

## COMPLICATIONS AND RISK MANAGEMENT

Endoscopic procedures in children are generally regarded as safe[2,6], with a serious complication rate of less than 1%. In contrast, therapeutic procedures have higher complication rates but are usually performed without concerns[38]. The complication may be categorized by severity (minor *vs* major) or time of occurrence (endoscopy or procedure-related, or early or late post-procedural)[39]. Endoscopy-related bleeding, internal organ injury, pneumoperitoneum, cellulitis, and minor wound infections are among the early complications following endoscopy in children[38,40]. The complication rate, including bowel perforation and significant bleeding following endoscopic balloon dilatation in stricturing Crohn's disease, is approximately 2%[41]. In ERCP, post-ERCP pancreatitis (4.7%), bleeding (0.6%), and infarction (0.8%) are the most common complications, followed by cholangitis and minor papilla restenosis as long-term issues[42].

The complications during pediatric endoscopy are commonly due to sedation and anesthesia administered during the procedure[43]. Upper GI endoscopy in children is generally performed under moderate sedation (conscious sedation) or general anesthesia. Retaining the protective airway reflexes and spontaneous breathing during examination are some of the positive factors for moderate sedation. In contrast, deep sedation provides a more reliable state of sedation[13]. Children are more likely to experience respiratory complications due to higher lung resistance and obligatory nasal breathing, particularly infants less than seven months[13]. Moreover, they are also less resistant to hypoxemia. This leads to considering that respiratory infections in children with underlying hyperactive airways are an absolute contraindication for elective endoscopy under anesthesia. Further, in all patients, cardiovascular parameters and oxygen saturation should be monitored for 15 to 30 minutes after the procedure. Oral intake for clear fluid is allowed, possibly one hour after sedation. Discharge of the patient is possible if sufficient cardiovascular function and airway patency are confirmed, the patient is fully oriented, and protective reflexes are intact[24].

## CHALLENGES AND LIMITATIONS

Significant constraints to the evolution of pediatric endoscopy services include the scarcity of scopes in various sizes, as

**Table 4 Models and specifications of gastroscopes available for pediatric use**

Weight of the child (kg)	Model	Working length (cm)	Diameter (mm)		Manufacturer
			Outer	Inner	
< 5, ultrathin gastroscope	Olympus GIF-XP190N	110	4.9	2	Olympus corporation
5-20, slim adult gastroscope	Olympus GIF-XP190N	110	5.4	2.2	Olympus corporation
	Fujifilm EG-580NW2	110	5.9	2.4	Fujifilm Endoscopy
> 20, adult-size gastroscope	Olympus GIF-H190	103	9.2	2.8	Olympus corporation
	Fujifilm EG-590WR	110	9.4	2.8	Fujifilm Endoscopy

well as the insufficient knowledge and skills among pediatric gastroenterologists to perform advanced endoscopic procedures. High equipment and maintenance costs and the need for specialized units with facilities for general anesthesia and dedicated trained staff impose financial restrictions on developing a pediatric endoscopy service. Therefore, most of the pediatric GI endoscopy procedures are performed in units dedicated to adults. In settings where dedicated pediatric endoscopy units are lacking, the number of advanced procedures performed on pediatric patients tends to be lower. This is primarily due to challenges such as the unavailability of pediatric-sized scopes and accessories, competition for endoscopy resources with the large volume of adult patients, and difficulties in securing operating theatre time, as well as the necessary anesthesiologist services for general anesthesia. Overall, advanced therapeutic procedures are less commonly performed in pediatric patients than in adults[3]. Therapeutic endoscopic procedures in children require general anesthesia, unlike adults, which can be challenging, especially in resource-poor settings. Furthermore, one of the major challenges facing pediatric endoscopy is the lack of specialized training courses in advanced pediatric GI interventions, along with financial constraints in developing dedicated pediatric units[3]. Another major obstacle faced even in the tertiary center is meeting the competency standards by performing the recommended number of specialized procedures required[44]. The choice of endoscope is crucial and depends on the age and weight of the child, with different scopes (ultrathin, slim, and standard pediatric/adult) employed for various weight ranges[21]. The small size and distinct anatomical features of children, including a shorter, narrower, and easily compressible esophagus and a more angulated antrum and proximal duodenum, necessitate specialized endoscopes[18].

Although endoscopy permits direct examination and tissue biopsies, studies show that the agreement between endoscopic and histopathological findings is not high[45]. Routine tissue sampling is commonly practised even without visible abnormalities, partly to minimize the need for repeated procedures and anesthesia[6]. However, processing and reporting biopsies can increase the overall financial cost of the procedures, as more than half of patients undergoing endoscopy are reported to have no endoscopic or histological abnormalities[46-48]. IEE can highlight mucosal features but often still requires a biopsy for a definitive diagnosis[12]. A significant drawback of pediatric-sized endoscopes is the smaller size of their working channels, which can restrict the passage of many useful accessories and therapeutic tools[3]. Developing pediatric upper GI endoscopy services in low-income countries faces challenges such as a lack of expertise in the field, with most pediatric procedures being performed by adult gastroenterologists. Additionally, there is often a shortage of funds to establish dedicated endoscopy suites, unavailability of equipment and infrastructure, limited theatre facilities, and a shortage of anesthetists capable of providing anesthesia.

## RECENT ADVANCES AND FUTURE DIRECTIONS

IEE represents a significant advancement, moving beyond conventional white-light endoscopy. Using various optical or electronic technologies, IEE enhances contrast, improves clarity of the images, and increases visibility of mucosal microstructure and microvasculature, leading to higher detection rates of mucosal abnormalities[12]. IEE includes dye-based CE and electronic CE methods, NBI, FICE, and i-SCAN (electronic methods)[12]. High-definition endoscopy is also considered a form of IEE due to its ability to provide significantly magnified and sharper images, allowing for the visualization of subtle mucosal changes[11]. Dye-based CE entails spraying dyes onto the mucosal surface to enhance the visualization of microstructures and vascular patterns, thereby aiding in delineating lesion boundaries for targeted biopsies. It is used for Barrett's esophagus and screening of esophageal and squamous cell carcinoma in high-risk groups. Dyes such as indigo carmine accentuate surface features, while methylene blue is absorbed by normal mucosa, leaving inflammatory or dysplastic areas unstained[12]. On the other hand, Electronic CE uses electronic image processing to improve the visualization of the mucosa without requiring time-consuming dye injections[12].

NBI uses a specific light wavelength, based on the principle that the depth of light penetration into tissue is proportional to the wavelength used[12]. Blue light ( $415 \pm 15$  nm) penetrates only the superficial tissues, and it is absorbed by hemoglobin. Therefore, the capillaries in the superficial mucosal layer appear darker, helping to distinguish them from one another. In contrast, green light ( $540 \pm 15$  nm) penetrates slightly deeper layers, resulting in a secondary hemoglobin absorption peak, which makes deeper mucosal and submucosal vessels visible. This aids in the detection of early GI neoplasias, boundaries of Barrett's esophagus, and the gastroesophageal junction to diagnose GERD. FICE and i-SCANs are other software that utilize post-processing algorithms on white light images[11]. Their main functions include surface, contrast, and tone enhancements, which assist in visually inspecting subtle changes in the mucosa and better identifying

and examining lesions[48].

## CONCLUSION

In conclusion, pediatric upper GI endoscopy plays a pivotal role in the diagnosis and management of pediatric GI disorders, offering both diagnostic precision and therapeutic advantages. It is particularly critical in identifying complex and emerging pediatric GI conditions. Recent advances in endoscopic technology have resulted in improved mucosal visualization, leading to greater diagnostic accuracy and enhanced therapeutic outcomes. To fully harness these benefits, robust and standardized pediatric-specific training programs, validated assessment tools, and simulation-based curricula are essential. Setting clear competency standards tailored to pediatric practice and providing structured trainer development are important for maintaining safety and quality. Additionally, there is a pressing need for pediatric-centered research, including well-designed clinical trials, to understand the clinical impact of endoscopy better, refine current techniques, and evaluate the suitability of methods adapted from adult practice. Ongoing commitment to innovation and education will be key to ensuring that pediatric endoscopy continues to meet the evolving needs of children. Furthermore, incorporating advances used in adult endoscopy into children, after following safety precautions, will help to improve the technology more quickly.

## FOOTNOTES

**Author contributions:** Hathagoda W collected and analyzed the evidence and drafted the initial manuscript; Devanarayana NM and Rajindrajith S were substantially involved in revising it; Devanarayana NM conceptualized the paper. All authors checked the final manuscript before submission.

**Conflict-of-interest statement:** All the authors report no relevant conflicts of interest for this article.

**Open Access:** This article is an open-access article that was selected by an in-house editor and fully peer-reviewed by external reviewers. It is distributed in accordance with the Creative Commons Attribution NonCommercial (CC BY-NC 4.0) license, which permits others to distribute, remix, adapt, build upon this work non-commercially, and license their derivative works on different terms, provided the original work is properly cited and the use is non-commercial. See: <https://creativecommons.org/licenses/by-nc/4.0/>

**Country of origin:** Sri Lanka

**ORCID number:** Wathsala Hathagoda 0000-0002-3567-0069; Shaman Rajindrajith 0000-0003-1379-5052; Niranga Manjuri Devanarayana 0000-0002-2988-110X.

**Corresponding Author's Membership in Professional Societies:** The Physiological Society of Sri Lanka; Asian Neurogastroenterology and Motility Association; Sri Lanka Society of Gastroenterology; Sri Lanka Medical Association; South Asian Association of Physiologists; International Union of Physiologists Scientists.

**S-Editor:** Bai SR

**L-Editor:** A

**P-Editor:** Xu J

## REFERENCES

- 1 **Ukarapol N, Tanatip N, Sharma A, Vitug-Sales M, Lopez RN, Malik R, Ng RT, Umetsu S, Getsuwan S, Lui TYS, Yang YJ, Lee YJ, Arai K, Kim KM; APPSPGHAN Endoscopy Scientific Subcommittee.** Current pediatric endoscopy training situation in the Asia-Pacific region: A collaborative survey by the Asian Pan-Pacific Society for Pediatric Gastroenterology, Hepatology and Nutrition Endoscopy Scientific Subcommittee. *Pediatr Gastroenterol Hepatol Nutr* 2024; **27**: 258-265 [RCA] [PMID: 39035405 DOI: 10.5223/pghn.2024.27.4.258] [FullText] [Full Text(PDF)]
- 2 **Mahmud S, Gulshan J, Baidya M, Rashid R, Tasneem F, Hasan AR, Farhana T, Begum D, Asha NF, Ahmed SS.** Spectrum of upper GI endoscopy in children: A tertiary centre experience from Bangladesh. *Dhaka Shishu (Child) Hosp J* 2022; **37**: 123-128 [DOI: 10.3329/dshj.v37i2.63220] [FullText]
- 3 **Nabi Z, Reddy DN.** Advanced therapeutic gastrointestinal endoscopy in children - today and tomorrow. *Clin Endosc* 2018; **51**: 142-149 [RCA] [PMID: 29228523 DOI: 10.5946/ce.2017.102] [FullText] [Full Text(PDF)]
- 4 **Rosen R, Vandenplas Y, Singendonk M, Cabana M, DiLorenzo C, Gottrand F, Gupta S, Langendam M, Staiano A, Thapar N, Tipnis N, Tabbers M.** Pediatric gastroesophageal reflux clinical practice guidelines: Joint recommendations of the North American Society for Pediatric Gastroenterology, Hepatology, and Nutrition and the European Society for Pediatric Gastroenterology, Hepatology, and Nutrition. *J Pediatr Gastroenterol Nutr* 2018; **66**: 516-554 [RCA] [PMID: 29470322 DOI: 10.1097/MPG.0000000000001889] [FullText]
- 5 **Altamimi E, Odeh Y, Al-Quraan T, Mohamed E, Rawabdeh N.** Diagnostic yield and appropriate indication of upper endoscopy in Jordanian children. *BMC Pediatr* 2021; **21**: 10 [RCA] [PMID: 33402143 DOI: 10.1186/s12887-020-02470-6] [FullText] [Full Text(PDF)]
- 6 **Thomson M, Tringali A, Dumonceau JM, Tavares M, Tabbers MM, Furlano R, Spaander M, Hassan C, Tzvinikos C, Ijsselstijn H, Viala J, Dall'Oglio L, Benninga M, Orel R, Vandenplas Y, Keil R, Romano C, Brownstone E, Hlava Š, Gerner P, Dolak W, Landi R, Huber WD,**

- Everett S, Vecsei A, Aabakken L, Amil-Dias J, Zambelli A. Paediatric gastrointestinal endoscopy: European Society for Paediatric Gastroenterology Hepatology and Nutrition and European Society of Gastrointestinal Endoscopy Guidelines. *J Pediatr Gastroenterol Nutr* 2017; **64**: 133-153 [RCA] [PMID: 27622898 DOI: 10.1097/MPG.0000000000001408] [FullText]
- 7 Kluge F, Seidler E. Zur Erstanwendung der Oesophago- und Gastroskopie: Briefe von Adolf Kussmaul und seinen Mitarbeitern. *Medizinhist J* 1986; **21**: 288-307 [RCA] [PMID: 11637391] [FullText]
- 8 Hirschowitz BI, Curtiss LE, Peters CW, Pollard HM. Demonstration of a new gastroscope, the fiberscope. *Gastroenterology* 1958; **35**: 50; discussion 51-50; discussion 53 [PMID: 13562387 DOI: 10.1016/S0016-5085(19)35579-9] [FullText]
- 9 Cadranel S, Rodesch P, Peeters JP, Cremer M. Fiberendoscopy of the gastrointestinal tract in children. A series of 100 examinations. *Am J Dis Child* 1977; **131**: 41-45 [RCA] [PMID: 299976 DOI: 10.1001/archpedi.1977.02120140043006] [FullText]
- 10 Belsha D, Bremner R, Thomson M. Indications for gastrointestinal endoscopy in childhood. *Arch Dis Child* 2016; **101**: 1153-1160 [RCA] [PMID: 27246069 DOI: 10.1136/archdischild-2014-306043] [FullText]
- 11 Subramanian V, Ragnath K. Advanced endoscopic imaging: a review of commercially available technologies. *Clin Gastroenterol Hepatol* 2014; **12**: 368-76.e1 [RCA] [PMID: 23811245 DOI: 10.1016/j.cgh.2013.06.015] [FullText]
- 12 Jang JY. The past, present, and future of image-enhanced endoscopy. *Clin Endosc* 2015; **48**: 466-475 [RCA] [PMID: 26668791 DOI: 10.5946/ce.2015.48.6.466] [FullText] [Full Text(PDF)]
- 13 Friedt M, Welsch S. An update on pediatric endoscopy. *Eur J Med Res* 2013; **18**: 24 [RCA] [PMID: 23885793 DOI: 10.1186/2047-783X-18-24] [FullText] [Full Text(PDF)]
- 14 Lyons H, Zhang Y, Szpunar S, Dharmaraj R. Predictors of positive esophagogastroduodenoscopy outcomes in children and adolescents: a single center experience. *BMC Res Notes* 2017; **10**: 356 [RCA] [PMID: 28754143 DOI: 10.1186/s13104-017-2693-7] [FullText] [Full Text (PDF)]
- 15 North American Society for Pediatric Gastroenterology, Hepatology and Nutrition. Pediatric Gastroenterology Workforce Survey, 2003-2004. *J Pediatr Gastroenterol Nutr* 2005; **40**: 397-405 [RCA] [PMID: 15795584 DOI: 10.1097/01.mpg.0000158523.92175.50] [FullText]
- 16 ASGE Standards of Practice Committee, Lightdale JR, Acosta R, Shergill AK, Chandrasekhara V, Chathadi K, Early D, Evans JA, Fanelli RD, Fisher DA, Fonkalsrud L, Hwang JH, Kashab M, Muthusamy VR, Pasha S, Saltzman JR, Cash BD; American Society for Gastrointestinal Endoscopy. Modifications in endoscopic practice for pediatric patients. *Gastrointest Endosc* 2014; **79**: 699-710 [RCA] [PMID: 24593951 DOI: 10.1016/j.gie.2013.08.014] [FullText]
- 17 Isoldi S, Cucchiara S, Repici A, Lerner DG, Thomson M, Oliva S. Gastrointestinal endoscopy in children and adults: How do they differ? *Dig Liver Dis* 2021; **53**: 697-705 [RCA] [PMID: 33692010 DOI: 10.1016/j.dld.2021.02.016] [FullText]
- 18 Pall H, Lerner D, Khlevner J, Reynolds C, Kurowski J, Troendle D, Utterson E, Evans PM, Brill H, Wilsey M, Fishman DS. Developing the Pediatric Gastrointestinal Endoscopy Unit: A clinical report by the Endoscopy and Procedures Committee. *J Pediatr Gastroenterol Nutr* 2016; **63**: 295-306 [RCA] [PMID: 26974415 DOI: 10.1097/MPG.0000000000001189] [FullText]
- 19 Dehghan SM, Haghighat M, Imanieh MH, Tabebordbar MR. Upper gastrointestinal bleeding in children in Southern Iran. *Indian J Pediatr* 2009; **76**: 635-638 [RCA] [PMID: 19390793 DOI: 10.1007/s12098-009-0092-3] [FullText]
- 20 Huang IF, Wu TC, Wang KS, Hwang B, Hsieh KS. Upper gastrointestinal endoscopy in children with upper gastrointestinal bleeding. *J Chin Med Assoc* 2003; **66**: 271-275 [RCA] [PMID: 12908568] [FullText]
- 21 Rahman I, Patel P, Boger P, Rasheed S, Thomson M, Afzal NA. Therapeutic upper gastrointestinal tract endoscopy in Paediatric Gastroenterology. *World J Gastrointest Endosc* 2015; **7**: 169-182 [RCA] [PMID: 25789087 DOI: 10.4253/wjge.v7.i3.169] [FullText] [Full Text (PDF)]
- 22 Roy-Shapira A, Stein HJ, Swartz D, Fich A, Sonnenschein E. Endoluminal methods of treating gastroesophageal reflux disease. *Dis Esophagus* 2002; **15**: 132-136 [RCA] [PMID: 12220420 DOI: 10.1046/j.1442-2050.2002.00242.x] [FullText]
- 23 Tan Y, Zhu H, Li C, Chu Y, Huo J, Liu D. Comparison of peroral endoscopic myotomy and endoscopic balloon dilation for primary treatment of pediatric achalasia. *J Pediatr Surg* 2016; **51**: 1613-1618 [RCA] [PMID: 27339081 DOI: 10.1016/j.jpedsurg.2016.06.008] [FullText]
- 24 Coté CJ, Wilson S; American Academy of Pediatrics; American Academy of Pediatric Dentistry. Guidelines for monitoring and management of pediatric patients before, during, and after sedation for diagnostic and therapeutic procedures. *Pediatrics* 2019; **143**: e20191000 [RCA] [PMID: 31138666 DOI: 10.1542/peds.2019-1000] [FullText]
- 25 Messeri A, Caprilli S, Busoni P. Anaesthesia induction in children: a psychological evaluation of the efficiency of parents' presence. *Paediatr Anaesth* 2004; **14**: 551-556 [RCA] [PMID: 15200651 DOI: 10.1111/j.1460-9592.2004.01258.x] [FullText]
- 26 Giles E, Walton-Salih E, Shah N, Hinds R. Routine coagulation screening in children undergoing gastrointestinal endoscopy does not predict those at risk of bleeding. *Endoscopy* 2006; **38**: 508-510 [RCA] [PMID: 16767588 DOI: 10.1055/s-2005-921041] [FullText]
- 27 Fishbein M, Lugo RA, Woodland J, Lininger B, Linscheid T. Evaluation of intranasal midazolam in children undergoing esophagogastroduodenoscopy. *J Pediatr Gastroenterol Nutr* 1997; **25**: 261-266 [RCA] [PMID: 9285375 DOI: 10.1097/00005176-199709000-00004] [FullText]
- 28 Liacouras CA, Mascarenhas M, Poon C, Wenner WJ. Placebo-controlled trial assessing the use of oral midazolam as a premedication to conscious sedation for pediatric endoscopy. *Gastrointest Endosc* 1998; **47**: 455-460 [RCA] [PMID: 9647368 DOI: 10.1016/s0016-5107(98)70244-5] [FullText]
- 29 Early DS, Lightdale JR, Vargo JJ 2nd, Acosta RD, Chandrasekhara V, Chathadi KV, Evans JA, Fisher DA, Fonkalsrud L, Hwang JH, Khashab MA, Muthusamy VR, Pasha SF, Saltzman JR, Shergill AK, Cash BD, DeWitt JM; ASGE Standards of Practice Committee. Guidelines for sedation and anesthesia in GI endoscopy. *Gastrointest Endosc* 2018; **87**: 327-337 [RCA] [PMID: 29306520 DOI: 10.1016/j.gie.2017.07.018] [FullText]
- 30 De Silva AP, Niriella MA, Perera H, Aryasingha S, Kalubovila U, Manchanayake J, Dassanayake AS, Devanarayana NM, Pathmeswaran A, de Silva HJ. Is a six hour fast after a rice meal sufficient before upper gastrointestinal endoscopy? *Scand J Gastroenterol* 2010; **45**: 987-991 [RCA] [PMID: 20334477 DOI: 10.3109/00365521003710174] [FullText]
- 31 Wilson W, Taubert KA, Gewitz M, Lockhart PB, Baddour LM, Levison M, Bolger A, Cabell CH, Takahashi M, Baltimore RS, Newburger JW, Strom BL, Tani LY, Gerber M, Bonow RO, Pallasch T, Shulman ST, Rowley AH, Burns JC, Ferrieri P, Gardner T, Goff D, Durack DT; American Heart Association Rheumatic Fever, Endocarditis, and Kawasaki Disease Committee; American Heart Association Council on Cardiovascular Disease in the Young; American Heart Association Council on Clinical Cardiology; American Heart Association Council on Cardiovascular Surgery and Anesthesia; Quality of Care and Outcomes Research Interdisciplinary Working Group. Prevention of infective endocarditis: guidelines from the American Heart Association: a guideline from the American Heart Association Rheumatic Fever,

- Endocarditis, and Kawasaki Disease Committee, Council on Cardiovascular Disease in the Young, and the Council on Clinical Cardiology, Council on Cardiovascular Surgery and Anesthesia, and the Quality of Care and Outcomes Research Interdisciplinary Working Group. *Circulation* 2007; **116**: 1736-1754 [RCA] [PMID: 17446442 DOI: 10.1161/CIRCULATIONAHA.106.183095] [FullText]
- 32 **Hirota WK**, Petersen K, Baron TH, Goldstein JL, Jacobson BC, Leighton JA, Mallery JS, Waring JP, Fanelli RD, Wheeler-Harborough J, Faigel DO; Standards of Practice Committee of the American Society for Gastrointestinal Endoscopy. Guidelines for antibiotic prophylaxis for GI endoscopy. *Gastrointest Endosc* 2003; **58**: 475-482 [RCA] [PMID: 14520276 DOI: 10.1067/s0016-5107(03)01883-2] [FullText]
- 33 **Levine A**, Koletzko S, Turner D, Escher JC, Cucchiara S, de Ridder L, Kolho KL, Veres G, Russell RK, Paerregaard A, Buderus S, Greer ML, Dias JA, Veereman-Wauters G, Lionetti P, Sladek M, Martin de Carpi J, Staiano A, Ruummele FM, Wilson DC; European Society of Pediatric Gastroenterology, Hepatology, and Nutrition. ESPGHAN revised Porto criteria for the diagnosis of inflammatory bowel disease in children and adolescents. *J Pediatr Gastroenterol Nutr* 2014; **58**: 795-806 [RCA] [PMID: 24231644 DOI: 10.1097/MPG.0000000000000239] [FullText]
- 34 **ASGE Technology Committee**, Barth BA, Banerjee S, Bhat YM, Desilets DJ, Gottlieb KT, Maple JT, Pfau PR, Pleskow DK, Siddiqui UD, Tokar JL, Wang A, Song LM, Rodriguez SA. Equipment for pediatric endoscopy. *Gastrointest Endosc* 2012; **76**: 8-17 [RCA] [PMID: 22579260 DOI: 10.1016/j.gie.2012.02.023] [FullText]
- 35 **Olympus Medical Systems**. Product catalog and specifications. Available from: <https://medical.olympusamerica.com>
- 36 **Fujifilm Endoscopy**. Pediatric endoscope portfolio. Available from: <https://www.fujifilm.com/us/en/healthcare/endoscopy>
- 37 **Lerner DG**, Mencin A, Novak I, Huang C, Ng K, Lirio RA, Khlevner J, Utterson EC, Harris BR, Pitman RT, Mir S, Gugig R, Walsh CM, Fishman D. Advances in pediatric diagnostic endoscopy: A state-of-the-art review. *JPGN Rep* 2022; **3**: e224 [RCA] [PMID: 37168622 DOI: 10.1097/PJG9.0000000000000224] [FullText]
- 38 **Rothbaum RJ**. Complications of pediatric endoscopy. *Gastrointest Endosc Clin N Am* 1996; **6**: 445-459 [PMID: 8673336 DOI: 10.1016/S1052-5157(18)30371-4] [FullText]
- 39 **Hucl T**, Spicak J. Complications of percutaneous endoscopic gastrostomy. *Best Pract Res Clin Gastroenterol* 2016; **30**: 769-781 [RCA] [PMID: 27931635 DOI: 10.1016/j.bpg.2016.10.002] [FullText]
- 40 **Homan M**, Hauser B, Romano C, Tzivinikos C, Torroni F, Gottrand F, Hojsak I, Dall'Oglio L, Thomson M, Bontems P, Narula P, Furlano R, Oliva S, Amil-Dias J. Percutaneous endoscopic gastrostomy in children: An update to the ESPGHAN position paper. *J Pediatr Gastroenterol Nutr* 2021; **73**: 415-426 [RCA] [PMID: 34155150 DOI: 10.1097/MPG.0000000000003207] [FullText]
- 41 **Singh VV**, Draganov P, Valentine J. Efficacy and safety of endoscopic balloon dilation of symptomatic upper and lower gastrointestinal Crohn's disease strictures. *J Clin Gastroenterol* 2005; **39**: 284-290 [RCA] [PMID: 15758621 DOI: 10.1097/01.mcg.0000155128.31208.44] [FullText]
- 42 **Usatin D**, Fernandes M, Allen IE, Perito ER, Ostroff J, Heyman MB. Complications of endoscopic retrograde cholangiopancreatography in pediatric patients: A systematic literature review and meta-analysis. *J Pediatr* 2016; **179**: 160-165.e3 [RCA] [PMID: 27663215 DOI: 10.1016/j.jpeds.2016.08.046] [FullText] [Full Text(PDF)]
- 43 **Dar AQ**, Shah ZA. Anesthesia and sedation in pediatric gastrointestinal endoscopic procedures: A review. *World J Gastrointest Endosc* 2010; **2**: 257-262 [RCA] [PMID: 21160616 DOI: 10.4253/wjge.v2.i7.257] [FullText] [Full Text(PDF)]
- 44 **Lerner DG**, Li BU, Mamula P, Fishman DS, Kramer R, Goh VL, El-Chammas K, Pentiu SP, Rothbaum R, Gurram B, Rahhal RM, Goday PS, Vitola B. Challenges in meeting fellowship procedural guidelines in pediatric therapeutic endoscopy and liver biopsy. *J Pediatr Gastroenterol Nutr* 2014; **58**: 27-33 [RCA] [PMID: 24051484 DOI: 10.1097/MPG.000000000000184] [FullText]
- 45 **Dahshan A**, Rabah R. Correlation of endoscopy and histology in the gastroesophageal mucosa in children: are routine biopsies justified? *J Clin Gastroenterol* 2000; **31**: 213-216 [RCA] [PMID: 11033999 DOI: 10.1097/00004836-200010000-00005] [FullText]
- 46 **Aydin M**, Niggeschmidt J, Ballauff A, Wirth S, Hensel KO. Common indications and the diagnostic yield of esophagogastroduodenoscopy in children with gastrointestinal distress. *Klin Padiatr* 2019; **231**: 21-27 [RCA] [PMID: 30021234 DOI: 10.1055/a-0628-7001] [FullText]
- 47 **Noble AJ**, Drouin E, Tamblyn R. Design of predictive models for positive outcomes of upper and lower gastrointestinal endoscopies in children and adolescents. *J Pediatr Gastroenterol Nutr* 2008; **46**: 409-413 [RCA] [PMID: 18367953 DOI: 10.1097/MPG.0b013e3181565e3c] [FullText]
- 48 **Berger TD**, Soffer S, Vurzel-Harel T, Silbermintz A, Fleishaker H, Shamir R, Zevit N. The yield of upper gastrointestinal endoscopy at a pediatric tertiary care center. *Isr Med Assoc J* 2020; **22**: 164-168 [RCA] [PMID: 32147981] [FullText]



Published by **Baishideng Publishing Group Inc**  
7041 Koll Center Parkway, Suite 160, Pleasanton, CA 94566, USA  
**Telephone:** +1-925-3991568  
**E-mail:** [office@baishideng.com](mailto:office@baishideng.com)  
**Help Desk:** <https://www.f6publishing.com/helpdesk>  
<https://www.wjgnet.com>

