



Name of journal: *World Journal of Orthopedics*

ESPS Manuscript NO: 19708

Manuscript Type: REVIEW

**Surgical management of sickle cell disease of the hip**

Atul F Kamath, Michael H. McGraw, Craig L. Israelite

**Abstract**

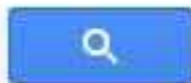
Sickle cell disease is a known risk factor for osteonecrosis of the hip. Necrosis within the femoral head may cause severe pain, functional limitations, and compromise quality of life in this patient population. Early stages of avascular necrosis of the hip may be

Match Overview

|   |   |     |
|---|---|-----|
| 1 | Internet 42 words<br>crawled on 09-May-2010<br><a href="http://www.wikidoc.org">www.wikidoc.org</a>   | 1%  |
| 2 | CrossCheck 37 words<br>M KAIN. "Total Hip Arthroplasty in Patients with Metabolic Diseases", <i>Surgical Treatment of Hip Arthritis</i> , 2009      | 1%  |
| 3 | Publications 29 words<br>"Study Results from University of Pennsylvania Update ...<br>nderstanding of Disease Progression.(Report)", <i>Medical</i> | 1%  |
| 4 | Internet 13 words<br>crawled on 04-Dec-2013<br><a href="http://www.ncbi.nlm.nih.gov">www.ncbi.nlm.nih.gov</a>                                       | <1% |
| 5 | CrossCheck 13 words<br>Sierra, Rafael, Matthew Houdek, Gody Wyles, and John<br>Martin. "Stem cell treatment for avascular necrosis of ti ...        | <1% |
| 6 | CrossCheck 9 words<br>M. C. Chamberlain. "Recurrent Cerebellar Gliomas: Sc...<br>age Therapy With Oral Etoposide", <i>Journal of Child Neur</i>     | <1% |



Surgical management of sickle cell disease of the hip



学术搜索

找到约 14,700 条结果 (用时0.11秒)

我的著作引用情况

文章

我的图书馆

时间不限

2015以来

2014以来

2011以来

自定义范围...

按相关性排序

按日期排序

搜索所有网页

中文网页

简体中文网页

包括专利

包含引用

创建快讯

小提示: 只搜索中文(简体)结果, 可在 学术搜索设置 指定搜索语言

### A comparison of conservative and aggressive transfusion regimens in the perioperative management of sickle cell disease

EP Vichinsky, CM Haberkern, L Neumayr... - ... England Journal of ..., 1995 - Mass Medical Soc  
... Patients were enrolled at 36 centers. Each institution had a principal investigator, surgeon, anesthesiologist, data coordinator, and nurse assigned to the study. ... Surgical management of patients with sickle cell syndromes. In: Mankad VN, Moore RB, eds. ... Surgery and anesthesia. ...  
被引用次数: 424 相关文章 所有 6 个版本 引用 保存

### Sickle cell disease as a cause of osteonecrosis of the femoral head

PF Milner, AP Kraus, JI Sebes... - ... England Journal of ..., 1991 - Mass Medical Soc  
... 2009) Outcomes of inpatients with and without sickle cell disease after high-volume surgical procedures. American Journal of Hematology 84:11, 703-709. ... Journal of Shoulder and Elbow Surgery 16:2, 129-134. 37. ... (2005) Three decades of innovation in the management of sickle ...  
被引用次数: 220 相关文章 所有 4 个版本 引用 保存

### Total replacement of the hip for avascular necrosis in sickle cell disease

HJ Clarke, RH Jinnah, AF Brooker... - ... Bone & Joint Surgery ..., 1989 - bjj.boneandjoint.org.uk  
... Surgeons should be aware of these problems. Sickle cell disease is a life-threatening condition. An ... disease due to improved medical management means ... two of the patients who had exchange transfusion developed mild sickle crises after surgery. ...  
被引用次数: 78 相关文章 所有 7 个版本 引用 保存

boneandjoint.org.uk 中的 [PDF]

### Osteonecrosis of the hip in the sickle-cell diseases. Treatment and complications.

GJ Hanker, HC Amstutz - The Journal of Bone & Joint Surgery, 1988 - jbjs.org  
Abstract The results of arthroplasty of the hip and other surgical procedures that were performed in nine patients who had sickle-cell disease or sickle-cell trait and osteonecrosis



[网页](#) [图片](#) [视频](#) [新闻](#) [更多 ▾](#) [搜索工具](#)

找到约 41,000 条结果 (用时 0.58 秒)

## Google 学术: Surgical management of osteonecrosis of the femoral head in patients with sickle cell disease

... cell disease as a cause of osteonecrosis of the femoral ... - [Milner](#) - 被引用次数: 221

Treatment of osteonecrosis of the femoral head with ... - [Gangji](#) - 被引用次数: 365

Avascular necrosis of the femoral head in sickle-cell ... - [Hernigou](#) - 被引用次数: 73

## Physical therapy alone compared with core decompression ...

[www.ncbi.nlm.nih.gov/pubmed/17142406](http://www.ncbi.nlm.nih.gov/pubmed/17142406) ▾ [翻译此页](#)

作者: LD Neumayr - 2006 - 被引用次数: 50 - [相关文章](#)

Physical **therapy** alone compared with core decompression and physical **therapy** for **femoral head osteonecrosis in sickle cell disease**. ... Oakland, CA 94609, and Department of Orthopaedic **Surgery**, University of California, ... alone for the **treatment of osteonecrosis of the femoral head in patients with sickle cell disease**.

## Management of avascular necrosis of femoral head at pre ...

[www.ncbi.nlm.nih.gov](http://www.ncbi.nlm.nih.gov) > ... > [PubMed Central \(PMC\)](#) ▾ [翻译此页](#)

作者: RK Sen - 2009 - 被引用次数: 45 - [相关文章](#)

The **avascular necrosis (AVN) or osteonecrosis of the femur head (ONFH)**, ... of the lesion (at pre-collapse stage) have been managed with hip salvage **surgery**. ..... in necrotic lesions of the **femoral head in patients with sickle cell disease**.

## Femoral Head Avascular Necrosis Treatment & Management

[emedicine.medscape.com/article/86568-treatment](http://emedicine.medscape.com/article/86568-treatment) ▾ [翻译此页](#)

**Avascular necrosis (AVN) of the femoral head** is a pathologic process that results from ... If symptoms ensue, repeat imaging and **surgical treatment** are indicated. ... when **patients** are carefully selected in early stages of the disease (stage I). ... often associated with