

47540-Review

By Tomofumi Horie

WORD COUNT

4201

TIME SUBMITTED

13-MAY-2019 05:22PM

PAPER ID

47005216

Name of Journal: *World Journal of Gastrointestinal Endoscopy*

Manuscript NO: 47540

Manuscript Type: ORIGINAL ARTICLE

Retrospective Study

Endoscopic characteristics of small intestinal malignant tumors observed by balloon-assisted enteroscopy

Horie T *et al.* Endoscopic characteristics of small intestinal tumors

Tomofumi Horie, Naoki Hosoe, Kaoru Takabayashi, Yukie Hayashi, Kenji JL Limpias Kamuya, Ryoichi Miyanaga, Shinta Mizuno, Kayoko Fukuhara, Seiichiro Fukuhara, Makoto Naganuma, Masayuki Shimoda, Haruhiko Ogata, Takanori Kanai

Abstract

BACKGROUND

Capsule endoscopy and balloon-assisted enteroscopy (BAE) enable visualization of rare small bowel conditions such as small intestinal malignant tumors. However, details of the endoscopic characteristics of small intestinal malignant tumors are still unknown.

AIM

To elucidate the endoscopic characteristics of small intestinal malignant tumors.

METHODS

From March 2005 to February 2017, 1329 BAE procedures were performed at Keio University Hospital. Of these procedures, malignant tumors were classified into three groups, Group 1: epithelial tumors including primary small intestinal cancer, metastatic small intestinal cancer, and direct small intestinal invasion by an adjacent organ cancer; Group 2: small intestinal malignant lymphoma; and Group 3, small intestinal gastrointestinal stromal tumors. We systematically collected clinical and endoscopic data from patients' medical records to determine the endoscopic

characteristics for each group.

RESULTS

The number of patients in each group was 16 (Group 1), 23 (Group 2), and 6 (Group 3), and the percentage of solitary tumors was 100%, 43.5%, and 100%, respectively ($P < 0.001$). Patients' clinical background parameters including age, symptoms, and laboratory data were not significantly different between the groups. Seventy-five percent of epithelial tumors (Group 1) were located in the upper small intestine (duodenum and ileum), and approximately 70% of gastrointestinal stromal tumors (Group 3) were located in the jejunum. Solitary protruding or mass-type tumors were not seen in malignant lymphoma (Group 2) ($P < 0.001$). Stenosis was seen more often in Group 1, (68.8%, 27.3%, and 0%; Group 1, 2, and 3, respectively; $P = 0.004$). Enlarged white villi inside and/or surrounding the tumor were seen in 12.5%, 54.5%, and 0% in Group 1, 2, and 3, respectively ($P = 0.001$).

CONCLUSION

The differential diagnosis of small intestinal malignant tumors could be tentatively made based on BAE findings.

INTRODUCTION

The small intestine is a long luminal organ that constitutes 75% of the length of gastrointestinal tract and 90% of its mucosal surface area. Small intestinal cancer is relatively rare, accounting for less than 5% of gastrointestinal cancers^[1] and with an incidence of 6.8 cases per million^[2]. The gastrointestinal tract is a major organ affected by extranodal malignant lymphoma, accounting for 30%–40% of all extranodal lymphomas and 5%–20% of all non-Hodgkin lymphomas^[3]. The most frequent primary gastrointestinal site of malignant lymphoma is the stomach (60%–70%), followed by the small intestine (20%–30%)^[4]. Until the development of balloon-assisted enteroscopy (BAE) and video capsule endoscopy, small intestinal malignant tumors could not be observed endoscopically. Moreover, BAE enables direct observation of these small intestinal lesions, and also permits biopsy and endoscopic therapy, such as stent

placement and endoscopic tattooing for subsequent surgical therapy^{15,61}. A previous study reported the incidence of small intestinal tumors detected by BAE^{16,71}; however, the endoscopic characteristics of small intestinal tumors have been reported only in a limited number of case reports¹⁸⁻¹⁰¹, and the details of these characteristics are still unknown.

The aim of this study was to investigate the endoscopic characteristics of small intestinal malignant tumors observed by BAE.

MATERIALS AND METHODS

This study was a retrospective medical record analysis and was approved by the ethics committee of Keio University Hospital (approval number, 20160431). Data was collected from patients' medical records, and the endoscopy findings were collected using an endoscopy reporting system (Solemio ENDO®, Olympus, Tokyo, Japan). Patients who underwent BAE (EN450/T5 or EN450/P5; Fujifilm, Tokyo, Japan or SIF-Q260; Olympus, Tokyo, Japan) between March 2005 and February 2017 in Keio University Hospital were screened. Of the 1329 procedures, 44 small intestinal malignant tumors were seen endoscopically, and data for these tumors were included in the analysis. Benign small intestinal polyp and polyposis syndrome such as Peutz-Jeghers syndrome and familial adenomatous were excluded from the analysis. The included small intestinal malignant tumors were classified into three groups: Group 1: epithelial tumors including primary small intestinal cancer (adenocarcinoma), metastatic small intestinal cancer (adenocarcinoma), and direct small intestinal invasion by adjacent organ cancer (adenocarcinoma); Group 2: small intestinal malignant lymphoma; and Group 3: small intestinal gastrointestinal stromal tumors (GIST). Patients' clinical background parameters included age, symptom, and laboratory data. To define the endoscopic characteristics for each group, endoscopic data such as tumor location, solitary or multiple lesions, type or form, presence of stenosis, presence of bleeding, and presence of white villi were systematically collected from patients' medical charts and the endoscopy reporting system. Solitary and multiple lesions were confirmed by computed tomography and/or barium swallow. Stricture was defined as a stenosis through which we could not pass an enteroscope

(EN450/T5 or SIF-Q260). Bleeding was defined as spontaneous bleeding before passing the enteroscope. We also focused on the endoscopic findings of white villi in malignant lymphoma. To determine the morphological and pathological characteristics of white villi in malignant lymphoma, we compared the pathological findings and endoscopic findings from each biopsy site.

Statistical analysis

Statistical analyses were performed using the Fisher's exact test for percentages and one way ANOVA to assess differences in parameters showing a normal distribution. Non-normally distributed data were analyzed using the Kruskal-Wallis test. *P*-values < 0.05 were considered significant, and SPSS version 22 software (SPSS Inc., Tokyo, Japan) was used for all statistical analyses.

RESULTS

A flow diagram of patient enrollment is shown in Figure 1. In total, 1328 BAE procedures were performed from March 2005 to February 2017. Of these 1328 procedures, the number of patients in each group was 16 (Group 1), 22 (Group 2), and 6 (Group 3) (Figure 1). Table 1 shows the patients' characteristics. We found no statistically-significant difference in age, symptoms (epigastric pain, melena, weight loss), and blood test results (white blood cell count, hemoglobin, lactate dehydrogenase) between the groups. The endoscopic characteristics of the small intestinal malignant tumors are shown in Table 2 and Figure 2. Seventy-five percent of epithelial tumors (Group 1) were located in the upper small intestine (duodenum and jejunum), and approximately 70% of GISTs were located in the jejunum. The percentage of solitary tumors was 100%, 45.5%, and 100% in Group 1, 2, and 3, respectively ($P < 0.001$). Solitary protruding or mass-type tumors were not seen in malignant lymphoma (Group 2) ($P < 0.001$). Solitary infiltrative ulcerated type tumors were seen only in Group 1 ($P = 0.007$) (Figure 2A). Multiple lesions with ulcerated surfaces or polyposis were seen only in Group 2, and stenosis was seen more frequently in Group 1, (68.8%, 27.3%, and 0%; Group 1, 2, and 3, respectively; $P = 0.004$). Although the difference was not statistically significant, Group 1 tended to have more

bleeding compared with Group 2 and 3. Enlarged white villi inside and/or surrounding the tumor were seen in 12.5%, 54.5%, and 0% in Group 1, 2 and 3, respectively ($P < 0.001$) (Figure 2B and C). We further investigated the pathological and morphological features of white villi in Group 2. Adequate biopsy samples were not obtained from four patients; therefore, we excluded data for these patients from the analysis (Table 3). Of the 22 Group 2 patients, enlarged white villi were seen in 12 patients. At the biopsy sites where most of the white villi were seen, lymphoma cells infiltrated into the villi with an intact epithelium; villi were filled with lymphoma cells (Table 3 and Figure 3). When the intact epithelium was ulcerated or lymphoma cells were present in the deep mucosa, white villi could not be seen (Table 3 and Figure 4).

DISCUSSION

In the current study, we described the endoscopic characteristics of tumor location and morphology of small intestinal malignant tumors. Small intestinal malignant tumors were classified into three groups, and statistical analyses were performed between the groups. Patients' clinical background parameters including age, symptoms, and laboratory data were not significantly different between the groups. First, we evaluated the endoscopic characteristics of tumor location and the number of tumors. Approximately three quarters of epithelial tumors were found in the duodenum or jejunum, and all were observed as solitary lesions (Table 2). Previous studies using BAE reported that primary small intestinal adenocarcinoma was located mainly in the duodenum or jejunum with a range of 77.8%–100.0%^[6,7,11-14]. Primary small intestinal adenocarcinoma was reported as a solitary lesion in several studies^[6,7,12-14], which was consistent with our results, whereas metastatic tumors were sometimes observed as multiple lesions^[11,15]. In our classification, primary and metastatic tumors were classified into the same groups; however, it might be better to distinguish between metastatic and primary tumors. In the current study, malignant lymphoma lesions were located mainly in the jejunum and ileum, and approximately 60% were multiple lesions (Table 2), consistent with previous reports^[11-14,16]. GISTs are reported mainly as solitary jejunal tumors^[11-13,17,18]. Nakano *et al*^[19] reported that 76% of patients with GIST had jejunal lesions, and that 3/25 patients had tumors in multiple sites (stomach and

jejunum: 1; duodenum and jejunum: 1; and stomach, duodenum, and jejunum: 1). A particular type of GIST that is associated with neurofibromatosis type1 appears as multiple tumors^[20-22]. However, as our results, most GISTs appeared as a solitary jejunal tumor, except for neurofibromatosis type1 associated type^[20-22].

The endoscopic morphology of small intestinal tumors has not been systemically evaluated. In the current study, we evaluated the endoscopic morphology of small intestinal tumors. Epithelial tumors appeared as protruded or mass type, ulcerated type, or infiltrative ulcerated type, and 68.8% (11/16) were associated with stenosis. The infiltrative ulcerated type was typically recognized in epithelial tumors (Figure 2A). Malignant lymphoma appeared mainly as multiple lesions such as multiple ulcers or multiple lymphomatous polyposis (MLP), and stenosis was detected in 6/22 patients (27.3%). GIST was observed as the protruded or mass type [66.7% (4/6)], or the ulcerated type [33.3 % (2/6)] without stenosis. Chung *et al*^[7] and Imaoka *et al*^[12] reported that most small bowel adenocarcinomas appeared as the ulcerative form. Imaoka *et al*^[12] and Almeida *et al*^[23] reported that most epithelial small bowel tumors were associated with stenosis [70% (7/10) and 100% (3/3), respectively], similar to our findings. Previous reports^[12,23,24] showed that malignant lymphoma occurred mainly as multiple lesions, such as multiple ulcers or MLP. MLP as multiple white nodules was observed in follicular lymphoma in previous studies^[3,24-27]. Nakano *et al*^[19] reported that the morphology of GISTs was classified into three groups: intraductal, extraductal, and mixed type. Lesions in 21 patients occurred as submucosal tumors and two occurred as diverticular transformation, in the 18 patients with ulceration. We saw no diverticular transformation in our study.

Of 22 patients with malignant lymphoma, enlarged white villi were seen in 12 patients (Table 2, Figure 3). The pathological and morphological features of the white villi biopsy sites showed that the lymphoma cells had infiltrated into the villi with an intact epithelium (Table 3 and Figure 3). In the current study, there were two types of malignant lymphoma that did not exhibit white villi. The first type showed the lymphoma cells sparsely infiltrated the villi, some lymphoma cells presented in the deep mucosa (Figure 4A and B). The second type showed the lymphoma cells infiltrated the mucosa without an intact epithelium (Figure 4C and D). Endoscopic

findings of follicular lymphoma were described as “multiple polypoid lesions” and “multiple whitish small polyps” in a previous study^[24]. These whitish polypoid lesions were seen as enlarged white villi using magnifying endoscopy^[28-30]. Yamamoto *et al*^[24] reported that each white enlarged villus was an enlarged neoplastic follicle consisting of lymphoma cells in the lamina propria, which was confirmed histologically. Another report showed that enlarged white duodenal villi were caused by infiltration of lymphoma cells into the villi, which formed lymphoid follicles^[29]. From the pathological findings of our study, jejunal and/or ileal white villi in malignant lymphoma, even in other than the follicular type, are considered to consist of lymphoma cells in the lamina propria as with duodenal follicular lymphoma. Previous reports describe white villi of duodenal follicular lymphoma using esophagogastroduodenoscopy^[24,28-30]. To our knowledge, ours is the first report of white villi in jejunal and ileal malignant lymphoma observed by BAE.

The endoscopic characteristics of the small intestinal tumors in our study are summarized in Table 4. Generally, epithelial small intestinal tumors appeared as solitary tumors with stenosis, small intestinal malignant lymphoma tumors as multiple tumors with white villi, and GISTs as solitary protruded lesions.

Several limitations of this study should be addressed. First, this was a retrospective study; thus, many confounding factors could affect the results. Second, small intestinal tumors are very rare, and our sample size was relatively small. Future studies require higher numbers of patients to analyze larger datasets. However, there have been few studies to show the differences of endoscopic features among group1, 2 and 3. Furthermore, the importance of “white villi” could be emphasized in our study.

In conclusion, based on endoscopic findings during BAE, we were able to make tentative differential diagnoses of small intestinal malignant tumors.

REFERENCES

- 1 Neugut AI, Jacobson JS, Suh S, Mukherjee R, Arber N. The epidemiology of cancer of the small bowel. *Cancer Epidemiol Biomarkers Prev* 1998; 7: 243-251 [PMID: 9521441]
- 2 Schottenfeld D, Beebe-Dimmer JL, Vigneau FD. The epidemiology and pathogenesis of neoplasia in the small intestine. *Ann Epidemiol* 2009; 19: 58-69 [PMID: 19064190 DOI:

10.1016/j.annepidem.2008.10.004]

3 Nakamura S, Matsumoto T. Gastrointestinal lymphoma: recent advances in diagnosis and treatment. *Digestion* 2013; 87: 182-188 [PMID: 23635497 DOI: 10.1159/000350051]

4 Nakamura S, Matsumoto T, Iida M, Yao T, Tsuneyoshi M. Primary gastrointestinal lymphoma in Japan: a clinicopathologic analysis of 455 patients with special reference to its time trends. *Cancer* 2003; 97: 2462-2473 [PMID: 12733145 DOI: 10.1002/cncr.11415]

5 Yamamoto H, Kita H, Sunada K, Hayashi Y, Sato H, Yano T, Iwamoto M, Sekine Y, Miyata T, Kuno A, Ajibe H, Ido K, Sugano K. Clinical outcomes of double-balloon endoscopy for the diagnosis and treatment of small-intestinal diseases. *Clin Gastroenterol Hepatol* 2004; 2: 1010-1016 [PMID: 15551254 DOI: 10.1016/S1542-3565(04)00453-7]

6 Mitsui K, Tanaka S, Yamamoto H, Kobayashi T, Ehara A, Yano T, Goto H, Nakase H, Tanaka S, Matsui T, Iida M, Sugano K, Sakamoto C. Role of double-balloon endoscopy in the diagnosis of small-bowel tumors: the first Japanese multicenter study. *Gastrointest Endosc* 2009; 70: 498-504 [PMID: 19555947 DOI: 10.1016/j.gie.2008.12.242]

7 Chung CS, Tai CM, Huang TY, Chang CW, Chen KC, Tseng CM, Wang HY, Chu CH, Wu JM, Chen Y, Wang HP. Small bowel tumors: A digestive endoscopy society of Taiwan (DEST) multicenter enteroscopy-based epidemiologic study. *J Formos Med Assoc* 2018; 117: 705-710 [PMID: 28988888 DOI: 10.1016/j.jfma.2017.09.003]

8 Kawano S, Miyashima Y, Miyabe Y, Kawai Y, Murata T, Uda M, Inokuchi T, Okada H. A case of small intestinal neuroendocrine carcinoma diagnosed using double-balloon endoscopy with long-term survival. *Clin J Gastroenterol* 2018; 11: 240-244 [PMID: 29450787 DOI: 10.1007/s12328-018-0834-8]

9 Li X, Gui Y, Shen F, Zhao CL, Yang Y, Han W. The application value of capsule endoscopy in diagnosing small intestinal carcinoma. *J Cancer Res Ther* 2018; 14: 57-60 [PMID: 29516960 DOI: 10.4103/jcrt.JCRT_584_17]

10 Ying X, Wang M, Verma V, Wang M, Ye S, Bi J, Zhou X, Han G, Zhen W. Metastatic spread of solid subtype lung adenocarcinoma to the small intestine with anemia and melena: A case report. *Medicine (Baltimore)* 2017; 96: e7768 [PMID: 28834880 DOI: 10.1097/MD.00000000000007768]

11 Honda W, Ohnuya N, Hirooka Y, Nakamura M, Miyahara R, Ohno E, Kawashima

H, Itoh A, Watanabe O, Ando T, Goto H. Enteroscopic and radiologic diagnoses, treatment, and prognoses of small-bowel tumors. *Gastrointest Endosc* 2012; 76: 344-354 [PMID: 22817787 DOI: 10.1016/j.gie.2012.04.443]

12 Imaoka H, Higaki N, Kumagi T, Miyaike J, Ohmoto M, Yamauchi K, Murakami T, Murakami H, Ikeda Y, Yokota T, Shibata N, Ninomiya T, Abe M, Hiasa Y, Matsuura B, Onji M, Umeda M, Horiike N. Characteristics of small bowel tumors detected by double balloon endoscopy. *Dig Dis Sci* 2011; 56: 2366-2371 [PMID: 21597978 DOI: 10.1007/s10620-011-1741-8]

13 Chen WG, Shan GD, Zhang H, Li L, Yue M, Xiang Z, Cheng Y, Wu CJ, Fang Y, Chen LH. Double-balloon enteroscopy in small bowel tumors: a Chinese single-center study. *World J Gastroenterol* 2013; 19: 3665-3671 [PMID: 23801870 DOI: 10.3748/wjg.v19.i23.3665]

14 Yamagami H, Oshitani N, Hosomi S, Suekane T, Kamata N, Sogawa M, Okazaki H, Watanabe K, Tominaga K, Watanabe T, Fujiwara Y, Arakawa T. Usefulness of double-balloon endoscopy in the diagnosis of malignant small-bowel tumors. *Clin Gastroenterol Hepatol* 2008; 6: 1202-1205 [PMID: 18799359 DOI: 10.1016/j.cgh.2008.05.014]

15 Nishimura N, Mizuno M, Shimodate Y, Doi A, Mouri H, Matsueda K, Yamamoto H. The Role of Double-balloon Enteroscopy in the Diagnosis and Surgical Treatment of Metastatic Small Bowel Tumors. *Intern Med* 2018; 57: 1209-1212 [PMID: 29279517 DOI: 10.2169/internalmedicine.9877-17]

16 Lee BI, Choi H, Choi KY, Byeon JS, Jang HJ, Eun CS, Cheon JH, Shin SJ, Kim JO, Lee MS, Choi JH. Clinical characteristics of small bowel tumors diagnosed by double-balloon endoscopy: KASID multi-center study. *Dig Dis Sci* 2011; 56: 2920-2927 [PMID: 21814803 DOI: 10.1007/s10620-011-1839-z]

17 Zhou L, Liao Y, Wu J, Yang J, Zhang H, Wang X, Sun S. Small bowel gastrointestinal stromal tumor: a retrospective study of 32 cases at a single center and review of the literature. *Ther Clin Risk Manag* 2018; 14: 1467-1481 [PMID: 30174429 DOI: 10.2147/TCRM.S167248]

18 Murino A, Nakamura M, Watanabe O, Yamamura T, Nagura A, Yoshimura T, Nakano A, Goto H, Hirooka Y. Effectiveness of Endoscopic Ultrasonography during

Double Balloon Enteroscopy for characterization and management of small bowel submucosal tumours. *Dig Liver Dis* 2016; **48**: 1187-1193 [PMID: 27474200 DOI: 10.1016/j.dld.2016.06.026]

19 Nakano A, Nakamura M, Watanabe O, Yamamura T, Funasaka K, Ohno E, Kawashima H, Miyahara R, Goto H, Hirooka Y. Endoscopic Characteristics, Risk Grade, and Prognostic Prediction in Gastrointestinal Stromal Tumors of the Small Bowel. *Digestion* 2017; **95**: 122-131 [PMID: 28161705 DOI: 10.1159/000454728]

20 Salvi PF, Lorenzon L, Caterino S, Antolino L, Antonelli MS, Balducci G. Gastrointestinal stromal tumors associated with neurofibromatosis 1: a single centre experience and systematic review of the literature including 252 cases. *Int J Surg Oncol* 2013; **2013**: 398570 [PMID: 24386562 DOI: 10.1155/2013/398570]

21 Miettinen M, Fetsch JF, Sobin LH, Lasota J. Gastrointestinal stromal tumors in patients with neurofibromatosis 1: a clinicopathologic and molecular genetic study of 45 cases. *Am J Surg Pathol* 2006; **30**: 90-96 [PMID: 16330947 DOI: 10.1097/01.pas.0000176433.81079.bd]

22 Hakozaki Y, Sameshima S, Tatsuoka T, Okuyama T, Yamagata Y, Noie T, Oya M, Fujii A, Ueda Y, Shimura C, Katagiri K. Rectal carcinoma and multiple gastrointestinal stromal tumors (GIST) of the small intestine in a patient with neurofibromatosis type 1: a case report. *World J Surg Oncol* 2017; **15**: 160 [PMID: 28835241 DOI: 10.1186/s12957-017-1231-3]

23 Almeida N, Figueiredo P, Lopes S, Gouveia H, Leitão MC. Double-balloon enteroscopy and small bowel tumors: a South-European single-center experience. *Dig Dis Sci* 2009; **54**: 1520-1524 [PMID: 18958620 DOI: 10.1007/s10620-008-0512-7]

24 Yamamoto S, Nakase H, Yamashita K, Matsuura M, Takada M, Kawanami C, Chiba T. Gastrointestinal follicular lymphoma: review of the literature. *J Gastroenterol* 2010; **45**: 370-388 [PMID: 20084529 DOI: 10.1007/s00535-009-0182-z]

25 Higuchi K, Komatsu K, Wakamatsu H, Kawasaki H, Murata M, Miyazaki K, Oikawa K, Ohwada M, Nanjo H, Otaka M, Watanabe S, Komatsu K. Small intestinal follicular lymphoma with multiple tumor formations diagnosed by double-balloon enteroscopy. *Intern Med* 2007; **46**: 705-709 [PMID: 17541220 DOI: 10.2169/internalmedicine.46.6087]

26 Nakamura M, Ohmiya N, Hirooka Y, Miyahara R, Ando T, Watanabe O, Itoh A, Kawashima H, Ohno E, Kinoshita T, Goto H. Endoscopic diagnosis of follicular lymphoma with small-bowel involvement using video capsule endoscopy and double-balloon endoscopy: a case series. *Endoscopy* 2013; 45: 67-70 [PMID: 23208779 DOI: 10.1055/s-0032-1325867]

27 Matsumoto T, Nakamura S, Esaki M, Yada S, Moriyama T, Yanai S, Hirahashi M, Yao T, Iida M. Double-balloon endoscopy depicts diminutive small bowel lesions in gastrointestinal lymphoma. *Dig Dis Sci* 2010; 55: 158-165 [PMID: 19241169 DOI: 10.1007/s10620-009-0713-8]

28 Iwamuro M, Kondo E, Otsuka F, Takata K, Yoshino T, Kawahara Y, Okada H. Detection of Minute Duodenal Follicular Lymphoma Lesions Using Magnifying Endoscopy. *Acta Med Okayama* 2016; 70: 139-144 [PMID: 27094839 DOI: 10.18926/AMO/54193]

29 Iwamuro M, Okada H, Takata K, Kawai Y, Kawano S, Nasu J, Kawahara Y, Tanaka T, Yoshino T, Yamamoto K. Magnified endoscopic features of duodenal follicular lymphoma and other whitish lesions. *Acta Med Okayama* 2015; 69: 37-44 [PMID: 25703169 DOI: 10.18926/AMO/53120]

30 Iwamuro M, Okuda M, Yumoto E, Suzuki S, Shirakawa A, Takata K, Yoshino T, Okada H, Yamamoto K. Magnifying endoscopy for intestinal follicular lymphoma is helpful for prompt diagnosis. *Gut Liver* 2013; 7: 258-261 [PMID: 23560166 DOI: 10.5009/gnl.2013.7.2.258]

Table 1 Patients' characteristics

	Group 1 (epithelial)	Group 2 (malignant lymphoma)	Group 3 (GIST)	P-value
Age (mean ± SD)	62.9 ± 13.7	67.7 ± 7.1	67.0 ± 11.9	0.47
Symptom (%)				
Epigastric pain	25.0 (4/16)	27.3 (6/22)	0 (0/6)	0.36
Melena	25.0 (4/16)	13.6 (3/22)	16.7 (1/6)	0.67
Weight loss	6.3 (1/16)	4.5 (1/22)	0 (0/16)	0.82

Other	43.8 (7/16)	54.5 (12/22)	83.3 (5/6)	N/A
Blood test results (mean \pm SD)				
WBC (/ μ L)	7712.5 \pm 3428.1	6536.4 \pm 2858.5	4950.0 1312.6	\pm 0.25
Hb (g/dL)	10.7 \pm 2.7	11.6 \pm 2.1	12.2 \pm 2.4	0.63
LDH (IU/L)	201.0 \pm 52.1	189.9 \pm 49.1	175.0 \pm 35.8	0.35

N/A: Not applicable; GIST: Gastrointestinal stromal tumor; WBC: White blood cell count; Hb: Hemoglobin; LDH: Lactate dehydrogenase.

Table 2 Endoscopic characteristics of the small intestinal malignant tumors

	Group 1 (Epithelial) (%)	Group 2 (Malignant lymphoma) (%)	Group 3 (GIST) (%)	P-value
Tumor location				
Duodenum	43.8 (7/16)	18.2 (4/22)	16.7 (1/6)	0.18
Jejunum	31.3 (5/16)	50.0 (11/22)	66.7 (4/6)	0.28
Ileum	25.0 (4/16)	45.5 (10/22)	16.7 (1/6)	0.26
Solitary lesion	100.0 (16/16)	45.5 (10/22)	100.0 (6/6)	< 0.001
Type or form				
Solitary				
Protruded or mass type	31.3 (5/16)	0 (0/22)	66.7 (4/6)	< 0.001
Ulcerated type				
(with raised margins)	37.5 (6/16)	40.9 (9/22)	33.3 (2/6)	0.94
Infiltrative ulcerated type	31.3 (5/16)	0 (0/22)	0 (0/6)	0.007
Multiple				
Multiple ulcers	0 (0/16)	22.7 (5/22)	0 (0/6)	0.06
MLP	0 (0/16)	13.6 (3/22)	0 (0/6)	0.20
Others	0 (0/16)	22.7 (5/22)	0 (0/6)	N/A
Presence of stenosis	68.8 (11/16)	27.3 (6/22)	0 (0/6)	0.004
Presence of bleeding	43.8 (7/16)	22.7 (5/22)	16.7 (1/6)	0.178
White villi	12.5 (2/16)	54.5 (12/22)	0 (0/6)	< 0.001

GIST: Gastrointestinal stromal tumor; MLP: Multiple lymphomatous polyposis.

Table 3 Pathological features of the biopsy sites with or without white villi in malignant lymphoma

	White villi		P-value
	Presence	Absence	
Lymphoma cells infiltrating the villi with an intact epithelium	91.7% (11/12)	0 % (0/10)	< 0.001
Lymphoma cells infiltrating the villi without an intact epithelium	0% (0/12)	50.0% (5/10)	0.293
Lymphoma cells present in the deep mucosa	0% (0/12)	20.0% (2/10)	0.195
Not assessed	8.3% (1/12)	30% (3/10)	N/A

N/A: Not applicable.

Table 4 Summary of the endoscopic characteristics of the small intestinal tumors

	Group (Epithelial)	1	Group (Malignant lymphoma)	2	Group (GIST)	3
Solitary tumor	1		2		1	
Protruded or mass type	2		3		1	
Infiltrative ulcerated type	2		3		3	
Presence of stenosis	1		2		3	
White villi	3		2		3	

1: More likely; 2: Intermediate; 3: Less likely; GIST: Gastrointestinal stromal tumor.

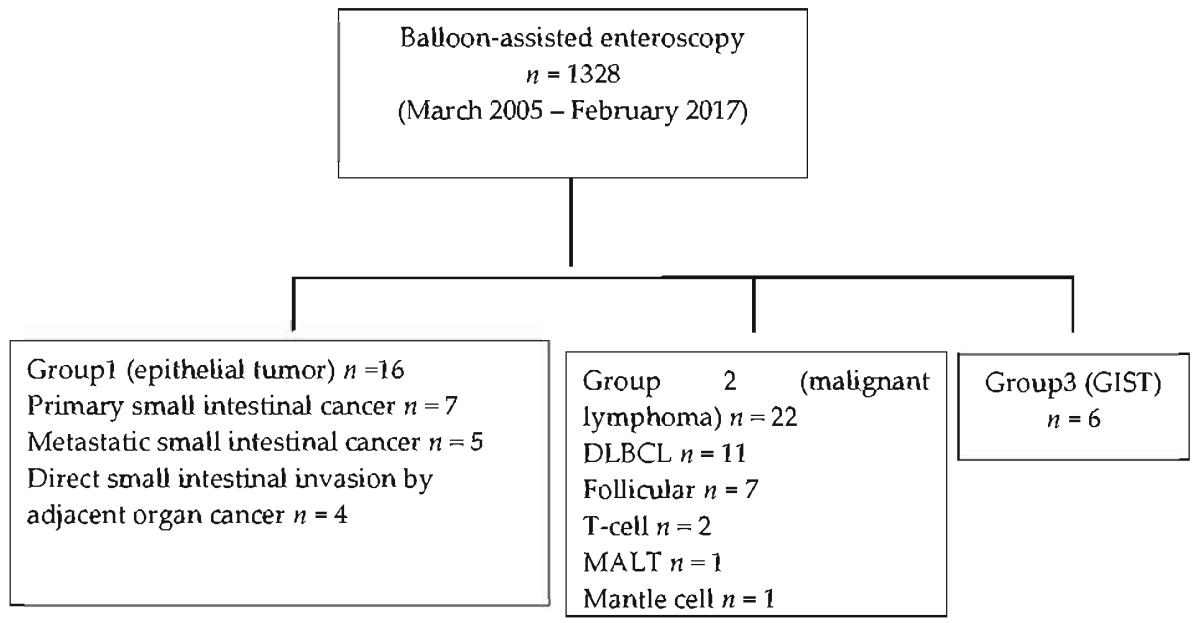


Figure 1 Flow diagram of the patient enrollment. DLBCL: Diffuse large B-cell lymphoma; GIST: Gastrointestinal stromal tumor; MALT: Mucosa-associated lymphoid tissue.

Figure 2 Endoscopic findings for each small intestinal tumor. A: Representative image of an epithelial tumor (Group 1: primary small intestinal cancer). This tumor was solitary and located in the jejunum. The type was infiltrative ulcerated type. This tumor was also associated with stenosis and bleeding; B and C: Representative images of malignant lymphoma (Group 2: diffuse large B-cell lymphoma). These tumors were multiple and located in the jejunum and ileum and appeared as ulcerated masses with raised margins. These tumors also had white villi (arrows) and were not associated with stenosis or bleeding; D: Representative image of a gastrointestinal stromal tumor (Group 3). This tumor was solitary and located in the jejunum and appeared as a protruded mass. This tumor was not associated with stenosis or bleeding.

Figure 3 Endoscopic and pathological findings of the white villi. Representative endoscopic and pathological images of the white villi (Follicular lymphoma). A: White light image with indigo carmine staining shows diffuse white villi in the ileum; B, C: Pathological images are showing the lymphoma cells infiltrating the villi with an intact epithelium. Most of the villi are filled with lymphoma cells, which formed lymphoid follicles (B: Hematoxylin and eosin staining, × 10; C: Immunohistochemical staining for bcl-2 was positive, ×10).

Figure 4 Endoscopic and pathological images of malignant lymphoma without white villi appearance. A, B: Representative endoscopic and pathological images of malignant lymphoma without white villi appearance (Follicular lymphoma) [A: White light image shows enlarged villi with stenosis, without white villi appearance in the ileum (with stenosis); B: Pathological image is showing the lymphoma cells sparsely infiltrating the villi, some lymphoma cells present in the deep mucosa (red arrow), immunohistochemical staining for bcl-2, $\times 10$]; C, D: Representative endoscopic and pathological images of malignant lymphoma without white villi appearance (Mantle cell lymphoma) (C: White light image with indigo carmine staining shows multiple polyposis with ulceration, without white villi appearance in the ileum; D: Pathological image is showing the lymphoma cells infiltrating the mucosa without an intact epithelium, immunohistochemical staining for cyclin D1, $\times 10$).

47540-Review

ORIGINALITY REPORT

6%

SIMILARITY INDEX

PRIMARY SOURCES

1 Arihiro Nakano, Masanao Nakamura, Osamu Watanabe, Takeshi Yamamura et al. "Endoscopic Characteristics, Risk Grade, and Prognostic Prediction in Gastrointestinal Stromal Tumors of the Small Bowel", *Digestion*, 2017 34 words — 1%

[Crossref](#)

2 Shotaro Nakamura, Takayuki Matsumoto. "Gastrointestinal Lymphoma: Recent Advances in Diagnosis and Treatment", *Digestion*, 2013 34 words — 1%

[Crossref](#)

3 www.physoc.org 32 words — 1%

Internet

4 Thomas Aparicio, Aziz Zaanani, Magali Svrcek, Pierre Laurent-Puig et al. "Small bowel adenocarcinoma: Epidemiology, risk factors, diagnosis and treatment", *Digestive and Liver Disease*, 2014 26 words — 1%

[Crossref](#)

EXCLUDE QUOTES ON

EXCLUDE MATCHES < 1%

EXCLUDE BIBLIOGRAPHY ON