

WJO 5th Anniversary Special Issues (4): Hip**Management of femoral neck fractures in the young patient: A critical analysis review**

Thierry Pauyo, Justin Drager, Anthony Albers, Edward J Harvey

Thierry Pauyo, Justin Drager, Anthony Albers, Edward J Harvey, Montreal General Hospital, McGill University Health Center, Department of Orthopaedics, Montreal Quebec H3G 1A4, Canada

Author contributions: Pauyo T, Drager J and Albers A designed manuscript, acquired and analyzed literature and drafted manuscript; Pauyo T and Harvey EJ finalized manuscript; Harvey EJ provided substantial input concerning the conception and design and critically revised the manuscript; all authors provided final approval of the article to be published.

Correspondence to: Edward J Harvey, MD, MSc, FRCSC, McGill University Health Center, Department of Orthopaedics, 1650 Cedar Avenue-Room B5.159.5, Montreal Quebec H3G 1A4, Canada. harvey.ej@gmail.com

Telephone: +1-514-9341934 Fax: +1-514-9348283

Received: December 28, 2013 Revised: April 17, 2014

Accepted: May 29, 2014

Published online: July 18, 2014

Abstract

Femoral neck fractures account for nearly half of all hip fractures with the vast majority occurring in elderly patients after simple falls. Currently there may be sufficient evidence to support the routine use of hip replacement surgery for low demand elderly patients in all but non-displaced and valgus impacted femoral neck fractures. However for the physiologically young patients, preservation of the natural hip anatomy and mechanics is a priority in management because of their high functional demands. The biomechanical challenges of femoral neck fixation and the vulnerability of the femoral head blood supply lead to a high incidence of non-union and osteonecrosis of the femoral head after internal fixation of displaced femoral neck fractures. Anatomic reduction and stable internal fixation are essentials in achieving the goals of treatment in this young patient population. Furthermore, other management variables such as surgical timing, the role of capsulotomy and the choice of implant for fixation remain

controversial. This review will focus both on the demographics and injury profile of the young patient with femoral neck fractures and the current evidence behind the surgical management of these injuries as well as their major secondary complications.

© 2014 Baishideng Publishing Group Inc. All rights reserved.

Key words: Osteonecrosis; Femoral neck fracture; Young patient; Capsulotomy; Surgical timing

Core tip: This critical analysis review provides an overview of the pathophysiology of femoral neck fracture in the young adults. Additionally, it offers recommendations to guide the orthopedic surgeon in the management of femoral neck fracture and its most common surgical complications. Few studies have reviewed this controversial subject and provided treatment guidelines.

Pauyo T, Drager J, Albers A, Harvey EJ. Management of femoral neck fractures in the young patient: A critical analysis review. *World J Orthop* 2014; 5(3): 204-217 Available from: URL: <http://www.wjgnet.com/2218-5836/full/v5/i3/204.htm> DOI: <http://dx.doi.org/10.5312/wjo.v5.i3.204>

INTRODUCTION

Femoral neck fractures account for nearly half of all hip fractures with the vast majority occurring in elderly patients after simple falls^[1]. Currently there may be sufficient evidence to support the routine use of hip replacement surgery for low demand elderly patients in all but non-displaced and valgus impacted femoral neck fractures. This is based on a multitude of randomized controlled trials documenting improved short and long-term hip function and lower re-operation rates with hip

arthroplasty as compared to internal fixation in elderly adults^[2-5]. Furthermore, early weight bearing protocols post-arthroplasty minimizes complications of prolonged inactivity^[6].

For the non-elderly patient with good bone quality, preservation of the natural hip anatomy and mechanics is a priority as their high functional demands and young age preclude their candidacy for replacement procedures^[7]. While only 3%-10% of these fractures occur in younger adults, the major differences in physiology, injury characteristics and activity level necessitate a dedicated treatment pathway^[8,9]. However, the biomechanical challenges of femoral neck fixation and the vulnerability of the femoral head blood supply lead to a high incidence of non-union and osteonecrosis of the femoral head (ONFH) after internal fixation of displaced femoral neck fractures^[10-15]. These complications are highly symptomatic in active patients leading to salvage procedures with significant failure rates.

Undisputedly, anatomic reduction and stable internal fixation are essentials for achieving the goals of treatment in this young population allowing preservation of the femoral head while minimizing rates of non-union and osteonecrosis^[16]. Other management variables such as surgical timing, the role of capsulotomy and the choice of implant remain controversial. This review will focus both on the demographics and injury profile of the young patient with a femoral neck fracture and the current evidence behind the management of these injuries and their secondary complications.

Consideration of physiological age

The age range describing a young patient is most often between skeletal maturity and the age of fifty^[8,9,12-15,17]. More recently, patients up to 65 years have been considered within this definition^[6,18,19]. The majority of surgeons prefer to treat young patients (< 60 years) and elderly patients with non-displaced fractures with internal fixation and favor arthroplasty for displaced fractures in patients above 80 years^[20]. However, for patients outside these categories, the treatment approach is variable. For the "young-elderly" population, chronologic age becomes less important and establishing a patient's physiologic age becomes the first step in management^[21]. Several variables have been used to characterize the physiologic age of a patient; pre-injury activity level, medical co-morbidities and bone quality. In addition to chronological age these variables dictate the goals of management for these two populations and have an impact on the outcomes of surgical treatments. Bone quality influences the success of internal fixation of femoral neck fractures. Cadaveric studies of femoral neck fixation have shown a positive correlation between bone density and achieved fixation stability^[22,23]. In a review of over one thousand patients with femoral neck fractures, Parker *et al.* found the incidence of non-union to be age dependent with a rate of 5.9% in patients younger than 40 years compared to 24.9% for patients in their 70s. In addition to non-union,

failure of osteoporotic bone around multiple screw fixation leads to increased screw sliding and shortening of the femoral neck. Femoral neck shortening of more than 5 mm has been correlated with decreased functional outcomes and an increased incidence of requiring walking assistance^[24].

Overall, secondary surgical procedures are significantly more common in elderly patients treated with internal fixation compared to those treated with arthroplasty^[25]. Although risks of non-union and osteonecrosis are significant in the younger patient, arthroplasty is avoided as first line treatment. Highly active patients have increased failure rates of hip prosthetics and less favorable functional outcomes compared to their elderly counterparts^[7,26]. Robinson *et al.*^[19] developed a scoring system used to categorize patients between the ages of 65-85 years within the two physiological age categories. Five variables were quantified: mobility, patient living conditions, bone quality, cognitive status and medical condition. Patients with a high "physiologic status score" underwent internal fixation and patients with a lower score underwent arthroplasty. Forty two percent of patients had scores in the arthroplasty range. Observed revision rates at 21 mo were of 5% for internal fixation group and 2% for the arthroplasty group. Although follow-up observation time was short these rates were significantly lower than those previously published. This work imparts the necessity of appropriate patient selection based on physiological age.

Demographics of the young femoral neck fracture patient

The literature suggests that femoral neck fractures in young adults are most often a result of high-energy trauma such as motor vehicle collisions^[14,27]. Patients often present with poly-traumatic injuries such as other fractures or head, chest and abdominal trauma^[28]. While this is true for patients with dense bone, more recent work demonstrates femoral neck fractures in chronologically young patients occur from low energy trauma with a higher than expected frequency^[13,29,30]. A study conducted by Robinson *et al.*^[8] examined ninety-five patients with both intra and extra-capsular hip fractures under the age of 50 over a five-year period. They identified two demographics within this population; a male predominant group between the ages of 20 and 40 years who sustained high-energy injuries, and a larger group between the ages of 40 and 50 years who sustained fractures after falls. The majority of patients within the latter group had long standing medical conditions and a high prevalence of alcoholism. This demonstrates that there are two main reasons for femoral neck fractures in chronologically young adults, significant trauma in healthy patients or comparatively low energy trauma in patients with predisposing diseases, alcoholism or early age related bone fragility. A low threshold for referral to specialist services for analysis of bone marrow density and/or treatment of osteoporosis should be observed in young patients with

femoral neck fractures.

Anatomy

Femoral head vascularity is at risk after femoral neck fractures because the vascular supply is intra-capsular. The most common hypotheses of causes for femoral head ischemia after femoral neck fracture are direct disruption or distortion of the intra-capsular arteries during the initial femoral neck fracture, compression secondary to elevated intra-capsular pressure due to fracture hematoma, pre-operative traction and quality of the surgical reduction and its ability to restore blood flow^[31-41].

Blood supply to the femoral head comes from three main sources, the medial femoral circumflex artery (MFCA), the lateral femoral circumflex artery (LFCA) and the obturator artery. The majority of the blood supply to the femoral head, more specifically to the vital superior-lateral weight-bearing portion, comes from the lateral epiphyseal artery, a branch of the MFCA. This artery courses up the posterior-superior aspect of the femoral neck where it is prone to damage during femoral neck fracture fragment displacement. The second largest contributor to femoral head blood supply is the LFCA whose ascending branch gives rise to the inferior metaphyseal artery supplying the anterior-inferior aspect of the femoral head. Finally, the smallest and most variable contributor to blood supply in the adult femoral head is *via* the obturator artery which enters the head via the ligamentum teres^[42-46].

INITIAL EVALUATION

The mechanism of injury is important. As previously discussed, a large majority of young patients with femoral neck fractures present after high-energy trauma. If a young patient with femoral neck fracture presents after a low-energy trauma or no clear history of trauma, a more in depth history should be carried out. Low-energy fracture can be due to underlying osteoporosis^[29,47], stress fracture or pathologic bone. One should inquire specifically about risk factors for osteoporosis, previous pain about the hip both at rest or with activity and constitutional symptoms including fever, weight loss and night sweats.

In a poly-trauma presentation, Advance Trauma Life Support (ATLS) protocol is promptly initiated; fixation of the femoral neck fracture is dealt with following the appropriate treatment algorithm based on priority of the injuries. Nevertheless, in isolated or in poly-trauma situations, the patient needs to be medically optimized prior to surgery and evaluated by an anesthesiologist.

Physical examination findings in patients of all ages with femoral neck fractures are similar. Classically, the affected limb is painful, especially with movement, shortened, fixed and externally rotated. However, the diagnosis of femoral neck fracture in young patients can be more elusive. With a significant proportion of patients presenting after high-energy injuries and often in poly-

traumatized patients, these fractures can easily be overlooked^[28]. In the presence of a femoral shaft fracture, an ipsilateral femoral neck fracture will occur up to 9% of the time^[48]. In this clinical setting, the diagnosis is missed approximately 30% of the time^[49,50]. Most of these fractures (between 25% and 60%) are non-displaced at initial presentation^[51]. Because of the morbidity associated with osteonecrosis, a high index of suspicion should be entertained when evaluating the poly-traumatized patient. Prompt recognition of femoral neck injuries cannot be underemphasized as timing to surgical intervention may affect outcomes^[6].

IMAGING AND CLASSIFICATION

Regardless of the mechanism of injury, antero-posterior (AP) pelvis, AP and lateral plain radiographs of the affected hip and entire femur should be obtained. In addition, traction-internal rotation radiographs may allow for a better interpretation of fracture pattern^[52]. Up to 2%-10% of femoral neck fractures may not be clearly visible on standard radiographs and computed tomography (CT) can aid in the diagnosis^[53]. In cases of significant trauma where an abdomino-pelvic CT scan is required, it is recommended to extend imaging to the level of the lesser trochanter in order to fully evaluate the femoral neck. This enables identification of occult injuries, especially in the obtunded patient where a reliable physical examination is difficult. Recent studies have found CT scan to be as effective as MRI in detecting these fractures and reducing the chance of a missed injury^[54].

Several characteristics identified on imaging have been shown to influence the biomechanical stability of the fracture. First, the verticality of the fracture line in the coronal plane should be assessed. Pauwels first recognized the significance of high angle fractures in the 1930s. He established a descriptive classification scheme that helps determine fracture stability based on the "Pauwels angle". A femoral neck fracture line < 30 degrees from the horizontal plane is Pauwels Type I, fractures with an angle between 30 and 50 degrees is Pauwels Type II, and an angle of > 50 degrees categorizes a Pauwels Type III fracture. Increased verticality of the fracture decreases the load shared through the fracture fragments resulting in a biomechanically unstable pattern, susceptible to the development of mal-unions, non-unions and osteonecrosis^[6,52,55-57].

Another well-known and widely used classification system is that of Garden, originally published in 1961^[58] (Figure 1). Low inter and intra-rater reliability has led to it being mostly used for femoral neck fractures in the elderly population where the classification can be simplified to non-displaced (Garden I or II) vs displaced (Garden III or IV) in order to dictate appropriate management^[59-61]. Secondly, special consideration should also be given to fractures with posterior neck comminution. Several studies have indicated this to be a poor prognostic factor after internal fixation and correlate the comminution with

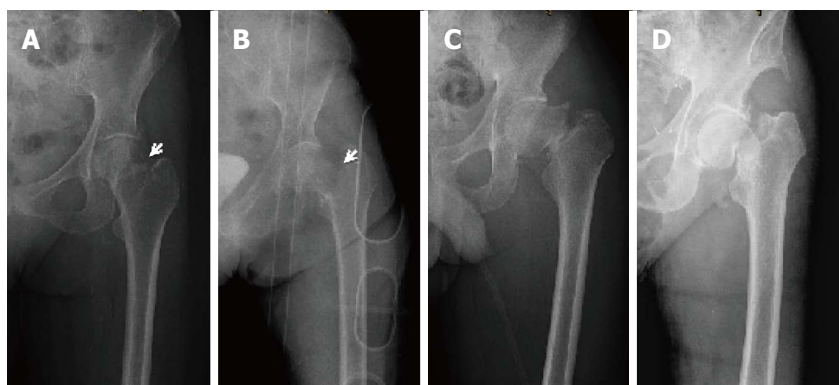


Figure 1 Garden classification. A: Incomplete fracture of the femoral neck with valgus impaction. Note the radiopaque overlap of the femoral neck and head; B: Displaced complete fracture of the femoral neck; C: Less than 50% displacement of a complete fracture of the femoral neck; D: Complete fracture of the femoral neck with complete displacement.

fracture severity and instability^[62-64].

PRINCIPLES OF MANAGEMENT

Non-operative treatment of femoral neck fractures in younger patients has a very limited role and is only reserved for the sickest of patients whose surgical risks negate any benefit of fixation. Moreover, operative management is recommended for non-displaced impacted fractures. In a prospective study of three hundred and twelve patients with impacted femoral neck fracture (Garden I - II), Raatmakers *et al*^[65] found that 5% of healthy patient below age 70 had secondary displacement and only 87% of patients in this age group achieved union. Considering the pre-injury activity level of most young patients, surgical management is recommended, as union rates are higher with operative treatment^[17,62,66]. Goals of the surgical management of femoral neck fractures in young adult patients are three-fold: (1) Return to pre-injury level of function; (2) Achieve an anatomic reduction of the fracture to preserve the blood supply and effectively prevent ONFH; and (3) Provide a stable fixation while preserving bone stock to achieve union.

PRE-OPERATIVE CONSIDERATIONS

Surgical timing of displaced and non-displaced fracture

The consensus for time to surgery following femoral neck fracture in the young patient is still a matter of debate. Minimally or non-displaced fractures are classically treated on an urgent basis and displaced fractures are managed on an emergent basis with the aim to regain and preserve blood flow to the femoral head. The difficulty with basing this decision on an X-ray finding is that the single time radiographs may not represent ongoing instability or displacement. Studies have shown that early fixation decreases osteonecrosis and increases functional outcome^[14,67]. In a retrospective study, Jain *et al*^[68] looked at thirty-six young patients with femoral neck fractures. Patients treated within twelve hours of injury had a decreased rate of osteonecrosis as compared to the

delayed fixation group. However, there was no difference in functional outcomes between the early and delayed fixation group. In contrast, other studies have found no difference in osteonecrosis rates between early and delayed time to fixation^[17,69]. Razik *et al*^[70] retrospectively analyzed ninety-two patients with femoral neck fractures and found no difference in rates of osteonecrosis when comparing treatment within 6 h post-injury, and delayed treatment 48 h post-injury. They found that the rate of osteonecrosis was related to the type of fixation, which may be indicative of surgeon treatment bias. The conflicting results in the literature are indicative of the wide amount of variance in the studies, which did not uniformly control for confounding variables such as the quality or the type of reduction and fixation^[71]. Given the controversial evidence and considering the impetus to prevent osteonecrosis and improve functional outcome, we recommend treating displaced femoral neck fracture on an urgent basis.

Anesthesia consideration

There is little debate regarding the benefits of intra-operative regional anesthesia compared to general anesthesia in young healthy adults; however special circumstances including extreme hypovolemia or coagulopathy associated with poly-trauma, or patient specific factors including respiratory or cardiovascular comorbidities might warrant a particular anesthetic approach. A meta-analysis of randomized controlled trial of hip fractures in all aged group showed a decrease in incidence of deep vein thrombosis and reduction in fatal pulmonary embolism, with regional anesthesia^[72]. General anesthesia was associated with a reduction in the length of the operation. A lumbar plexus block may be the post-operative modality of choice for analgesia of the hip as it reliably blocks the lateral femoral cutaneous, femoral and obturator nerves^[73].

SURGICAL MANAGEMENT

Open vs closed reduction

The decision between attempting an open or closed

approach for fracture reduction is the first step when attempting primary fixation. Most authors agree on performing a closed reduction and internal fixation for management of non-displaced femoral neck fractures (Garden I - II) given low rates of ONFH and non-union^[17,74]. However there is considerable debate between the two strategies for reduction of displaced fractures (Garden III - IV). Obtaining an anatomic reduction is paramount in the young patient as a poorly reduced fracture is a major risk factor for non-union and ONFH^[62,75,76]. Some authors argue that closed reduction can achieve anatomic reduction with intra-operative fluoroscopy; they suggest that this approach decreases cost, is less invasive and saves operating time^[77]. Care should be taken while performing the close reduction, as multiples attempts are associated with an increased risk of ONFH^[34,78]. Others support the need for an open reduction to facilitate direct visualization for anatomic reduction, and with the same token, provide relief of a possible intra-capsular tamponade^[66]. Traditionally, there are two different surgical approaches for the internal fixation of femoral neck fractures; the Watson-Jones (antero-lateral) and the Modified Smith-Peterson (anterior)^[77,79]. There is no gold standard as to proceed with closed or open reduction for displaced femoral neck fracture in young adults as long as anatomic reduction is achieved.

Closed reduction can be attempted by adequate sedation and relaxation of muscle tone. Leadbetter first described in 1939, the maneuver to reduce of femoral neck fractures^[80]. The affected leg is fixed to 45° with slight abduction and then extended with internal rotation while longitudinal traction is applied. The reduction is verified with fluoroscopy in the AP and lateral view of the hip to verify the anatomic reduction. The quality of reduction can be ascertained using Garden's alignment index, which evaluates the angle of the compressive trabeculae as compared to the femoral shaft on both AP and lateral hip radiographs. Anatomic reduction is achieved with an angle of 160° on the AP, and 180° on the lateral view. Varus angulation of less than 160° on the AP view and posterior angulation of more than 5° on the lateral view indicate an unsatisfactory reduction^[62,77].

Hematoma decompression

Another topic of controversy in treating femoral neck fractures in young patients is the role of capsulotomy for hematoma decompression. The theoretical goal of capsulotomy is to relieve the tamponading effect of the developed intra-capsular hematoma and subsequently increase blood flow to the femoral head. There is good evidence in the literature correlating hemarthrosis following femoral neck fracture and increased intra-articular joint pressure^[36].

In an interventional study, Beck *et al.*^[81] injected saline into intact intra-capsular space of eleven patients before having surgical dislocations and subsequently measured blood flow to the femoral head with laser Doppler flowmetry. The measurable blood flow to the femoral head

disappeared with increased pressure (average 58 mmHg) and the blood flow returned once the saline was re-aspirated. In contrast, in a prospective study involving thirty-four patients with femoral neck fractures, Maruenda *et al.*^[35] found no correlation between increased intra-capsular pressure and femoral head perfusion. Interestingly they also showed no difference in intra-capsular pressure between non-displaced and displaced fractures. Others have suggested higher pressures are found in non-displaced fractures^[34]. Disruption of the hip capsule during fracture fragment displacement is thought to be responsible for the decreasing intra-capsular pressures.

Numerous clinical studies have shown a reduction in intra-capsular pressure with capsulotomy and a resulting improvement femoral head blood flow^[33,38-40]. However there are no clinical data documenting improved outcomes with capsulotomy. In their retrospective study of ninety two young patients with femoral fractures, Upadhyay *et al.*^[62] found no difference in the rate of osteonecrosis with patients treated with open (capsulotomy) or closed reduction (no capsulotomy) and internal fixation. In the above-mentioned study by Maruenda *et al.*^[35] five out of the six patients that developed osteonecrosis had pre-operative intra-capsular pressures below diastolic pressure. They concluded what many presently think: high-energy trauma and the initial fracture displacement probably play a more significant role than intra-capsular tamponade in the development of osteonecrosis.

Some surgeons perform capsulotomy while proceeding with their open procedures while others opt for fluoroscopic guided hip capsulotomy; this latter technique has been previously found to be safe and effective at decreasing intra-articular pressure^[82]. Nevertheless, given the current evidence, we do not recommend the routine use of capsulotomy for femoral neck fractures.

Choice of construct

There are several biomechanical constructs available for the fixation of femoral neck fractures and knowing when and how to position the implant is paramount to attain a stable fixation. Compression screws (CS) and fixed-angle dynamic implants, or a combination of both, promote union during weight bearing by allowing the fracture fragments to slide along the implant while being axially loaded^[71]. Fixed-angle and length stable implants, such as blade plates, maintain intraoperative reduction by providing a rigid construct^[71]. Currently, hemiarthroplasty or total hip arthroplasty are not used as the primary surgery in young patients. Total hip arthroplasty and valgus osteotomy are used as salvage operations in case of failure of fixation. There is still a debate on the optimal method of fixation for promoting union and preventing ONFH in young patients^[70]. This is mainly because most opinions on fixation in this population are extrapolated from studies in elderly osteoporotic patients.

Multiples compressive screws: The use of the multiple compressive screws has been advocated for Garden type

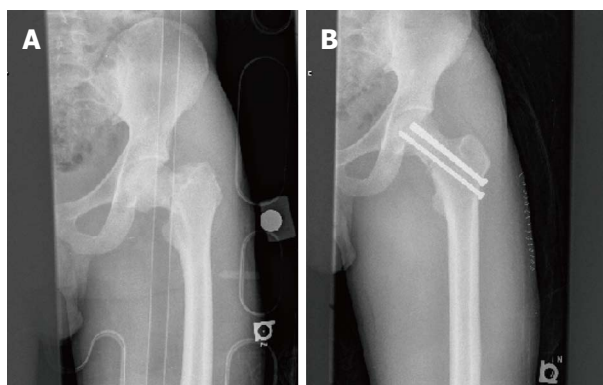


Figure 2 Cannulated screw fixation. A: Anterior posterior view; B: Anterior posterior view with cannulated screw.

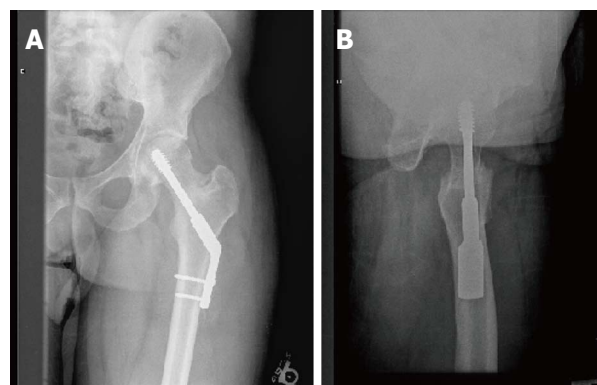


Figure 3 Dynamic hip screw fixation. A: Anterior posterior view with 2 holes 135° dynamic hip screw; B: Lateral view of 2 holes 135° dynamic hip screw.

I - II in attaining union^[83]. In a prospective randomized controlled trial of patients allocated to CS or dynamic hip screw (DHS) with non-displaced or minimally displaced femoral neck fracture, Watson *et al*^[84] found no difference in union rate, ONFH or functional outcomes between the groups. Numerous studies have looked at biomechanical variations of this construct including the number and placement of the screws or variability in the properties of the screws themselves such as the length of the threads^[85]. For instance parallel screws have been shown to be superior construct than convergent screws in maintaining stability reduction^[86]. Some authors advocate the use of a fourth screw in cases of fractures with posterior comminution^[6]. However, optimal stiffness can be achieved with a three-screw configuration^[16]. Three parallel screws placed perpendicular to the fracture line in an inverted triangle with the most inferior screw placed on the medial aspect of the distal femoral neck provides the ideal stability and compression at the fracture site^[6] (Figure 2).

Fixed angle implants: The dynamic compressive screw has been advocated as a more stable construct than compressive screws for high shear angle neck fractures (Pauwels type III)^[86] (Figure 3). Addition of a derotational screw placed in the cranial part of the femoral neck superior to the dynamic hip screw can improve the rotational stability of the construct (Figure 4). In a biomechanical study comparing four commonly used constructs for Pauwels type III fractures, Bonnaire *et al*^[86] found the DHS with derotational screw to be more load stable than compressive screws, a fixed-angle plate or a simple DHS construct. However, for more stable fracture patterns this screw may be of little benefit. Recently Makki *et al*^[87] showed no benefit in union rate or development of ONFH in patients with Garden I - II femoral neck fractures treated with a DHS alone or with a DHS with a derotational screw^[87]. Furthermore, in their retrospective study of ninety-two young patients with femoral neck fractures, Razik *et al*^[70] found that DHS alone or DHS supplemented with a derotational screw had significantly less osteonecrosis for Garden III-IV fractures.

In a cadaveric study, Aminian *et al*^[88] compared the stability of DHS, CS, dynamic condylar screw and a proximal femoral locking plate (PFLP) for Pauwels type III femoral neck fracture. PFLP was the most stable for this fracture pattern, followed by the dynamic condylar screw, the DHS and CS. Currently, no clinical studies directly compare proximal femoral locking plate with DHS and/or DHS with derotational screw. We recommend the treatment of Garden I - II fracture with CS and Garden III - IV with a DHS and the addition of a derotational screw for Pauwels type III fractures.

Replacement arthroplasty: Replacement arthroplasty is not considered a first line treatment in young patients as bone stock should be preserved and the potential complications of replacement arthroplasty avoided. The major early complications are dislocations for total hip arthroplasty and acetabular erosion for hemiarthroplasty^[89]. In the elderly patients, short-term follow up has shown better functional outcome for total hip arthroplasty over hemiarthroplasty^[90,91]. Studies have shown that internal fixation has higher re-operation rates and that both hemiarthroplasty and internal fixation have comparable functional outcomes^[92]. To this date, there are no level- I studies comparing arthroplasty to internal fixation in the young adult.

SUBACUTE PRESENTATION AND MANAGEMENT

The term “neglected” femoral neck fracture has been described as a subacute presentation of at least 30 d delay after initial injury^[93]. This pathology is more prevalent in developing countries where urgent orthopedic care is not readily available^[93]. There is no consensus on the treatment of this pathology and different surgical managements have been described in treating non-union of femoral neck fractures in young adults^[94]. Operations such as internal fixation with valgus intertrochanteric osteotomy and internal fixation with vascularized muscle pedicle bone grafting or non-vascularized bone grafting

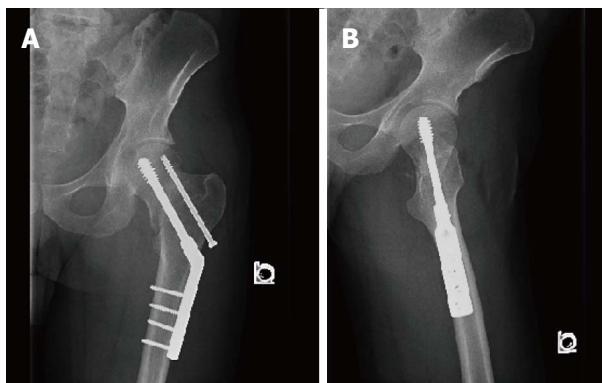


Figure 4 Dynamic hip screw with derotation screw. A: Anterior posterior view pre-operative of 4 holes 145° dynamic hip screw; B: Lateral view pre-operative of 4 holes 145° dynamic hip screw.

are frequently used to achieve union^[95]. Valgus osteotomy and free fibular bone graft has had better reported outcomes with osteonecrosis rates ranging from 0-17% and non-union from 0%-15%^[93].

POST-OPERATIVE CONSIDERATIONS

The postoperative recommendations are geared to lower the incidence of wound infection, deep vein thrombosis (DVT), and pulmonary embolism as well as to encourage mobilization. An antibiotic regimen with a first generation cephalosporin is indicated for 24 h^[96]. The patients should be placed on DVT prophylaxis for thirty days with a pharmacologic agent such as low molecular weight heparin^[97]. Physiotherapy should not be delayed and patients should be encouraged to mobilize with no restriction on range of motion of the hip. The patients are usually subject to toe-touch weight bearing with a walker or crutches for 12 wk until fracture is healed. They are then progressed to full weight bearing as tolerated. The patient should follow-up in 10-14 d post-operatively to assess the wound for infection and to assess the stability of the fixation construct. Follow up visits are indicated at six weeks and three months to assess for clinical and radiologic signs of non-union, osteonecrosis and hardware failure.

COMPLICATIONS

Femoral neck fractures in the young are not known to be associated with a high mortality rate as they are in the elderly population^[28]. However young patients suffer great morbidity from the injury due to high rates of osteonecrosis and tolerable yet significant delays in union. In this section we present a brief overview of these two complications with an emphasis on their management.

Osteonecrosis of the femoral head

Osteonecrosis of the femoral head, previously referred to as avascular necrosis, remains one of the greatest concerns in the young patient with a femoral neck fracture. Despite our increasing understanding of the pathophysiology

surrounding post-traumatic osteonecrosis, the incidence has been documented to be as high as 86% in young adults post femoral neck fracture^[6]. The development of osteonecrosis has been correlated with multiple factors including age at time of injury (older patients develop less osteonecrosis), the degree of displacement, presence of posterior comminution, verticality of the fracture line, quality of reduction, and implant removal^[25,55-58,98]. Osteonecrosis of the femoral head can present anywhere between 6 mo and many years after the initial injury, however, most cases will present within 2 years^[99,100]. For this reason, patients should be followed at least for two years post-operatively looking for signs of osteonecrosis, both clinically and radiologically.

Patients will characteristically present complaining of pain localized in the groin, sometimes radiating to the anterior-medial thigh and/or ipsilateral knee. The pain is usually described as deep, throbbing and is exacerbated by weight-bearing activities or at night. There exist many different imaging modalities for diagnosing ONFH however plain radiographs and MRI remain the most useful^[101-104]. To date, there is no universally accepted classification. Ficat and Arlet, one of sixteen different systems existing in the literature, is the most commonly quoted^[105,106].

Surgical management of osteonecrosis of the femoral head:

Treatment of post-traumatic osteonecrosis depends on multiple factors including patient age, stage of disease, level of activity and symptoms. In the majority of cases, once osteonecrosis develops and particularly if it is symptomatic, it will eventually progress to subchondral collapse and secondary osteoarthritis^[107]. Once this occurs; the only definitive option remaining is total hip arthroplasty. However, questions remain surrounding the young patient with pre-collapse and early post-collapse ONFH. Multiple joint salvaging techniques have been proposed for patients in whom revision arthroplasty within the patient's lifetime is a foreseeable concern.

Core decompression has been almost exclusively studied in the treatment of idiopathic ONFH. It is the most common method of treatment for pre-collapsed stages of ONFH^[108]. It is theorized to work by reducing elevated intra-osseous pressure, improving venous outflow and thereby restoring vascular inflow. Despite early studies showing improvement for all stages of disease, a recent review of four prospective studies with validated outcome scores and a minimum two year follow up showed only minimally improved outcomes^[109]. In all four studies, better results were found in pre-collapse and smaller femoral head lesions^[110]. Overall, core decompression is a cost-effective choice over observation and its use is recommended as a first line treatment for pre-collapse disease^[100].

Various methods of non-vascularized bone grafting have also been used in the treatment of ONFH. Bone grafting has been recommended when there is less than 2 mm of subchondral bone depression, when under 30% of the femoral head is involved and when core

decompression fails^[111]. It is also been used in conjunction with other methods, such as core decompression. Post-traumatic osteonecrosis tends to create large lesions and decompression alone is thought to be insufficient to completely prevent collapse^[100,112-118]. Without good reproducible evidence, evaluation of these techniques in long-term prospective studies is necessary before they can be recommended for routine use.

Vascularized bone grafting using either a local muscle pedicle iliac crest graft or a free vascularized fibular graft have been described for young patients with femoral neck non-union or ONFH. Commonly cited indications from studies of non-traumatic ONFH include no evidence of bony collapse or articular collapse of less than 3-mm in lesions involving less than 50% of the femoral head^[119]. The main pitfalls of vascular grafting are donor site morbidity and advanced microvascular surgical techniques^[120]. Although less predictable for larger lesions typical of post-traumatic ONFH, when following indications, vascularized bone grafting can be effective if used early and should be considered for improving hip function and delaying disease progression^[119-125].

For patients with more advanced ONFH, usually with post-collapse disease, proximal femoral osteotomies have been proposed with the premise of moving the lesion away from the weight bearing zone. There is currently no general consensus on indications for proximal femoral osteotomies with some authors obtaining good results while others observed high failure rates^[126-134]. Other concerns surrounding these procedures are poorer outcomes with more challenging subsequent total hip arthroplasty, with increased rates of blood loss, operative time, femoral shaft fracture and component loosening^[135,136]. We believe that in the right hands osteotomies can lead to reproducible results however without generalizable results one should proceed cautiously when considering proximal femoral osteotomies for treatment of ONFH.

Non-union

The incidence of non-union after femoral neck fixation has been reported to be between 10% to 33%^[137]. Initial fracture displacement, quality of reduction and increasing patient age correlate with a higher risk of non-union^[16,138-140]. A recent study evaluating the survivorship of the hip in patients younger than 50 years after femoral neck fractures, reported that 8% of patients were diagnosed with non-union and 23% with evidence of osteonecrosis^[17]. Moreover in this series, patients with anatomic reductions had only a 4% rate of aseptic nonunion.

In comparison to osteonecrosis of the femoral head, patients with non-unions present with symptoms earlier, often several months after internal fixation. Most commonly patients describe a history of persistent pain, typically localized to the groin and over the anterolateral aspect of the injured leg, aggravated by weight-bearing^[141]. Three to six months should have elapsed before a nonunion may be diagnosed but evidence of failure of fixation can allow the diagnosis to be made sooner^[141].

Plain radiographs may demonstrate a lucent fracture zone, osteopenia or bone loss, or signs of instability of the implant such as changes in screw position or backing out of the screws. When plain radiography is equivocal, computed tomography can help determine whether bony union has occurred^[140].

Once non-union has been diagnosed, several factors will decide whether salvage of the femoral head is a viable revision option, including the patient's physiological age, femoral head viability, the amount of femoral neck resorption, and the duration of the nonunion^[140]. Four options are available for treatment: fixation with new hardware, angulation osteotomy, prosthetic replacement and arthrodesis. In the physiologically young patient salvage the femoral head and preservation the hip joint is preferable. This can be achieved by either improving the mechanical environment to favor healing by attempting valgus-producing osteotomies or improving the biologic milieu at the non-union site with bone graft^[140].

In young patients femoral neck non-union is thought to be more often a result of mechanical factors over biological ones. Varus displacement of the femoral head leads impaired blood supply to the fracture and femoral head resulting in non-union and avascular necrosis^[142]. Two features commonly seen in young patients have been identified as predicting higher incidences of fixation failure and non-union; posterior wall comminution and high shear angled fractures (Pauwels Type III)^[62,143-147]. With a vertical fracture line, the calcar does not offer enough support to prevent the femoral head from shearing and displacing into varus^[74]. It is unclear whether posterior comminution indicates a more extensive soft tissue and vascular injury or whether this pattern compromises stability after fixation^[141].

Valgus osteotomy reorients the fracture so that its plane is nearly perpendicular to the force across the hip joint. This converts the shearing forces parallel to the nonunion to compressive forces to stabilize the non-union and promote healing. This procedure also restores femoral length improving the abductor mechanics by restoring the abductor moment arm^[140]. As much as 2 cm of length can be gained in some instances^[148]. Rotational and angular deformities can also be corrected at the same time. The disadvantage of this osteotomy as a salvage procedure is that the valgus orientation of the proximal femur increases contact pressures on the femoral head potentially leading to degenerative disease or progression of osteonecrosis. Although there are no concrete contraindications for this procedure, Varghese *et al.*^[149] has demonstrated that a decreased preoperative femoral neck bone stock was a risk factor for non-union after valgus osteotomy.

Several published series reporting on the outcomes of valgus-producing proximal femoral osteotomies for the treatment of femoral non-union have demonstrated positive results. Marti *et al.*^[150] reported a union rate of 86% after osteotomy in 50 patients with femoral neck non-unions with a average time to union of 4 mo. Mean

postoperative Harris Hip Score was 91 points in reviewed patients. Although 22 patients had radiographic evidence of osteonecrosis at the time of osteotomy only three of these patients showed progressive collapse of the femoral head that eventually required hip replacement surgery. Four other patients required replacement surgery for persistent non-union or hardware failure. Ballmer *et al.*^[151] reported on a series of 17 patients treated with valgus osteotomies with a total union rate of 88%. Three patients required revision fixation but eventually healed. Three patients had progressive osteonecrosis and required hip arthroplasty. Excellent functional results were reported in 11 of the 17 patients. Some authors have recently advocated sliding hip screws for the same purpose based on favorable outcomes and technical ease associated with this implant^[152,153]. We recommend the use of valgus intertrochanteric osteotomy for the treatment of aseptic non-union after femoral neck fracture fixation.

Autogenous bone grafting is used in an attempt to improve the biologic milieu at the nonunion site. This can be done using non-vascularized, free vascularized or muscle pedicle-type grafts^[154-157]. Rarely are bone grafting procedures undertaken for isolated femoral non-unions, but are indicated more so when concomitant ONFH is present. There are no clear indications for the use of grafting techniques for femoral neck non-union, however these procedures should be considered when there is considerable loss of bone stock or non-unions are present in well-aligned fractures with low shear angles.

RECOMMENDATIONS

The role of conservative management in young patients with femoral neck fracture is limited to patients who are medically unfit; we recommend treating displaced femoral neck fracture on an urgent basis; we do not recommend the routine use of capsulotomy for femoral neck fractures given the lack of evidence to support the development of osteonecrosis from intracapsular hematoma; we recommend the treatment of Garden I - II fracture with compressive screws and Garden III-IV with a dynamic hip screw and the addition of a derotational screw for Pauwels type III; we recommend core decompression for pre-collapse osteonecrosis of the femoral head; we recommend the use of valgus intertrochanteric osteotomy with or without bone grafting for the treatment of aseptic non-union after femoral neck fracture fixation.

REFERENCES

- 1 **Karagas MR**, Lu-Yao GL, Barrett JA, Beach ML, Baron JA. Heterogeneity of hip fracture: age, race, sex, and geographic patterns of femoral neck and trochanteric fractures among the US elderly. *Am J Epidemiol* 1996; **143**: 677-682 [PMID: 8651229 DOI: 10.1093/oxfordjournals.aje.a008800]
- 2 **Blomfeldt R**, Törnkvist H, Ponzer S, Söderqvist A, Tidermark J. Comparison of internal fixation with total hip replacement for displaced femoral neck fractures. Randomized, controlled trial performed at four years. *J Bone Joint Surg Am* 2005; **87**: 1680-1688 [PMID: 16085605 DOI: 10.2106/

- JBJS.D.02655]
- 3 **Rogmark C**, Carlsson A, Johnell O, Sernbo I. A prospective randomised trial of internal fixation versus arthroplasty for displaced fractures of the neck of the femur. Functional outcome for 450 patients at two years. *J Bone Joint Surg Br* 2002; **84**: 183-188 [PMID: 11922358 DOI: 10.1302/0301-620x.84b2.11923]
- 4 **Tidermark J**, Ponzer S, Svensson O, Söderqvist A, Törnkvist H. Internal fixation compared with total hip replacement for displaced femoral neck fractures in the elderly. A randomised, controlled trial. *J Bone Joint Surg Br* 2003; **85**: 380-388 [PMID: 12729114 DOI: 10.1302/0301-620x.85b3.13609]
- 5 **Chammout GK**, Mukka SS, Carlsson T, Neander GF, Stark AW, Skoldenberg OG. Total hip replacement versus open reduction and internal fixation of displaced femoral neck fractures: a randomized long-term follow-up study. *J Bone Joint Surg Am* 2012; **94**: 1921-1928 [PMID: 23014835 DOI: 10.2106/JBJS.K.01615]
- 6 **Ly TV**, Swiontkowski MF. Treatment of femoral neck fractures in young adults. *J Bone Joint Surg Am* 2008; **90**: 2254-2266 [PMID: 18829925 DOI: 10.4103/0019-5413.38574]
- 7 **Girard J**, Glorion C, Bonnomet F, Fron D, Migaud H. Risk factors for revision of hip arthroplasties in patients younger than 30 years. *Clin Orthop Relat Res* 2011; **469**: 1141-1147 [PMID: 21086195 DOI: 10.1007/s11999-010-1669-x]
- 8 **Robinson CM**, Court-Brown CM, McQueen MM, Christie J. Hip fractures in adults younger than 50 years of age. Epidemiology and results. *Clin Orthop Relat Res* 1995; **(312)**: 238-246 [PMID: 7634609]
- 9 **Gerber C**, Strehle J, Ganz R. The treatment of fractures of the femoral neck. *Clin Orthop Relat Res* 1993; **(292)**: 77-86 [PMID: 8519139 DOI: 10.1097/00003086-199307000-00010]
- 10 **Verettas DA**, Galanis B, Kazakos K, Hatziyiannakis A, Kotsios E. Fractures of the proximal part of the femur in patients under 50 years of age. *Injury* 2002; **33**: 41-45 [PMID: 11879831 DOI: 10.1016/s0020-1383(01)00070-5]
- 11 **Obrant K**. Orthopedic treatment of hip fracture. *Bone* 1996; **18**: 145S-148S [PMID: 8777080 DOI: 10.1016/8756-3282(95)00495-5]
- 12 **Askin SR**, Bryan RS. Femoral neck fractures in young adults. *Clin Orthop Relat Res* 1976; **(114)**: 259-264 [PMID: 1261119]
- 13 **Zetterberg CH**, Irstam L, Andersson GB. Femoral neck fractures in young adults. *Acta Orthop Scand* 1982; **53**: 427-435 [PMID: 7090765 DOI: 10.3109/17453678208992237]
- 14 **Swiontkowski MF**, Winkquist RA, Hansen ST. Fractures of the femoral neck in patients between the ages of twelve and forty-nine years. *J Bone Joint Surg Am* 1984; **66**: 837-846 [PMID: 6736085]
- 15 **Tooke SM**, Favero KJ. Femoral neck fractures in skeletally mature patients, fifty years old or less. *J Bone Joint Surg Am* 1985; **67**: 1255-1260 [PMID: 4055851]
- 16 **Yang JJ**, Lin LC, Chao KH, Chuang SY, Wu CC, Yeh TT, Lian YT. Risk factors for nonunion in patients with intracapsular femoral neck fractures treated with three cannulated screws placed in either a triangle or an inverted triangle configuration. *J Bone Joint Surg Am* 2013; **95**: 61-69 [PMID: 23283374 DOI: 10.2106/jbjs.k.01081]
- 17 **Haidukewych GJ**, Rothwell WS, Jacofsky DJ, Torchia ME, Berry DJ. Operative treatment of femoral neck fractures in patients between the ages of fifteen and fifty years. *J Bone Joint Surg Am* 2004; **86-A**: 1711-1716 [PMID: 15292419]
- 18 **Karantana A**, Boulton C, Bouliotis G, Shu KS, Scammell BE, Moran CG. Epidemiology and outcome of fracture of the hip in women aged 65 years and under: a cohort study. *J Bone Joint Surg Br* 2011; **93**: 658-664 [PMID: 21511933 DOI: 10.1302/0301-620x.93b5.24536]
- 19 **Robinson CM**, Saran D, Annan IH. Intracapsular hip fractures. Results of management adopting a treatment proto-

- col. *Clin Orthop Relat Res* 1994; **(302)**: 83-91 [PMID: 8168327 DOI: 10.1097/00003086-199405000-00015]
- 20 **Bhandari M**, Devereaux PJ, Tornetta P, Swiontkowski MF, Berry DJ, Haidukewych G, Schemitsch EH, Hanson BP, Koval K, Dirschl D, Leece P, Keel M, Petrisor B, Heetveld M, Guyatt GH. Operative management of displaced femoral neck fractures in elderly patients. An international survey. *J Bone Joint Surg Am* 2005; **87**: 2122-2130 [PMID: 16140828 DOI: 10.2106/JBJS.E.00535]
 - 21 **Talboys R**, Pickup L, Chojnowski A. The management of intracapsular hip fractures in the 'young elderly' internal fixation or total hip replacement? *Acta Orthop Belg* 2012; **78**: 41-48 [PMID: 22523926]
 - 22 **Hedstrom M**. Are patients with a nonunion after a femoral neck fracture more osteoporotic than others? BMD measurement before the choice of treatment? A pilot study of hip BMD and biochemical bone markers in patients with femoral neck fractures. *Acta Orthop Scand* 2004; **75**: 50-52 [DOI: 10.1080/00016470410001708090]
 - 23 **Swiontkowski MF**, Harrington RM, Keller TS, Vanpatten PK. Torsion and Bending Analysis of Internal-Fixation Techniques for Femoral-Neck Fractures - the Role of Implant Design and Bone-Density. *J Orthopaed Res* 1987; **5**: 433-444 [DOI: 10.1002/Jor.1100050316]
 - 24 **Zlowodzki M**, Brink O, Switzer J, Wingerter S, Woodall J, Petrisor BA, Kregor PJ, Bruinsma DR, Bhandari M. The effect of shortening and varus collapse of the femoral neck on function after fixation of intracapsular fracture of the hip: a multi-centre cohort study. *J Bone Joint Surg Br* 2008; **90**: 1487-1494 [PMID: 18978271 DOI: 10.1302/0301-620X.90B11.20582]
 - 25 **Lu-Yao GL**, Keller RB, Littenberg B, Wennberg JE. Outcomes after displaced fractures of the femoral neck. A meta-analysis of one hundred and six published reports. *J Bone Joint Surg Am* 1994; **76**: 15-25 [PMID: 8288658 DOI: 10.1055/s-2005-919113]
 - 26 **Adelani MA**, Keeney JA, Palisch A, Fowler SA, Clohisy JC. Has total hip arthroplasty in patients 30 years or younger improved? A systematic review. *Clin Orthop Relat Res* 2013; **471**: 2595-2601 [PMID: 23564363 DOI: 10.1007/s11999-013-2975-x]
 - 27 **Protzman RR**, Burkhalter WE. Femoral-neck fractures in young adults. *J Bone Joint Surg Am* 1976; **58**: 689-695 [PMID: 932067]
 - 28 **Davidovitch RI**, Jordan CJ, Egol KA, Vrahas MS. Challenges in the treatment of femoral neck fractures in the non-elderly adult. *J Trauma* 2010; **68**: 236-242 [PMID: 20065780 DOI: 10.1097/Ta.0b013e3181c428ce]
 - 29 **Al-Ani AN**, Neander G, Samuelsson B, Blomfeldt R, Ekström W, Hedström M. Risk factors for osteoporosis are common in young and middle-aged patients with femoral neck fractures regardless of trauma mechanism. *Acta Orthop* 2013; **84**: 54-59 [PMID: 23343373 DOI: 10.3109/17453674.2013.765639]
 - 30 **Boden SD**, Labropoulos P, Saunders R. Hip fractures in young patients: is this early osteoporosis? *Calcif Tissue Int* 1990; **46**: 65-72 [PMID: 2105151 DOI: 10.1007/bf02556089]
 - 31 **Arnoldi CC**, Lemperg RK. Fracture of the femoral neck. II. Relative importance of primary vascular damage and surgical procedure for the development of necrosis of the femoral head. *Clin Orthop Relat Res* 1977; **(129)**: 217-222 [PMID: 608278 DOI: 10.1097/00003086-197711000-00029]
 - 32 **Arnoldi CC**, Linderholm H. Fracture of the femoral neck. I. Vascular disturbances in different types of fractures, assessed by measurements of intraosseous pressures. *Clin Orthop Relat Res* 1972; **84**: 116-127 [PMID: 5032833 DOI: 10.1097/00003086-197205000-00021]
 - 33 **Swiontkowski MF**, Tepic S, Perren SM, Moor R, Ganz R, Rahn BA. Laser Doppler flowmetry for bone blood flow measurement: correlation with microsphere estimates and evaluation of the effect of intracapsular pressure on femoral head blood flow. *J Orthop Res* 1986; **4**: 362-371 [PMID: 2942654 DOI: 10.1002/jor.1100040313]
 - 34 **Kregor PJ**. The effect of femoral neck fractures on femoral head blood flow. *Orthopedics* 1996; **19**: 1031-1036; quiz 1031-1036 [PMID: 8972521]
 - 35 **Maruenda JI**, Barrios C, Gomar-Sancho F. Intracapsular hip pressure after femoral neck fracture. *Clin Orthop Relat Res* 1997; **(340)**: 172-180 [PMID: 9224253 DOI: 10.1097/00003086-199707000-00022]
 - 36 **Bonnaire F**, Schaefer DJ, Kuner EH. Hemarthrosis and hip joint pressure in femoral neck fractures. *Clin Orthop Relat Res* 1998; **(353)**: 148-155 [PMID: 9728169 DOI: 10.1097/00003086-199808000-00017]
 - 37 **Crawford EJ**, Emery RJ, Hansell DM, Phelan M, Andrews BG. Capsular distension and intracapsular pressure in sub-capital fractures of the femur. *J Bone Joint Surg Br* 1988; **70**: 195-198 [PMID: 3279041]
 - 38 **Strömqvist B**, Nilsson LT, Egund N, Thorngren KG, Wingstrand H. Intracapsular pressures in undisplaced fractures of the femoral neck. *J Bone Joint Surg Br* 1988; **70**: 192-194 [PMID: 3346286]
 - 39 **Harper WM**, Barnes MR, Gregg PJ. Femoral head blood flow in femoral neck fractures. An analysis using intraosseous pressure measurement. *J Bone Joint Surg Br* 1991; **73**: 73-75 [PMID: 1991780]
 - 40 **Holmberg S**, Dalen N. Intracapsular pressure and caput circulation in nondisplaced femoral neck fractures. *Clin Orthop Relat Res* 1987; **(219)**: 124-126 [PMID: 3555924 DOI: 10.1097/00003086-198706000-00018]
 - 41 **Xiao J**, Yang XJ, Xiao XS. DSA observation of hemodynamic response of femoral head with femoral neck fracture during traction: a pilot study. *J Orthop Trauma* 2012; **26**: 407-413 [PMID: 22739255 DOI: 10.1097/bot.0b013e318216dd60]
 - 42 **Claffey TJ**. Avascular necrosis of the femoral head. An anatomical study. *J Bone Joint Surg Br* 1960; **42-B**: 802-809 [PMID: 14448717]
 - 43 **Trueta J**, Harrison MH. The normal vascular anatomy of the femoral head in adult man. *J Bone Joint Surg Br* 1953; **35-B**: 442-461 [PMID: 13084696]
 - 44 **Howe WW**, Lacey T, Schwartz RP. A study of the gross anatomy of the arteries supplying the proximal portion of the femur and the acetabulum. *J Bone Joint Surg Am* 1950; **32**: 856-866 [PMID: 14784496]
 - 45 **Sevitt S**. Avascular necrosis and revascularisation of the femoral head after intracapsular fractures; a combined arteriographic and histological necropsy study. *J Bone Joint Surg Br* 1964; **46**: 270-296 [PMID: 14167637]
 - 46 **Sevitt S**, Thompson RG. The distribution and anastomoses of arteries supplying the head and neck of the femur. *J Bone Joint Surg Br* 1965; **47**: 560-573 [PMID: 14341080]
 - 47 **Cheng K**, Cheng S, Montgomery S, Housley E, Wheelwright. Clinical Risk Factors for Hip Fracture in Young Adults Under 50 Years Old. *Eur J Trauma Emerg Surg* 2009; **35**: 40-42 [DOI: 10.1007/s00068-008-7177-48]
 - 48 **Tornetta P**, Kain MS, Creevy WR. Diagnosis of femoral neck fractures in patients with a femoral shaft fracture. Improvement with a standard protocol. *J Bone Joint Surg Am* 2007; **89**: 39-43 [PMID: 17200308 DOI: 10.2106/jbjs.f.00297]
 - 49 **Benterud JG**, Husby T, Nordsletten L, Alho A. Fixation of displaced femoral neck fractures with a sliding screw plate and a cancellous screw or two Olmed screws. A prospective, randomized study of 225 elderly patients with a 3-year follow-up. *Ann Chir Gynaecol* 1997; **86**: 338-342 [PMID: 9474428]
 - 50 **Rierner BL**, Butterfield SL, Ray RL, Daffner RH. Clandestine femoral neck fractures with ipsilateral diaphyseal fractures. *J Orthop Trauma* 1993; **7**: 443-449 [PMID: 8229381 DOI: 10.1097/00005131-199310000-00007]
 - 51 **Wolinsky PR**, Johnson KD. Ipsilateral femoral neck and

- shaft fractures. *Clin Orthop Relat Res* 1995; **(318)**: 81-90 [PMID: 7671535]
- 52 **Collinge CA**, Mir H, Reddix R. Fracture morphology of high shear angle "vertical" femoral neck fractures in young adult patients. *J Orthop Trauma* 2014; **28**: 270-275 [PMID: 24096307 DOI: 10.1097/BOT.000000000000014]
- 53 **Lubovsky O**, Liebergall M, Mattan Y, Weil Y, Mosheiff R. Early diagnosis of occult hip fractures MRI versus CT scan. *Injury* 2005; **36**: 788-792 [PMID: 15910835 DOI: 10.1016/j.injury.2005.01.024]
- 54 **Gill SK**, Smith J, Fox R, Chesser TJ. Investigation of occult hip fractures: the use of CT and MRI. *Scientific-WorldJournal* 2013; **2013**: 830319 [PMID: 23476147 DOI: 10.1155/2013/830319]
- 55 **Bartonicek J**. Pauwels' classification of femoral neck fractures: correct interpretation of the original. *J Orthop Trauma* 2001; **15**: 358-360 [PMID: 11433141 DOI: 10.1097/00005131-200106000-00009]
- 56 **Baitner AC**, Maurer SG, Hickey DG, Jazrawi LM, Kummer FJ, Jamal J, Goldman S, Koval KJ. Vertical shear fractures of the femoral neck. A biomechanical study. *Clin Orthop Relat Res* 1999; **(367)**: 300-305 [PMID: 10546628 DOI: 10.1097/00003086-199910000-00037]
- 57 **Parker MJ**, Dynan Y. Is Pauwels classification still valid? *Injury* 1998; **29**: 521-523 [PMID: 10193494 DOI: 10.1016/s0020-1383(98)00118-1]
- 58 **Garden RS**. Low-angle fixation in fractures of the femoral neck. *J Bone Joint Surg Br* 1961; **43**: 647-663
- 59 **Van Embden D**, Rhemrev SJ, Genelin F, Meylaerts SA, Roukema GR. The reliability of a simplified Garden classification for intracapsular hip fractures. *Orthop Traumatol Surg Res* 2012; **98**: 405-408 [PMID: 22560590 DOI: 10.1016/j.otsr.2012.02.003]
- 60 **Beimers L**, Kreder HJ, Berry GK, Stephen DJ, Schemitsch EH, McKee MD, Jaglal S. Subcapital hip fractures: the Garden classification should be replaced, not collapsed. *Can J Surg* 2002; **45**: 411-414 [PMID: 12500914]
- 61 **Frandsen PA**, Andersen E, Madsen F, Skjødt T. Garden's classification of femoral neck fractures. An assessment of inter-observer variation. *J Bone Joint Surg Br* 1988; **70**: 588-590 [PMID: 3403602]
- 62 **Upadhyay A**, Jain P, Mishra P, Maini L, Gautum VK, Dhaon BK. Delayed internal fixation of fractures of the neck of the femur in young adults. A prospective, randomised study comparing closed and open reduction. *J Bone Joint Surg Br* 2004; **86**: 1035-1040 [PMID: 15446534 DOI: 10.1302/0301-620x.86b7.15047]
- 63 **Scheck M**. Intracapsular fractures of the femoral neck. Continuation of the posterior neck cortex as a cause of unstable fixation. *J Bone Joint Surg Am* 1959; **41-A**: 1187-1200 [PMID: 13854659]
- 64 **Asnis SE**, Wanek-Sgaglione L. Intracapsular fractures of the femoral neck. Results of cannulated screw fixation. *J Bone Joint Surg Am* 1994; **76**: 1793-1803 [PMID: 7989384]
- 65 **Raaymakers EL**. The non-operative treatment of impacted femoral neck fractures. *Injury* 2002; **33** Suppl 3: C8-14 [PMID: 12423585 DOI: 10.1016/s0020-1383(02)00325-x]
- 66 **Gautam VK**, Anand S, Dhaon BK. Management of displaced femoral neck fractures in young adults (a group at risk). *Injury* 1998; **29**: 215-218 [PMID: 9709424 DOI: 10.1016/s0020-1383(97)00184-8]
- 67 **Kuner EH**, Lorz W, Bonnaire F. [Femoral neck fractures in adults: joint sparing operations. I. Results of an AO collective study with 328 patients]. *Unfallchirurg* 1995; **98**: 251-258 [PMID: 7610385 DOI: 10.1007/bf02588353]
- 68 **Jain R**, Koo M, Kreder HJ, Schemitsch EH, Davey JR, Mahomed NN. Comparison of early and delayed fixation of subcapital hip fractures in patients sixty years of age or less. *J Bone Joint Surg Am* 2002; **84-A**: 1605-1612 [PMID: 12208917]
- 69 **Karaeminogullari O**, Demirors H, Atabek M, Tuncay C, Tandogan R, Ozalay M. Avascular necrosis and nonunion after osteosynthesis of femoral neck fractures: effect of fracture displacement and time to surgery. *Adv Ther* 2004; **21**: 335-342 [PMID: 15727403 DOI: 10.1007/bf02850038]
- 70 **Razik F**, Alexopoulos AS, El-Osta B, Connolly MJ, Brown A, Hassan S, Ravikumar K. Time to internal fixation of femoral neck fractures in patients under sixty years--does this matter in the development of osteonecrosis of femoral head? *Int Orthop* 2012; **36**: 2127-2132 [PMID: 22829122 DOI: 10.1007/s00264-012-1619-1]
- 71 **Lowe JA**, Crist BD, Bhandari M, Ferguson TA. Optimal treatment of femoral neck fractures according to patient's physiologic age: an evidence-based review. *Orthop Clin North Am* 2010; **41**: 157-166 [PMID: 20399355 DOI: 10.1016/j.jocl.2010.01.001]
- 72 **Urwin SC**, Parker MJ, Griffiths R. General versus regional anaesthesia for hip fracture surgery: a meta-analysis of randomized trials. *Br J Anaesth* 2000; **84**: 450-455 [PMID: 10823094 DOI: 10.1093/oxfordjournals.bja.a013468]
- 73 **Stein BE**, Srikumaran U, Tan EW, Freehill MT, Wilckens JH. Lower-extremity peripheral nerve blocks in the perioperative pain management of orthopaedic patients: AAOS exhibit selection. *J Bone Joint Surg Am* 2012; **94**: e167 [PMID: 23172334 DOI: 10.2106/jbjs.k.01706]
- 74 **Petrie J**, Sassoon A, Haidukewych GJ. When femoral fracture fixation fails: salvage options. *Bone Joint J* 2013; **95-B**: 7-10 [PMID: 24187343 DOI: 10.1302/0301-620x.95b11.32896]
- 75 **Parker MJ**. The management of intracapsular fractures of the proximal femur. *J Bone Joint Surg Br* 2000; **82**: 937-941 [PMID: 11041577 DOI: 10.1302/0301-620x.82b7.11595]
- 76 **Weinrobe M**, Stankewich CJ, Mueller B, Tencer AF. Predicting the mechanical outcome of femoral neck fractures fixed with cancellous screws: an in vivo study. *J Orthop Trauma* 1998; **12**: 27-36; discussion 36-37 [PMID: 9447516 DOI: 10.1097/00005131-199801000-00005]
- 77 **Bosch U**, Schreiber T, Krettek C. Reduction and fixation of displaced intracapsular fractures of the proximal femur. *Clin Orthop Relat Res* 2002; **(399)**: 59-71 [PMID: 12011695 DOI: 10.1097/00003086-200206000-00009]
- 78 **Garden RS**. Malreduction and avascular necrosis in subcapital fractures of the femur. *J Bone Joint Surg Br* 1971; **53**: 183-197 [PMID: 5578215]
- 79 **Molnar RB**, Routt ML. Open reduction of intracapsular hip fractures using a modified Smith-Petersen surgical exposure. *J Orthop Trauma* 2007; **21**: 490-494 [PMID: 17762484 DOI: 10.1097/BOT.0b013e31804a7f7f]
- 80 **Leadbetter GW**. A treatment for fracture of the neck of the femur. Reprinted from *J Bone Joint Surg* 20: 108-113, 1938. *Clin Orthop Relat Res* 2002; **(399)**: 4-8 [PMID: 12011688 DOI: 10.1097/00003086-200206000-00002]
- 81 **Beck M**, Siebenrock KA, Affolter B, Nötzli H, Parvizi J, Ganz R. Increased intraarticular pressure reduces blood flow to the femoral head. *Clin Orthop Relat Res* 2004; **(424)**: 149-152 [PMID: 15241157 DOI: 10.1097/01.bl0.0000128296.28666.35]
- 82 **Christal AA**, Taitsman LA, Dunbar RP, Krieg JC, Nork SE. Fluoroscopically guided hip capsulotomy: effective or not? A cadaveric study. *J Orthop Trauma* 2011; **25**: 214-217 [PMID: 21399470 DOI: 10.1097/BOT.0b013e3181e93cbe]
- 83 **Zhou L**, Tan J, Xu B. [Treatment of femoral neck fracture with cannulated screw fixation in young adults]. *Zhongguo Xiufu Chongjian Waike Zazhi* 2007; **21**: 275-277 [PMID: 17419210]
- 84 **Watson A**, Zhang Y, Beattie S, Page RS. Prospective randomized controlled trial comparing dynamic hip screw and screw fixation for undisplaced subcapital hip fractures. *ANZ J Surg* 2013; **83**: 679-683 [PMID: 22998439 DOI: 10.1111/j.1445-2197.2012.06256.x]
- 85 **Parker MJ**, Ali SM. Short versus long thread cannulated cancellous screws for intracapsular hip fractures: a randomised trial of 432 patients. *Injury* 2010; **41**: 382-384 [PMID:

- 19883909 DOI: 10.1016/j.injury.2009.10.008]
- 86 **Bonnaire FA**, Weber AT. Analysis of fracture gap changes, dynamic and static stability of different osteosynthetic procedures in the femoral neck. *Injury* 2002; **33** Suppl 3: C24-C32 [PMID: 12423588 DOI: 10.1016/s0020-1383(02)00328-5]
 - 87 **Makki D**, Mohamed AM, Gadiyar R, Patterson M. Addition of an anti-rotation screw to the dynamic hip screw for femoral neck fractures. *Orthopedics* 2013; **36**: e865-e868 [PMID: 23823042 DOI: 10.3928/01477447-20130624-15]
 - 88 **Aminian A**, Gao F, Fedoriw WW, Zhang LQ, Kalainov DM, Merk BR. Vertically oriented femoral neck fractures: mechanical analysis of four fixation techniques. *J Orthop Trauma* 2007; **21**: 544-548 [PMID: 17805021 DOI: 10.1097/BOT.0b013e31814b822e]
 - 89 **Avery PP**, Baker RP, Walton MJ, Rooker JC, Squires B, Gargan MF, Bannister GC. Total hip replacement and hemiarthroplasty in mobile, independent patients with a displaced intracapsular fracture of the femoral neck: a seven- to ten-year follow-up report of a prospective randomised controlled trial. *J Bone Joint Surg Br* 2011; **93**: 1045-1048 [PMID: 21768626 DOI: 10.1302/0301-620x.93b8.27132]
 - 90 **Baker RP**, Squires B, Gargan MF, Bannister GC. Total hip arthroplasty and hemiarthroplasty in mobile, independent patients with a displaced intracapsular fracture of the femoral neck. A randomized, controlled trial. *J Bone Joint Surg Am* 2006; **88**: 2583-2589 [PMID: 17142407 DOI: 10.2106/jbjs.e.01373]
 - 91 **Keating JF**, Grant A, Masson M, Scott NW, Forbes JF. Randomized comparison of reduction and fixation, bipolar hemiarthroplasty, and total hip arthroplasty. Treatment of displaced intracapsular hip fractures in healthy older patients. *J Bone Joint Surg Am* 2006; **88**: 249-260 [PMID: 16452734 DOI: 10.2106/jbjs.e.00215]
 - 92 **Parker MJ**, Pryor G, Gurusamy K. Hemiarthroplasty versus internal fixation for displaced intracapsular hip fractures: a long-term follow-up of a randomised trial. *Injury* 2010; **41**: 370-373 [PMID: 19879576 DOI: 10.1016/j.injury.2009.10.003]
 - 93 **Roshan A**, Ram S. The neglected femoral neck fracture in young adults: review of a challenging problem. *Clin Med Res* 2008; **6**: 33-39 [PMID: 18591377 DOI: 10.3121/cmr.2008.752]
 - 94 **Lifeso R**, Younge D. The neglected hip fracture. *J Orthop Trauma* 1990; **4**: 287-292 [PMID: 2231127 DOI: 10.1097/00005131-199004030-00009]
 - 95 **Gupta A**. The management of ununited fractures of the femoral neck using internal fixation and muscle pedicle periosteal grafting. *J Bone Joint Surg Br* 2007; **89**: 1482-1487 [PMID: 17998186 DOI: 10.1302/0301-620x.89b11.19298]
 - 96 **Gillespie WJ**, Walenkamp GH. Antibiotic prophylaxis for surgery for proximal femoral and other closed long bone fractures. *Cochrane Database Syst Rev* 2010; **(3)**: CD000244 [PMID: 20238310 DOI: 10.1002/14651858.CD000244.pub2]
 - 97 **Barrera LM**, Perel P, Ker K, Cirocchi R, Farinella E, Morales Uribe CH. Thromboprophylaxis for trauma patients. *Cochrane Database Syst Rev* 2013; **3**: CD008303 [PMID: 23543562 DOI: 10.1002/14651858.CD008303.pub2]
 - 98 **Ai ZS**, Gao YS, Sun Y, Liu Y, Zhang CQ, Jiang CH. Logistic regression analysis of factors associated with avascular necrosis of the femoral head following femoral neck fractures in middle-aged and elderly patients. *J Orthop Sci* 2013; **18**: 271-276 [PMID: 23114858 DOI: 10.1007/s00776-012-0331-8]
 - 99 **Manninger J**, Kazar G, Fekete G, Nagy E, Zolczer L, Frenyo S. Avoidance of avascular necrosis of the femoral head, following fractures of the femoral neck, by early reduction and internal fixation. *Injury* 1985; **16**: 437-448 [PMID: 4030066 DOI: 10.1016/0020-1383(85)90162-7]
 - 100 **Bachiller FG**, Caballer AP, Portal LF. Avascular necrosis of the femoral head after femoral neck fracture. *Clin Orthop Relat Res* 2002; **(399)**: 87-109 [PMID: 12011698]
 - 101 **Heuck A**, Reiser M, Schmucker F, Lehner K, Gmeinwieser J, Kahn T, Rupp N. Selective digital subtraction arteriography in necrosis of the femoral head. *Skeletal Radiol* 1987; **16**: 270-274 [PMID: 3303350 DOI: 10.1007/bf00361467]
 - 102 **Watanabe Y**, Terashima Y, Takenaka N, Kobayashi M, Matsushita T. Prediction of avascular necrosis of the femoral head by measuring intramedullary oxygen tension after femoral neck fracture. *J Orthop Trauma* 2007; **21**: 456-461 [PMID: 17762476 DOI: 10.1097/bot.0b013e318126bb56]
 - 103 **Sugamoto K**, Ochi T, Takahashi Y, Tamura T, Matsuoka T. Hemodynamic measurement in the femoral head using laser Doppler. *Clin Orthop Relat Res* 1998; **(353)**: 138-147 [PMID: 9728168 DOI: 10.1097/00003086-199808000-00016]
 - 104 **Greiff J**, Bergmann F. Growth disturbance following fracture of the tibia in children. *Acta Orthop Scand* 1980; **51**: 315-320 [PMID: 7435192 DOI: 10.3109/17453678008990805]
 - 105 **Mont MA**, Seyler TM, Marker DR, Marulanda GA, Delanois RE. Use of metal-on-metal total hip resurfacing for the treatment of osteonecrosis of the femoral head. *J Bone Joint Surg Am* 2006; **88** Suppl 3: 90-97 [PMID: 17079373 DOI: 10.2106/jbjs.f.00543]
 - 106 **Ficat P**, Arlet J. [Dysplasias, osteoarthritis and osteonecrosis of the hip]. *Sem Hop* 1974; **50**: 567-579 [PMID: 4368109]
 - 107 **Assouline-Dayan Y**, Chang C, Greenspan A, Shoenfeld Y, Gershwin ME. Pathogenesis and natural history of osteonecrosis. *Semin Arthritis Rheum* 2002; **32**: 94-124 [PMID: 12430099]
 - 108 **Lieberman JR**, Berry DJ, Mont MA, Aaron RK, Callaghan JJ, Rajadhyaksha AD, Urbaniak JR. Osteonecrosis of the hip: management in the 21st century. *Instr Course Lect* 2003; **52**: 337-355 [PMID: 12690862]
 - 109 **Stulberg BN**, Davis AW, Bauer TW, Levine M, Easley K. Osteonecrosis of the femoral head. A prospective randomized treatment protocol. *Clin Orthop Relat Res* 1991; **(268)**: 140-151 [PMID: 2060201]
 - 110 **Soohoo NF**, Vyas S, Manunga J, Sharifi H, Kominski G, Lieberman JR. Cost-effectiveness analysis of core decompression. *J Arthroplasty* 2006; **21**: 670-681 [PMID: 16877152 DOI: 10.1016/j.arth.2005.08.018]
 - 111 **Marker DR**, Seyler TM, McGrath MS, Delanois RE, Ulrich SD, Mont MA. Treatment of early stage osteonecrosis of the femoral head. *J Bone Joint Surg Am* 2008; **90** Suppl 4: 175-187 [PMID: 18984729 DOI: 10.2106/jbjs.h.00671]
 - 112 **Buckley PD**, Gearen PF, Petty RW. Structural bone-grafting for early atraumatic avascular necrosis of the femoral head. *J Bone Joint Surg Am* 1991; **73**: 1357-1364 [PMID: 1918119]
 - 113 **Phemister DB**. Treatment of the necrotic head of the femur in adults. Dallas Burton Phemister (1882-1951). *Clin Orthop Relat Res* 2000; **(381)**: 4-8 [PMID: 11127669]
 - 114 **Keizer SB**, Kock NB, Dijkstra PD, Taminiau AH, Nelissen RG. Treatment of avascular necrosis of the hip by a non-vascularised cortical graft. *J Bone Joint Surg Br* 2006; **88**: 460-466 [PMID: 16567779 DOI: 10.1302/0301-620x.88b4.16950]
 - 115 **Merle D'Aubigné R**, Postel M, Mazabraud A, Massias P, Gueguen J, France P. Idiopathic necrosis of the femoral head in adults. *J Bone Joint Surg Br* 1965; **47**: 612-633 [PMID: 5846763]
 - 116 **Wang BL**, Sun W, Shi ZC, Zhang NF, Yue DB, Guo WS, Shi SH, Li ZR. Treatment of nontraumatic osteonecrosis of the femoral head using bone impaction grafting through a femoral neck window. *Int Orthop* 2010; **34**: 635-639 [PMID: 19529935 DOI: 10.1007/s00264-009-0822-1]
 - 117 **Mont MA**, Einhorn TA, Sponseller PD, Hungerford DS. The trapdoor procedure using autogenous cortical and cancellous bone grafts for osteonecrosis of the femoral head. *J Bone Joint Surg Br* 1998; **80**: 56-62 [PMID: 9460954]
 - 118 **Ko JY**, Meyers MH, Wenger DR. "Trapdoor" procedure for osteonecrosis with segmental collapse of the femoral head in teenagers. *J Pediatr Orthop* 1995; **15**: 7-15 [PMID: 7883932 DOI: 10.1097/01241398-199501000-00003]
 - 119 **Aldridge JM**, Urbaniak JR. Avascular necrosis of the femoral head: role of vascularized bone grafts. *Orthop Clin*

- North Am 2007; **38**: 13-22, v [PMID: 17145291 DOI: 10.1016/j.jocl.2006.10.012]
- 120 **Parsons SJ**, Steele N. Osteonecrosis of the femoral head: Part 2-Options for treatment. *Curr Orthopaed* 2008; **22**: 349-58 [DOI: 10.1016/j.cuor.2008.07.009]
- 121 **Soucacos PN**, Beris AE, Malizos K, Koropiliias A, Zalavras H, Dailiana Z. Treatment of avascular necrosis of the femoral head with vascularized fibular transplant. *Clin Orthop Relat Res* 2001; **(386)**: 120-130 [PMID: 11347825 DOI: 10.1097/00003086-200105000-00016]
- 122 **Urbaniak JR**, Harvey EJ. Revascularization of the femoral head in osteonecrosis. *J Am Acad Orthop Surg* 1998; **6**: 44-54 [PMID: 9692940]
- 123 **Marciniak D**, Furey C, Shaffer JW. Osteonecrosis of the femoral head. A study of 101 hips treated with vascularized fibular grafting. *J Bone Joint Surg Am* 2005; **87**: 742-747 [PMID: 15805201 DOI: 10.2106/jbjs.d.02004]
- 124 **Eward WC**, Rineer CA, Urbaniak JR, Richard MJ, Ruch DS. The vascularized fibular graft in precollapse osteonecrosis: is long-term hip preservation possible? *Clin Orthop Relat Res* 2012; **470**: 2819-2826 [PMID: 22733182 DOI: 10.1007/s11999-012-2429-x]
- 125 **Zhao D**, Xu D, Wang W, Cui X. Iliac graft vascularization for femoral head osteonecrosis. *Clin Orthop Relat Res* 2006; **442**: 171-179 [PMID: 16394757 DOI: 10.1097/01.blo.0000181490.31424.96]
- 126 **Amanatullah DF**, Strauss EJ, Di Cesare PE. Current management options for osteonecrosis of the femoral head: part II, operative management. *Am J Orthop (Belle Mead NJ)* 2011; **40**: E216-E225 [PMID: 22263205]
- 127 **Mont MA**, Fairbank AC, Krackow KA, Hungerford DS. Corrective osteotomy for osteonecrosis of the femoral head. *J Bone Joint Surg Am* 1996; **78**: 1032-1038 [PMID: 8698720]
- 128 **Seki T**, Hasegawa Y, Masui T, Yamaguchi J, Kanoh T, Ishiguro N, Kawabe K. Quality of life following femoral osteotomy and total hip arthroplasty for nontraumatic osteonecrosis of the femoral head. *J Orthop Sci* 2008; **13**: 116-121 [PMID: 18392915 DOI: 10.1007/s00776-007-1208-0]
- 129 **Scher MA**, Jakim I. Intertrochanteric osteotomy and autogenous bone-grafting for avascular necrosis of the femoral head. *J Bone Joint Surg Am* 1993; **75**: 1119-1133 [PMID: 8354670]
- 130 **Sugioka Y**, Hotokebuchi T, Tsutsui H. Transtrochanteric anterior rotational osteotomy for idiopathic and steroid-induced necrosis of the femoral head. Indications and long-term results. *Clin Orthop Relat Res* 1992; **(277)**: 111-120 [PMID: 1555330 DOI: 10.1097/00003086-199204000-00013]
- 131 **Sugioka Y**, Yamamoto T. Transtrochanteric posterior rotational osteotomy for osteonecrosis. *Clin Orthop Relat Res* 2008; **466**: 1104-1109 [PMID: 18327629 DOI: 10.1007/s11999-008-0192-9]
- 132 **Miyaniishi K**, Noguchi Y, Yamamoto T, Irisa T, Suenaga E, Jingushi S, Sugioka Y, Iwamoto Y. Prediction of the outcome of transtrochanteric rotational osteotomy for osteonecrosis of the femoral head. *J Bone Joint Surg Br* 2000; **82**: 512-516 [PMID: 10855873 DOI: 10.1302/0301-620x.82b4.10065]
- 133 **Gallinaro P**, Massè A. Flexion osteotomy in the treatment of avascular necrosis of the hip. *Clin Orthop Relat Res* 2001; **(386)**: 79-84 [PMID: 11347852 DOI: 10.1097/00003086-200105000-00010]
- 134 **Marker DR**, Seyler TM, Ulrich SD, Srivastava S, Mont MA. Do modern techniques improve core decompression outcomes for hip osteonecrosis? *Clin Orthop Relat Res* 2008; **466**: 1093-1103 [PMID: 18392909 DOI: 10.1007/s11999-008-0184-9]
- 135 **Kawasaki M**, Hasegawa Y, Sakano S, Masui T, Ishiguro N. Total hip arthroplasty after failed transtrochanteric rotational osteotomy for avascular necrosis of the femoral head. *J Arthroplasty* 2005; **20**: 574-579 [PMID: 16309991 DOI: 10.1016/j.arth.2005.01.018]
- 136 **Ferguson GM**, Cabanela ME, Ilstrup DM. Total hip arthroplasty after failed intertrochanteric osteotomy. *J Bone Joint Surg Br* 1994; **76**: 252-257 [PMID: 8113286]
- 137 **Estrada LS**, Volgas DA, Stannard JP, Alonso JE. Fixation failure in femoral neck fractures. *Clin Orthop Relat Res* 2002; **(399)**: 110-118 [PMID: 12011699 DOI: 10.1097/00003086-200206000-00013]
- 138 **Parker MJ**, Raghavan R, Gurusamy K. Incidence of fracture-healing complications after femoral neck fractures. *Clin Orthop Relat Res* 2007; **458**: 175-179 [PMID: 17224836 DOI: 10.1097/BLO.0b013e3180325a42]
- 139 **Parker MJ**. Prediction of fracture union after internal fixation of intracapsular femoral neck fractures. *Injury* 1994; **25** Suppl 2: B3-B6 [PMID: 7960079 DOI: 10.1016/0020-1383(94)90229-1]
- 140 **Angelini M**, McKee MD, Waddell JP, Haidukewych G, Schemitsch EH. Salvage of failed hip fracture fixation. *J Orthop Trauma* 2009; **23**: 471-478 [PMID: 19550237 DOI: 10.1097/BOT.0b013e3181acfc8c]
- 141 **Jackson M**, Learmonth ID. The treatment of nonunion after intracapsular fracture of the proximal femur. *Clin Orthop Relat Res* 2002; **(399)**: 119-128 [PMID: 12011700 DOI: 10.1097/00003086-200206000-00014]
- 142 **Stankewich CJ**, Chapman J, Muthusamy R, Quaid G, Schemitsch E, Tencer AF, Ching RP. Relationship of mechanical factors to the strength of proximal femur fractures fixed with cancellous screws. *J Orthop Trauma* 1996; **10**: 248-257 [PMID: 8723403 DOI: 10.1097/00005131-199605000-00005]
- 143 **Parker MJ**. Results of internal fixation of Pauwels type-3 vertical femoral neck fractures. *J Bone Joint Surg Am* 2009; **91**: 490-491; author reply 491 [PMID: 19182004]
- 144 **Banks HH**. Nonunion in fractures of the femoral neck. *Orthop Clin North Am* 1974; **5**: 865-885 [PMID: 4606848]
- 145 **Hammer AJ**. Nonunion of subcapital femoral neck fractures. *J Orthop Trauma* 1992; **6**: 73-77 [PMID: 1556627]
- 146 **Rawall S**, Bali K, Upendra B, Garg B, Yadav CS, Jayaswal A. Displaced femoral neck fractures in the young: significance of posterior comminution and raised intracapsular pressure. *Arch Orthop Trauma Surg* 2012; **132**: 73-79 [PMID: 21928054 DOI: 10.1007/s00402-011-1395-1]
- 147 **Scheck M**. The significance of posterior comminution in femoral neck fractures. *Clin Orthop Relat Res* 1980; **(152)**: 138-142 [PMID: 7438596 DOI: 10.1097/00003086-198010000-00014]
- 148 **Mathews V**, Cabanela ME. Femoral neck nonunion treatment. *Clin Orthop Relat Res* 2004; **(419)**: 57-64 [PMID: 15021132 DOI: 10.1097/00003086-200402000-00010]
- 149 **Varghese VD**, Boopalan PR, Titus VT, Oommen AT, Jepeganansan TS. Indices affecting outcome of neglected femoral neck fractures after valgus intertrochanteric osteotomy. *J Orthop Trauma* 2014; **28**: 410-416 [PMID: 24164787 DOI: 10.1097/bot.000000000000030]
- 150 **Marti RK**, Schüller HM, Raaymakers EL. Intertrochanteric osteotomy for non-union of the femoral neck. *J Bone Joint Surg Br* 1989; **71**: 782-787 [PMID: 2584247]
- 151 **Ballmer FT**, Ballmer PM, Baumgaertel F, Ganz R, Mast JW. Pauwels osteotomy for nonunions of the femoral neck. *Orthop Clin North Am* 1990; **21**: 759-767 [PMID: 2216406]
- 152 **Hartford JM**, Patel A, Powell J. Intertrochanteric osteotomy using a dynamic hip screw for femoral neck nonunion. *J Orthop Trauma* 2005; **19**: 329-333 [PMID: 15891542]
- 153 **Khan AQ**, Khan MS, Sherwani MK, Agarwal R. Role of valgus osteotomy and fixation with dynamic hip screw and 120 degrees double angle barrel plate in the management of neglected and ununited femoral neck fracture in young patients. *J Orthop Traumatol* 2009; **10**: 71-78 [PMID: 19484358 DOI: 10.1007/s10195-009-0049-3]
- 154 **Meyers MH**, Harvey JP, Moore TM. Treatment of displaced subcapital and transcervical fractures of the femoral neck by muscle-pedicle-bone graft and internal fixation. A prelimi-

- nary report on one hundred and fifty cases. *J Bone Joint Surg Am* 1973; **55**: 257-274 [PMID: 4572222]
- 155 **Baksi DP**. Internal fixation of ununited femoral neck fractures combined with muscle-pedicle bone grafting. *J Bone Joint Surg Br* 1986; **68**: 239-245 [PMID: 3958010]
- 156 **Leung PC**, Shen WY. Fracture of the femoral neck in younger adults. A new method of treatment for delayed and nonunions. *Clin Orthop Relat Res* 1993; **(295)**: 156-160 [PMID: 8403641 DOI: 10.1097/00003086-199310000-00022]
- 157 **LeCroy CM**, Rizzo M, Gunneson EE, Urbaniak JR. Free vascularized fibular bone grafting in the management of femoral neck nonunion in patients younger than fifty years. *J Orthop Trauma* 2002; **16**: 464-472 [PMID: 12172276 DOI: 10.1097/00005131-200208000-00004]

P- Reviewer: Chen YK **S- Editor:** Ji FF **L- Editor:** A
E- Editor: Lu YJ



