



[网页](#) [图片](#) [新闻](#) [视频](#) [购物](#) [更多](#) [搜索工具](#)

找到约 27,600 条结果 (用时 0.58 秒)

### Discrepancies in the histologic type between biopsy and ...

[www.ncbi.nlm.nih.gov](http://www.ncbi.nlm.nih.gov) > ... > Literature > PubMed Central (PMC) - [翻译此页](#)

作者: S Komatsu - 2015 - [相关文章](#)

2015年4月21日 - In specimens **diagnosed** as the **differentiated** type from biopsy specimens, ... In **early gastric cancer**, the histologic type affects the **extent of lymph node metastasis**. ... to be one of the independent **risk factors of lymph node metastasis**[1-3]. ... **mixed type** with a < 50% undifferentiated **component** (D > U group); ...

### Histological mixed-type as an independent prognostic factor ...

[www.ncbi.nlm.nih.gov](http://www.ncbi.nlm.nih.gov) > ... > PubMed Central (PMC) - [翻译此页](#)

作者: S Komatsu - 2015 - [被引用次数: 1](#) - [相关文章](#)

2015年1月14日 - In the **early** stage of **gastric cancer**, the histological **type** influences the **extent of lymph node metastasis**; the undifferentiated **type**, in particular, is one of the independent **risk factors of lymph node metastasis**[3-5]. ... it is classified based on the weakest **differentiated component** by the TNM classification.

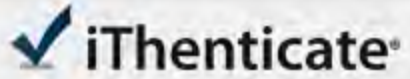
### Histological mixed-type as an independent risk ... - Springer

[link.springer.com/content/.../10.1007%2Fs13277-015-3864-6.p...](http://link.springer.com/content/.../10.1007%2Fs13277-015-3864-6.p...) - [翻译此页](#)

2015年7月29日 - on **lymph node metastasis** in patients with submucosal gastric cancer ... **differentiated type** in the JCGC and TNM classifications and ... scopic screening have led to the **early** detection of **gastric cancer** ... the incidence of LNM relative to the **extent of differentiated** or ... **differentiated component** (pure U group).

### Lymph node metastasis after endoscopic submucosal ...

[onlinelibrary.wiley.com/doi/10.1111/den.12261/pdf](http://onlinelibrary.wiley.com/doi/10.1111/den.12261/pdf) - [翻译此页](#)



ESPS Manuscript NO: 23096  
Manuscript Type: ORIGINAL ARTICLE  
*Retrospective Study*

**4**  
Risk of lymph node metastasis in mixed-type early gastric cancer determined by the extent of the poorly differentiated component

Hwang CS *et al.* Lymph node metastasis in diffuse EGC

**7**  
Chung-Su Hwang, Sangjeong Ahn, Bong-Eun Lee, So-Jeong Lee, Ahrong Kim, Chang In Choi, Dae Hwan Kim, Tae-Yong Jeon, Gwang Ha Kim, Geum Am Song, Do Youn Park

**15**  
**Abstract**  
AIM: To predict the rate of lymph node metastasis in diffuse- and mixed-type early gastric cancers (EGC) for guidelines of the treatment.

Match Overview

<b>1</b>	<b>CrossCheck</b> 103 words Kim, Joo-Yeon, Woo-Gyeong Kim, Tae-Yong Jeon, Gwang Ha Kim, Eun-Hee Jeong, Dae Hwan Kim, Do Youn P	3%
<b>2</b>	<b>CrossCheck</b> 46 words Kang, H.J.. "Lymph node metastasis from intestinal-type early gastric cancer: experience in a single institution an	1%
<b>3</b>	<b>CrossCheck</b> 40 words "Gastrointestinal Pathology", Laboratory Investigation, 2015.	1%
<b>4</b>	<b>Internet</b> 22 words crawled on 30-May-2015 <a href="http://www.researchgate.net">www.researchgate.net</a>	1%
<b>5</b>	<b>CrossCheck</b> 21 words Seigo Kitano. "What technique is suitable for laparoscopic suprapancreatic lymph node dissection?", Gastric Ca	1%
<b>6</b>	<b>CrossCheck</b> 14 words "Poster Abstracts : Poster Abstracts", Journal of Gastroenterology and Hepatology, 2011.	<1%
<b>7</b>	<b>CrossCheck</b> 14 words Kim, Jae Hun. "Intracorporeal esophagojejunostomy using the double stapling technique after laparoscopic to	<1%



[全部](#) [图片](#) [新闻](#) [购物](#) [视频](#) [更多 ▾](#) [搜索工具](#)

找到约 22,700 条结果 (用时 0.78 秒)

### [Histological mixed-type as an independent prognostic factor ...](#)

[www.ncbi.nlm.nih.gov > ... > PubMed Central \(PMC\)](#) [▼ 翻译此页](#)

作者: S Komatsu - 2015 - [被引用次数: 3](#) - [相关文章](#)

2015年1月14日 - In the **early** stage of **gastric cancer**, the histological **type** influences the **extent** of **lymph node metastasis**; the undifferentiated **type**, in particular, is one of the independent **risk** factors of **lymph node metastasis**[3-5]. ... it is classified based on the weakest **differentiated component** by the TNM classification.

### [Discrepancies in the histologic type between biopsy and ...](#)

[www.ncbi.nlm.nih.gov > ... > Literature > PubMed Central \(PMC\)](#) - [翻译此页](#)

作者: S Komatsu - 2015 - [相关文章](#)

2015年4月21日 - In specimens **diagnosed** as the **differentiated** type from biopsy specimens, ... In **early gastric cancer**, the histologic type affects the **extent** of **lymph node metastasis**. ... to be one of the independent **risk** factors of **lymph node metastasis**[1-3]. ... **mixed type** with a < 50% undifferentiated **component** (D > U group); ...

### [\[PDF\] Manuscript - BioMed Central](#)

[www.biomedcentral.com/.../1996524524129323\\_manuscript.p...](#) [▼ 翻译此页](#)

was significant associated with tumor size, **lymph node metastasis** and depth of ... Key words: **gastric cancer**, histological **type**, tumor **differentiation**, prognosis ... any criteria using histopathological tumor-related factors to **determine** the ... survival rates of advanced and **early gastric cancer** patients with **mixed** form were ...

### [Stomach cancer - Wikipedia, the free encyclopedia](#)

[https://en.wikipedia.org/wiki/Stomach\\_cancer](#) [▼ 翻译此页](#)

Stomach cancer, also known as **gastric cancer**, is cancer developing from the ... **Early**

[全部](#) [图片](#) [新闻](#) [视频](#) [购物](#) [更多 ▾](#) [搜索工具](#)

找到约 24,400 条结果 (用时 0.86 秒)

### Histological mixed-type as an independent prognostic factor ...

[www.ncbi.nlm.nih.gov](http://www.ncbi.nlm.nih.gov) > ... > PubMed Central (PMC) ▾ [翻译此页](#)

作者：S Komatsu - 2015 - 被引用次数：3 - [相关文章](#)

2015年1月14日 - In the **early** stage of **gastric cancer**, the histological **type** influences the **extent** of **lymph node metastasis**; the undifferentiated **type**, in particular, is one of the ... based on the weakest **differentiated component** by the TNM classification. ... Four hundred and forty-six patients with stage I **gastric cancer diagnosed** ...

### Discrepancies in the histologic type between biopsy and ...

[www.ncbi.nlm.nih.gov](http://www.ncbi.nlm.nih.gov) > ... > Literature > PubMed Central (PMC) - [翻译此页](#)

作者：S Komatsu - 2015 - [相关文章](#)

2015年4月21日 - In specimens **diagnosed** as the **differentiated** type from biopsy specimens, ... In **early gastric cancer**, the histologic type affects the **extent** of **lymph node metastasis**. ... to be one of the independent **risk** factors of **lymph node metastasis** [1-3]. ... **mixed type** with a < 50% undifferentiated **component** (D > U group); ...

### [PDF] Manuscript - BioMed Central

[www.biomedcentral.com/.../1996524524129323\\_manuscript.p...](http://www.biomedcentral.com/.../1996524524129323_manuscript.p...) ▾ [翻译此页](#)

was significant associated with tumor size, **lymph node metastasis** and depth of ... Key words: **gastric cancer**, histological **type**, tumor **differentiation**, prognosis ... any criteria using histopathological tumor-related factors to **determine** the .... survival rates of advanced and **early gastric cancer** patients with **mixed** form were ...

### Clinicopathological characteristics and treatment strategies ...

[jeccr.biomedcentral.com/articles/10.1186/1756-9966-30-117](http://jeccr.biomedcentral.com/articles/10.1186/1756-9966-30-117) ▾ [翻译此页](#)

作者：H Ito - 2011 - 被引用次数：11 - [相关文章](#)

**early gastric cancer lymph node metastasis** endoscopic submucosal dissection ... **poorly differentiated** adenocarcinoma (por), signet-ring cell carcinoma (sig), or