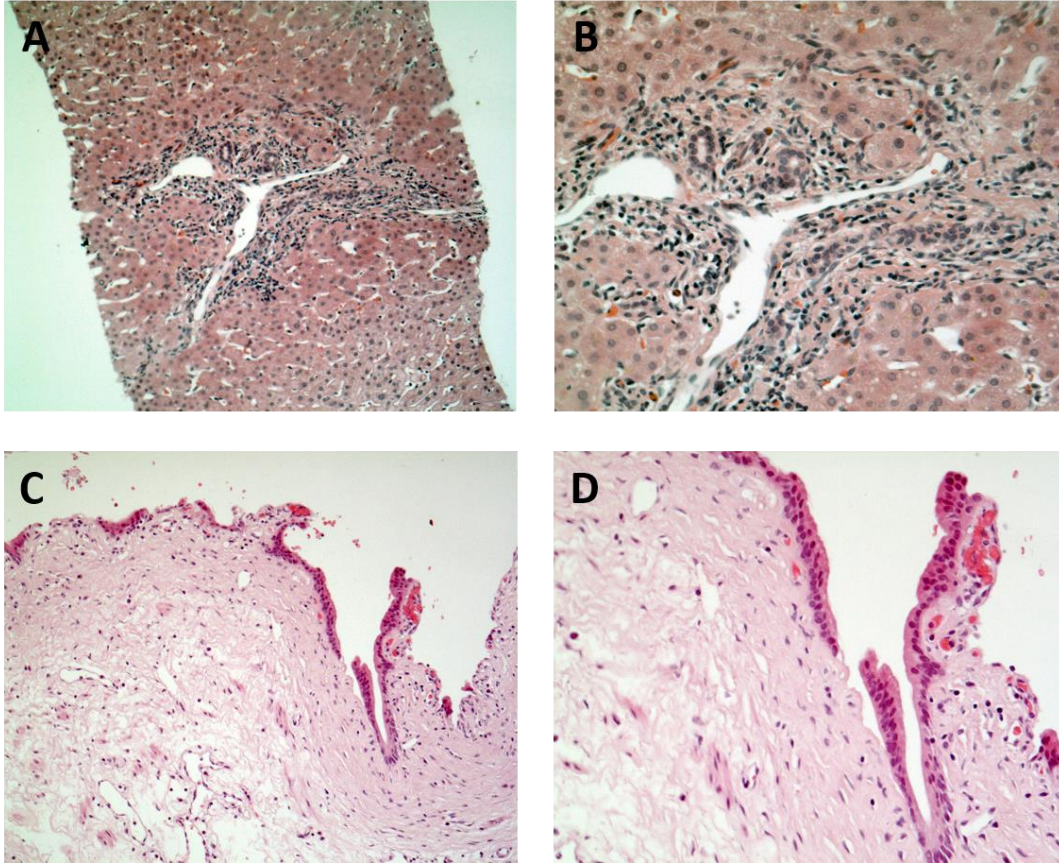


**Supplementary Table 1 Case reports on eosinophilic cholangitis**

<b>Ref.</b>	<b>Year</b>	<b>Sex</b>	<b>Age (yr)</b>	<b>Treatment</b>
Leegard <i>et al</i> <sup>[1]</sup>	1980	Male	46	CE, CS
Butler <i>et al</i> <sup>[2]</sup>	1985	Male	32	CE
Platt <i>et al</i> <sup>[3]</sup>	1990	Female	56	CE
Rosengart <i>et al</i> <sup>[4]</sup>	1990	Male	48	CE
Scheurlen <i>et al</i> <sup>[5]</sup>	1993	Male	30	Hydroxyurea
Grauer <i>et al</i> <sup>[6]</sup>	1993	Male	41	CS, UDCA
Schoonbroodt <i>et al</i> <sup>[7]</sup>	1995	Male	20	CE, CS
Ichikawa <i>et al</i> <sup>[8]</sup>	1997	Male	17	CS, UDCA
Song <i>et al</i> <sup>[9]</sup>	1997	Female	48	CE
Tenner <i>et al</i> <sup>[10]</sup>	1997	Female	38	CE, CS
Rodgers <i>et al</i> <sup>[11]</sup>	2001	Female	50	Roux-en-Y, CE
Shanti <i>et al</i> <sup>[12]</sup>	2001	Male	33	CE, Roux-En-Y
Shanti <i>et al</i> <sup>[12]</sup>	2001	Female	57	Roux-en-Y
Al-Abdulla <i>et al</i> <sup>[13]</sup>	2002	Female	42	CE, CS
Jimenez-Saenz <i>et al</i> <sup>[14]</sup>	2003	Female	67	CE, CS
Vauthey <i>et al</i> <sup>[15]</sup>	2003	Male	16	CS
Duseja <i>et al</i> <sup>[16]</sup>	2005	Female	16	CS
Jeyamani <i>et al</i> <sup>[17]</sup>	2007	Male	13	CS
Jeyamani <i>et al</i> <sup>[17]</sup>	2007	Male	26	CS
Matsumoto <i>et al</i> <sup>[18]</sup>	2007	Female	38	CS
Sussmann <i>et al</i> <sup>[19]</sup>	2008	Male	52	CS, AZT, UDCA

Chen <i>et al</i> <sup>[20]</sup>	2009	Male	55	CE, Roux-en-Y, CS
Iwamuro <i>et al</i> <sup>[21]</sup>	2009	Female	66	CS
Miura <i>et al</i> <sup>[22]</sup>	2009	Male	46	PPPD
Horiuchi <i>et al</i> <sup>[8]</sup>	2009	Male	45	CS, UDCA, Bezafibrat
Dubay <i>et al</i> <sup>[23]</sup>	2010	Female	29	Roux-en-Y
Nashed <i>et al</i> <sup>[24]</sup>	2010	Male	33	Roux-en-Y
Kroemer <i>et al</i> <sup>[25]</sup>	2012	Male	49	PPPD
Goode <i>et al</i> <sup>[26]</sup>	2013	Male	20	CS
Kimura <i>et al</i> <sup>[27]</sup>	2013	Male	48	CE
Vainer <i>et al</i> <sup>[28]</sup>	2014	Female	15	CE, CS
Seow-En <i>et al</i> <sup>[29]</sup>	2014	Male	63	CE, Roux-En-Y
Hokuto <i>et al</i> <sup>[30]</sup>	2015	Male	73	CE, Roux-En-Y
Walter <i>et al</i> <sup>[31]</sup>	2016	Female	41	CS
Fragulidis <i>et al</i> <sup>[32]</sup>	2016	Female	27	CS

AZT: Azathioprine; CE: Cholecystectomy, CS: Corticosteroids; PPPD: Pylorus preserving partial pancreatoduodenectomy; Roux-En-Y: Choledochojejunostomy or hepaticojejunostomy; UDCA: Ursodeoxycholic acid.



**Supplementary Figure 1 Hematoxylin-eosin stained tissue sections of cases of primary sclerosing cholangitis (A: 100 ×, B: 200 ×) and non-inflammatory biliary epithelium of a liver transplant donor (C: 100 ×, D: 200 ×) without eosinophilic infiltration.**

## REFERENCES

1. Leegaard M (1980) Eosinophilic cholecystitis. *Acta Chir Scand* 146:295–6.
2. Butler TW, Feintuch TA, Caine WP (1985) Eosinophilic cholangitis, lymphadenopathy, and peripheral eosinophilia: a case report. *Am J Gastroenterol* 80:572–4.
3. Platt ML, Kiesling VJ, Vaccaro JA (1990) Eosinophilic ureteritis associated with eosinophilic cholangitis: a case report. *J Urol* 144:127–9.
4. Rosengart TK, Rotterdam H, Ranson JH (1990) Eosinophilic cholangitis: a self-limited cause of extrahepatic biliary obstruction. *Am J Gastroenterol* 85:582–5.
5. Scheurlen M, Mörk H, Weber P (1992) Hypereosinophilic syndrome resembling chronic inflammatory bowel disease with primary sclerosing cholangitis. *J Clin Gastroenterol* 14:59–63.
6. Grauer L, Padilla VM, Bouza L, Barkin JS (1993) Eosinophilic sclerosing cholangitis associated with hypereosinophilic syndrome. *Am J Gastroenterol* 88:1764–9.
7. Schoonbroodt D, Horsmans Y, Laka A, et al (1995) Eosinophilic gastroenteritis presenting with colitis and cholangitis. *Dig Dis Sci* 40:308–14.
8. Horiuchi K, Kakizaki S, Kosone T, et al (2009) Marked eosinophilia as the first manifestation of sclerosing cholangitis. *Intern Med* 48:1377–82.
9. Song HH, Byun JY, Jung SE, et al Eosinophilic cholangitis: US, CT, and cholangiography findings. *J Comput Assist Tomogr* 21:251–3.
10. Tenner S, Roston A, Lichtenstein D, et al (1997) Eosinophilic cholangiopathy. *Gastrointest Endosc* 45:307–9.
11. Rodgers MS, Allen JP, Koea JB, McCall JL (2001) Eosinophilic cholangitis: a case of “malignant masquerade”. *HPB (Oxford)* 3:235–9. doi: 10.1080/136518201753242280
12. Shanti CM, Lucas CE, Tyburski JG, et al (2001) Eosinophilic abscess and eosinophilic pseudotumor presenting as bile duct masses: a report of 2 cases. *Surgery* 130:104–8. doi: 10.1067/msy.2001.113285
13. al-Abdulla NA, Schulick RD, Regan F Hypereosinophilic sclerosing cholangitis:

findings using half-Fourier magnetic resonance imaging. *Hepatogastroenterology* 47:359–61.

14. Jimenez-Saenz M, Villar-Rodriguez JL, Torres Y, et al (2003) Biliary tract disease: a rare manifestation of eosinophilic gastroenteritis. *Dig Dis Sci* 48:624–7.
15. Vauthey J-N, Loyer E, Chokshi P, Lahoti S (2003) Case 57: eosinophilic cholangiopathy. *Radiology* 227:107–12. doi: 10.1148/radiol.2271010938
16. Duseja A, Nada R, Dhiman RK, et al (2005) Eosinophilic cholangiopathy--a case report. *Dig Dis Sci* 50:1422–5.
17. Jeyamani R, Ramakrishna BS, Kurian G Eosinophilic cholangiopathy - a report of two cases. *Indian J Gastroenterol* 26:190–1.
18. Matsumoto N, Yokoyama K, Nakai K, et al (2007) A case of eosinophilic cholangitis: imaging findings of contrast-enhanced ultrasonography, cholangioscopy, and intraductal ultrasonography. *World J Gastroenterol* 13:1995–7.
19. Sussman DA, Bejarano PA, Regev A (2008) Eosinophilic cholangiopathy with concurrent eosinophilic colitis in a patient with idiopathic hypereosinophilic syndrome. *Eur J Gastroenterol Hepatol* 20:574–7. doi: 10.1097/MEG.0b013e3282f1cc11
20. Chen WH, Yu CC, Wu CC, Jan YJ (2009) Eosinophilic cholangitis with obstructive jaundice mimicking bile duct carcinoma. *J Hepatobiliary Pancreat Surg* 16:242–5. doi: 10.1007/s00534-008-0041-y
21. Iwamuro M, Yamamoto K, Kawamoto H, et al (2009) Eosinophilic cholangitis with initial clinical features indistinguishable from IgG4-related cholangitis. *Intern Med* 48:1143–7.
22. Miura F, Asano T, Amano H, et al (2009) Resected case of eosinophilic cholangiopathy presenting with secondary sclerosing cholangitis. *World J Gastroenterol* 15:1394–7.
23. Dubay D, Jhala N, Eloubeidi M (2010) Eosinophilic cholangitis. *Clin Gastroenterol Hepatol* 8:A22. doi: 10.1016/j.cgh.2010.02.006
24. Chamberlain RS, Nashed C, Sakpal SV, Shusharina V (2010) Eosinophilic

cholangitis and cholangiopathy: A sheep in wolves clothing. *HPB Surg* 2010;906496. doi: 10.1155/2010/906496

25. Kroemer A, Sabet-Baktach M, Doenecke A, et al (2012) Eosinophilic cholangitis and wirsungitis as cause of simultaneous bile duct obstruction and pancreatitis. *Zeitschrift für Gastroenterol* 50:766–70. doi: 10.1055/s-0031-1299110
26. Goode EC, Simpson BW, Rushbrook SM (2013) A rare cause of cholangiopathy. *Gastroenterology* 144:e14-5. doi: 10.1053/j.gastro.2013.03.029
27. Kimura Y, Yamashita Y, Mikami S, et al (2013) [Eosinophilic cholangitis from almost normal appearance to the bile duct sclerosis similar to primary sclerosing cholangitis]. *Nihon Shokakibyō Gakkai Zasshi* 110:271–81.
28. Vainer E, Vainer G, Jacob H, Faroja M (2014) Eosinophilic cholangitis diagnosed endoscopically. *Endoscopy* 46:E95–E96. doi: 10.1055/s-0033-1359137
29. Seow-En I, Chiow AKH, Tan SS, Poh WT (2014) Eosinophilic cholangiopathy: the diagnostic dilemma of a recurrent biliary stricture. Should surgery be offered for all? *BMJ Case Rep*. doi: 10.1136/bcr-2013-202225
30. Hokuto D, Yamato I, Nomi T, et al (2015) Eosinophilic cholangitis coexisted with idiopathic thrombocytopenic purpura: Report of a case. *Hepatol Res* 45:595–600. doi: 10.1111/hepr.12380
31. Walter D, Hartmann S, Albert JG (2016) Indeterminate biliary stricture with suspicion for malignancy unmasked as eosinophilic cholangitis by cholangioscopy. *Gastrointest Endosc*. doi: 10.1016/j.gie.2016.02.019
32. Fragulidis GP, Vezakis AI, Kontis EA, et al (2016) Eosinophilic Cholangitis--A Challenging Diagnosis of Benign Biliary Stricture: A Case Report. *Medicine (Baltimore)* 95:e2394. doi: 10.1097/MD.0000000000002394