



Chronic acetabular rim fracture - 3D CT, 3D MRI and arthroscopic correlation.



网页 图片 视频 新闻 更多 搜索工具

找到约 16,600 条结果 (用时 0.84 秒)

Google 学术 : Femoroacetabular impingement with chronic acetabular rim fracture - 3D CT, 3D MRI and arthroscopic correlation.

Femoroacetabular impingement: a review of diagnosis ... - Banerjee - 被引用次数 : 45

Acetabular labral tears in patients with sports injury - Kang - 被引用次数 : 30

Imaging findings of femoroacetabular impingement ... - Beall - 被引用次数 : 155

Femoroacetabular impingement: a review of diagnosis and ...

www.ncbi.nlm.nih.gov > ... > PubMed Central (PMC) > 翻译此页

作者 : P Banerjee - 2011 - 被引用次数 : 46 - 相关文章

2011年3月16日 - Open or arthroscopic exploration of the hip is undertaken with bony resection to ... Femoro-acetabular impingement is defined as the abutment between the proximal femur and the acetabular rim [2]. CT 3D surface reconstructions allow the lesion to be visualised and surgical resection planned (Fig. 7).

Magnetic resonance imaging of hip joint cartilage and labrum

www.ncbi.nlm.nih.gov > ... > PubMed Central (PMC) > 翻译此页

作者 : C Zilkens - 2011 - 被引用次数 : 6 - 相关文章

2011年6月29日 - The concept of femoroacetabular impingement (FAI) as a major contributor A poor histologic correlation is reported for these MRI-findings.⁸⁹ Figure ... healing of rim fractures.⁹⁴ Supra-acetabular fossae (Figure 11C) appear as faster imaging times and three-dimensional (3D) dGEMRIC.^{108,116} This ...

[PDF] ACR Appropriateness Criteria® Chronic Hip Pain ...

www.acr.org/~l.../5bad72e317ac40ae89bbdc6ae25ea9fe.pdf > 翻译此页

acetabular labrum and for the evaluation of ... of unsuspected pelvic fracture and soft-

Name of journal: World Journal of Orthopedics

ESPS Manuscript NO: 16866

Columns: Case Report

Femoroacetabular impingement with chronic acetabular rim fracture- 3D CT, 3D MRI and arthroscopic correlation

Avneesh Chhabra, Shaun Nordeck, Sai Madhavapeddi, William J Robertson

Abstract

Femoroacetabular impingement is uncommonly associated with a large rim fragment of bone along the superolateral acetabulum. We report an unusual case of femoroacetabular impingement (FAI) with chronic acetabular rim fracture. Radiographic, 3D CT, 3D MRI and arthroscopy correlation is presented with discussion of relative advantages and disadvantages of various modalities in the context of FAI.

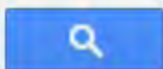
Key words: 3D computed tomography; 3D Magnetic Resonance Imaging; Femoroacetabular Impingement; Rim fracture; CAM; PINCER

Match Overview

1	CrossCheck 21 words Segmuller, H.E.. "Arthroscopic treatment of adhesive capsulitis", Journal of Shoulder and Elbow Surgery, 199511/12	1%
2	Internet 18 words crawled on 31-Aug-2014 borhan.org.sa	<1%
3	Internet 16 words crawled on 03-Sep-2013 caseconnector.jbjs.org	<1%
4	CrossCheck 14 words Novais, Eduardo N., Wudbhav N. Sankar, Lawrence Wells, Patrick M. Carry, and Young-Jo Kim. "Preliminary Results	<1%
5	Internet 12 words crawled on 25-Jan-2010 www.acr.org	<1%
6	CrossCheck 11 words Economopoulos, Kostas J.. "The Role of Femoroacetabular Impingement in the Etiology of Athletic Pubalgia and Spor	<1%
7	Internet 11 words crawled on 21-Apr-2013 www.ncbi.nlm.nih.gov	<1%
8	CrossCheck 9 words	<1%



Femoroacetabular impingement with chronic acetabular rim fracture - 3D



网页 图片 视频 新闻 更多 搜索工具

找到约 13,800 条结果 (用时 0.71 秒)

Google 学术 : Femoroacetabular impingement with chronic acetabular rim fracture - 3D computed tomography, 3D magnetic resonance imaging and arthroscopic correlation

... of the acetabular labrum with histologic correlation in ... - Hodler - 被引用次数 : 188

Herniation pit of the femoral neck - Pitt - 被引用次数 : 174

Femoroacetabular impingement: a review of diagnosis ... - Banerjee - 被引用次数 : 45

Femoroacetabular impingement: a review of diagnosis and ...

www.ncbi.nlm.nih.gov > ... > PubMed Central (PMC) 翻译此页

作者 : P Banerjee - 2011 - 被引用次数 : 45 - 相关文章

2011年3月16日 - Open or arthroscopic exploration of the hip is undertaken with bony ... The use of magnetic resonance imaging has helped to improve the ... Femoroacetabular impingement is defined as the abutment CT 3D surface reconstructions allow the lesion to be visualised and surgical resection planned (Fig. 7).

[PDF] ACR Appropriateness Criteria® Chronic Hip Pain ...

https://acsearch.acr.org/docs/69425/EvidenceTable/ 翻译此页

acetabular labrum and for the evaluation of articular ... of unsuspected pelvic fracture and soft-tissue injury in ... femoroacetabular impingement. Magn ... resolution of MRI is superior to CT and is vital arthroscopic correlation. ... 3D CT. The mean alpha angle for the symptomatic and the control group were: 66.4 vs 43.8.

A quantitative non-invasive assessment of femoroacetabular ...

www.biomedcentral.com/1471-2474/16/50 翻译此页

作者 : MA Röling - 2015

[网页](#)[图片](#)[视频](#)[新闻](#)[更多](#)[搜索工具](#)

找到约 4,080 条结果 (用时 0.52 秒)

Google 学术: Femoroacetabular impingement with chronic acetabular rim fracture - 3D computed tomography, 3D magnetic resonance imaging and arthroscopic correlation

... of the acetabular labrum with histologic correlation in ... - Hodler - 被引用次数: 189

Herniation pit of the femoral neck - Pitt - 被引用次数: 174

Femoroacetabular impingement: a review of diagnosis ... - Banerjee - 被引用次数: 45

Femoroacetabular impingement: a review of diagnosis and ...

www.ncbi.nlm.nih.gov > ... > PubMed Central (PMC) ▾ [翻译此页](#)

作者: P Banerjee - 2011 - 被引用次数: 45 - 相关文章

2011年3月16日 - Open or arthroscopic exploration of the hip is undertaken with bony ...

The use of magnetic resonance imaging has helped to improve the ... Femoro-acetabular impingement is defined as the abutment CT 3D surface reconstructions allow the lesion to be visualised and surgical resection planned (Fig. 7).

[PDF] ACR Appropriateness Criteria® Chronic Hip Pain ...

<https://acsearch.acr.org/docs/69425/EvidenceTable/> ▾ [翻译此页](#)

acetabular labrum and for the evaluation of articular ... of unsuspected pelvic fracture and soft-tissue injury in ... femoroacetabular impingement. Magn ... resolution of MRI is