


World Journal of *Hepatology*

World J Hepatol 2018 July 27; 10(7): 452-529



**REVIEW**

- 452 Contemporary role of liver biopsy in hepatocellular carcinoma
Sparchez Z, Mocan T

MINIREVIEWS

- 462 MR with Gd-EOB-DTPA in assessment of liver nodules in cirrhotic patients
Inchingolo R, Faletti R, Grazioli L, Tricarico E, Gatti M, Pecorelli A, Ippolito D
- 474 Associations between nonalcoholic fatty liver disease and ischemic stroke
Alkagiet S, Papagiannis A, Tziomalos K
- 479 Status and perspective of laparoscopic repeat liver resection
Morise Z
- 485 Balloon-occluded transcatheter arterial chemoembolization for hepatocellular carcinoma
Hatanaka T, Arai H, Kakizaki S

ORIGINAL ARTICLE**Basic Study**

- 496 Amelioration of hepatotoxicity by biodegradable aminothiols chimeras of isoniazid: Design, synthesis, kinetics and pharmacological evaluation
Bhilare NV, Dhaneshwar SS, Mahadik KR

CASE REPORT

- 509 Hepatitis B virus subgenotype F3 reactivation with vaccine escape mutations: A case report and review of the literature
Schlabe S, van Bremen K, Aldabbagh S, Glebe D, Bremer CM, Marsen T, Mellin W, Di Cristanziano V, Eis-Hübingen AM, Spengler U
- 517 Large primary hepatic gastrinoma in young patient treated with trisegmentectomy: A case report and review of the literature
Pipek LZ, Jardim YJ, Mesquita GHA, Nii F, Medeiros KAA, Carvalho BJ, Martines DR, Iuamoto LR, Waisberg DR, D'Albuquerque LAC, Meyer A, Andraus W



- 523 Hepatectomy for gallbladder-cancer with unclassified anomaly of right-sided ligamentum teres: A case report and review of the literature
Goto T, Terajima H, Yamamoto T, Uchida Y

ABOUT COVER

Editorial Board Member of *World Journal of Hepatology*, Ahmet Gurakar, MD, Associate Professor, Department of Medicine, Division of Gastroenterology and Hepatology, Johns Hopkins University, Baltimore, MA 21205, United States

AIM AND SCOPE

World Journal of Hepatology (*World J Hepatol*, *WJH*, online ISSN 1948-5182, DOI: 10.4254), is a peer-reviewed open access academic journal that aims to guide clinical practice and improve diagnostic and therapeutic skills of clinicians.

WJH covers topics concerning liver biology/pathology, cirrhosis and its complications, liver fibrosis, liver failure, portal hypertension, hepatitis B and C and inflammatory disorders, steatohepatitis and metabolic liver disease, hepatocellular carcinoma, biliary tract disease, autoimmune disease, cholestatic and biliary disease, transplantation, genetics, epidemiology, microbiology, molecular and cell biology, nutrition, geriatric and pediatric hepatology, diagnosis and screening, endoscopy, imaging, and advanced technology. Priority publication will be given to articles concerning diagnosis and treatment of hepatology diseases. The following aspects are covered: Clinical diagnosis, laboratory diagnosis, differential diagnosis, imaging tests, pathological diagnosis, molecular biological diagnosis, immunological diagnosis, genetic diagnosis, functional diagnostics, and physical diagnosis; and comprehensive therapy, drug therapy, surgical therapy, interventional treatment, minimally invasive therapy, and robot-assisted therapy.

We encourage authors to submit their manuscripts to *WJH*. We will give priority to manuscripts that are supported by major national and international foundations and those that are of great basic and clinical significance.

INDEXING/ABSTRACTING

World Journal of Hepatology is now indexed in Emerging Sources Citation Index (Web of Science), PubMed, PubMed Central, and Scopus.

EDITORS FOR THIS ISSUE

Responsible Assistant Editor: *Xiang Li*
Responsible Electronic Editor: *Wen-Wen Tan*
Proofing Editor-in-Chief: *Lian-Sheng Ma*

Responsible Science Editor: *Fang-Fang Ji*
Proofing Editorial Office Director: *Jin-Lei Wang*

NAME OF JOURNAL
World Journal of Hepatology

ISSN
ISSN 1948-5182 (online)

LAUNCH DATE
October 31, 2009

FREQUENCY
Monthly

EDITOR-IN-CHIEF
Wan-Long Chuang, MD, PhD, Doctor, Professor,
Hepatobiliary Division, Department of Internal Medicine, Kaohsiung Medical University Hospital, Kaohsiung Medical University, Kaohsiung 807, Taiwan

EDITORIAL BOARD MEMBERS
All editorial board members resources online at <http://www.wjgnet.com/1948-5182/editorialboard.htm>

EDITORIAL OFFICE
Jin-Lei Wang, Director

World Journal of Hepatology
Baishideng Publishing Group Inc
7901 Stoneridge Drive, Suite 501,
Pleasanton, CA 94588, USA
Telephone: +1-925-2238242
Fax: +1-925-2238243
E-mail: editorialoffice@wjgnet.com
Help Desk: <http://www.f6publishing.com/helpdesk>
<http://www.wjgnet.com>

PUBLISHER
Baishideng Publishing Group Inc
7901 Stoneridge Drive, Suite 501,
Pleasanton, CA 94588, USA
Telephone: +1-925-2238242
Fax: +1-925-2238243
E-mail: bpgoffice@wjgnet.com
Help Desk: <http://www.f6publishing.com/helpdesk>
<http://www.wjgnet.com>

PUBLICATION DATE
July 27, 2018

COPYRIGHT

© 2018 Baishideng Publishing Group Inc. Articles published by this Open Access journal are distributed under the terms of the Creative Commons Attribution Non-commercial License, which permits use, distribution, and reproduction in any medium, provided the original work is properly cited, the use is non commercial and is otherwise in compliance with the license.

SPECIAL STATEMENT

All articles published in journals owned by the Baishideng Publishing Group (BPG) represent the views and opinions of their authors, and not the views, opinions or policies of the BPG, except where otherwise explicitly indicated.

INSTRUCTIONS TO AUTHORS

<http://www.wjgnet.com/bpg/gerinfo/204>

ONLINE SUBMISSION

<http://www.f6publishing.com>

Status and perspective of laparoscopic repeat liver resection

Zenichi Morise

Zenichi Morise, Department of Surgery, Fujita Health University School of Medicine, Toyoake 470-1192, Aichi, Japan

ORCID number: Zenichi Morise (0000-0001-6382-6502).

Author contributions: Morise Z collected the data and wrote this paper.

Conflict-of-interest statement: Morise Z declares no conflicts of interest related to this publication.

Open-Access: This article is an open-access article which was selected by an in-house editor and fully peer-reviewed by external reviewers. It is distributed in accordance with the Creative Commons Attribution Non-Commercial (CC BY-NC 4.0) license, which permits others to distribute, remix, adapt, build upon this work non-commercially, and license their derivative works on different terms, provided the original work is properly cited and the use is non-commercial. See: <http://creativecommons.org/licenses/by-nc/4.0/>

Manuscript source: Invited manuscript

Correspondence to: Zenichi Morise, MD, PhD, Professor, Department of Surgery, Fujita Health University School of Medicine, 1-98 Kutsukakecho Toyoake 470-1192, Aichi, Japan. zmorise@fujita-hu.ac.jp
Telephone: +81-562-939246
Fax: +81-562-935125

Received: March 26, 2018

Peer-review started: March 27, 2018

First decision: April 13, 2018

Revised: April 18, 2018

Accepted: May 30, 2018

Article in press: May 30, 2018

Published online: July 27, 2018

Abstract

Liver resection (LR) is now actively applied to intrahepatic recurrence of liver metastases and hepatocellular

carcinoma. Although indications of laparoscopic LR (LLR) have been expanded, there are increased risks of intraoperative complications and conversion in repeat LLR. Controversy still exists for the indication. There are 16 reports of small series to date. These studies generally reported that repeat LLR has better short-term outcomes than open (reduced bleedings, less or similar morbidity and shorter hospital stay) without compromising the long-term outcomes. The fact that complete adhesiolysis can be avoided in repeat LLR is also reported. In the comparison of previous procedures, it is reported that the operation time for repeat LLR was shorter for the patients previously treated with LLR than open. Furthermore, it is speculated that LLR for minor repeat LR of cirrhotic liver can be minimized the deterioration of liver function by LR. However, further experience and evaluation of anatomical resection or resections exposing major vessels as repeat LLR, especially after previous anatomical resection, are needed. There should be a chance to prolong the overall survival of the patients by using LLR as a powerful local therapy which can be applied repeatedly with minimal deterioration of liver function.

Key words: Hepatocellular carcinoma; Laparoscopic liver resection; Repeat surgery; Metastasis

© **The Author(s) 2018.** Published by Baishideng Publishing Group Inc. All rights reserved.

Core tip: There are 16 reports of repeat laparoscopic liver resection (LLR). They reported that it has better short-term outcomes than open (reduced bleedings, less or similar morbidity and shorter hospital stay). The fact that complete adhesiolysis can be avoided in repeat LLR is also reported. It is speculated that LLR for minor repeat LR of cirrhotic liver can be minimized the deterioration of liver function by LR. Repeated application of LLR as a powerful local therapy, which can be applied repeatedly with minimal deterioration of liver function, could improve the overall survival of the patients.

Morise Z. Status and perspective of laparoscopic repeat liver resection. *World J Hepatol* 2018; 10(7): 479-484 Available from: URL: <http://www.wjgnet.com/1948-5182/full/v10/i7/479.htm> DOI: <http://dx.doi.org/10.4254/wjh.v10.i7.479>

INTRODUCTION

The neoplastic liver background of hepatocellular carcinoma (HCC) with chronic liver disease (CLD) develops multifocal and metachronous liver tumors repeatedly. Also, metastases of various tumors can occur repeatedly in the liver. Repeat treatments for HCC and metastases, especially of colorectal cancer, are often needed.

Nowadays, liver resection (LR) is often performed to such lesions, if they are resectable without other uncontrollable/distant disease, and the reports for repeat LR has increased^[1-4]. Furthermore, indications of laparoscopic LR (LLR) are expanding with the accumulation of experiences and technical/instrumental developments^[5-8]. In LLR, surgeons should overcome restricted manipulation, lack of tactile sensation and three-dimensional (3D) vision (which is recently partially resolved by 3D-laparoscope), and disorientation from the lack of an overview of operative field, during liver mobilization, pedicle control and parenchymal transection, which is a trade-off to magnified fine local view^[9,10]. Postoperative adhesions with the need for adhesiolysis are known to increase the operation time of subsequent surgeries and the incidence of bowel injury^[11,12]. Therefore, increased rates of complications and conversion from laparoscopic to open surgery had been reported in repeat laparoscopic surgery^[13]. A previous history of surgery had been among the contraindications for laparoscopic surgery. However, many laparoscopic procedures with previous surgical history, such as cholecystectomy^[12,13], appendectomy^[14], colectomy^[15], and gastrectomy^[16], can be performed nowadays with technical and instrumental improvements. On the other, LLR itself remains a demanding procedure and the indications of repeat LLR are under discussion. Adequate dissection of adhesion and mobilization of the involved liver should be performed before repeat LR. Adhesion can disrupt the dissection of hilar area and hepatoduodenal ligament, which is often crucial in LR. The deformity of the liver and surrounding scars and adhesion makes the localization of tumors and the important structures (vessels) difficult. The fact that liver capsule bleeds easily during adhesiolysis and mobilization leads to increase the intraoperative bleeding and create a suboptimal operative field^[17]. These changes after previous surgery can increase the risks of intraoperative injury to vascular or biliary structures.

STUDIES OF REPEAT LLR

Only 16 reports of small series were found out under

Medline-search with the words "repeat" and "laparoscopic liver resection" and their re-quotations^[18-33] (Table 1), although they are gradually increasing. Belli *et al*^[20] reported that LLR with its magnified view facilitates more meticulous dissection of adhesions strained by the pneumoperitoneum. An additional possible advantage of repeat LLR is reported that complete adhesiolysis can be avoided when the adhesion does not affect the current operative procedure^[24,29]. Generally, these studies reported that repeat LLR has better short-term outcomes (similar or longer operation time, reduced bleedings, less blood transfusion, less or similar morbidity and shortened hospital stay) with the comparable long-term outcomes. Each study concluded that repeat LLR is feasible and safe for selected patients, although those studies are the mixtures of the patients with HCC and metastases. The settings of the patients with HCC and metastases are different in LR. The patients with metastases sometimes undergo major LR with the handling of Glissonian pedicles on the soft liver with congestion and/or steatosis. Minor LR on the fibrous hard liver with poor functional reserve and surrounding collateral vessels is often performed for HCC patients. Five studies of repeat LLR, which only include HCC patients^[20,24,26,27,31], reported the outcomes for the series of 12, 6, 3, 20 and 8 patients. The conclusions of all studies are that repeat LLR for recurrent HCC in CLD backgrounds is a safe and feasible procedure. It is mentioned that the adhesiolysis was easier and the operation time was shorter in repeat LLR for the patients with previous LLR compared to open LR^[20]. Belli *et al*^[20] referred the advantages of LLR for the management during the long history with repeat oncogenesis in cirrhotic patients. Kanazawa *et al*^[27] mentioned that the complication rate and the hospital stay had been decreased in their institute by the introduction of LLR for recurrent HCC patients.

LLR CHARACTERISTICS

It is previously reported that LLR is especially beneficial for severe CLD patients^[34]. LLR with minimal laparotomy and mobilization can minimize the destruction of blood and lymphatic collaterals, as well as the parenchymal injury by compression. It reduces postoperative ascites and liver failure for CLD patients^[35]. In LR, resection of the liver inside the subphrenic rib cage is performed. The cage is opened with a big subcostal incision and then the liver is picked up with mobilization in open LR. On the other, laparoscope and forceps intrude into the cage directly from the caudal direction ("Caudal approach"^[36-38], Figure 1) and perform LR in the small targeted area without damages to the surrounding area in LLR. LLR also facilitates the usage of postural change and the gravity for handling organs/tumors, since the same surgical view under position changes can be established by the adjustments of laparoscope's positioning and rotation. That reduces compression on the liver during surgery. Our previous

Table 1 Summary of previous reports of repeat laparoscopic liver resection

<i>n</i>	Disease	Previous LR (open:lap)	Procedure	Bleeding (mL)	Operating time (min)	Conversion (<i>n</i>)	Postoperative hospital stay (d)	Morbidity	Mortality	Ref.
12	HCC	4:8	LLS (<i>n</i> = 5), Pt (<i>n</i> = 4), Seg (<i>n</i> = 3)	297 ± 134 272.2 ± 120	114.4 ± 11.0 63.9 ± 13.3	1	7.4 ± 2.5 6.2 ± 3.0	26.60%	0%	[20]
2	Met	ND	ND	ND	ND	ND	ND	ND	ND	[21]
6	HCC	(Lap RFA, <i>n</i> = 2)	LLS (<i>n</i> = 2), Pt (<i>n</i> = 4)	283.3 ± 256.3	140.8 ± 35.7	0	5.67 ± 1.63	16.7%	0%	[24]
76	Met (<i>n</i> = 63), HCC (<i>n</i> = 3), others (<i>n</i> = 10)	28:44	LLS (<i>n</i> = 4), Pt, seg (<i>n</i> = 53), above-seg (<i>n</i> = 19)	300 (0–5000)	180 (80–570)	8	6 (2–42)	26%	0%	[23]
4	HCC (<i>n</i> = 3), Met (<i>n</i> = 1)	0:4	LLS (<i>n</i> = 1), Pt (<i>n</i> = 3)	481.7 ± 449.5	312.3 ± 158.4	1	10.6 ± 7.4	23.4%	0%	[22]
3	HCC	0:3	ND	281.3 (mean)	264.6 (mean)	0	8.6 (mean)		0%	[26]
17	ND	ND	ND	ND	ND	ND	ND	ND	ND	[25]
20	HCC	15:5	Pt	78 (1–1500)	239 (69–658)	2 (HALS)	9 (5–22)	5%	0%	[27]
20	HCC (<i>n</i> = 2), Met (<i>n</i> = 16), others (<i>n</i> = 2)	0:20	Minor (<i>n</i> = 14), major (<i>n</i> = 6)	400 (IQR 150–200 mL)	285 (IQR 195–360)	3	4 (1–57)	10%	0%	[30]
12	HCC (<i>n</i> = 8), Met (<i>n</i> = 2), others (<i>n</i> = 2)	8:4	Pt (<i>n</i> = 9), Subseg (<i>n</i> = 3)	50 (NC–840)	301 (104–570)	0	12 (9–30)	0%	0%	[29]
11	HCC	6:5	LLS = 2 Subseg = 9	100 (50–500)	200 (131–352)	0	6 (3–17)	18.2%	0%	[33]
27	Met	ND	Major = 25 Minor = 2	ND (4 patients received transfusion)	252.5 (180–300)	1	9 (IQR 8–18)	48.1%	0%	[32]
8	HCC	6:2	Sec = 2 Seg = 2 Subseg = 4	200 (30–5000)	343 (120–530)	1	3.5 (3–8)	12.5%	0%	[31]
20	HCC (<i>n</i> = 15) Met (<i>n</i> = 5)	12:8	Anatomical = 1 Non-anatomical = 19	159 +/- 256	225 +/- 85	1	14.2 +/- 5.4	0%	0%	[19]
33	HCC and combined (<i>n</i> = 18) Met (<i>n</i> = 15)	21:12	Anatomical = 11 Non-anatomical = 22	30 (NC–1012)	217 (43–356)	0	6.5 (3–47)	6.1%	3%	[18]

Data are expressed as median (range) or mean ± SD, unless stated otherwise. In the paper from Belli, operation time, bleeding and postoperative hospital stay are described separately for patients whose previous hepatectomy was open (upper) or laparoscopic (lower). LLR: Laparoscopic liver resection; LR: Liver resection; HCC: Hepatocellular carcinoma; LLS: Left lateral sectorectomy; Met: Metastasis; Minor: Resection of 2 segments or less; Major: Resection of 3 segments or more; ND: Not documented; Pt: Partial resection; Sec: Sectionectomy; Seg: Segmentectomy; Subseg: Subsegmentectomy; IQR: Interquartile range; NC: Not countable.

report of the caudal approach posterior sectionectomy in the left lateral position^[36] posed the novel concept of “caudal approach” in LLR. Although the supine to semi-lateral positioning had been employed for the other resections, the transection plane of posterior sectionectomy was horizontal and gravity obstructs the exposure of the plane in the supine position. A clear view from the caudal direction and an easy access to postural changes is among the advantages of LLR (Figure 1). We perform parenchymal transection prior to mobilization in the left lateral position for laparoscopic posterior sectionectomy. It facilitates exposure of the cutting plane during the transection in caudal-to-cranial one direction. The transection plane is well-op-

ened between the retroperitoneal-fixed posterior section and the remnant liver falling down to left by gravity. Moreover, the resection of segment(s) 7 should be performed in the deeper and smaller cranial subphrenic space and S6 is an obstacle under the laparoscopic caudal view even in the left lateral position. Semi-prone position with only partial dissection of the retroperitoneum is employed for those resections^[39]. Our key aim in LLR is to carry out minimal dissection around the liver with the intrusion and manipulation of laparoscope and forceps to the small target area under postural changes. In the same context, repeat LLR requires smaller (than open) working space between adhesions. Direct approach to the tumor after

Table 2 The summary of present status and future perspectives of repeat laparoscopic liver resection**Present status**

There are 16 reports of small series. Controversy still exists in the indication of repeat LLR
 These studies generally reported that it has better short-term outcomes without compromising the long-term outcomes (similar or longer operation time, reduces bleedings, reduced blood transfusion rate, less or similar morbidity and shorter hospital stay)
 It facilitates more meticulous dissection of adhesions strained by the pneumoperitoneum using magnified laparoscopic view
 Complete adhesiolysis can be avoided when the adhesion does not affect the current operative procedure
 Operation time was shorter and the adhesiolysis was easier for the patients previously treated with LLR than open LR
 It requires smaller (than open) working space between adhesions (this fact allows for minimal adhesiolysis, and operation time and bleeding amount were similar in primary and repeat LLR, although those from open LR are longer and increased)

Future perspectives

Further evaluations of anatomical resection or resections exposing major vessels after previous anatomical resection are needed
 One of the possible advantages for minor repeat LR of CLD liver is that the deterioration of liver function can be minimized
 It could prolong the overall survival of the HCC patients with CLD as a powerful local therapy which can be applied repeatedly with minimal deterioration of liver function

LLR: Laparoscopic liver resection; LR: Liver resection; HCC: Hepatocellular carcinoma; CLD: Chronic liver disease.

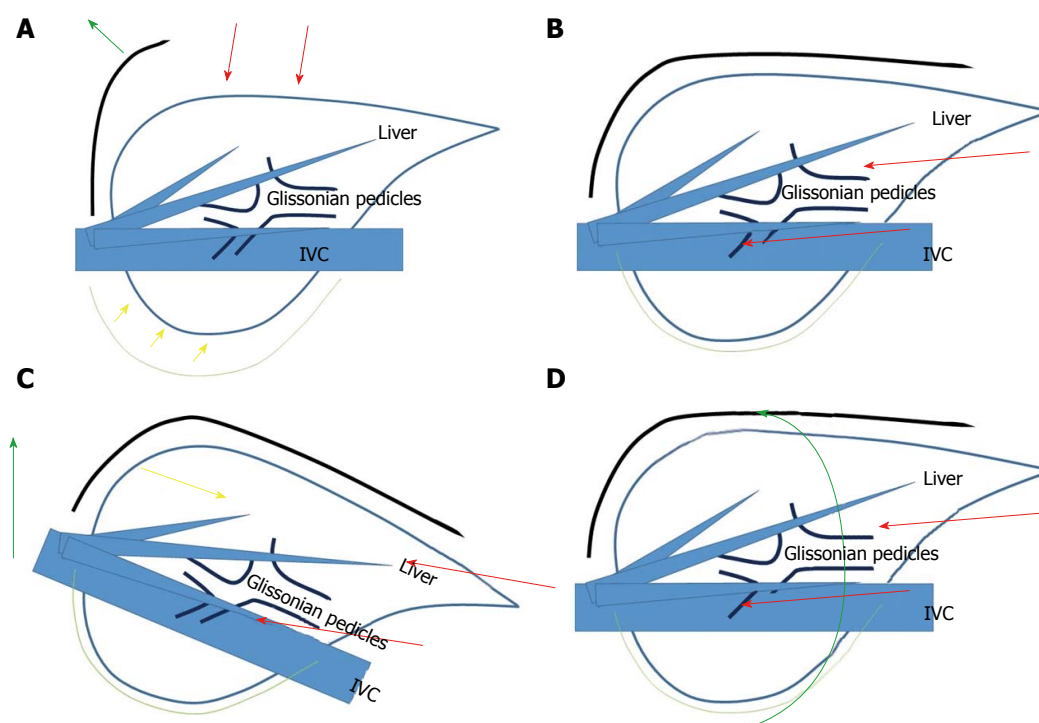


Figure 1 Schema of open liver resection (A), laparoscopic liver resection (B), position change in laparoscopic liver resection (tilting the bed for head-up position, C) and position change in laparoscopic liver resection (rotation from supine to semi-prone position, D). Red arrows indicate the directions of the view and manipulation in each approach. A: In the open approach, the subcostal cage containing the liver is opened with a large subcostal incision, and instruments are used to lift the costal arch up. The liver is dissected and mobilized (picked up) from the retroperitoneum; B: In the laparoscopic caudal approach, the laparoscope and forceps are placed into the subcostal cage from caudal direction, and surgery is performed with minimal alteration and destruction of the associated structures; C and D: In the laparoscopic approach, the same surgical view under position changes (tilting the bed and rotation of the patient's body), acquired by the adjustments of laparoscope's positioning and rotation, allows for handling large-volume liver/tumor by postural changes.

minimal adhesiolysis for the space where laparoscope and forceps can intrude and do manipulation can be allowed especially in repeat small LLR^[23,24,29]. That is why some studies showed that operation time and bleeding amount were similar in primary and repeat LLR^[18,29]. The operation time and blood loss are usually much longer and larger in open repeat than open primary LR. Operation time and bleeding amount of repeat partial resection could be reduced under laparoscopic approach.

OUR EXPERIENCES AND FUTURE PERSPECTIVES OF REPEAT LLR

Most reported cases of repeat LLR underwent minor resection of HCC with CLD, as mentioned above. The impact of alterations from the previous surgery on hepatic parenchyma and intrahepatic structure could be smaller in such cases. There were three repeat cases with anatomical resection or resections exposing major vessels (including S8 segmentectomy after

4-times LLR^[40]) after previous anatomical resection who developed bile leakage and > 30 d hospital stay, among our 33 repeat and 12 three or more-time repeat LLR cases. Anatomical alterations surrounded by the scars and adhesions on major vessel structures could have big impacts on subsequent anatomical resection or resections exposing major vessels, experiences and evaluations of such setting of repeat LLR are required for the settlement (Table 2).

REFERENCES

- Petrowsky H**, Gonen M, Jarnagin W, Lorenz M, DeMatteo R, Heinrich S, Encke A, Blumgart L, Fong Y. Second liver resections are safe and effective treatment for recurrent hepatic metastases from colorectal cancer: a bi-institutional analysis. *Ann Surg* 2002; **235**: 863-871 [PMID: 12035044 DOI: 10.1097/0000658-200206000-00015]
- Wanebo HJ**, Chu QD, Avradopoulos KA, Veziridis MP. Current perspectives on repeat hepatic resection for colorectal carcinoma: a review. *Surgery* 1996; **119**: 361-371 [PMID: 8643998 DOI: 10.1016/S0039-6060(96)80133-4]
- Morise Z**, Sugioka A, Fujita J, Hoshimoto S, Kato T, Hasumi A, Suda T, Negi H, Hattori Y, Sato H, Maeda K. Does repeated surgery improve the prognosis of colorectal liver metastases? *J Gastrointest Surg* 2006; **10**: 6-11 [PMID: 16368485 DOI: 10.1016/j.gassur.2005.09.006]
- Itamoto T**, Nakahara H, Amano H, Kohashi T, Ohdan H, Tashiro H, Asahara T. Repeat hepatectomy for recurrent hepatocellular carcinoma. *Surgery* 2007; **141**: 589-597 [PMID: 17462458 DOI: 10.1016/j.surg.2006.12.014]
- Nguyen KT**, Gamblin TC, Geller DA. World review of laparoscopic liver resection-2,804 patients. *Ann Surg* 2009; **250**: 831-841 [PMID: 19801936 DOI: 10.1097/SLA.0b013e3181b0c4df]
- Buell JF**, Thomas MT, Rudich S, Marvin M, Nagubandi R, Ravindra KV, Brock G, McMasters KM. Experience with more than 500 minimally invasive hepatic procedures. *Ann Surg* 2008; **248**: 475-486 [PMID: 18791368 DOI: 10.1097/SLA.0b013e318185e647]
- Wakabayashi G**, Cherqui D, Geller DA, Buell JF, Kaneko H, Han HS, Asbun H, O'Rourke N, Tanabe M, Koffron AJ, Tsung A, Soubrane O, Machado MA, Gayet B, Troisi RI, Pessaux P, Van Dam RM, Scatton O, Abu Hilal M, Belli G, Kwon CH, Edwin B, Choi GH, Aldrighetti LA, Cai X, Cleary S, Chen KH, Schön MR, Sugioka A, Tang CN, Herman P, Pekolj J, Chen XP, Dagher I, Jarnagin W, Yamamoto M, Strong R, Jagannath P, Lo CM, Clavien PA, Kokudo N, Barkun J, Strasberg SM. Recommendations for laparoscopic liver resection: a report from the second international consensus conference held in Morioka. *Ann Surg* 2015; **261**: 619-629 [PMID: 25742461 DOI: 10.1097/SLA.0000000000001184]
- Morise Z**, Wakabayashi G. First quarter century of laparoscopic liver resection. *World J Gastroenterol* 2017; **23**: 3581-3588 [PMID: 28611511 DOI: 10.3748/wjg.v23.i20.3581]
- Buell JF**, Thomas MJ, Doty TC, Gersin KS, Merchen TD, Gupta M, Rudich SM, Woodle ES. An initial experience and evolution of laparoscopic hepatic resectional surgery. *Surgery* 2004; **136**: 804-811 [PMID: 15467665 DOI: 10.1016/j.surg.2004.07.002]
- Vibert E**, Perniceni T, Levard H, Denet C, Shahri NK, Gayet B. Laparoscopic liver resection. *Br J Surg* 2006; **93**: 67-72 [PMID: 16273531 DOI: 10.1002/bjs.5150]
- Beck DE**, Ferguson MA, Opelka FG, Fleshman JW, Gervaz P, Wexner SD. Effect of previous surgery on abdominal opening time. *Dis Colon Rectum* 2000; **43**: 1749-1753 [PMID: 11156462 DOI: 10.1007/BF02236862]
- Karayiannakis AJ**, Polychronidis A, Perente S, Botaitis S, Simopoulos C. Laparoscopic cholecystectomy in patients with previous upper or lower abdominal surgery. *Surg Endosc* 2004; **18**: 97-101 [PMID: 14569455 DOI: 10.1007/s00464-003-9001-4]
- Wiebke EA**, Pruitt AL, Howard TJ, Jacobson LE, Broadie TA, Goulet RJ Jr, Canal DF. Conversion of laparoscopic to open cholecystectomy. An analysis of risk factors. *Surg Endosc* 1996; **10**: 742-745 [PMID: 8662431 DOI: 10.1007/BF00193048]
- Wu JM**, Lin HF, Chen KH, Tseng LM, Tsai MS, Huang SH. Impact of previous abdominal surgery on laparoscopic appendectomy for acute appendicitis. *Surg Endosc* 2007; **21**: 570-573 [PMID: 17103279 DOI: 10.1007/s00464-006-9027-5]
- Law WL**, Lee YM, Chu KW. Previous abdominal operations do not affect the outcomes of laparoscopic colorectal surgery. *Surg Endosc* 2005; **19**: 326-330 [PMID: 15624064 DOI: 10.1007/s00464-004-8114-8]
- Nunobe S**, Hiki N, Fukunaga T, Tokunaga M, Ohyama S, Seto Y, Yamaguchi T. Previous laparotomy is not a contraindication to laparoscopy-assisted gastrectomy for early gastric cancer. *World J Surg* 2008; **32**: 1466-1472 [PMID: 18340481 DOI: 10.1007/s00268-008-9542-8]
- Szomstein S**, Lo Menzo E, Simpfendorfer C, Zundel N, Rosenthal RJ. Laparoscopic lysis of adhesions. *World J Surg* 2006; **30**: 535-540 [PMID: 16555020 DOI: 10.1007/s00268-005-7778-0]
- Ome Y**, Hashida K, Yokota M, Nagahisa Y, Yamaguchi K, Okabe M, Kawamoto K. The feasibility and efficacy of pure laparoscopic repeat hepatectomy. *Surg Endosc* 2018 [PMID: 29344784 DOI: 10.1007/s00464-018-6066-7]
- Noda T**, Eguchi H, Wada H, Iwagami Y, Yamada D, Asaoka T, Gotoh K, Kawamoto K, Takeda Y, Tanemura M, Umehita K, Doki Y, Mori M. Short-term surgical outcomes of minimally invasive repeat hepatectomy for recurrent liver cancer. *Surg Endosc* 2018; **32**: 46-52 [PMID: 28639044 DOI: 10.1007/s00464-017-5632-8]
- Belli G**, Cioffi L, Fantini C, D'Agostino A, Russo G, Limongelli P, Belli A. Laparoscopic redo surgery for recurrent hepatocellular carcinoma in cirrhotic patients: feasibility, safety, and results. *Surg Endosc* 2009; **23**: 1807-1811 [PMID: 19277781 DOI: 10.1007/s00464-009-0344-3]
- Nguyen KT**, Laurent A, Dagher I, Geller DA, Steel J, Thomas MT, Marvin M, Ravindra KV, Mejia A, Lainas P, Franco D, Cherqui D, Buell JF, Gamblin TC. Minimally invasive liver resection for metastatic colorectal cancer: a multi-institutional, international report of safety, feasibility, and early outcomes. *Ann Surg* 2009; **250**: 842-848 [PMID: 19806058 DOI: 10.1097/SLA.0b013e3181bc789c]
- Ahn KS**, Han HS, Yoon YS, Cho JY, Kim JH. Laparoscopic liver resection in patients with a history of upper abdominal surgery. *World J Surg* 2011; **35**: 1333-1339 [PMID: 21452069 DOI: 10.1007/s00268-011-1073-z]
- Shafae Z**, Kazaryan AM, Marvin MR, Cannon R, Buell JF, Edwin B, Gayet B. Is laparoscopic repeat hepatectomy feasible? A tri-institutional analysis. *J Am Coll Surg* 2011; **212**: 171-179 [PMID: 21276531 DOI: 10.1016/j.jamcollsurg.2010.10.012]
- Hu M**, Zhao G, Xu D, Liu R. Laparoscopic repeat resection of recurrent hepatocellular carcinoma. *World J Surg* 2011; **35**: 648-655 [PMID: 21184074 DOI: 10.1007/s00268-010-0919-0]
- Cannon RM**, Brock GN, Marvin MR, Buell JF. Laparoscopic liver resection: an examination of our first 300 patients. *J Am Coll Surg* 2011; **213**: 501-507 [PMID: 21624840 DOI: 10.1016/j.jamcollsurg.2011.04.032]
- Tsuchiya M**, Otsuka Y, Maeda T, Ishii J, Tamura A, Kaneko H. Efficacy of laparoscopic surgery for recurrent hepatocellular carcinoma. *Hepatogastroenterology* 2012; **59**: 1333-1337 [PMID: 22591625 DOI: 10.5754/hge12302]
- Kanazawa A**, Tsukamoto T, Shimizu S, Kodai S, Yamamoto S, Yamazoe S, Ohira G, Nakajima T. Laparoscopic liver resection for treating recurrent hepatocellular carcinoma. *J Hepatobiliary Pancreat Sci* 2013; **20**: 512-517 [PMID: 23404252 DOI: 10.1007/s00534-012-0592-9]
- Montalti R**, Berardi G, Laurent S, Sebastiani S, Ferdinando L, Libbrecht LJ, Smeets P, Brescia A, Rogiers X, de Hemptinne B, Geboes K, Troisi RI. Laparoscopic liver resection compared to open approach in patients with colorectal liver metastases improves further resectability: Oncological outcomes of a case-control matched-pairs analysis. *Eur J Surg Oncol* 2014; **40**: 536-544 [PMID: 24555996 DOI: 10.1016/j.ejso.2014.01.005]
- Isetani M**, Morise Z, Kawabe N, Tomishige H, Nagata H, Kawase

- J, Arakawa S. Pure laparoscopic hepatectomy as repeat surgery and repeat hepatectomy. *World J Gastroenterol* 2015; **21**: 961-968 [PMID: 25624731 DOI: 10.3748/wjg.v21.i3.961]
- 30 **Shelat VG**, Serin K, Samim M, Besselink MG, Al Saati H, Gioia PD, Pearce NW, Abu Hilal M. Outcomes of repeat laparoscopic liver resection compared to the primary resection. *World J Surg* 2014; **38**: 3175-3180 [PMID: 25138071 DOI: 10.1007/s00268-014-2728-3]
- 31 **Goh BKP**, Teo JY, Chan CY, Lee SY, Cheow PC, Chung AYY. Laparoscopic repeat liver resection for recurrent hepatocellular carcinoma. *ANZ J Surg* 2017; **87**: E143-E146 [PMID: 27117542 DOI: 10.1111/ans.13628]
- 32 **Hallet J**, Sa Cunha A, Cherqui D, Gayet B, Goéré D, Bachellier P, Laurent A, Fuks D, Navarro F, Pessaux P; French Colorectal Liver Metastases Working Group, Association Française de Chirurgie. Laparoscopic Compared to Open Repeat Hepatectomy for Colorectal Liver Metastases: a Multi-institutional Propensity-Matched Analysis of Short- and Long-Term Outcomes. *World J Surg* 2017; **41**: 3189-3198 [PMID: 28717911 DOI: 10.1007/s00268-017-4119-z]
- 33 **Chan AC**, Poon RT, Chok KS, Cheung TT, Chan SC, Lo CM. Feasibility of laparoscopic re-resection for patients with recurrent hepatocellular carcinoma. *World J Surg* 2014; **38**: 1141-1146 [PMID: 24305932 DOI: 10.1007/s00268-013-2380-3]
- 34 **Morise Z**, Sugioka A, Kawabe N, Umemoto S, Nagata H, Ohshima H, Kawase J, Arakawa S, Yoshida R. Pure laparoscopic hepatectomy for hepatocellular carcinoma patients with severe liver cirrhosis. *Asian J Endosc Surg* 2011; **4**: 143-146 [PMID: 22776279 DOI: 10.1111/j.1758-5910.2011.00081.x]
- 35 **Morise Z**, Ciria R, Cherqui D, Chen KH, Belli G, Wakabayashi G. Can we expand the indications for laparoscopic liver resection? A systematic review and meta-analysis of laparoscopic liver resection for patients with hepatocellular carcinoma and chronic liver disease. *J Hepatobiliary Pancreat Sci* 2015; **22**: 342-352 [PMID: 25663288 DOI: 10.1002/jhbp.215]
- 36 **Tomishige H**, Morise Z, Kawabe N, Nagata H, Ohshima H, Kawase J, Arakawa S, Yoshida R, Isetani M. Caudal approach to pure laparoscopic posterior sectionectomy under the laparoscopy-specific view. *World J Gastrointest Surg* 2013; **5**: 173-177 [PMID: 23977419 DOI: 10.4240/wjgs.v5.i6.173]
- 37 **Soubrane O**, Schwarz L, Cauchy F, Perotto LO, Brustia R, Bernard D, Scatton O. A Conceptual Technique for Laparoscopic Right Hepatectomy Based on Facts and Oncologic Principles: The Caudal Approach. *Ann Surg* 2015; **261**: 1226-1231 [PMID: 24854453 DOI: 10.1097/SLA.0000000000000737]
- 38 **Wakabayashi G**, Cherqui D, Geller DA, Han HS, Kaneko H, Buell JF. Laparoscopic hepatectomy is theoretically better than open hepatectomy: preparing for the 2nd International Consensus Conference on Laparoscopic Liver Resection. *J Hepatobiliary Pancreat Sci* 2014; **21**: 723-731 [PMID: 25130985 DOI: 10.1002/jhbp.139]
- 39 **Morise Z**. Laparoscopic liver resection for posterosuperior tumors using caudal approach and postural changes: A new technical approach. *World J Gastroenterol* 2016; **22**: 10267-10274 [PMID: 28058008 DOI: 10.3748/wjg.v22.i47.10267]
- 40 **Morise Z**, Isetani M, Kawabe N, Tomishige H, Nagata H, Arakawa S, Ikeda M, Kamio K. Case report of the fourth laparoscopic liver resection and review of repeat laparoscopic resection for recurrent hepatocellular carcinoma in cirrhotic liver. *Hepatoma Res* 2016; **2**: 253-258 [DOI: 10.20517/2394-5079.2016.09]

P- Reviewer: Aurello P, Bian AZL, Donadon M **S- Editor:** Ji FF

L- Editor: A **E- Editor:** Tan WW





Published by **Baishideng Publishing Group Inc**
7901 Stoneridge Drive, Suite 501, Pleasanton, CA 94588, USA
Telephone: +1-925-223-8242
Fax: +1-925-223-8243
E-mail: bpgoffice@wjgnet.com
Help Desk: <http://www.f6publishing.com/helpdesk>
<http://www.wjgnet.com>

