



ALL

IMAGES

VIDEOS

39,200 Results

Any time ▾

Open links in new tab



## Coronary fistulas can develop collateral vessels ...

<https://www.ncbi.nlm.nih.gov/pubmed/21297210>

Coronary fistulas can develop collateral vessels: angiographic follow-up of an embolized giant right coronary artery-superior vena cava fistula in a patient with variant angina. Ilhan E(1), Sahin S, Celebi A.

Cited by: 1

Author: Erkan Ilhan, Sinan Sahin, Ahmet Celebi

Publish Year: 2011

## [Transitory appearance of collateral circulation during ...

<https://www.ncbi.nlm.nih.gov/pubmed/6439165>

Coronary angiography showed an important, transient collateral system arising from the left coronary artery, probably minimising the effects of complete occlusion of a dominant right coronary artery. The...

Cited by: 2

Author: Grollier G, Commeau P, Iselin M, Hiance ...

Publish Year: 1984

## Coronary Collaterals | Circulation

<https://www.ahajournals.org/doi/full/10.1161/01.cir.0000065118.99409.5f>



Coronary Collateral Circulati...

Risk Factors, Trigger Factors,...

Determina



Coronary collaterals, or "natural bypasses," are anastomotic connections without an intervening capillary bed between portions of the same coronary artery and between different coronary arteries (Figure 1).<sup>1</sup> Collateral circulation potentially offers an important alternative source of blood supply when the original vessel fails to provide sufficient blood.<sup>2</sup> Timely enlargement of collaterals may even avoid transmural myocardial infarction (MI) and death in symptomatic patients.<sup>3</sup> As early as in 1956, Baroldi et al.

See more on [ahajournals.org](https://www.ahajournals.org)

## Single right coronary artery with right ventricular ...

<https://pubmed.ncbi.nlm.nih.gov/31486350>

We report an extremely rare case of a 14-month-old girl who was diagnosed with a single right coronary artery with coronary artery fistula communicating with the right ventricle and congenital...

Cited by: 1

Author: Tamer Yoldaş, Meryem Beyazal, Utku A ...

Publish Year: 2019

**Name of Journal:** *World Journal of Clinical Cases*

**Manuscript NO:** 66503

**Manuscript Type:** CASE REPORT

**Intermittent appearance of right coronary fistula and collateral circulation: A case report**

Long WJ *et al.* Right coronary fistula and collateral circulation

Wen-Jie Long, Xi Huang, Yuan-Hong Lu, Hao-Ming Huang, Guo-Wei Li, Xia Wang, Zhi-Ling He

**Abstract**

BACKGROUND

## Match Overview

- |   |   |    |
|---|---|----|
| 1 | <b>Internet</b> 16 words<br>crawled on 16-Oct-2020<br><a href="http://www.wjgnet.com">www.wjgnet.com</a>  | 1% |
| 2 | <b>Crossref</b> 15 words<br>Upshaw, C.B.. "Congenital coronary arteriovenous fistula r ...<br>port of a case with an analysis of seventy-three reported cas | 1% |
| 3 | <b>Crossref</b> 14 words<br>Hyeon Seong Kim, Ji Won Jung, You Jin Jung, Young Suck<br>Ro, Si-Bog Park, Kyu Hoon Lee. "Complete recovery of he ...           | 1% |



ALL

IMAGES

VIDEOS

80,900 Results

Any time ▾

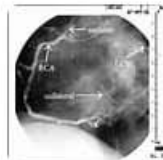
## Coronary Collaterals | Circulation

<https://www.ahajournals.org/doi/full/10.1161/01.cir.0000065118.99409.5f>

**Coronary Collateral Circulation:...**

Risk Factors, Trigger Factors, a...

Determinant: &gt;



**Coronary collaterals**, or “natural bypasses,” are anastomotic connections without an intervening capillary bed between portions of the same coronary artery and between different coronary arteries (Figure 1).<sup>1</sup> Collateral circulation potentially offers an important alternative source of blood supply when the original vessel fails to provide sufficient blood.<sup>2</sup> Timely enlargement of **collaterals** may even avoid transmural myocar...

[See more on ahajournals.org](https://www.ahajournals.org)

## Coronary Artery Fistulas: Pathophysiology, Imaging ...

<https://pubs.rsna.org/doi/full/10.1148/rg.2018170158>

Mar 30, 2018 · When a dilated **coronary** sinus is noted, both the presence of a **coronary** artery **fistula** and other causes of **coronary** sinus dilatation should be considered in the differential diagnoses. The other causes include unroofed **coronary** sinus, anomalous pulmonary venous return, and tricuspid valve abnormalities, which cause a left-to-**right** shunt ( 53 ).

**Cited by:** 27

**Author:** Gabin Yun, Tae Hyun Nam, Eun Ju Chun

**Publish Year:** 2018

## Coronary Collateral Flow after Traumatic Fistula between ...