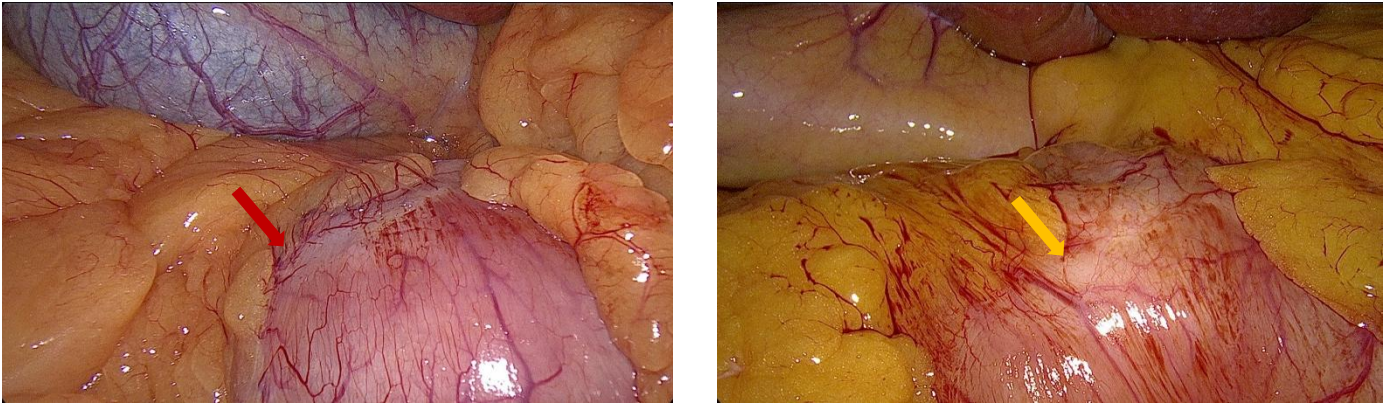


## Supplementary Material



Supplementary Figure 1: Intraoperative laparoscopic photographs showing two scenarios of anatomical landmark A localization. A: Clearly identifiable pre-pyloric vein (red arrow) as landmark A; B: Indistinct pre-pyloric vein, with the pyloric ring (yellow arrow) as landmark A.