

# World Journal of *Clinical Cases*

*World J Clin Cases* 2019 July 6; 7(13): 1535-1731





### REVIEW

- 1535 Intracranial pressure monitoring: Gold standard and recent innovations

*Nag DS, Sahu S, Swain A, Kant S*

- 1554 Role of the brain-gut axis in gastrointestinal cancer

*Di YZ, Han BS, Di JM, Liu WY, Tang Q*

### MINIREVIEWS

- 1571 Cholestatic liver diseases: An era of emerging therapies

*Samant H, Manatsathit W, Dies D, Shokouh-Amiri H, Zibari G, Boktor M, Alexander JS*

### ORIGINAL ARTICLE

#### Basic Study

- 1582 Neural metabolic activity in idiopathic tinnitus patients after repetitive transcranial magnetic stimulation

*Kan Y, Wang W, Zhang SX, Ma H, Wang ZC, Yang JG*

#### Retrospective Study

- 1591 Neuroendoscopic and microscopic transsphenoidal approach for resection of nonfunctional pituitary adenomas

*Ding ZQ, Zhang SF, Wang QH*

- 1599 Safety and efficacy of transjugular intrahepatic portosystemic shunt combined with palliative treatment in patients with hepatocellular carcinoma

*Luo SH, Chu JG, Huang H, Yao KC*

- 1611 Leveraging machine learning techniques for predicting pancreatic neuroendocrine tumor grades using biochemical and tumor markers

*Zhou RQ, Ji HC, Liu Q, Zhu CY, Liu R*

#### Clinical Trials Study

- 1623 Development and validation of a model to determine risk of refractory benign esophageal strictures

*Lu Q, Lei TT, Wang YL, Yan HL, Lin B, Zhu LL, Ma HS, Yang JL*

### SYSTEMATIC REVIEWS

- 1634 Hydatid cyst of the colon: A systematic review of the literature

*Lataat-Córdoba MÁ, Ruiz-Blanco S, Sanchez M, Santiago-Boyer C, Soto-García P, Sun W, Ramia JM*

## CASE REPORT

- 1643** Colon cancer arising from colonic diverticulum: A case report  
*Kayano H, Ueda Y, Machida T, Hiraiwa S, Zakoji H, Tajiri T, Mukai M, Nomura E*
- 1652** Endoscopic submucosal dissection as excisional biopsy for anorectal malignant melanoma: A case report  
*Manabe S, Boku Y, Takeda M, Usui F, Hirata I, Takahashi S*
- 1660** Gastrointestinal infection-related disseminated intravascular coagulation mimicking Shiga toxin-mediated hemolytic uremic syndrome - implications of classical clinical indexes in making the diagnosis: A case report and literature review  
*Li XY, Mai YF, Huang J, Pai P*
- 1671** A complicated case of innominate and right common arterial aneurysms due to Takayasu's arteritis  
*Wang WD, Sun R, Zhou MX, Liu XR, Zheng YH, Chen YX*
- 1677** Multimodality-imaging manifestations of primary renal-allograft synovial sarcoma: First case report and literature review  
*Xu RF, He EH, Yi ZX, Lin J, Zhang YN, Qian LX*
- 1686** Chronic progression of recurrent orthokeratinized odontogenic cyst into squamous cell carcinoma: A case report  
*Wu RY, Shao Z, Wu TF*
- 1696** Gastric adenocarcinoma of fundic gland type after *Helicobacter pylori* eradication: A case report  
*Yu YN, Yin XY, Sun Q, Liu H, Zhang Q, Chen YQ, Zhao QX, Tian ZB*
- 1703** Synchronous multiple primary gastrointestinal cancers with *CDH1* mutations: A case report  
*Hu MN, Lv W, Hu RY, Si YF, Lu XW, Deng YJ, Deng H*
- 1711** Primary hepatoid adenocarcinoma of the lung in Yungui Plateau, China: A case report  
*Shi YF, Lu JG, Yang QM, Duan J, Lei YM, Zhao W, Liu YQ*
- 1717** Liver failure associated with benzbromarone: A case report and review of the literature  
*Zhang MY, Niu JQ, Wen XY, Jin QL*
- 1726** Giant low-grade appendiceal mucinous neoplasm: A case report  
*Yang JM, Zhang WH, Yang DD, Jiang H, Yu L, Gao F*

**ABOUT COVER**

Editorial Board Member of *World Journal of Clinical Cases*, Hitoshi Hirose, MD, PhD, Associate Professor, Department of Cardiothoracic Surgery, Thomas Jefferson University, Philadelphia, PA 19107, United States

**AIMS AND SCOPE**

*World Journal of Clinical Cases* (*World J Clin Cases*, *WJCC*, online ISSN 2307-8960, DOI: 10.12998) is a peer-reviewed open access academic journal that aims to guide clinical practice and improve diagnostic and therapeutic skills of clinicians.

The primary task of *WJCC* is to rapidly publish high-quality Case Report, Clinical Management, Editorial, Field of Vision, Frontier, Medical Ethics, Original Articles, Meta-Analysis, Minireviews, and Review, in the fields of allergy, anesthesiology, cardiac medicine, clinical genetics, clinical neurology, critical care, dentistry, dermatology, emergency medicine, endocrinology, family medicine, gastroenterology and hepatology, etc.

**INDEXING/ABSTRACTING**

The *WJCC* is now indexed in PubMed, PubMed Central, Science Citation Index Expanded (also known as SciSearch®), and Journal Citation Reports/Science Edition. The 2019 Edition of Journal Citation Reports cites the 2018 impact factor for *WJCC* as 1.153 (5-year impact factor: N/A), ranking *WJCC* as 99 among 160 journals in Medicine, General and Internal (quartile in category Q3).

**RESPONSIBLE EDITORS FOR THIS ISSUE**

Responsible Electronic Editor: *Yan-Xia Xing*

Proofing Production Department Director: *Yun-Xiaojuan Wu*

**NAME OF JOURNAL**

*World Journal of Clinical Cases*

**ISSN**

ISSN 2307-8960 (online)

**LAUNCH DATE**

April 16, 2013

**FREQUENCY**

Semimonthly

**EDITORS-IN-CHIEF**

Dennis A Bloomfield, Sandro Vento

**EDITORIAL BOARD MEMBERS**

<https://www.wjnet.com/2307-8960/editorialboard.htm>

**EDITORIAL OFFICE**

Jin-Lei Wang, Director

**PUBLICATION DATE**

July 6, 2019

**COPYRIGHT**

© 2019 Baishideng Publishing Group Inc

**INSTRUCTIONS TO AUTHORS**

<https://www.wjnet.com/bpg/gerinfo/204>

**GUIDELINES FOR ETHICS DOCUMENTS**

<https://www.wjnet.com/bpg/GerInfo/287>

**GUIDELINES FOR NON-NATIVE SPEAKERS OF ENGLISH**

<https://www.wjnet.com/bpg/gerinfo/240>

**PUBLICATION MISCONDUCT**

<https://www.wjnet.com/bpg/gerinfo/208>

**ARTICLE PROCESSING CHARGE**

<https://www.wjnet.com/bpg/gerinfo/242>

**STEPS FOR SUBMITTING MANUSCRIPTS**

<https://www.wjnet.com/bpg/GerInfo/239>

**ONLINE SUBMISSION**

<https://www.f6publishing.com>

## Liver failure associated with benzbromarone: A case report and review of the literature

Ming-Yuan Zhang, Jun-Qi Niu, Xiao-Yu Wen, Qing-Long Jin

**ORCID number:** Ming-Yuan Zhang (0000-0003-0744-5945); Jun-Qi Niu (0000-0002-9857-6520); Xiao-Yu Wen (0000-0002-9037-8693); Qing-Long Jin (0000-0003-3486-2795).

**Author contributions:** Zhang MY was the patient's attending physician, and she contributed to the manuscript drafting and reviewed the literature; Niu JQ was responsible for the revision of the manuscript; Wen XY collected the patient's clinical data and contributed to the manuscript drafting; Jin QL designed the report and revised the manuscript; Wen XY and Jin QL are co-corresponding authors; all authors issued final approval for the version to be submitted.

**Informed consent statement:** The study was reviewed and approved by the First Hospital of Jilin University Institutional Review Board. The patient and his family were offered written explanations prior to the start of treatment, and they provided consent.

**Conflict-of-interest statement:** The authors declare that they have no conflicts of interest, and no additional data are available.

**CARE Checklist (2016) statement:** The authors have read the CARE Checklist (2016), and the manuscript was prepared and revised accordingly.

**Open-Access:** This article is an open-access article which was selected by an in-house editor and fully peer-reviewed by external reviewers. It is distributed in accordance with the Creative

Ming-Yuan Zhang, Jun-Qi Niu, Xiao-Yu Wen, Qing-Long Jin, Department of Hepatology, First Hospital of Jilin University, Changchun 130021, Jilin Province, China

**Corresponding author:** Qing-Long Jin, MD, PhD, Professor, Department of Hepatology, First Hospital of Jilin University, No. 71, Xinmin Street, Changchun 130021, Jilin Province, China. [jinqi@jlu.edu.cn](mailto:jinqi@jlu.edu.cn)

**Telephone:** +86-138-4410 9523

**Fax:** +86-431-88786006

### Abstract

#### BACKGROUND

Benzbromarone is a uricosuric agent that reduces proximal tubular reabsorption of uric acid. Because of hepatotoxicity, it has been withdrawn from the market in Europe. Recently, some benefit-risk assessments of benzbromarone suggest that benzbromarone has greater benefits than risks, and the application of benzbromarone in the treatment of gout and hyperuricemia is still under debate.

#### CASE SUMMARY

A 39-year-old man was admitted to the hospital for icterus and nausea, and he was treated with benzbromarone (100 mg/d) for 4 mo because of hyperuricemia. He had a 10-year history of beer drinking (alcohol: about 28 g/d). Laboratory data showed severe liver injury and serious coagulation dysfunction; tests for autoimmune antibodies, viral hepatitis, and human immunodeficiency virus were negative. Despite administration of liver function-protecting drugs and efficient supportive treatment, the patient deteriorated quickly after hospitalization and developed grade II encephalopathy within a few days. The patient accepted continuous plasma exchange six times; however, his condition did not improve. Based on suggestions from multidisciplinary consultation, the patient underwent liver transplantation 26 d after admission. Liver specimen pathology results showed massive necrosis consistent with drug-induced liver injury, supporting the diagnosis of acute liver failure associated with benzbromarone. The patient recovered quickly thereafter.

#### CONCLUSION

This case highlights that clinicians should be on the alert for the severe hepatotoxicity of benzbromarone. Before prescribing benzbromarone, physicians should evaluate the high-risk factors that may lead to liver injury and provide suggestions for monitoring benzbromarone's hepatotoxicity during treatment.

**Key words:** Benzbromarone; Hepatotoxicity; Liver failure; Liver transplantation; Case

Commons Attribution Non Commercial (CC BY-NC 4.0) license, which permits others to distribute, remix, adapt, build upon this work non-commercially, and license their derivative works on different terms, provided the original work is properly cited and the use is non-commercial. See: <http://creativecommons.org/licenses/by-nc/4.0/>

**Manuscript source:** Unsolicited manuscript

**Received:** March 15, 2019

**Peer-review started:** March 15, 2019

**First decision:** April 18, 2019

**Revised:** April 22, 2019

**Accepted:** May 2, 2019

**Article in press:** March 2, 2019

**Published online:** July 6, 2019

**P-Reviewer:** Garbuzenko DV, Pallav K, Singh S

**S-Editor:** Ji FF

**L-Editor:** Wang TQ

**E-Editor:** Wu YXJ



report

©The Author(s) 2019. Published by Baishideng Publishing Group Inc. All rights reserved.

**Core tip:** Here, we present a case of liver failure associated with benzbromarone. This is the ninth reported case associated with benzbromarone hepatotoxicity to date. We recommend that before prescribing, the benefits and risks of benzbromarone should be carefully evaluated. Additionally, an in-depth understanding of the relevant high-risk factors that may lead to liver injury and the prompt monitoring of hepatotoxicity of benzbromarone are essential.

**Citation:** Zhang MY, Niu JQ, Wen XY, Jin QL. Liver failure associated with benzbromarone: A case report and review of the literature. *World J Clin Cases* 2019; 7(13): 1717-1725

**URL:** <https://www.wjnet.com/2307-8960/full/v7/i13/1717.htm>

**DOI:** <https://dx.doi.org/10.12998/wjcc.v7.i13.1717>

## INTRODUCTION

Benzbromarone is a uricosuric agent that reduces proximal tubular reabsorption of uric acid. Due to reports of severe hepatotoxicity, the use of benzbromarone has been prohibited in European and American countries<sup>[1]</sup>; however, the use of benzbromarone is still allowed and frequently occurs in Asian countries<sup>[2]</sup>. In general, reports regarding its potentially severe hepatotoxicity are rare. Here, we report a case of liver failure associated with the use of benzbromarone followed by a comprehensive literature review. The search strategy involved searching for the keywords "benzbromarone", "liver injury", and "liver failure" in various data-bases; 33 results were retrieved from PubMed and Web of Science (the dates were from the launch of the databases to December 30, 2018). Additionally, we used the terms "benzbromarone", "liver failure", and "liver injury" in Chinese to search the China National Knowledge Infrastructure website, and three research studies (published between the launch of the database and December 30<sup>th</sup>, 2018) were retrieved. Further selection was performed by searching for reports that directly described the hepatotoxicity of benzbromarone, with eight studies selected (five in English, two in Chinese, and one in Japanese). In our literature review, we describe patient clinical features related to benzbromarone hepatotoxicity, combined with a benefit-risk assessment of benzbromarone. The results will provide additional evidence for evaluating the risk of selecting benzbromarone as a uricosuric drug and for monitoring hepatotoxicity during treatment in clinical practice.

## CASE PRESENTATION

### Chief complaints

A 39-year-old man was admitted to the hospital for icterus and nausea on July 3, 2018.

### History of present illness

Seven days before, he suffered from headache and vomiting and was deeply jaundiced.

### History of past illness

Four months before admission, he started treatment with benzbromarone (100 mg/d) due to hyperuricemia, but he stopped taking the drug because of the recent jaundice. He had no history of liver disease or other diseases.

### Personal and family history

The patient has a history of drinking beer for 10 years and consumes approximately 28 g of alcohol per day. There was no family medical history of note.

### Physical examination upon admission

Severe jaundice was found on the skin and sclera, and no signs of encephalopathy were found. The patient's temperature was 36.8 °C, heart rate was 90 bpm, respiratory rate was 18 breaths per minute, blood pressure was 112/77 mmHg, and oxygen



saturation was 98%. His body mass index was 23.7 kg/m<sup>2</sup>.

### Laboratory examinations

Laboratory indicators were as follows: Aspartate aminotransferase (AST), 170.6 U/L; alanine transaminase (ALT), 208.2 U/L;  $\gamma$ -glutamyltransferase (GGT), 76 U/L; alkaline phosphatase (ALP), 94.2 U/L; total bilirubin, 702.5  $\mu$ mol/L; direct bilirubin, 362.5  $\mu$ mol/L; albumin, 34.2 g/L; prothrombin time, 33.5 s; prothrombin time activity, 25%. Tests for viral hepatitis and human immunodeficiency virus were negative, and autoimmune antibody tests were negative. His blood ammonia level was 145  $\mu$ mol/L (normal value: 9–47  $\mu$ mol/L). Other laboratory data are provided in [Table 1](#).

### Imaging examinations

A computed tomography (CT) scan showed the following: The surface of the liver was irregular, the proportion of each part of the liver was not coordinated, the hilum and hepatic fissure were not wide, and the density of the liver parenchyma was slightly reduced; the intrahepatic bile duct was not dilated. Based on these findings, the patient was suspected of having liver cirrhosis ([Figure 1](#)).

### Further diagnostic work-up

The patient deteriorated quickly and developed grade II encephalopathy within a few days. We applied the RECUM criteria<sup>[3]</sup> to evaluate the possibility of drug-induced liver injury (DILI). The RECUM score of this patient was 9, which strongly indicated DILI, and the R value was 5.78, which indicated that this was a case of hepatocellular-type DILI.

## MULTIDISCIPLINARY EXPERT CONSULTATION

### *Ning Ma, MD, Department of Rheumatology, First Hospital of Jilin University*

Although there are reports about the hepatotoxicity of benzbromarone, severe liver failure due to this drug is rare, and the liver disease should be treated first. Treatment for gout should not be started under this condition.

### *Xiao-Dong Sun, MD, PhD, Associate Professor of Department of Hepatobiliary Surgery, First Hospital of Jilin University*

The patient is young, and his condition became worse in a relatively short time.

If there is no sign of improvement, liver transplantation should be considered.

### *Qing-Long Jin, MD, PhD, Professor of Department of Hepatology, First Hospital of Jilin University*

The patient should be registered for liver transplantation. Prior to the surgery, continuous plasma exchange (PE) with an artificial extracorporeal liver support system could be performed, and the best supporting treatment should be provided.

## FINAL DIAGNOSIS

The final diagnosis of the presented case was acute liver failure due to benzbromarone.

## TREATMENT

In addition to albumin and plasma infusion, adenosylmethionine and ornithine aspartate were administered to protect liver function. Additionally, ursodeoxycholic acid was provided orally, and continuous PE was performed six times. However, there was no improvement in the patient's laboratory indices or clinical symptoms ([Figure 2](#)). The patient agreed to register for liver transplantation, and he underwent liver surgery 26 d after admission. Liver specimen pathology revealed massive necrosis of liver tissue, cholestasis, and biliary duct hyperplasia ([Figure 3](#)). When consulting with the pathology experts, they inferred that the change in the liver on the CT scan might be due to massive necrosis of liver tissue, which caused the shape of the liver to become irregular and atrophic. Liver cirrhosis was not diagnosed in this patient.

**Table 1** Laboratory data on admission

Parameter	Result (normal value)	Parameter	Result (normal value)
AST (IU/L)	170.6 (15-40)	WBC ( $\times 10^9$ /L)	8.8 (3.5-9.5)
ALT (IU/L)	208.2 (9-50)	RBC ( $\times 10^9$ /L)	4.89 (4.3-5.8)
GGT (IU/L)	76 (10-60)	Hemoglobin (g/L)	152 (130-175)
ALP (IU/L)	94.2 (45-125)	Platelets ( $\times 10^9$ /L)	216 (125-350)
ACHE(IU/L)	5050 (4300-12000)	Eosinophils ( $\times 10^9$ /L)	0.1 (0.02-0.52)
TP (g/L)	52.7 (65-85)	Basophils ( $\times 10^9$ /L)	0.01 (0-0.06)
ALB (g/L)	34.2 (40-55)	Coagulation function	
GLB (g/L)	18.5 (20-40)	Prothrombin time (s)	33.5 (9.0-13.0)
TBIL ( $\mu$ mol/L)	702.5 (6.8-30)	INR	2.86 (0.80-1.20)
DBIL ( $\mu$ mol/L)	362.5 (0.0-8.6)	PTA (%)	25 (80-120)
IBIL ( $\mu$ mol/L)	340 (5.1-21.4)		
BUN (mmol/L)	1.64 (3.1-8)	Virology test	
CR ( $\mu$ mol/L)	64 (57-97)	Anti-HAV-IgM	- (-)
UA ( $\mu$ mol/L)	178 (208-428)	Anti-HEV-IgM	- (-)
CHOL (mmol/L)	3.52 (2.6-6.0)	HBsAg	- (-)
Immunological test		HBeAg	- (-)
Anti-dsDNA	- (-)	Anti-HBsAb	- (-)
Anti-gp210	- (-)	Anti-HBeAb	- (-)
Anti-M2	- (-)	Anti-HBcAb	+ (-)
Anti-SSA-52/Ro52	- (-)	Anti-HCV	- (-)
Anti-SP100	- (-)	Anti-HIV	- (-)
Anti-Sm	- (-)	Tumor marker	
Anti-nRNP/Sm	- (-)	$\alpha$ -fetoprotein (ng/mL)	82.86 (< 20)
Immunoglobulin G4	0.545 (0.03-2.01)	Thyroid function	
Immunoglobulin A	3.01 (0.7-4.0)	TSH (mIU/L)	1.62 (0.372-4.94)
Immunoglobulin G	12.6 (7.0-16)	FT3 (pmol/L)	5.35 (3.1-6.8)
Immunoglobulin M	0.86 (0.4-2.3)	FT4 (pmol/L)	32.9 (12.0-22.0)
Complement (C3)	0.58 (0.9-1.8)		

AST: Aspartate aminotransferase; ALT: Alanine aminotransferase; GGT:  $\gamma$ -glutamyltransferase; ALP: Alkaline phosphatase; ACHE: Acetylcholinesterase; TP: Total protein; ALB: Albumin; GLB: Globulin; TBIL: Total bilirubin; DBIL: Direct bilirubin; IBIL: Indirect bilirubin; BUN: Blood urea nitrogen; CR: Creatinine; UA: Uric acid; CHOL: Cholesterol; Anti-dsDNA: Anti-double strand DNA antibody; AMA M2: Anti-mitochondrial antibody M2; anti-Sm: Anti-smooth muscle antibody; WBC: White blood cells; RBC: Red blood cells; INR: International standard value; PTA: Prothrombin time activity; anti-HCV: Anti-hepatitis C virus antibody; anti-HIV: Anti-human immunodeficiency virus antibody; TSH: Thyroid-stimulating hormone; FT3: Free triiodothyronine; FT4: Free thyroxine; -: Negative; +: Positive.

## OUTCOME AND FOLLOW-UP

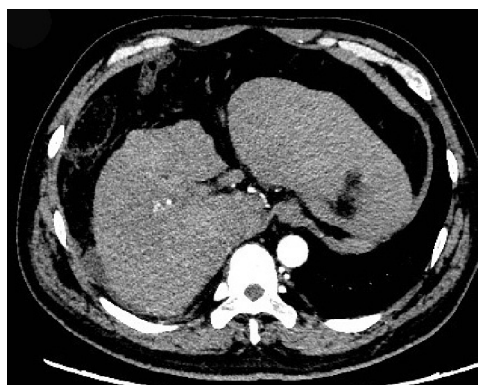
After liver transplantation, the patient recovered quickly, and jaundice and other symptoms, such as vomiting and headache, disappeared. Laboratory indicators were as follows: AST, 26.3 U/L; ALT, 72.2 U/L; GGT, 165.4 U/L; ALP, 77.2 U/L; total bilirubin, 25.9  $\mu$ mol/L; direct bilirubin, 13.1  $\mu$ mol/L; albumin, 31.8 g/L; prothrombin time, 12.4 s; prothrombin time activity, 85%. These indicators were markedly improved compared to the pre-transplantation levels. CT scanning showed a normal change after liver transplantation. The patient left the hospital 95 d after admission, on October 3, 2018, and remained well after 6 mo following transplantation.

## DISCUSSION

### Prevalence of gout and drug treatment

The prevalence of gout in the general population is 1%-4%, and the annual incidence is 2.68 per 1000 persons. The worldwide incidence of gout has gradually increased due to poor dietary habits, such as the consumption of fast food, lack of exercise, and





**Figure 1 Contrast-enhanced computed tomography image.** The liver volume decreased. Computed tomography showed an irregular shape of the surface, the proportion of each leaf was not coordinated, and the density of the hepatic parenchymal was variable.

increased incidence of obesity and metabolic syndrome<sup>[4]</sup>. Gout has an important effect on musculoskeletal function and health-related quality of life. Poorly controlled gout leads to absence from work, health care use, and reduced social participation<sup>[5]</sup>. Previous clinical and pathophysiological data have shown that lowering uricemia to under the saturation point is the best and most reliable way to control gout symptoms in the long term. The most commonly used urate-lowering drugs are allopurinol, febuxostat, uricosurics, and urate oxidases. Benzbromarone is a powerful uricosuric drug; however, after reports of several serious hepatotoxicities, benzbromarone was withdrawn by Sanofi in 2003. Nonetheless, it was still recommended in clinical guidelines for patients with mild/moderate renal impairment<sup>[5,6]</sup>. Currently, benzbromarone is mainly used in Japan, China, Singapore, and other Asian countries. In China, benzbromarone is mainly used for the treatment of gout and hyperuricemia in clinical practice<sup>[7]</sup>. Thus far, most published hepatotoxicity cases due to benzbromarone have been reported in Asian countries (Figure 4).

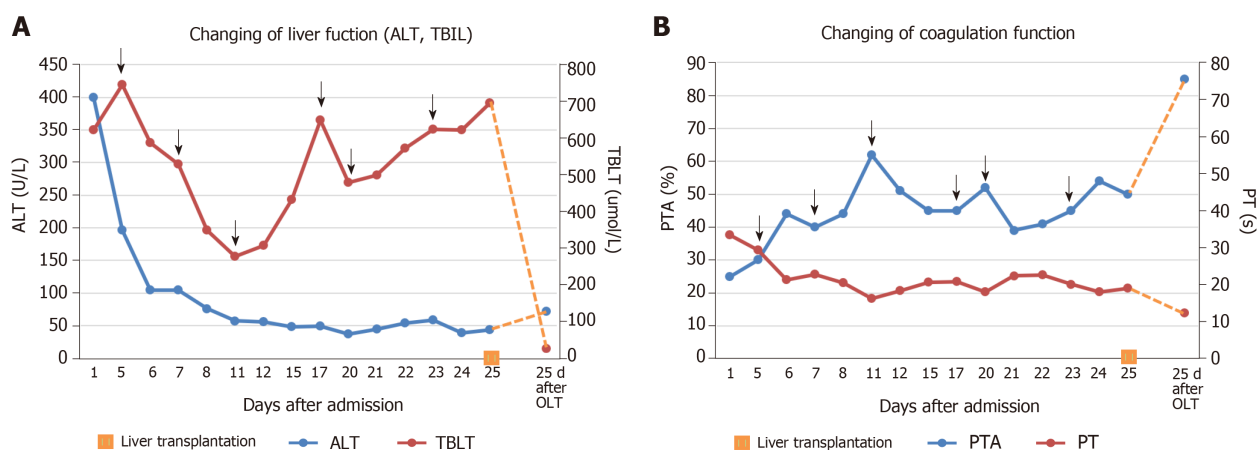
#### **Hepatotoxicity mechanism of benzbromarone**

The hepatotoxicity associated with benzbromarone might be explained by mitochondrial toxicity and subsequent induction of apoptosis and necrosis. Priska found that benzbromarone decreased the mitochondrial membrane potential of isolated rat hepatocytes by 81%. In mitochondria, benzbromarone decreased the state 3 oxidation and respiratory control ratios of L-glutamate, decreased mitochondrial  $\beta$ -oxidation, and increased reactive oxygen species production<sup>[8]</sup>. Another study demonstrated that benzbromarone is associated with profound changes in mitochondrial structure, which may be associated with apoptosis<sup>[9]</sup>. Additionally, Wang *et al*<sup>[10]</sup> reported that metabolic epoxidation is a key step in the development of benzbromarone-induced hepatotoxicity.

Hepatotoxicity is often associated with cytochrome P450-mediated bioactivation. Early metabolic studies revealed two major hydroxylated metabolites of benzbromarone, 1'-hydroxy benzbromarone and 6-hydroxy benzbromarone, in urine, bile, and plasma<sup>[11]</sup>. Further oxidation of 6-hydroxy benzbromarone in human liver microsomes results in the formation of 5,6-dihydroxy metabolites<sup>[12]</sup>. These metabolites of benzbromarone have been reported to induce a transition in mitochondrial membrane permeability, and the metabolites and their reactive intermediates have been associated with liver injury<sup>[13-15]</sup>. According to Kaoru's research, CYP3A4 and CYP2C9 catalyze the formation of 1'-hydroxy benzbromarone and 6-hydroxy benzbromarone, respectively, with CYP2C9 and CYP1A2 further catalyzing the formation of 5,6-dihydroxy benzbromarone in human liver microsomes. The activity of these CYP isozymes might be related to benzbromarone-induced liver toxicity<sup>[16]</sup>.

#### **Reports of benzbromarone-related hepatotoxicity in the literature**

We retrieved eight reported cases of benzbromarone-related hepatotoxicity, for a total of nine including the present case (Table 2): One from the Netherlands, one from Turkey, three from China, and the remaining four from Japan. In addition, the Periodic Safety Update Report listed 11 patients who developed hepatotoxicity from benzbromarone, among whom nine died; however, details of these unpublished data could not be obtained<sup>[17]</sup>. According to the National Center for Adverse Drug Reaction (ADR) monitoring website, 533 side effects related to benzbromarone were reported



**Figure 2 Clinical course.** A: Changes in alanine aminotransferase and total bilirubin; B: Changes in prothrombin time and prothrombin time activity. ALT: Alanine aminotransferase; TBIL: Total bilirubin; PT: Prothrombin time; PTA: Prothrombin time activity; OLT: Orthotopic liver transplantation.

in China before January 10, 2015, including 28 cases of liver injury (5.25%), 16 cases of mild liver injury (ALT abnormality,  $1 \times \text{ULN} < \text{total bilirubin} \leq 5 \times \text{ULN}$ , and no or mild symptoms), three cases of severe liver injury (ALT  $\geq 10 \times \text{ULN}$ ,  $5 \times \text{ULN} < \text{total bilirubin} \leq 10 \times \text{ULN}$ , with severe symptoms and typical signs in physical examination), and nine cases that could not be clearly classified. No liver failure cases were reported on this website, and no more information was provided regarding these patients<sup>[7]</sup>. To date, the case presented here is the first report of liver failure related to benzbromarone in China.

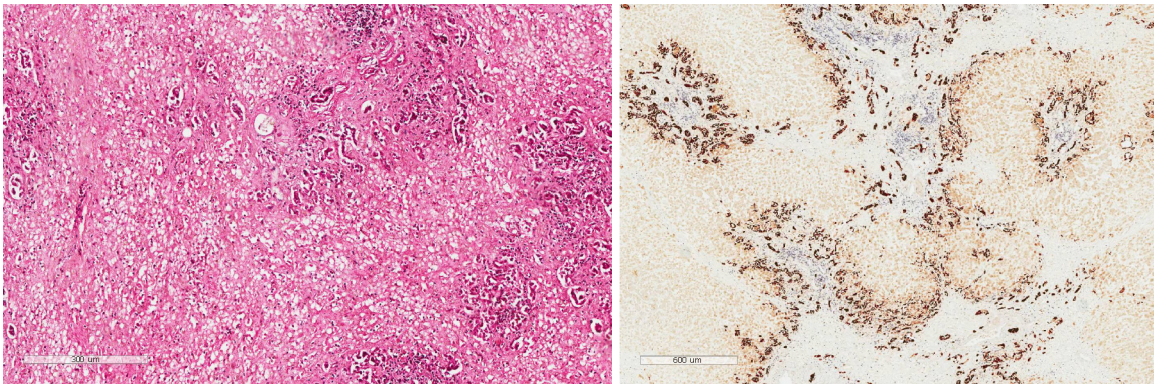
Treatment in our case was successful. Based on suggestions from multidisciplinary consultation, the patient accepted the best supportive treatment, PE as bridge treatment, and liver transplantation, and the follow-up results were good. Our initial diagnosis was confirmed by pathological results of liver tissue sections. The limitation of this research was that we did not assess the activity of CYP isozymes, which might be related to benzbromarone-induced liver toxicity, as these tests were not available in our hospital.

Among all reported cases, four patients have died, three patients recovered after PE, hemodiafiltration, prednisolone, or liver transplantation, alone or in combination, and two patients took benzbromarone for less than 1 mo and recovered after conservative treatment or methylprednisolone therapy. Although benzbromarone hepatotoxicity varied in severity, a high proportion of patients developed acute liver failure, leading to death or emergency liver transplantation. Therefore, medical professionals should exert caution before prescribing this drug, and the risk of hepatotoxicity should be carefully assessed individually, as seven among nine reported patients used other drugs or alcohol when taking benzbromarone, which may aggravate damage to the liver.

### Benefits and risks of benzbromarone treatment for gout

Although benzbromarone has been withdrawn in Europe due to serious hepatotoxicity, there is still a debate regarding whether this is in the best interests of gout patients. In 2008, Lee *et al.*<sup>[25]</sup> presented a benefit-risk assessment of benzbromarone. These authors examined the clinical benefits associated with benzbromarone treatment and compared these benefits with alternative therapies, such as allopurinol and probenecid; they also examined the degree to which the reported cases of hepatotoxicity can be attributed to treatment with benzbromarone and calculated the incidence of benzbromarone hepatotoxicity in Europe (approximately 1/17000 patients). Based on this benefit-risk assessment, the authors recommended the use of benzbromarone for gout and suggested that the risks of hepatotoxicity could be ameliorated by employing a graded dosage increase and regular monitoring of liver function. CYP2C9 status determination and the consideration of potential impacts of inhibition of this enzyme should also be considered<sup>[25]</sup>.

In 2015, the China Food and Drug Administration (CFDA) also performed a benefit-risk assessment of benzbromarone and suggested that the drug has greater benefits than risks in the treatment of gout or hyperuricemia. To prevent hepatotoxicity, the CFDA recommends the following: (1) Benzbromarone treatment should start at a low dose, and during treatment, liver function should be tested regularly; combination with other hepatotoxicity drugs should be avoided; (2)



**Figure 3** Liver biopsy specimen staining. HE staining showed massive necrosis of liver tissue, and immunohistochemical staining for CD19 revealed cholestasis and biliary duct hyperplasia.

Attention should be paid to the signs of liver injury, such as loss of appetite, nausea, vomiting, diarrhea, and jaundice; once these signs occur, medical advice should be provided in a timely manner; and (3) Arug manufacturers should strengthen ADR monitoring to ensure that product safety information is provided to the public, especially to doctors and patients<sup>[7]</sup>.

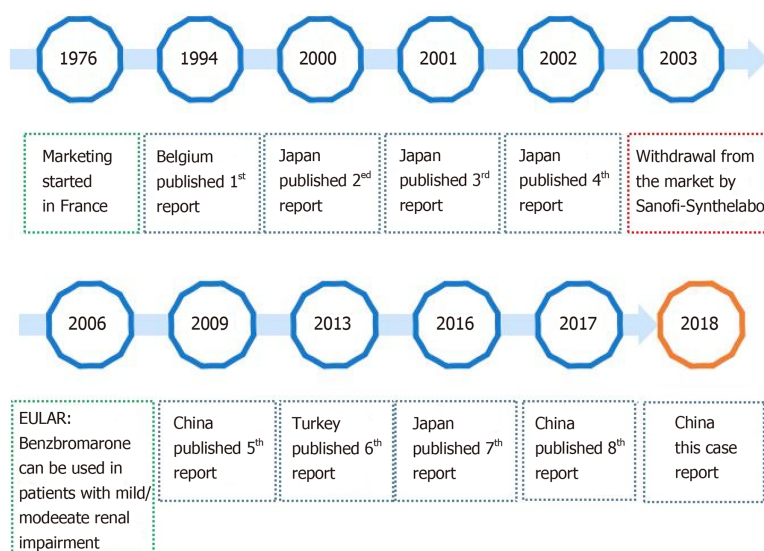
## CONCLUSION

In summary, benzbromarone may have benefits in the treatment of gout or hyperuricemia, which support its application. Although cases of severe hepatotoxicity are rare, they can be fatal. Here, we present a successful treatment approach for liver failure associated with benzbromarone. The experience was that the risk of hepatotoxicity should be carefully assessed individually and that hepatotoxicity of benzbromarone should be properly monitored during treatment.

**Table 2** Characteristics of benzbromarone-induced hepatotoxicity cases

Age	Sex	Course of benzbromarone	Dose	Combined medication	Prior liver diseases	Other diseases	Treatment	Outcome	Ref.
68	F	3.5 mo	200 mg/d (6 wk); 100 mg/d (2 mo)	Methyldopa	-	Gout, hypertension	Conservative treatment	Recovery (24 d)	[17]
62	M	6 mo	75 mg/d	-	-	Hyperuricemia	Bilirubin absorption	Death (62 d)	[18]
58	M	2 mo	Not described	Allopurinol, tocopherol, nicotinate, alprazolam, theophylline, azelastine hydrochloride, nilvadipine alcohol: (approximately 36 g/d)	-	Hyperuricemia, hypertension, asthmatic bronchitis	PE + HDF, prednisolone (30 mg/d orally, reduced gradually)	Recovery (94 d)	[19]
53	F	2 mo	100 mg/d	Allopurinol	-	Hyperuricemia, proteinuria	Liver transplant	Death (124 d)	[20]
53	M	3 d	50 mg/d	-	-	Hyperuricemia, diabetes	Conservative treatment	Recovery (3 d)	[21]
77	F	4 mo	Not described	Torsemide, nebivolol, ramipril, thyronajod	-	Hypertension, hyperthyroid disease, adiposity	Conservative treatment	Death (53 d)	[22]
59	M	More than 1 yr	50 mg/d	Benidipine, pravastatin, alcohol (60 g/d)	Liver dysfunction	Hyperuricemia, hypertension, dyslipidemia	HDF, liver transplant	Recovery (70 d)	[23]
47	M	15 d	Not described	Thiopronin	NAFLD	Gout, diabetes, hyperlipidemia	Methylprednisolone (8 mg/d orally)	Recovery (70 d)	[24]
39	M	4 mo	100 mg/d	Alcohol: (approximately 28 g/d for 10 yr)	-	Gout	PE + liver transplant	Recovery	

HDF: Hemodiafiltration; NAFLD: Non-alcoholic fatty liver disease; PE: Plasma exchange; M: Male; F: Female.

**Figure 4** Timeline of benzbromarone production and countries with published results regarding benzbromarone hepatotoxicity



## ACKNOWLEDGEMENTS

We sincerely thank professor Mei-Shan Jin from the Department of Pathology, First Hospital of Jilin University, for kindly helping us with accurate differential diagnosis based on the liver biopsy pathology.

## REFERENCES

- National Institutes of Health.** DRUG RECORD: Benzbromarone. Available from: <https://livertox.nlm.nih.gov/Benzbromarone.htm>
- Ragab G,** Elshahaly M, Bardin T. Gout: An old disease in new perspective - A review. *J Adv Res* 2017; **8**: 495-511 [PMID: 28748116 DOI: 10.1016/j.jare.2017.04.008]
- Yu YC,** Mao YM, Chen CW. Guidelines for the management of drug-induced liver injury. *J Clin Hepatol* 2015; **31**: 1752-69 [DOI: 10.3969/j.issn.1001-5256.2015.11.002]
- Kuo CF,** Grainge MJ, Zhang W, Doherty M. Global epidemiology of gout: prevalence, incidence and risk factors. *Nat Rev Rheumatol* 2015; **11**: 649-662 [PMID: 26150127 DOI: 10.1038/nrrheum.2015.91]
- Dalbeth N,** Merriman TR, Stamp LK. Gout. *Lancet* 2016; **388**: 2039-2052 [PMID: 27112094 DOI: 10.1016/S0140-6736(16)00346-9]
- Zhang W,** Doherty M, Bardin T, Pascual E, Barskova V, Conaghan P, Gerster J, Jacobs J, Leeb B, Lioté F, McCarthy G, Netter P, Nuki G, Perez-Ruiz F, Pignone A, Pimentão J, Punzi L, Roddy E, Uhlig T, Zimmermann-Görska I; EULAR Standing Committee for International Clinical Studies Including Therapeutics. EULAR evidence based recommendations for gout. Part II: Management. Report of a task force of the EULAR Standing Committee for International Clinical Studies Including Therapeutics (ESCISIT). *Ann Rheum Dis* 2006; **65**: 1312-1324 [PMID: 16707532 DOI: 10.1136/ard.2006.055269]
- National Center for ADR Monitoring.** Adverse Drug Reactions Information Circular (Phase 65) Alert Benzbromarone's Risk of Liver Injury. Available from: [http://www.cdr-adr.org.cn/xxbt\\_255/yplbfyxxbt/201501/t20150110\\_7960.html](http://www.cdr-adr.org.cn/xxbt_255/yplbfyxxbt/201501/t20150110_7960.html)
- Kaufmann P,** Török M, Hänni A, Roberts P, Gasser R, Krähenbühl S. Mechanisms of benzarone and benzbromarone-induced hepatic toxicity. *Hepatology* 2005; **41**: 925-935 [PMID: 15799034 DOI: 10.1002/hep.20634]
- Felser A,** Lindinger PW, Schnell D, Kratschmar DV, Odermatt A, Mies S, Jenö P, Krähenbühl S. Hepatocellular toxicity of benzbromarone: effects on mitochondrial function and structure. *Toxicology* 2014; **324**: 136-146 [PMID: 25108121 DOI: 10.1016/j.tox.2014.08.002]
- Wang H,** Peng Y, Zhang T, Lan Q, Zhao H, Wang W, Zhao Y, Wang X, Pang J, Wang S, Zheng J. Metabolic Epoxidation Is a Critical Step for the Development of Benzbromarone-Induced Hepatotoxicity. *Drug Metab Dispos* 2017; **45**: 1354-1363 [PMID: 29021351 DOI: 10.1124/dmd.117.077818]
- Broekhuysen J,** Pacco M, Sion R, Demeulenaere L, Van Hee M. Metabolism of benzbromarone in man. *Eur J Clin Pharmacol* 1972; **4**: 125-130 [PMID: 4655683 DOI: 10.1007/BF00562509]
- McDonald MG,** Rettie AE. Sequential metabolism and bioactivation of the hepatotoxin benzbromarone: formation of glutathione adducts from a catechol intermediate. *Chem Res Toxicol* 2007; **20**: 1833-1842 [PMID: 18020424 DOI: 10.1021/tx7001228]
- Shirakawa M,** Sekine S, Tanaka A, Horie T, Ito K. Metabolic activation of hepatotoxic drug (benzbromarone) induced mitochondrial membrane permeability transition. *Toxicol Appl Pharmacol* 2015; **288**: 12-18 [PMID: 26148448 DOI: 10.1016/j.taap.2015.06.018]
- Yoshida M,** Cho N, Akita H, Kobayashi K. Association of a reactive intermediate derived from 1',6'-dihydroxy metabolite with benzbromarone-induced hepatotoxicity. *J Biochem Mol Toxicol* 2017; **31** [PMID: 28598529 DOI: 10.1002/jbt.21946]
- Cho N,** Kobayashi K, Yoshida M, Kogure N, Takayama H, Chiba K. Identification of novel glutathione adducts of benzbromarone in human liver microsomes. *Drug Metab Pharmacokinet* 2017; **32**: 46-52 [PMID: 28131653 DOI: 10.1016/j.dmpk.2016.10.412]
- Kobayashi K,** Kajiwara E, Ishikawa M, Oka H, Chiba K. Identification of CYP isozymes involved in benzbromarone metabolism in human liver microsomes. *Biopharm Drug Dispos* 2012; **33**: 466-473 [PMID: 22933344 DOI: 10.1002/bdd.1813]
- van der Klauw MM,** Houtman PM, Stricker BH, Spoelstra P. Hepatic injury caused by benzbromarone. *J Hepatol* 1994; **20**: 376-379 [PMID: 8014449 DOI: 10.1016/S0168-8278(94)80011-1]
- Wagayama H,** Shiraki K, Sugimoto K, Fujikawa K, Shimizu A, Takase K, Nakano T, Tameda Y. Fatal fulminant hepatic failure associated with benzbromarone. *J Hepatol* 2000; **32**: 874 [PMID: 10845680 DOI: 10.1016/S0168-8278(00)80263-9]
- Suzuki T,** Suzuki T, Kimura M, Shinoda M, Fujita T, Miyake N, Yamamoto S, Tashiro K. [A case of fulminant hepatitis, possibly caused by benzbromarone]. *Nihon Shokakibyo Gakkai Zasshi* 2001; **98**: 421-425 [PMID: 11400273]
- Arai M,** Yokosuka O, Fujiwara K, Kojima H, Kanda T, Hirasawa H, Saisho H. Fulminant hepatic failure associated with benzbromarone treatment: a case report. *J Gastroenterol Hepatol* 2002; **17**: 625-626 [PMID: 12084041 DOI: 10.1046/j.1440-1746.2002.02692.x]
- Hou GC,** Sun XL. A case of acute liver injury caused by Benzbromarone. *Linchuang Yiyao Shijian* 2009; **18**: 471
- Haring B,** Kudlich T, Rauthe S, Melcher R, Geier A. Benzbromarone: a double-edged sword that cuts the liver? *Eur J Gastroenterol Hepatol* 2013; **25**: 119-121 [PMID: 23196726 DOI: 10.1097/MEG.0b013e328358ace9]
- Haga Y,** Yasui S, Kanda T, Hattori N, Wakamatsu T, Nakamura M, Sasaki R, Wu S, Nakamoto S, Arai M, Maruyama H, Ohtsuka M, Oda S, Miyazaki M, Yokosuka O. Successful Management of Acute Liver Failure Patients Waiting for Liver Transplantation by On-Line Hemodiafiltration with an Arteriovenous Fistula. *Case Rep Gastroenterol* 2016; **10**: 139-145 [PMID: 27403116 DOI: 10.1159/000445186]
- Zhu FY,** Meng Q. A severe case of acute liver injury caused by Benzbromarone. *Chinese Hepatology* 2017; **22**: 973-974 [DOI: 10.14000/j.cnki.issn.1008-1704.2017.10.036]
- Lee MH,** Graham GG, Williams KM, Day RO. A benefit-risk assessment of benzbromarone in the treatment of gout. Was its withdrawal from the market in the best interest of patients? *Drug Saf* 2008; **31**: 643-665 [PMID: 18636784 DOI: 10.2165/00002018-200831080-00002]



Published By Baishideng Publishing Group Inc  
7041 Koll Center Parkway, Suite 160, Pleasanton, CA 94566, USA  
Telephone: +1-925-2238242  
Fax: +1-925-2238243  
E-mail: [bpgoffice@wjgnet.com](mailto:bpgoffice@wjgnet.com)  
Help Desk: <https://www.f6publishing.com/helpdesk>  
<https://www.wjgnet.com>

