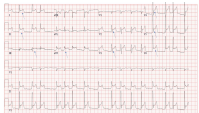
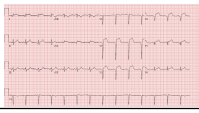


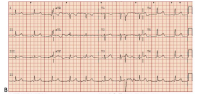



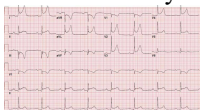
Supplementary Table 1 Demographic Details of Patients Included in the Case Reports and Summary of Diagnoses from Case Reports
Generated by ChatGPT o1 and DeepThink-R1

Author, Year	Age and Sex	PMH	Presentation Summary*	Diagnosis in original case report	Did ChatGPT o1 Include Pericarditis as one of the three differentials? (Yes/No)	Did DeepThink-R1 include Pericarditis as one of the three differentials? (Yes/No)	ChatGPT o1 Provisional Diagnosis	DeepThink-R1 Provisional Diagnosis	DOI
Javed et al., 2024	65M	HIV, diastolic dysfunction, prediabetes, hepatitis C, COPD, HTN, CKD, substance use disorder (remission), OSA	Unresponsive, altered mentation, substernal chest pain worsened by inspiration, weight loss, diarrhea, BP 142/75, RR 26, HR 151, mod. resp distress, wheezing, irregularly irregular rhythm, diffuse ST elevation, atrial flutter/fib 	Acute pericarditis	Yes	Yes	Acute Pericarditis	Acute Pericarditis	10.7759/cureus.65941
Masood et al., 2024	30M	Juvenile asthma, marijuana use	Recurrent chest pain, SOB, 9/10, worsened forward, BP 144/88, RR 20, HR 105, ST elevations V2–V6, PR depressions V2–V6	Marijuana-induced pericarditis	Yes	Yes	Acute Pericarditis	Acute pericarditis	10.55729/2000-9666.1351
Zarella et al., 2024	47M	HTN, HLD, smoking, FHx MI	Left chest pain, radiating to arm, began lifting, ECG: ST elevations anterolateral 	Pericarditis	Yes	No	STEMI	Anterior-Lateral STEMI	10.7759/cureus.71163
Mascarenhas et al., 2024	81M	Glaucoma, UTI, MSSA bacteriuria, sciatica, prednisone	Epigastric pain, worsened by inspiration, hypertensive, BP 168/81, HR 110, temperature 101.5°F, no ECG changes	Purulent pericarditis	No	No	Perforated peptic ulcer	Perforated peptic ulcer	10.1186/s12872-024-03828-9
Patel et al., 2024	60F	HTN, HLD, T1DM, ESRD, two failed kidney transplants, Marfan	Chest pain radiating to the back, SOB, dizziness, palpitations, BP 66/37, HR 134, muffled heart sounds, jugular venous distention, systolic ejection murmur (III/VI) at the right	Uremic pericarditis	No	No	Acute Type A Aortic Dissection	Cardiac Tamponade secondary to uremic pericarditis	10.55729/2000-9666.1307

			<p>parasternal 2nd intercostal space, AFib with nonspecific ST and T wave abnormalities in inferior and lateral leads.</p> 						
Medplali et al., 2024	29F	Medtronic leadless Micro AV2 pacemaker implantation	<p>Chest pain day post-implant, chest wall tender, diffuse ST elevation</p> 	Acute pericarditis	Yes	Yes	Acute Pericarditis	Cardiac perforation	10.7759/cureus.70027
Wagle et al., 2024	64M	HIV (nonadherent), opioid use	<p>Chest pain exacerbated by coughing, sitting up, and walking, fever, SOB, crackles, ST elevations and PR depressions in inferior/lateral leads</p> 	Acute pericarditis	Yes	Yes	Acute Pericarditis	Acute Pericarditis	10.1097/MS9.0000000000002552
Yeates & Quimby, 2024	22M	None, cleaning out bird coop housing chicken and turkey 3 weeks prior to presentation	<p>Chest discomfort exacerbated with deep breathing/back pain, fever, fatigue, BP 132/60, HR 132, temperature 39.3°C, diffuse abdominal tenderness, sinus tachycardia and non-specific T wave abnormality</p>	Acute pericarditis	No	No	Psittacosis	Psittacosis	10.7759/cureus.59512
Morello et al., 2024	91M	HTN, HLD, COPD, BPH	<p>Chest pain radiating to arm, BP 152/92, HR 95, RR 18, ST elevations in inferior/lateral leads</p> 	Acute pericarditis	Yes	No	STEMI	STEMI	10.7759/cureus.73818
Yetiskul et al., 2024	91F	HTN, HLD, presbycusis, influenza vaccine 2 days prior to presentation	<p>Chest pain after flu vaccine radiating to the left side of the chest, back, and left shoulder, and worse with inspiration, fever, BP 186/94, HR 101, temperature 38.2°C, rub, ST elevation and PR depression in inferior leads</p> <p>First ECG:</p>	Acute pericarditis	Yes	Yes	Acute Pericarditis	Acute Pericarditis	10.1155/2024/2729208

			 Repeat ECH: 						
Phang et al., 2024	47M	Psoriatic arthritis, alcohol	Weakness, jaundice, BP 126/73, HR 128, RR 24, temperature 38, icteric sclera, jaundiced skin, positive shifting dullness, no ECG	Liver failure and/ pericarditis	No	No	Acute decompensation of alcoholic cirrhosis, possibly precipitated by alcoholic hepatitis and/or SBP	Acute Alcoholic Hepatitis with Suspicion for SBP	10.12659/AJCR.943530
Ingram et al., 2024	66M	Alcohol, cocaine	Chest pain, SOB, BP 106/75, HR 116, RR 31, temperature 38.6°C, chest wall tenderness, ST elevations in anterior/lateral leads then diffusely	Acute Purulent pericarditis	Yes	Yes	Acute Pericarditis	Acute Myopericarditis	10.7759/cureus.54838
Nader et al., 2024	77M	Sick sinus syndrome (with a permanent Medtronic dual chamber pacemaker placed 8 years prior), paroxysmal AFib on Apixaban, HLD, depression,OSA	Nausea, vomiting, chest pain, BP 80/40, RR 27, distant sounds, diminished pulses, cool lower extremities, mild abdominal tenderness, diffuse ST elevations 	Acute Pericarditis with Tamponade secondary to pacemaker lead perforation	No	No	Tamponade	Tamponade	10.7812/TPP/24.044
Sehgal et al., 2024	30sM	Cocaine use	Chest pain relieved forward, BP 180/110 HR 130, diffuse ST elevation and PR depression electrical alternans 	Fistula w/ purulent pericarditis	Yes	Yes	Acute Pericarditis	Acute Pericarditis with Pericardial Effusion and Cardiac Tamponade	10.1136/bcr-2024-260427
Patel et al., 2025	71M	Esophageal adenocarcinoma, stage IV prostate cancer with bone	Weakness and odynophagia, BP 70/54, HR 104, temperature 101.8°F, ECG unremarkable	S. intermedium pericarditis	No	No	Sepsis	Septic Shock due to Mediastinal abscess	10.1093/omcr/omae161

		metastases, post distal esophagectomy, proximal gastrectomy 2 years prior		s					
Davis et al., 2024	60M	HTN, T2DM, wife as sick contact with cough and fever	Chest soreness, worsened with deep breaths and lying flat, the pain improved when he leaned forward, HR 50, first degree AV block with sinus bradycardia of 50 beats/min, and diffuse ST-segment elevations, with ST-segment depressions in leads III, aVF, and aVR. evolution of Q waves inferiorly	Infarct-associated pericarditis	Yes	Yes	Acute Pericarditis	Myopericarditis	10.1016/j.jaccas.2024.102722



*when vitals and physical examination are not mentioned, they are normal

HTN: Hypertension, HLD: Hyperlipidemia, T1DM: Type 1 Diabetes Mellitus, T2DM: Type 2 Diabetes Mellitus, CKD: Chronic Kidney Disease, COPD: Chronic Obstructive Pulmonary Disease, OSA: Obstructive Sleep Apnea, PMH: Past Medical History
 SOB: Shortness of Breath, BP: Blood Pressure, HR: Heart Rate, RR: Respiratory Rate, ECG: Electrocardiogram, AFib: Atrial Fibrillation
 FHx: Family History, BPH: Benign Prostatic Hyperplasia, SBP: Spontaneous Bacterial Peritonitis, STEMI: ST-Elevation Myocardial Infarction