

# World Journal of *Gastrointestinal Surgery*

*World J Gastrointest Surg* 2023 May 27; 15(5): 745-1006



**REVIEW**

- 745 Impact of anastomotic leakage on long-term prognosis after colorectal cancer surgery  
*Tonini V, Zanni M*
- 757 Application of indocyanine green in surgery: A review of current evidence and implementation in trauma patients  
*Abdelrahman H, El-Menyar A, Peralta R, Al-Thani H*

**MINIREVIEWS**

- 776 Global dissemination of minimally invasive living donor hepatectomy: What are the barriers?  
*Kakos CD, Papanikolaou A, Ziogas IA, Tsoufias G*
- 788 Post-COVID-19 cholangiopathy: Current understanding and management options  
*Veerankutty FH, Sengupta K, Vij M, Rammohan A, Jothimani D, Murali A, Rela M*
- 799 Changing trends in the minimally invasive surgery for corrosive esophagogastric stricture  
*Kalayarasan R, Durgesh S*

**ORIGINAL ARTICLE****Basic Study**

- 812 Distribution of splenic artery lymph nodes and splenic hilar lymph nodes  
*Umebayashi Y, Muro S, Tokunaga M, Saito T, Sato Y, Tanioka T, Kinugasa Y, Akita K*

**Case Control Study**

- 825 Preservation of left colic artery in laparoscopic colorectal operation: The benefit challenge  
*Liu FC, Song JN, Yang YC, Zhang ZT*

**Retrospective Cohort Study**

- 834 Surgical management of high-grade pancreatic injuries: Insights from a high-volume pancreaticobiliary specialty unit  
*Chui JN, Kotecha K, Gall TM, Mittal A, Samra JS*
- 847 Surgical management of hydatid cyst disease of the liver: An improvement from our previous experience?  
*Zaharie F, Valean D, Zaharie R, Popa C, Mois E, Schlanger D, Fetti A, Zdrehus C, Ciocan A, Al-Hajjar N*

**Retrospective Study**

- 859 Influence of liver function after laparoscopy-assisted *vs* totally laparoscopic gastrectomy  
*Xiao F, Qiu XF, You CW, Xie FP, Cai YY*

- 871 Rikkunshito increases appetite by enhancing gastrointestinal and incretin hormone levels in patients who underwent pylorus-preserving pancreaticoduodenectomy: A retrospective study

*Kono H, Hosomura N, Amemiya H, Shoda K, Furuya S, Akaike H, Kawaguchi Y, Kawaida H, Ichikawa D*

- 882 Diagnostic performance of texture analysis in the differential diagnosis of perianal fistulising Crohn's disease and glandular anal fistula

*Zhu X, Ye DD, Wang JH, Li J, Liu SW*

- 892 Elderly patients over 80 years undergoing colorectal cancer resection: Development and validation of a predictive nomogram for survival

*Chok AY, Zhao Y, Chen HLR, Tan IEH, Chew DHW, Zhao Y, Au MKH, Tan EJKW*

- 906 Retrospective efficacy analysis of olaparib combined with bevacizumab in the treatment of advanced colorectal cancer

*Jiang YL, Fu XY, Yin ZH*

### Observational Study

- 917 CD4<sup>+</sup>CD25<sup>+</sup> regulatory T cells decreased future liver remnant after associating liver partition and portal vein ligation for staged hepatectomy

*Wang W, Ye CH, Deng ZF, Wang JL, Zhang L, Bao L, Xu BH, Zhu H, Guo Y, Wen Z*

- 931 Diagnostic value of matrix metalloproteinases 2, 7 and 9 in urine for early detection of colorectal cancer

*Peng L, Zhang X, Zhang ML, Jiang T, Zhang PJ*

### SYSTEMATIC REVIEWS

- 940 How far is the endoscopist to blame for a percutaneous endoscopic gastrostomy complication?

*Stavrou G, Gionga P, Chatziantoniou G, Tzikos G, Menni A, Panidis S, Shrewsbury A, Kotzampassi K*

### META-ANALYSIS

- 953 Nutritional status efficacy of early nutritional support in gastrointestinal care: A systematic review and meta-analysis

*He LB, Liu MY, He Y, Guo AL*

### CASE REPORT

- 965 Precise mapping of hilar cholangiocarcinoma with a skip lesion by SpyGlass cholangioscopy: A case report

*Chiang CH, Chen KC, Devereaux B, Chung CS, Kuo KC, Lin CC, Lin CK, Wang HP, Chen KH*

- 972 Mallory-Weiss syndrome from giant gastric trichobezoar: A case report

*Lieto E, Auricchio A, Belfiore MP, Del Sorbo G, De Sena G, Napolitano V, Ruggiero A, Galizia G, Cardella F*

- 978 Giant teratoma with isolated intestinal duplication in adult: A case report and review of literature

*Xiong PF, Yang L, Mou ZQ, Jiang Y, Li J, Ye MX*

- 984 Computer-assisted rescue of the inferior mesenteric artery in a child with a giant ganglioneuroblastoma: A case report

*Xiu WL, Liu J, Zhang JL, Su N, Wang FJ, Hao XW, Wang FF, Dong Q*

- 992** Curative resection of leiomyosarcoma of the descending colon with metachronous liver metastasis: A case report  
*Lee SH, Bae SH, Lee SC, Ahn TS, Kim Z, Jung HI*
- 1000** Modified endoscopic submucosal tunnel dissection for large esophageal submucosal gland duct adenoma: A case report  
*Chen SY, Xie ZF, Jiang Y, Lin J, Shi H*

**ABOUT COVER**

Editorial Board Member of *World Journal of Gastrointestinal Surgery*, Ashok Kumar, BSc, FACS, FASCRS, FICS, FRCS, FRCS (Ed), MBBS, MCh, Professor, Department of Surgical Gastroenterology, Sanjay Gandhi Post Graduate Institute of Medical Sciences, Lucknow 226014, Uttar Pradesh, India. doc.ashokgupta@gmail.com

**AIMS AND SCOPE**

The primary aim of *World Journal of Gastrointestinal Surgery* (*WJGS*, *World J Gastrointest Surg*) is to provide scholars and readers from various fields of gastrointestinal surgery with a platform to publish high-quality basic and clinical research articles and communicate their research findings online.

*WJGS* mainly publishes articles reporting research results and findings obtained in the field of gastrointestinal surgery and covering a wide range of topics including biliary tract surgical procedures, biliopancreatic diversion, colectomy, esophagectomy, esophagostomy, pancreas transplantation, and pancreatectomy, etc.

**INDEXING/ABSTRACTING**

The *WJGS* is now abstracted and indexed in Science Citation Index Expanded (SCIE, also known as SciSearch®), Current Contents/Clinical Medicine, Journal Citation Reports/Science Edition, PubMed, PubMed Central, Reference Citation Analysis, China National Knowledge Infrastructure, China Science and Technology Journal Database, and Superstar Journals Database. The 2022 Edition of Journal Citation Reports® cites the 2021 impact factor (IF) for *WJGS* as 2.505; IF without journal self cites: 2.473; 5-year IF: 3.099; Journal Citation Indicator: 0.49; Ranking: 104 among 211 journals in surgery; Quartile category: Q2; Ranking: 81 among 93 journals in gastroenterology and hepatology; and Quartile category: Q4.

**RESPONSIBLE EDITORS FOR THIS ISSUE**

Production Editor: Rui-Rui Wu; Production Department Director: Xiang Li; Editorial Office Director: Jia-Ru Fan.

**NAME OF JOURNAL**

*World Journal of Gastrointestinal Surgery*

**ISSN**

ISSN 1948-9366 (online)

**LAUNCH DATE**

November 30, 2009

**FREQUENCY**

Monthly

**EDITORS-IN-CHIEF**

Peter Schemmer

**EDITORIAL BOARD MEMBERS**

<https://www.wjgnet.com/1948-9366/editorialboard.htm>

**PUBLICATION DATE**

May 27, 2023

**COPYRIGHT**

© 2023 Baishideng Publishing Group Inc

**INSTRUCTIONS TO AUTHORS**

<https://www.wjgnet.com/bpg/gerinfo/204>

**GUIDELINES FOR ETHICS DOCUMENTS**

<https://www.wjgnet.com/bpg/GerInfo/287>

**GUIDELINES FOR NON-NATIVE SPEAKERS OF ENGLISH**

<https://www.wjgnet.com/bpg/gerinfo/240>

**PUBLICATION ETHICS**

<https://www.wjgnet.com/bpg/GerInfo/288>

**PUBLICATION MISCONDUCT**

<https://www.wjgnet.com/bpg/gerinfo/208>

**ARTICLE PROCESSING CHARGE**

<https://www.wjgnet.com/bpg/gerinfo/242>

**STEPS FOR SUBMITTING MANUSCRIPTS**

<https://www.wjgnet.com/bpg/GerInfo/239>

**ONLINE SUBMISSION**

<https://www.f6publishing.com>



Retrospective Study

## Retrospective efficacy analysis of olaparib combined with bevacizumab in the treatment of advanced colorectal cancer

Yi-Ling Jiang, Xue-Yuan Fu, Zhi-Hui Yin

**Specialty type:** Gastroenterology and hepatology

**Provenance and peer review:** Unsolicited article; Externally peer-reviewed.

**Peer-review model:** Single-blind

**Peer-review report's scientific quality classification**

Grade A (Excellent): 0  
Grade B (Very good): B  
Grade C (Good): C, C  
Grade D (Fair): 0  
Grade E (Poor): 0

**P-Reviewer:** Celik GK, Turkey; Flynn DE, Australia; Rumpold H, Austria

**Received:** February 19, 2023

**Peer-review started:** February 19, 2023

**First decision:** March 1, 2023

**Revised:** March 11, 2023

**Accepted:** April 7, 2023

**Article in press:** April 7, 2023

**Published online:** May 27, 2023



**Yi-Ling Jiang**, Department of Oncology, The First Affiliated Hospital, Hengyang Medical School, University of South China, Hengyang 421001, Hunan Province, China

**Xue-Yuan Fu, Zhi-Hui Yin**, Department of Anorectal, The First Affiliated Hospital, Hengyang Medical School, University of South China, Hengyang 421001, Hunan Province, China

**Corresponding author:** Zhi-Hui Yin, MM, Associate Chief Physician, Department of Anorectal, The First Affiliated Hospital, Hengyang Medical School, University of South China, No. 69 Chuanshan Avenue, Shigu District, Hengyang 421001, Hunan Province, China.  
[yinzhihui6996@163.com](mailto:yinzhihui6996@163.com)

### Abstract

#### BACKGROUND

Colorectal cancer (CRC) is a highly prevalent malignancy of the digestive tract worldwide, characterized by a significant morbidity and mortality rate and subtle initial symptoms. Diarrhea, local abdominal pain, and hematochezia occur with the development of cancer, while systemic symptoms such as anemia and weight loss occur in patients with advanced CRC. Without timely interventions, the disease can have fatal consequences within a short span. The current therapeutic options for colon cancer include olaparib and bevacizumab, which are widely utilized. This study intends to evaluate the clinical efficacy of olaparib combined with bevacizumab in the treatment of advanced CRC, hoping to provide insights into advanced CRC treatment.

#### AIM

To investigate the retrospective efficacy of olaparib combined with bevacizumab in the treatment of advanced CRC.

#### METHODS

A retrospective analysis was conducted on a cohort of 82 patients with advanced colon cancer who were admitted to the First Affiliated Hospital of the University of South China between January 2018 and October 2019. Among them, 43 patients subjected to the classical FOLFOX chemotherapy regimen were selected as the control group, and 39 patients undergoing treatment with olaparib combined with bevacizumab were selected as the observation group. Subsequent to different treatment regimens, the short-term efficacy, time to progression (TTP), and incidence rate of adverse reactions between the two groups were compared. Changes in serum-related indicators [vascular endothelial growth factor (VEGF),



matrix metalloprotein-9 (MMP-9), cyclooxygenase-2 (COX-2)] and tumor markers [human epididymis protein 4 (HE4), carbohydrate antigen 125 (CA125), carbohydrate antigen 199 (CA199)] levels before and after treatment were compared between the two groups at the same time.

## RESULTS

The objective response rate was discovered to be 82.05%, and the disease control rate was 97.44% in the observation group, which were significantly higher than the respective rates of 58.14% and 83.72% in the control group ( $P < 0.05$ ). The median TTP was 24 mo (95%CI: 19.987-28.005) in the control group and 37 mo (95%CI: 30.854-43.870) in the observation group. The TTP in the observation group was significantly better than that in the control group, and the difference held statistical significance (log-rank test value = 5.009,  $P = 0.025$ ). Before treatment, no substantial difference was detected in serum VEGF, MMP-9, and COX-2 levels and tumor markers HE4, CA125, and CA199 levels between the two groups ( $P > 0.05$ ). Following treatment with different regimens, the above indicators in the two groups were remarkably promoted ( $P < 0.05$ ), VEGF, MMP-9, and COX-2 in the observation group were lower than those in the control group ( $P < 0.05$ ), and HE4, CA125, and CA199 levels were also lower than those in the control group ( $P < 0.05$ ). Vis-à-vis the control group, the total incidence of gastrointestinal reactions, thrombosis, bone marrow suppression, liver and kidney function injury, and other adverse reactions in the observation group was notably lowered, with the difference considered statistically significant ( $P < 0.05$ ).

## CONCLUSION

Olaparib combined with bevacizumab in the treatment of advanced CRC demonstrates a strong clinical effect of delaying disease progression and reducing the serum levels of VEGF, MMP-9, COX-2 and tumor markers HE4, CA125 and CA199. Moreover, given its fewer adverse reactions, it can be regarded as a safe and reliable treatment option.

**Key Words:** Olaparib; Bevacizumab; Advanced colorectal cancer; Efficacy

©The Author(s) 2023. Published by Baishideng Publishing Group Inc. All rights reserved.

**Core Tip:** Colorectal cancer (CRC) presents insignificant symptoms in the early stage and is commonly diagnosed in the middle and advanced stages. Therefore, surgery is usually not viable because the best timing is missed, and chemotherapy, targeted therapies and other regimens are often utilized as interventions. Olaparib and bevacizumab are common targeted therapies with excellent therapeutic effects in a variety of solid tumors. This research collected the clinical data of 82 patients with advanced CRC, retrospectively investigated the clinical efficacy and safety of olaparib combined with bevacizumab in advanced CRC treatment, and analyzed the effect of this treatment regimen on the serum levels of vascular endothelial growth factor, matrix metalloprotein-9, cyclooxygenase-2, and related tumor markers.

**Citation:** Jiang YL, Fu XY, Yin ZH. Retrospective efficacy analysis of olaparib combined with bevacizumab in the treatment of advanced colorectal cancer. *World J Gastrointest Surg* 2023; 15(5): 906-916

**URL:** <https://www.wjgnet.com/1948-9366/full/v15/i5/906.htm>

**DOI:** <https://dx.doi.org/10.4240/wjgs.v15.i5.906>

## INTRODUCTION

Colorectal cancer (CRC), a malignant tumor disease of the digestive tract originating from the epithelial tissues of the colon or rectal mucosa, is the third most prevalent cancer worldwide and the fourth leading contributor to cancer-related death[1-3]. Epidemiological statistics show that as of 2018, approximately 1.8 million new CRC pathologies were reported worldwide, resulting in 881000 deaths, underscoring the considerable harmful consequences of this disease[4]. Over the past five decades, the incidence and mortality of colon cancer have increased year by year in young and middle-aged people (< 50 years old), with an annual increase of 2% in individuals < 50 years old since 1994, leading to a surge in CRC incidence in younger age groups[5]. According to different histological types, colon cancer can be classified into three categories: adenocarcinoma, mucinous adenocarcinoma, and undifferentiated carcinoma[6,7]. Early-stage colon cancer often lacks obvious clinical symptoms and is easily neglected. Progressing to the middle and later stages, the disease often demonstrates abdominal pain, abdominal distension, diarrhea, hematochezia, and other symptoms. Moreover, about 20%-50% of patients have developed distant organ metastasis to varying degrees at the time of diagnosis[8], which

seriously impacts patient survival and prognosis.

At present, colon cancer is predominantly treated with surgical resection, but this approach is not suitable for advanced metastatic colon cancer. Chemotherapeutic drugs such as 5-fluorouracil, oxaliplatin, and olaparib are used clinically for first-line targeted chemotherapy[9,10]. In addition, with the continuous improvement of targeted molecular therapies, treatment strategies targeting vascular endothelial growth factor (VEGF) as well as epidermal growth factor (EGF) receptors have been demonstrated to heighten the survival rate of patients with advanced colon cancer[11,12]. Bevacizumab, an anti-angiogenic targeted therapeutic agent with strong anti-tumor activities, has been applied in the clinical treatment of malignant solid tumors such as breast cancer, non-small cell lung cancer, and CRC, and has achieved certain results[13,14]. Nevertheless, the efficacy of olaparib combined with bevacizumab in the clinical treatment of patients with advanced colon cancer remains less well studied. Based on this, 82 cases of advanced CRC patients admitted to the First Affiliated Hospital of the University of South China were collected for retrospective analysis in this study so as to investigate the efficacy of olaparib combined with bevacizumab in advanced CRC treatment. It's expected to offer more effective data support for the clinical application of this treatment regimen in advanced CRC.

## MATERIALS AND METHODS

### General information

Eighty-two patients with advanced colon cancer admitted to the First Affiliated Hospital of the University of South China from January 2018 to October 2019 were enrolled as the subjects of this retrospective study. The control group consisted of 43 patients who received the classical FOLFOX chemotherapy regimen, while the observation group included 39 patients who received olaparib combined with bevacizumab. The control group was composed of 24 males and 19 females, with age ranging from 22 to 71 years (average age:  $46.02 \pm 7.28$  years), while the observation group encompassed 19 males and 20 females aged between 21-73 years (mean age:  $48.37 \pm 6.41$  years). There was no remarkable statistical difference in gender, age, body mass index, histological type, and tumor-node-metastasis stage between the two groups ( $P > 0.05$ ), as shown in Table 1, indicating the comparability of the two groups.

### Inclusion and exclusion criteria

**Inclusion criteria:** Participants were aged 18 years or older; diagnosed with advanced colon cancer by magnetic resonance imaging, computed tomography, and other imaging examinations combined with pathological section, cytological examination, and clinical diagnosis; and were at stage III-IV according to the eighth edition of the American Joint Committee on Cancer Staging Manual[15]. Additionally, patients were required to have at least one objective measurable tumor lesion, blood routine, electrocardiogram, and other biochemical tests before treatment. Participants with no history of drug allergy and complete clinical data were included in the study.

**Exclusion criteria:** Patients with liver cancer, gastric cancer, and other malignant tumor diseases; patients with blood diseases or autoimmune diseases; patients with heart, liver and kidney, and other vital organ dysfunction; patients who received radiotherapy or other regimens of chemotherapy before enrollment; patients with hypertension, diabetes, heart disease, and other underlying diseases; patients with mental disorders, Alzheimer's disease or other cognitive impairment; patients during pregnancy and lactation; an expected survival of fewer than 3 mo.

### Treatment regimen

The control group (43 patients) received classical FOLFOX chemotherapy, which consisted of oxaliplatin (Zhejiang Hisun Pharmaceutical Co., Ltd.; approval number: GYZZ H20093487) administered intravenously at a dose of  $135 \text{ mg/m}^2$  for 2 h on day 1, calcium folinate (Jiangsu Hengrui Medicine Co., Ltd.; approval number: GYZZ H20000418) administered at  $200 \text{ mg/m}^2$  for 2 h on days 1-3, and 5-fluorouracil (Hainan Zhuotai Pharmaceutical Co., Ltd.; approval number: GYZZ H20051626) given continuously by an intravenous pump at a dose of  $2600 \text{ mg/m}^2$  for 46-48 h, every 3 weeks for a total of 6 cycles of chemotherapy.

The observation group (39 patients) underwent the treatment of olaparib combined with bevacizumab. To wit, olaparib (AstraZeneca; registration certificate number: H20180049) was taken orally at a dose of 200 mg twice daily- once in the morning and once in the evening; bevacizumab injection (Shanghai Roche Pharmaceutical Co., Ltd.; approval No.: S20120068) was intravenously injected at  $15 \text{ mg/kg}$  for 0.5-1 h on day 1, every three weeks for a total of six cycles of chemotherapy.

### Clinical assay items

**Short-term efficacy:** As per the iRECIST response evaluation criteria for cancer immunotherapy [16], the efficacy of both patient groups was assessed at the conclusion of treatment. Short-term efficacy was categorized into immune complete response (iCR), immune partial response (iPR), immune stable



Table 1 Comparison of general data between the two groups

General information	Control group (n = 43)	Observation group (n = 39)	$t/\chi^2$	P value
Gender (n)			0.413	0.521
Male	24	19		
Female	19	20		
Age (yr), mean $\pm$ SD	46.02 $\pm$ 7.28	48.37 $\pm$ 6.41	1.545	0.126
BMI (kg/m <sup>2</sup> ), mean $\pm$ SD	22.45 $\pm$ 3.46	23.01 $\pm$ 2.98	0.781	0.437
Histological classification (n)			0.427	0.808
Adenocarcinoma	27	22		
Mucinous cancer	12	12		
Undifferentiated carcinoma	4	5		
TNM stage (n)			2.201	0.138
III	12	17		
IV	31	22		

BMI: Body mass index; TNM: Tumor-node-metastasis.

disease (iSD) and immune progressive disease (iPD). Among them, iCR was identified as tumor changes disappeared and clinical symptoms improved; iPR was recognized upon lessened tumor volume and no detection of new tumor metastasis or lesion; iSD was identified when the tumor volume was reduced (degree of reduction less than 25%), and no new metastasis or lesion occurred; iPD was recognized when the tumor volume barely changed, and the number of distant metastasis and lesion increased instead. Objective response rate (ORR) = (iCR + iPR)/total number of patients > 100%, disease control rate (DCR) = (iCR + iPR + iSD)/total number of patients > 100%.

**Time to progression (TTP):** The time required from grouping to objective tumor progression was observed and counted for both groups during the follow-up period. Non-progression and survivors were considered censored data following the conclusion of the follow-up.

**Serum-related parameters:** Before treatment and after six treatment cycles, 5 mL fasting venous blood was harvested from each patient in both groups. The serum was separated after high-speed centrifugation and stored in an ultra-low temperature freezer at -80 °C for later use. Serum levels of VEGF, MMP-9, and COX-2 were determined using an enzyme-linked immunosorbent assay [17]. VEGF kits were purchased from Beijing Zhongshan Biotechnology Co., Ltd., MMP-9 kits were bought from Anhui Anke Biological Co., Ltd., and COX-2 kits were purchased from Shanghai Kaibo Biochemical Reagent Co., Ltd. All procedures were performed in strict accordance with the kit instructions.

**Tumor markers:** Prior to treatment and subsequent to six treatment cycles, 5 mL fasting venous blood was collected from each patient in the two groups. The serum was separated after high-speed centrifugation and stored in an ultra-low temperature freezer at -80 °C for later use. The levels of tumor markers HE4, CA125, and CA199 in serum samples were confirmed through enzyme-linked immunosorbent assay [18] with the assistance of an ST-360 automatic enzyme-linked immunosorbent assay analyzer (Shanghai Kehua Experimental Instrument Co., Ltd.). The kits were purchased from Shanghai Youkewei Biotechnology Co., Ltd. All operations were conducted in strict accordance with the kit instructions.

**Adverse reactions:** Gastrointestinal reactions, thrombosis, bone marrow suppression, and liver and kidney function injury, and other adverse reactions and symptoms were closely observed, recorded, and analyzed in both groups, and the incidence was calculated.

### Statistical analysis

All data in this study were processed and analyzed using SPSS 22.0 software. Measurement data were presented as mean  $\pm$  SD, and *t*-test was applied for analysis. Enumeration data were represented as percentages, and  $\chi^2$  test was used for analysis. The Kaplan-Meier method was utilized to calculate the TTP. When  $P < 0.05$ , statistical significance was determined.

## RESULTS

### **Comparison of short-term efficacy between the two groups**

Following distinct treatment strategies, a comparative evaluation of short-term efficacy was conducted between the two groups. The results showed that ORR attained 82.05%, while DCR was 97.44% in the observation group, which were higher than the respective rates of 58.14% and 83.72% in the control group. As highlighted in [Table 2](#), there was a notable difference in the short-term efficacy between the two groups ( $P < 0.05$ ).

### **Comparison of time to disease progression between the two groups**

The Kaplan-Meier analysis displayed that the median TTP was 24 mo (95%CI: 19.987-28.005) in the control group and 37 mo (95%CI: 30.854-43.870) in the observation group, which was better than that in the control group ([Figure 1](#)). The difference was statistically meaningful (log-rank test value = 5.009,  $P = 0.025$ ).

### **Comparison of serum-related index levels between the two groups**

Prior to treatment, no substantial difference was observed in serum VEGF, MMP-9, and COX-2 levels between the two groups ( $P > 0.05$ ). After the adoption of different treatment methods, the above indicators were improved in both groups ( $P < 0.05$ ). VEGF, MMP-9, and COX-2 in the observation group were  $294.81 \pm 20.63$  pg/mL,  $200.43 \pm 15.02$  mg/L, and  $311.36 \pm 22.14$  ng/L, respectively. In contrast, the control group exhibited higher levels of these indicators ( $375.60 \pm 22.05$  pg/mL,  $256.78 \pm 17.62$  mg/L, and  $523.41 \pm 27.48$  ng/L, respectively), as presented in [Table 3](#). The difference held statistical significance ( $P < 0.05$ ).

### **Comparison of tumor marker levels between the two groups**

Prior to treatment, there was no discernible difference in the levels of tumor markers HE4, CA125, and CA199 between the two groups ( $P > 0.05$ ). After distinct treatment strategies, the above indicators in the two groups were vigorously bolstered ( $P < 0.05$ ). HE4, CA125 and CA199 in the observation group were  $121.36 \pm 19.48$  pmol/L,  $35.61 \pm 4.25$  ng/mL and  $56.37 \pm 7.41$  U/mL, respectively. On the contrary, the control group had higher levels of the above indicators ( $184.65 \pm 22.34$  pmol/L,  $58.56 \pm 6.08$  ng/mL, and  $82.84 \pm 9.28$  U/mL, respectively), as displayed in [Table 4](#). The difference held statistical significance ( $P < 0.05$ ).

### **Comparison of the incidence of adverse reactions between the two groups**

The total incidence rate of adverse reactions, including gastrointestinal reactions, thrombosis, bone marrow suppression, and liver and kidney function injury, was significantly lower in the observation group (5.12%) compared to the control group (20.94%), as indicated in [Table 5](#). The difference was statistically significant ( $P < 0.05$ ). Timely symptomatic treatment ameliorated the adverse reactions for patients in both groups and had no substantial impact on the implementation of this treatment plan.

## DISCUSSION

According to global cancer incidence and mortality statistics, colon cancer has emerged as the second most common cancer worldwide, surpassed only by lung cancer, with an incidence rate as high as 10.2% and a mortality rate of 9.2% [19]. CRC exhibits no evident specific symptoms in the early stage and is mostly screened out during routine health examinations. However, patients are typically diagnosed when they seek medical treatment for hematochezia, diarrhea, abdominal pain, weight loss, anemia, and weight loss, at which point they are usually in the middle or advanced stage. Tumor lesions and metastases can severely impair the patient's physical condition, and invasive surgical resection or treatment methods with greater toxicity and side effects may not be suitable for advanced patients [20, 21]. Therefore, it is of paramount significance to explore effective treatment plans for advanced CRC that prolong the patient's life cycle and improve their quality of life.

The primary treatment for early-stage colon cancer is surgical resection of the tumor lesion. However, for advanced colon cancer, the high degree of malignancy and strong metastasis pose significant clinical challenges [22, 23]. In a survey of 7786 patients who underwent resection of colon cancer, Moghadamyeghaneh *et al* [24] reported that approximately 10.8% of patients developed metastases at the time of surgery, and patients with metastatic colon cancer displayed higher postoperative morbidity and mortality than those with localized colon cancer. At present, for the treatment of advanced colon cancer, cytotoxic drugs such as 5-fluorouracil, oxaliplatin, capecitabine, and irinotecan combined with biological agents such as cetuximab, panitumumab, and bevacizumab are mainly used for chemotherapy, with good clinical efficacy in improving progression-free survival and overall survival rates [25-27]. Based on previous studies, this study compared the short-term efficacy, time to progression, incidence of adverse reactions, and changes in serum VEGF, MMP-9, COX-2 levels and

**Table 2 Comparison of short-term efficacy between the two groups, *n* (%)**

Group	iCR	iPR	iSD	iPD	ORR	DCR
Control group ( <i>n</i> = 43)	9 (20.93)	16 (37.21)	11 (25.58)	7 (16.28)	25 (58.14)	36 (83.72)
Observation group ( <i>n</i> = 39)	20 (51.28)	12 (30.77)	6 (15.38)	1 (2.56)	32 (82.05)	38 (97.44)
$\chi^2$					5.518	4.369
<i>P</i> value					0.019	0.037

ORR: Objective response rate; DCR: Disease control rate; iCR: Immune complete response; iPR: Immune partial response; iSD: Immune stable disease; iPD: Immune progressive disease.

**Table 3 Comparison of serum-related index levels between the two groups**

Group	VEGF (pg/mL)		MMP-9 (mg/L)		COX-2 (ng/L)	
	Before treatment	After treatment	Before treatment	After treatment	Before treatment	After treatment
Control group ( <i>n</i> = 43), mean $\pm$ SD	421.38 $\pm$ 36.41	375.60 $\pm$ 22.05 <sup>a</sup>	301.25 $\pm$ 26.73	256.78 $\pm$ 17.62 <sup>a</sup>	711.39 $\pm$ 54.43	523.41 $\pm$ 27.48 <sup>a</sup>
Observation group ( <i>n</i> = 39), mean $\pm$ SD	427.91 $\pm$ 37.23	294.81 $\pm$ 20.63 <sup>a</sup>	308.43 $\pm$ 22.08	200.43 $\pm$ 15.02 <sup>a</sup>	718.43 $\pm$ 49.26	311.36 $\pm$ 22.14 <sup>a</sup>
<i>t</i>	0.802	17.083	1.318	15.504	0.612	38.227
<i>P</i> value	0.425	< 0.001	0.191	< 0.001	0.542	< 0.001

<sup>a</sup>*P* < 0.05 vs before treatment in the same group. VEGF: Vascular endothelial growth factor; MMP-9: Matrix metalloprotein-9; COX-2: Cyclooxygenase-2.

**Table 4 Comparison of tumor marker levels between the two groups**

Group	HE4 (pmol/L)		CA125 (ng/mL)		CA199 (U/mL)	
	Before treatment	After treatment	Before treatment	After treatment	Before treatment	After treatment
Control group ( <i>n</i> = 43), mean $\pm$ SD	343.75 $\pm$ 51.26	184.65 $\pm$ 22.34 <sup>a</sup>	82.43 $\pm$ 11.27	58.56 $\pm$ 6.08 <sup>a</sup>	119.60 $\pm$ 15.62	82.84 $\pm$ 9.28 <sup>a</sup>
Observation group ( <i>n</i> = 39), mean $\pm$ SD	349.81 $\pm$ 45.79	121.36 $\pm$ 19.48 <sup>a</sup>	83.26 $\pm$ 10.33	35.61 $\pm$ 4.25 <sup>a</sup>	121.03 $\pm$ 19.85	56.37 $\pm$ 7.41 <sup>a</sup>
<i>t</i>	0.562	13.610	0.346	19.618	0.364	14.177
<i>P</i> value	0.576	< 0.001	0.730	< 0.001	0.717	< 0.001

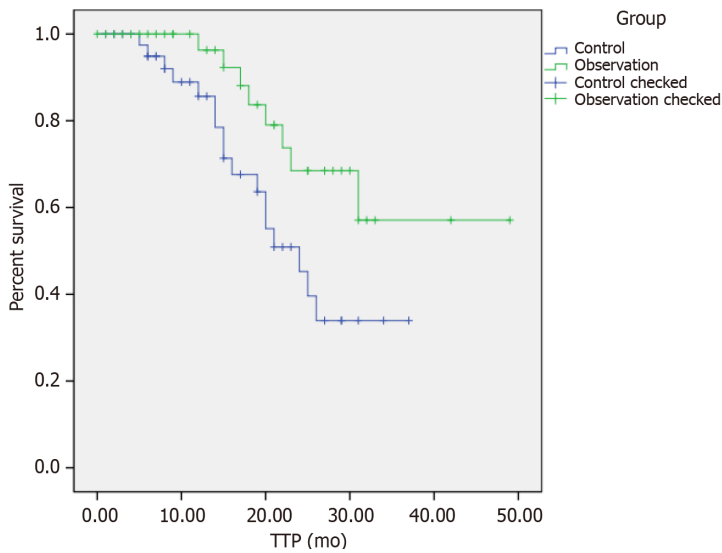
<sup>a</sup>*P* < 0.05 vs before treatment in the same group. HE4: Human epididymis protein 4; CA125: Carbohydrate antigen 125; CA199: Carbohydrate antigen 199.

**Table 5 Comparison of incidence rate of adverse reactions between the two groups, *n* (%)**

Group	Gastrointestinal reactions	Thrombus	Myelosuppression	Hepatic and renal impairment	Total incidence
Control group ( <i>n</i> = 43)	4 (9.30)	1 (2.33)	3 (6.98)	1 (2.33)	9 (20.94)
Observation group ( <i>n</i> = 39)	1 (2.56)	0 (0)	0 (0)	1 (2.56)	2 (5.12)
$\chi^2$					4.397
<i>P</i> value					0.036

tumor markers HE4, CA125, and CA199 levels before and after treatment in advanced colon cancer patients treated with the standard FOLFOX chemotherapy of 5-fluorouracil, oxaliplatin, and Calcium Folate combination, as well as the chemotherapy using olaparib combined with bevacizumab.

In this study, 43 patients in the control group treated with standard FOLFOX chemotherapy and 39 patients in the observation group treated with olaparib combined with bevacizumab chemotherapy



DOI: 10.4240/wjgs.v15.i5.906 Copyright ©The Author(s) 2023.

**Figure 1** Comparison of time to disease progression between control group and observation group. TTP: Time to progression.

were retrospectively analyzed to compare the clinical efficacy, disease progression time and adverse reactions between the two strategies during advanced CRC treatment. The outcomes demonstrated that ORR and DCR in the observation group were higher than those in the control group, the disease progression time was longer than that in the control group, while the total incidence of adverse reactions was lower than that in the control group, indicating that olaparib combined with bevacizumab in the treatment of advanced CRC not only had excellent short-term efficacy, but also prolonged the disease progression of patients, and had smaller toxic and side effects. As compared with the classical FOLFOX chemotherapy, it was safer and more reliable, with better clinical efficacy. FOLFOX chemotherapy is a widely used approach for the clinical management of CRC. Nonetheless, its clinical application may result in bone marrow suppression, digestive system disorders, and nervous system reactions, resulting in significant adverse effects on the patients [28]. Furthermore, studies have reported that approximately 60% of patients with CRC do not respond adequately to FOLFOX chemotherapy [29]. Kim *et al*[30] have pointed out that in patients with unresectable or metastatic CRC, the use of drugs such as olaparib or bevacizumab specifically targets proteins that promote cancer cell proliferation, with fewer toxic effects than FOLFOX chemotherapy. This study's results were consistent with previous reports, demonstrating that olaparib combined with bevacizumab was more effective than oxaliplatin, calcium folinate, and 5-fluorouracil chemotherapy for treating advanced CRC. Specifically, this therapy suppressed the homologous recombination defect of tumor genes by repressing PARP protein and tumor angiogenesis, effectively adopted cytotoxic therapy to increase cell killing, improved the efficiency of killing mutant cancer cells[31], and also effectively delayed tumor angiogenesis. For patients with small tumor masses requiring fewer chemotherapy cycles, it dampened the chance of inducing drug resistance, lowered the possibility of CRC cells becoming resistant to olaparib and bevacizumab, enhanced the immune activity after the resection of large tumors, bettered the clinical efficacy from multiple aspects[32], prolonged the patient's life cycle, and also lessened the damage done to the patient's body by the toxic and side effects of chemotherapeutic drugs[33,34]. This treatment method is relatively safer and more efficient.

Furthermore, this study compared the serum-associated indicators and tumor markers between the two groups subjected to different treatment regimens. The findings revealed no remarkable difference in various indicators between the two groups before treatment, while all indicators were effectively boosted subsequent to distinct treatment regimens. Serum VEGF, MMP-9, and COX-2 levels were significantly reduced in the observation group receiving olaparib combined with bevacizumab compared to the control group. Moreover, a more substantial decrease was observed in tumor markers, including HE4, CA125, and CA199 levels, in the observation group compared to the control group. These results provided evidence that olaparib combined with bevacizumab could effectively dampen tumor neovascularization, kill tumor cells, and assist in reducing tumor burden in patients diagnosed with advanced CRC. VEGF, MMP-9, and COX-2 are critical regulators of tumor angiogenesis, cell migration, as well as extracellular matrix degradation, and are typically present at high levels in advanced CRC[35,36]. HE4, an acidic protein tumor marker mainly expressed in epididymis and vas deferens epithelial cells, has been extensively applied in the diagnosis and prognostic evaluation of cancers such as endometrial cancer, ovarian cancer and lung cancer. The latest studies have also found it abnormally elevated in digestive system tumors [37]. CA125 is a heterogeneous mucin-like glycoprotein widely distributed in the mesothelial cell group and is dramatically heightened in patients with ovarian,

cervical, liver, lung, as well as CRC progression[38]. CA199, a glycolipid substance on the cell membrane, belongs to oligosaccharide tumor-correlated antigens and is widely believed to be highly expressed in patients with cholangiocarcinoma, gastric cancer, liver cancer, as well as colon cancer[39]. Here, bevacizumab was harnessed to block VEGF binding to its receptor to impede tumor neovascularization and suppress the formation of type IV collagen and integral membrane-bound protease[40]. Meanwhile, olaparib functioned in blocking base excision repair, specifically killing cancer cells while also repairing DNA damage after chemotherapy to some extent[41], hence impeding serum VEGF, MMP-9, and COX-2 levels and effectively attenuating the profiles of tumor-related markers HE4, CA125 and CA199 in serum[42].

Nonetheless, this study has some limitations that should be acknowledged. Firstly, the retrospective design of the study may have introduced inherent biases. Additionally, all enrolled cases were from the same hospital, and the research outcomes may be affected by the unique practice of the unit. As such, further prospective studies are recommended to validate these findings and fill the gaps.

## CONCLUSION

In summary, the combination of olaparib and bevacizumab has superior clinical efficacy compared to the conventional FOLFOX chemotherapy regimen for treating patients with advanced CRC. Specifically, the combination therapy was found to significantly delay disease progression and reduce serum VEGF, MMP-9, and COX-2 levels, as well as tumor marker HE4, CA125, and CA199 levels, while also exhibiting fewer adverse reactions and a high level of safety and reliability. These findings provide valuable insights for targeted therapies in the context of advanced rectal cancer and have significant clinical implications.

## ARTICLE HIGHLIGHTS

### **Research background**

Olaparib and bevacizumab are well-established targeted drugs utilized in the treatment of solid tumors in clinical settings. They can exert anti-tumor effects by inhibiting PARP and tumor neovascularization. Advanced colorectal cancer (CRC) has a high degree of malignancy, and conventional surgical treatment and chemotherapy are effective. However, there is a pressing need to identify safe and effective treatments for patients with advanced CRC.

### **Research motivation**

Olaparib combined with bevacizumab in the treatment of advanced CRC has an ideal clinical efficacy.

### **Research objectives**

This study aims to investigate the short-term efficacy, time to progression, safety, and their effects on the serum parameters of olaparib combined with bevacizumab in advanced CRC treatment.

### **Research methods**

Comparisons were made for the assessment of the short-term efficacy, time to progression (TTP), the incidence of adverse reactions, serum-related parameters [vascular endothelial growth factor (VEGF), matrix metalloprotein-9 (MMP-9), cyclooxygenase-2 (COX-2)], and tumor markers [human epididymis protein 4 (HE4), carbohydrate antigen 125 (CA125), carbohydrate antigen 199 (CA199)] levels in patients with advanced CRC treated with classical FOLFOX chemotherapy and olaparib combined with bevacizumab chemotherapy.

### **Research results**

The objective response rate and disease control rate in the observation group were significantly higher than those in the control group, and the median TTP in the observation group was better than that in the control group. After treatment, the serum levels of VEGF, MMP-9, COX-2, HE4, CA125, and CA199 in the observation group were lower than those in the control group, and the total incidence of adverse reactions in the observation group was also lower than that in the control group.

### **Research conclusions**

Olaparib combined with bevacizumab in the treatment of advanced CRC has a remarkable clinical effect. Specifically, the combination can delay the disease and reduce serum VEGF, MMP-9, and COX-2 levels and tumor markers HE4, CA125, and CA199 levels, with a high degree of safety and reliability.



### Research perspectives

The mechanism of olaparib combined with bevacizumab in the treatment of advanced CRC can be further investigated so as to enable a better understanding of its target and provide a comprehensive theoretical basis and data support for the clinical application of this treatment modality in patients with advanced CRC.

---

## FOOTNOTES

**Author contributions:** Jiang YL drafted the manuscript; Jiang YL and Fu XY collected and analyzed the clinical data; Yin ZH designed the study, reviewed and revised the manuscript; and all authors have read and approved the final manuscript.

**Institutional review board statement:** The study was approved by the Ethics Committee of The First Affiliated Hospital, Hengyang Medical School, University of South China.

**Informed consent statement:** The data used in this study were not involved in the patients' private information, so the informed consent was waived by the Ethics Committee of The First Affiliated Hospital, Hengyang Medical School, University of South China. All patient data obtained, recorded and managed are only used for this study, and all patient information is strictly confidential, without any harm to the patient.

**Conflict-of-interest statement:** All the authors report no relevant conflicts of interest for this article.

**Data sharing statement:** No additional data are available.

**Open-Access:** This article is an open-access article that was selected by an in-house editor and fully peer-reviewed by external reviewers. It is distributed in accordance with the Creative Commons Attribution NonCommercial (CC BY-NC 4.0) license, which permits others to distribute, remix, adapt, build upon this work non-commercially, and license their derivative works on different terms, provided the original work is properly cited and the use is non-commercial. See: <https://creativecommons.org/licenses/by-nc/4.0/>

**Country/Territory of origin:** China

**ORCID number:** Zhi-Hui Yin [0000-0002-7794-3010](https://orcid.org/0000-0002-7794-3010).

**S-Editor:** Gong ZM

**L-Editor:** A

**P-Editor:** Zhao S

---

## REFERENCES

- 1 **Patel SG**, Karltz JJ, Yen T, Lieu CH, Boland CR. The rising tide of early-onset colorectal cancer: a comprehensive review of epidemiology, clinical features, biology, risk factors, prevention, and early detection. *Lancet Gastroenterol Hepatol* 2022; **7**: 262-274 [PMID: [35090605](https://pubmed.ncbi.nlm.nih.gov/35090605/) DOI: [10.1016/S2468-1253\(21\)00426-X](https://doi.org/10.1016/S2468-1253(21)00426-X)]
- 2 **Kumar R**, Harilal S, Carradori S, Mathew B. A Comprehensive Overview of Colon Cancer- A Grim Reaper of the 21st Century. *Curr Med Chem* 2021; **28**: 2657-2696 [PMID: [33106132](https://pubmed.ncbi.nlm.nih.gov/33106132/) DOI: [10.2174/0929867327666201026143757](https://doi.org/10.2174/0929867327666201026143757)]
- 3 **Dekker E**, Tanis PJ, Vleugels JLA, Kasi PM, Wallace MB. Colorectal cancer. *Lancet* 2019; **394**: 1467-1480 [PMID: [31631858](https://pubmed.ncbi.nlm.nih.gov/31631858/) DOI: [10.1016/S0140-6736\(19\)32319-0](https://doi.org/10.1016/S0140-6736(19)32319-0)]
- 4 **Baidoun F**, Elshiwly K, Elkeraiye Y, Merjaneh Z, Khoudari G, Sarmini MT, Gad M, Al-Husseini M, Saad A. Colorectal Cancer Epidemiology: Recent Trends and Impact on Outcomes. *Curr Drug Targets* 2021; **22**: 998-1009 [PMID: [33208072](https://pubmed.ncbi.nlm.nih.gov/33208072/) DOI: [10.2174/1389450121999201117115717](https://doi.org/10.2174/1389450121999201117115717)]
- 5 **Mauri G**, Sartore-Bianchi A, Russo AG, Marsoni S, Bardelli A, Siena S. Early-onset colorectal cancer in young individuals. *Mol Oncol* 2019; **13**: 109-131 [PMID: [30520562](https://pubmed.ncbi.nlm.nih.gov/30520562/) DOI: [10.1002/1878-0261.12417](https://doi.org/10.1002/1878-0261.12417)]
- 6 **Khaliq AM**, Erdogan C, Kurt Z, Turgut SS, Grunvald MW, Rand T, Khare S, Borgia JA, Hayden DM, Pappas SG, Govekar HR, Kam AE, Reiser J, Turaga K, Radovich M, Zang Y, Qiu Y, Liu Y, Fishel ML, Turk A, Gupta V, Al-Sabti R, Subramanian J, Kuzel TM, Sadanandam A, Waldron L, Hussain A, Saleem M, El-Rayes B, Salahudeen AA, Masood A. Refining colorectal cancer classification and clinical stratification through a single-cell atlas. *Genome Biol* 2022; **23**: 113 [PMID: [35538548](https://pubmed.ncbi.nlm.nih.gov/35538548/) DOI: [10.1186/s13059-022-02677-z](https://doi.org/10.1186/s13059-022-02677-z)]
- 7 **Chen K**, Collins G, Wang H, Toh JWT. Pathological Features and Prognostication in Colorectal Cancer. *Curr Oncol* 2021; **28**: 5356-5383 [PMID: [34940086](https://pubmed.ncbi.nlm.nih.gov/34940086/) DOI: [10.3390/curroncol28060447](https://doi.org/10.3390/curroncol28060447)]
- 8 **Kim K**, Kim YW, Shim H, Kim BR, Kwon HY. Differences in clinical features and oncologic outcomes between metastatic right and left colon cancer. *J BUON* 2018; **23**: 11-18 [PMID: [30722106](https://pubmed.ncbi.nlm.nih.gov/30722106/)]
- 9 **Vodenkova S**, Buchler T, Cervena K, Veskrnova V, Vodicka P, Vymetalkova V. 5-fluorouracil and other fluoropyrimidines in colorectal cancer: Past, present and future. *Pharmacol Ther* 2020; **206**: 107447 [PMID: [31756363](https://pubmed.ncbi.nlm.nih.gov/31756363/) DOI: [10.1016/j.pharmthera.2019.107447](https://doi.org/10.1016/j.pharmthera.2019.107447)]



- 10 **Limagne E**, Thibaudin M, Nuttin L, Spill A, Derangère V, Fumet JD, Amellal N, Peranzoni E, Cattan V, Ghiringhelli F. Trifluridine/Tipiracil plus Oxaliplatin Improves PD-1 Blockade in Colorectal Cancer by Inducing Immunogenic Cell Death and Depleting Macrophages. *Cancer Immunol Res* 2019; 7: 1958-1969 [PMID: 31611243 DOI: 10.1158/2326-6066.CIR-19-0228]
- 11 **Nappi A**, Berretta M, Romano C, Tafuto S, Cassata A, Casaretti R, Silvestro L, Divitiis C, Alessandrini L, Fiorica F, Ottaiano A, Nasti G. Metastatic Colorectal Cancer: Role of Target Therapies and Future Perspectives. *Curr Cancer Drug Targets* 2018; 18: 421-429 [PMID: 28183254 DOI: 10.2174/1568009617666170209095143]
- 12 **Modest DP**, Pant S, Sartore-Bianchi A. Treatment sequencing in metastatic colorectal cancer. *Eur J Cancer* 2019; 109: 70-83 [PMID: 30690295 DOI: 10.1016/j.ejca.2018.12.019]
- 13 **Garcia J**, Hurwitz HI, Sandler AB, Miles D, Coleman RL, Deurloo R, Chinot OL. Bevacizumab (Avastin®) in cancer treatment: A review of 15 years of clinical experience and future outlook. *Cancer Treat Rev* 2020; 86: 102017 [PMID: 32335505 DOI: 10.1016/j.ctrv.2020.102017]
- 14 **Cremolini C**, Antoniotti C, Rossini D, Lonardi S, Loupakis F, Pietrantonio F, Bordonaro R, Latiano TP, Tamburini E, Santini D, Passardi A, Marmorino F, Grande R, Aprile G, Zaniboni A, Murgioni S, Granetto C, Buonadonna A, Moretto R, Corallo S, Cordio S, Antonuzzo L, Tomasello G, Masi G, Ronzoni M, Di Donato S, Carlomagno C, Clavarezza M, Ritorto G, Mambrini A, Roselli M, Cupini S, Mammoliti S, Fenocchio E, Corgna E, Zagonel V, Fontanini G, Ugolini C, Boni L, Falcone A; GONO Foundation Investigators. Upfront FOLFOX6 plus bevacizumab and reintroduction after progression versus mFOLFOX6 plus bevacizumab followed by FOLFIRI plus bevacizumab in the treatment of patients with metastatic colorectal cancer (TRIBE2): a multicentre, open-label, phase 3, randomised, controlled trial. *Lancet Oncol* 2020; 21: 497-507 [PMID: 32164906 DOI: 10.1016/S1470-2045(19)30862-9]
- 15 **Amin MB**, Greene FL, Edge SB, Compton CC, Gershenwald JE, Brookland RK, Meyer L, Gress DM, Byrd DR, Winchester DP. The Eighth Edition AJCC Cancer Staging Manual: Continuing to build a bridge from a population-based to a more “personalized” approach to cancer staging. *CA Cancer J Clin* 2017; 67: 93-99 [PMID: 28094848 DOI: 10.3322/caac.21388]
- 16 **Inno A**, Lo Russo G, Salgarello M, Corrao G, Casolino R, Galli G, Modena A, Romano L, Pusceddu S, Greco FG, Garassino MC, Gori S. The evolving landscape of criteria for evaluating tumor response in the era of cancer immunotherapy: From Karnofsky to iRECIST. *Tumori* 2018; 104: 88-95 [PMID: 29714647 DOI: 10.1177/0300891618766173]
- 17 **Karsten MM**, Beck MH, Rademacher A, Knabl J, Blohmer JU, Jückstock J, Radosa JC, Jank P, Rack B, Janni W. VEGF-A165b levels are reduced in breast cancer patients at primary diagnosis but increase after completion of cancer treatment. *Sci Rep* 2020; 10: 3635 [PMID: 32108136 DOI: 10.1038/s41598-020-59823-5]
- 18 **Kristjansdottir B**, Levan K, Partheen K, Sundfeldt K. Diagnostic performance of the biomarkers HE4 and CA125 in type I and type II epithelial ovarian cancer. *Gynecol Oncol* 2013; 131: 52-58 [PMID: 23891789 DOI: 10.1016/j.ygyno.2013.07.094]
- 19 **Bray F**, Ferlay J, Soerjomataram I, Siegel RL, Torre LA, Jemal A. Global cancer statistics 2018: GLOBOCAN estimates of incidence and mortality worldwide for 36 cancers in 185 countries. *CA Cancer J Clin* 2018; 68: 394-424 [PMID: 30207593 DOI: 10.3322/caac.21492]
- 20 **André T**, Shiu KK, Kim TW, Jensen BV, Jensen LH, Punt C, Smith D, Garcia-Carbonero R, Benavides M, Gibbs P, de la Fouchardiere C, Rivera F, Elez E, Bendell J, Le DT, Yoshino T, Van Cutsem E, Yang P, Farooqui MZH, Marinello P, Diaz LA Jr; KEYNOTE-177 Investigators. Pembrolizumab in Microsatellite-Instability-High Advanced Colorectal Cancer. *N Engl J Med* 2020; 383: 2207-2218 [PMID: 33264544 DOI: 10.1056/NEJMoa2017699]
- 21 **Bahadoer RR**, Dijkstra EA, van Etten B, Marijnen CAM, Putter H, Kranenbarg EM, Roodvoets AGH, Nagtegaal ID, Beets-Tan RGH, Blomqvist LK, Fokstuen T, Ten Tije AJ, Capdevila J, Hendriks MP, Edhemovic I, Cervantes A, Nilsson PJ, Glimelius B, van de Velde CJH, Hospers GAP; RAPIDO collaborative investigators. Short-course radiotherapy followed by chemotherapy before total mesorectal excision (TME) versus preoperative chemoradiotherapy, TME, and optional adjuvant chemotherapy in locally advanced rectal cancer (RAPIDO): a randomised, open-label, phase 3 trial. *Lancet Oncol* 2021; 22: 29-42 [PMID: 33301740 DOI: 10.1016/S1470-2045(20)30555-6]
- 22 **Wrobel P**, Ahmed S. Current status of immunotherapy in metastatic colorectal cancer. *Int J Colorectal Dis* 2019; 34: 13-25 [PMID: 30465238 DOI: 10.1007/s00384-018-3202-8]
- 23 **Li S**, Ma J, Hong X, Zheng M, Goto S, Takimoto R, Kamigaki T, Zang L. Significant clinical response of advanced colorectal cancer to combination therapy involving capecitabine and adoptive cell transfer therapy: a case report. *Transl Cancer Res* 2019; 8: 693-698 [PMID: 35116802 DOI: 10.21037/ter.2019.02.06]
- 24 **Moghadamyeghaneh Z**, Hanna MH, Hwang G, Mills S, Pigazzi A, Stamos MJ, Carmichael JC. Outcomes of colon resection in patients with metastatic colon cancer. *Am J Surg* 2016; 212: 264-271 [PMID: 27094117 DOI: 10.1016/j.amjsurg.2016.01.025]
- 25 **Sherman SK**, Lange JJ, Dahdaleh FS, Rajeev R, Gamblin TC, Polite BN, Turaga KK. Cost-effectiveness of Maintenance Capecitabine and Bevacizumab for Metastatic Colorectal Cancer. *JAMA Oncol* 2019; 5: 236-242 [PMID: 30489611 DOI: 10.1001/jamaoncol.2018.5070]
- 26 **Zhang PF**, Wen F, Zhou J, Huang JX, Zhou KX, Wu QJ, Wang XY, Zhang MX, Liao WT, Li Q. Cost-effectiveness analysis of capecitabine plus bevacizumab versus capecitabine alone in elderly patients with previously untreated metastatic colorectal cancer from Chinese societal perspective. *Clin Transl Oncol* 2020; 22: 103-110 [PMID: 31062173 DOI: 10.1007/s12094-019-02114-x]
- 27 **Modest DP**, Rivera F, Bachet JB, de Braud F, Pietrantonio F, Koukakis R, Demonty G, Douillard JY. Panitumumab-based maintenance after oxaliplatin discontinuation in metastatic colorectal cancer: A retrospective analysis of two randomised trials. *Int J Cancer* 2019; 145: 576-585 [PMID: 30614531 DOI: 10.1002/ijc.32110]
- 28 **Negarandeh R**, Salehifar E, Saghafi F, Jalali H, Janbabaee G, Abdhaghghi MJ, Nosrati A. Evaluation of adverse effects of chemotherapy regimens of 5-fluoropyrimidines derivatives and their association with DPYD polymorphisms in colorectal cancer patients. *BMC Cancer* 2020; 20: 560 [PMID: 32546132 DOI: 10.1186/s12885-020-06904-3]
- 29 **Kennedy SA**, Morrissey ME, Dunne MR, O’Connell F, Butler CT, Cathcart MC, Buckley AM, Mehigan BJ, Larkin JO,

- McCormick P, Kennedy BN, O’Sullivan J. Combining 1,4-dihydroxy quininib with Bevacizumab/FOLFOX alters angiogenic and inflammatory secretions in *ex vivo* colorectal tumors. *BMC Cancer* 2020; **20**: 952 [PMID: 33008336 DOI: 10.1186/s12885-020-07430-y]
- 30 **Kim TW**, Taieb J, Gurary EB, Lerman N, Cui K, Yoshino T. Olaparib with or without bevacizumab or bevacizumab and 5-fluorouracil in advanced colorectal cancer: Phase III LYNK-003. *Future Oncol* 2021; **17**: 5013-5022 [PMID: 34779646 DOI: 10.2217/fo-2021-0899]
- 31 **Qin C**, Ji Z, Zhai E, Xu K, Zhang Y, Li Q, Jing H, Wang X, Song X. PARP inhibitor olaparib enhances the efficacy of radiotherapy on XRCC2-deficient colorectal cancer cells. *Cell Death Dis* 2022; **13**: 505 [PMID: 35643812 DOI: 10.1038/s41419-022-04967-7]
- 32 **Covens AL**. A critique of surgical cytoreduction in advanced ovarian cancer. *Gynecol Oncol* 2000; **78**: 269-274 [PMID: 10985879 DOI: 10.1006/gyno.2000.5926]
- 33 **Itatani Y**, Kawada K, Yamamoto T, Sakai Y. Resistance to Anti-Angiogenic Therapy in Cancer-Alterations to Anti-VEGF Pathway. *Int J Mol Sci* 2018; **19** [PMID: 29670046 DOI: 10.3390/ijms19041232]
- 34 **Qin S**, Li J, Bai Y, Shu Y, Li W, Yin X, Cheng Y, Sun G, Deng Y, Zhong H, Li Y, Qian X, Zhang L, Zhang J, Chen K, Kang W; HLX04-mCRC03 Investigators. Efficacy, Safety, and Immunogenicity of HLX04 Versus Reference Bevacizumab in Combination with XELOX or mFOLFOX6 as First-Line Treatment for Metastatic Colorectal Cancer: Results of a Randomized, Double-Blind Phase III Study. *BioDrugs* 2021; **35**: 445-458 [PMID: 34014555 DOI: 10.1007/s40259-021-00484-9]
- 35 **Yue YC**, Yang BY, Lu J, Zhang SW, Liu L, Nassar K, Xu XX, Pang XY, Lv JP. Metabolite secretions of *Lactobacillus plantarum* YYC-3 may inhibit colon cancer cell metastasis by suppressing the VEGF-MMP2/9 signaling pathway. *Microb Cell Fact* 2020; **19**: 213 [PMID: 33228670 DOI: 10.1186/s12934-020-01466-2]
- 36 **Zhang Z**, Ghosh A, Connolly PJ, King P, Wilde T, Wang J, Dong Y, Li X, Liao D, Chen H, Tian G, Suarez J, Bonnette WG, Pande V, Diloreto KA, Shi Y, Patel S, Pietrak B, Szwczuk L, Sensenhauser C, Dallas S, Edwards JP, Bachman KE, Evans DC. Gut-Restricted Selective Cyclooxygenase-2 (COX-2) Inhibitors for Chemoprevention of Colorectal Cancer. *J Med Chem* 2021; **64**: 11570-11596 [PMID: 34279934 DOI: 10.1021/acs.jmedchem.1c00890]
- 37 **Kleif J**, Jørgensen LN, Hendel JW, Madsen MR, Vilandt J, Brandsborg S, Andersen LM, Khalid A, Ingeholm P, Ferm L, Davis GJ, Gawel SH, Martens F, Andersen B, Rasmussen M, Christensen IJ, Nielsen HJ. Early detection of colorectal neoplasia: application of a blood-based serological protein test on subjects undergoing population-based screening. *Br J Cancer* 2022; **126**: 1387-1393 [PMID: 35091694 DOI: 10.1038/s41416-022-01712-x]
- 38 **Gao Y**, Wang J, Zhou Y, Sheng S, Qian SY, Huo X. Evaluation of Serum CEA, CA19-9, CA72-4, CA125 and Ferritin as Diagnostic Markers and Factors of Clinical Parameters for Colorectal Cancer. *Sci Rep* 2018; **8**: 2732 [PMID: 29426902 DOI: 10.1038/s41598-018-21048-y]
- 39 **Lin S**, Wang Y, Peng Z, Chen Z, Hu F. Detection of cancer biomarkers CA125 and CA199 via terahertz metasurface immunosensor. *Talanta* 2022; **248**: 123628 [PMID: 35660997 DOI: 10.1016/j.talanta.2022.123628]
- 40 **Schiffmann LM**, Brunold M, Liwschitz M, Goede V, Loges S, Wroblewski M, Quaas A, Alakus H, Stippel D, Bruns CJ, Hallek M, Kashkar H, Hacker UT, Coutelle O. A combination of low-dose bevacizumab and imatinib enhances vascular normalisation without inducing extracellular matrix deposition. *Br J Cancer* 2017; **116**: 600-608 [PMID: 28141797 DOI: 10.1038/bjc.2017.13]
- 41 **Slade D**. PARP and PARG inhibitors in cancer treatment. *Genes Dev* 2020; **34**: 360-394 [PMID: 32029455 DOI: 10.1101/gad.334516.119]
- 42 **Polena H**, Creuzet J, Dufies M, Sidibé A, Khalil-Mgharbel A, Salomon A, Deroux A, Quesada JL, Roelants C, Filhol O, Cochet C, Blanc E, Ferlay-Segura C, Borchellini D, Ferrero JM, Escudier B, Négrier S, Pages G, Vilgrain I. The tyrosine-kinase inhibitor sunitinib targets vascular endothelial (VE)-cadherin: a marker of response to antitumoural treatment in metastatic renal cell carcinoma. *Br J Cancer* 2018; **118**: 1179-1188 [PMID: 29563634 DOI: 10.1038/s41416-018-0054-5]



Published by **Baishideng Publishing Group Inc**  
7041 Koll Center Parkway, Suite 160, Pleasanton, CA 94566, USA

**Telephone:** +1-925-3991568

**E-mail:** [bpgoffice@wjgnet.com](mailto:bpgoffice@wjgnet.com)

**Help Desk:** <https://www.f6publishing.com/helpdesk>

<https://www.wjgnet.com>

