ISSN 1948-9366 (online)

World Journal of

Gastrointestinal Surgery

World J Gastrointest Surg 2023 May 27; 15(5): 745-1006

Published by Baishideng Publishing Group Inc

WJGS

World Journal of Gastrointestinal Surgery

Contents

Monthly Volume 15 Number 5 May 27, 2023

REVIEW

745 Impact of anastomotic leakage on long-term prognosis after colorectal cancer surgery

Tonini V, Zanni M

757 Application of indocyanine green in surgery: A review of current evidence and implementation in trauma patients

Abdelrahman H, El-Menyar A, Peralta R, Al-Thani H

MINIREVIEWS

776 Global dissemination of minimally invasive living donor hepatectomy: What are the barriers?

Kakos CD, Papanikolaou A, Ziogas IA, Tsoulfas G

788 Post-COVID-19 cholangiopathy: Current understanding and management options

Veerankutty FH, Sengupta K, Vij M, Rammohan A, Jothimani D, Murali A, Rela M

799 Changing trends in the minimally invasive surgery for corrosive esophagogastric stricture

Kalayarasan R, Durgesh S

ORIGINAL ARTICLE

Basic Study

812 Distribution of splenic artery lymph nodes and splenic hilar lymph nodes

Umebayashi Y, Muro S, Tokunaga M, Saito T, Sato Y, Tanioka T, Kinugasa Y, Akita K

Case Control Study

825 Preservation of left colic artery in laparoscopic colorectal operation: The benefit challenge

Liu FC, Song JN, Yang YC, Zhang ZT

Retrospective Cohort Study

834 Surgical management of high-grade pancreatic injuries: Insights from a high-volume pancreaticobiliary specialty unit

Chui JN, Kotecha K, Gall TM, Mittal A, Samra JS

847 Surgical management of hydatid cyst disease of the liver: An improvement from our previous experience?

Zaharie F, Valean D, Zaharie R, Popa C, Mois E, Schlanger D, Fetti A, Zdrehus C, Ciocan A, Al-Hajjar N

Retrospective Study

859 Influence of liver function after laparoscopy-assisted *vs* totally laparoscopic gastrectomy

Xiao F, Qiu XF, You CW, Xie FP, Cai YY

Contents

871 Rikkunshito increases appetite by enhancing gastrointestinal and incretin hormone levels in patients who underwent pylorus-preserving pancreaticoduodenectomy: A retrospective study

Kono H, Hosomura N, Amemiya H, Shoda K, Furuya S, Akaike H, Kawaguchi Y, Kawaida H, Ichikawa D

882 Diagnostic performance of texture analysis in the differential diagnosis of perianal fistulising Crohn's disease and glandular anal fistula

Zhu X, Ye DD, Wang JH, Li J, Liu SW

892 Elderly patients over 80 years undergoing colorectal cancer resection: Development and validation of a predictive nomogram for survival

Chok AY, Zhao Y, Chen HLR, Tan IEH, Chew DHW, Zhao Y, Au MKH, Tan EJKW

906 Retrospective efficacy analysis of olaparib combined with bevacizumab in the treatment of advanced colorectal cancer

Jiang YL, Fu XY, Yin ZH

Observational Study

917 $CD4^+CD25^+$ regulatory T cells decreased future liver remnant after associating liver partition and portal vein ligation for staged hepatectomy

Wang W, Ye CH, Deng ZF, Wang JL, Zhang L, Bao L, Xu BH, Zhu H, Guo Y, Wen Z

931 Diagnostic value of matrix metalloproteinases 2, 7 and 9 in urine for early detection of colorectal cancer

Peng L, Zhang X, Zhang ML, Jiang T, Zhang PJ

SYSTEMATIC REVIEWS

940 How far is the endoscopist to blame for a percutaneous endoscopic gastrostomy complication?

Stavrou G, Gionga P, Chatziantoniou G, Tzikos G, Menni A, Panidis S, Shrewsbury A, Kotzampassi K

META-ANALYSIS

953 Nutritional status efficacy of early nutritional support in gastrointestinal care: A systematic review and meta-analysis

He LB, Liu MY, He Y, Guo AL

CASE REPORT

965 Precise mapping of hilar cholangiocarcinoma with a skip lesion by SpyGlass cholangioscopy: A case report

Chiang CH, Chen KC, Devereaux B, Chung CS, Kuo KC, Lin CC, Lin CK, Wang HP, Chen KH

972 Mallory-Weiss syndrome from giant gastric trichobezoar: A case report

Lieto E, Auricchio A, Belfiore MP, Del Sorbo G, De Sena G, Napolitano V, Ruggiero A, Galizia G, Cardella F

978 Giant teratoma with isolated intestinal duplication in adult: A case report and review of literature

Xiong PF, Yang L, Mou ZQ, Jiang Y, Li J, Ye MX

984 Computer-assisted rescue of the inferior mesenteric artery in a child with a giant ganglioneuroblastoma: A case report

Xiu WL, Liu J, Zhang JL, Su N, Wang FJ, Hao XW, Wang FF, Dong Q

Contents

992 Curative resection of leiomyosarcoma of the descending colon with metachronous liver metastasis: A case report

Lee SH, Bae SH, Lee SC, Ahn TS, Kim Z, Jung HI

1000 Modified endoscopic submucosal tunnel dissection for large esophageal submucosal gland duct adenoma: A case report

Chen SY, Xie ZF, Jiang Y, Lin J, Shi H

World Journal of Gastrointestinal Surgery

Monthly Volume 15 Number 5 May 27, 2023

Contents

ABOUT COVER

Editorial Board Member of *World Journal of Gastrointestinal Surgery*, Ashok Kumar, BSc, FACS, FASCRS, FICS, FRCS, FRCS (Ed), MBBS, MCh, Professor, Department of Surgical Gastroenterology, Sanjay Gandhi Post Graduate Institute of Medical Sciences, Lucknow 226014, Uttar Pradesh, India. doc.ashokgupta@gmail.com

AIMS AND SCOPE

The primary aim of *World Journal of Gastrointestinal Surgery* (*WJGS*, *World J Gastrointest Surg*) is to provide scholars and readers from various fields of gastrointestinal surgery with a platform to publish high-quality basic and clinical research articles and communicate their research findings online.

WJGS mainly publishes articles reporting research results and findings obtained in the field of gastrointestinal surgery and covering a wide range of topics including biliary tract surgical procedures, biliopancreatic diversion, colectomy, esophagectomy, esophagostomy, pancreas transplantation, and pancreatectomy, *etc*.

INDEXING/ABSTRACTING

The *WJGS* is now abstracted and indexed in Science Citation Index Expanded (SCIE, also known as SciSearch®), Current Contents/Clinical Medicine, Journal Citation Reports/Science Edition, PubMed, PubMed Central, Reference Citation Analysis, China National Knowledge Infrastructure, China Science and Technology Journal Database, and Superstar Journals Database. The 2022 Edition of Journal Citation Reports® cites the 2021 impact factor (IF) for *WJGS* as 2.505; IF without journal self cites: 2.473; 5-year IF: 3.099; Journal Citation Indicator: 0.49; Ranking: 104 among 211 journals in surgery; Quartile category: Q2; Ranking: 81 among 93 journals in gastroenterology and hepatology; and Quartile category: Q4.

RESPONSIBLE EDITORS FOR THIS ISSUE

Production Editor: *Rui-Rui Wu*; **Production Department Director:** *Xiang Li*; **Editorial Office Director:** *Jia-Ru Fan*.

NAME OF JOURNAL
World Journal of Gastrointestinal Surgery

ISSN
ISSN 1948-9366 (online)

LAUNCH DATE
November 30, 2009

FREQUENCY
Monthly

EDITORS-IN-CHIEF
Peter Schemmer

EDITORIAL BOARD MEMBERS
https://www.wjgnet.com/1948-9366/editorialboard.htm

PUBLICATION DATE
May 27, 2023

COPYRIGHT
© 2023 Baishideng Publishing Group Inc

INSTRUCTIONS TO AUTHORS
https://www.wjgnet.com/bpg/gerinfo/204

GUIDELINES FOR ETHICS DOCUMENTS
https://www.wjgnet.com/bpg/GerInfo/287

GUIDELINES FOR NON-NATIVE SPEAKERS OF ENGLISH
https://www.wjgnet.com/bpg/gerinfo/240

PUBLICATION ETHICS
https://www.wjgnet.com/bpg/GerInfo/288

PUBLICATION MISCONDUCT
https://www.wjgnet.com/bpg/gerinfo/208

ARTICLE PROCESSING CHARGE
https://www.wjgnet.com/bpg/gerinfo/242

STEPS FOR SUBMITTING MANUSCRIPTS
https://www.wjgnet.com/bpg/GerInfo/239

ONLINE SUBMISSION
https://www.f6publishing.com

© 2023 Baishideng Publishing Group Inc. All rights reserved. 7041 Koll Center Parkway, Suite 160, Pleasanton, CA 94566, USA
E-mail: bpgoffice@wjgnet.com https://www.wjgnet.com

World Journal of Gastrointestinal Surgery

Submit a Manuscript: https://www.f6publishing.com

World J Gastrointest Surg 2023 May 27; 15(5): 788-798

DOI: 10.4240/wjgs.v15.i5.788

ISSN 1948-9366 (online)

MINIREVIEWS

Post-COVID-19 cholangiopathy: Current understanding and management options

Fadl H Veerankutty, Kushan Sengupta, Mukul Vij, Ashwin Rammohan, Dinesh Jothimani, Ananthavadivelu Murali, Mohamed Rela

Specialty type: Gastroenterology and hepatology

Provenance and peer review: Invited article; Externally peer reviewed.

Peer-review model: Single blind

Peer-review report's scientific quality classification

Grade A (Excellent): 0
Grade B (Very good): 0
Grade C (Good): C, C
Grade D (Fair): 0
Grade E (Poor): 0

P-Reviewer: Fouad MM, Egypt; Freund O, Israel

Received: November 23, 2022
Peer-review started: November 23, 2022
First decision: January 2, 2023
Revised: February 10, 2023
Accepted: April 7, 2023
Article in press: April 7, 2023
Published online: May 27, 2023

Fadl H Veerankutty, Institute of Liver Disease and Transplantation, Dr. Rela Institute and Research Centre, Chennai 600044, India

Kushan Sengupta, Ashwin Rammohan, Dinesh Jothimani, Mohamed Rela, Institute of Liver Disease and Transplantation, Dr. Rela Institute and Medical Centre, Chennai 600044, India

Mukul Vij, Department of Pathology, Institute of Liver Disease and Transplantation, Chennai 600044, India

Ananthavadivelu Murali, Gastroenterology and Hepatology, Clinician's Point, Chennai 600014, Tamil Nadu, India

Corresponding author: Fadl H Veerankutty, MBBS, MS, FMAS, DrNB (Gastrointestinal Surgery), Post-Doctoral Fellowship in Liver Transplant & HPB Surgery, Consultant Physician-Scientist, Surgeon, Institute of Liver Disease and Transplantation, Dr. Rela Institute and Research Centre, 7, CLC Works Rd, Nagappa Nagar, Chromepet, Chennai 600044, India. fadl_05@yahoo.com

Abstract

Post-coronavirus disease 2019 (COVID-19) cholangiopathy (PCC) is a rare but life-threatening complication of COVID-19 infection. PCC typically presents when patients recovering from the contagion and manifests as cholestasis in patients with no history of pre-existing liver disease. The pathogenesis of PCC is little understood. Hepatic injury in PCC could be mediated by the predilection of severe acute respiratory syndrome coronavirus 2 for cholangiocytes. Though PCC shows some resemblance to secondary sclerosing cholangitis in critically ill patients, it is considered as a separate and unique entity in the literature. Various treatment options like ursodeoxycholic acid, steroids, plasmapheresis, and endoscopic retrograde cholangiopancreatography guided interventions have been tried but with limited success. We have noticed significant improvement in liver function with antiplatelet therapy in a couple of patients. PCC can progress to end-stage liver disease necessitating liver transplantation. In this article, we discuss the current knowledge of PCC focusing on its pathophysiology, clinical manifestations, and management strategies.

Key Words: COVID-19; Liver; Post-COVID-19 syndrome; Long haulers; Cholangiopathy; Cholestasis

©The Author(s) 2023. Published by Baishideng Publishing Group Inc. All rights reserved.

Core Tip: Post-coronavirus disease 2019 (COVID-19) cholangiopathy (PCC) is a rare complication of COVID-19 infection with gruesome prognosis. There is no proven treatment for this entity and patients often end up in liver transplantation. This review focusses on pathophysiology, clinical manifestations and management strategies of PCC along with our experience with antiplatelets in managing patients with PCC.

Citation: Veerankutty FH, Sengupta K, Vij M, Rammohan A, Jothimani D, Murali A, Rela M. Post-COVID-19 cholangiopathy: Current understanding and management options. *World J Gastrointest Surg* 2023; 15(5): 788-798
URL: https://www.wjgnet.com/1948-9366/full/v15/i5/788.htm
DOI: https://dx.doi.org/10.4240/wjgs.v15.i5.788

INTRODUCTION

World health organization declared coronavirus disease 2019 (COVID-19) as a global pandemic in March 2020[1]. Though severe acute respiratory syndrome corona virus 2 (SARS-CoV-2) mainly affects the respiratory system, studies have demonstrated that organotropism of the virus can cause multisystem inflammation[2,3]. Hypercoagulability associated fatal cardiovascular, cerebrovascular, and gastrointestinal complications have been reported. Derangements in liver function tests (LFT) are the most frequent hepatic manifestation of COVID-19, and its incidence among hospitalized COVID-19 patients varies between 14% to 83%[4-10]. However, the spectrum of liver injury due to COVID-19 extends beyond just abnormalities in LFT. Other attributed hepatic effects of this contagion include vascular thromboses, cholangiopathy, and COVID-19 vaccine-related auto-immune hepatitis[11-13]. Remarkably, 'Long haul COVID' or 'post-COVID syndrome' (a collective term used to denote the persistence of symptoms or development of delayed complications beyond four weeks after the initial presentation of COVID-19) has also been known to adversely affect the liver[14,15].

Although COVID-19 results most commonly in a hepatocellular pattern of liver injury, severe cholestasis has also been occasionally noted[16-20]. Roth *et al*[13] labeled this unique entity of severe cholestasis as post-COVID-19 cholangiopathy (PCC)[21]. PCC typically presents when patients recover from COVID-19 and manifests as cholestasis in patients with no history of pre-existing liver disease. PCC is diagnosed in less than 1% of patients hospitalized for COVID-19[22]. Literature regarding this newly described entity is sparse, and the natural course of the disease remains unknown. We searched PubMed, *Reference Citation Analysis* (RCA), and Web of Science using Mesh words such as "post-Covid-19 cholangiopathy", "COVID-19 sclerosing cholangiopathy", "Covid-19 and liver", and "COVID-19 and liver transplantation". The data on pathogenesis, histology, imaging findings, clinical features, management, and outcomes were collected. This review summarizes the current knowledge of PCC, focusing on its pathophysiology, clinical manifestations, and management strategies.

PATHOGENESIS

SARS-CoV-2 utilizes angiotensin converting enzyme 2 (ACE2) receptor to enter the host cell and the internalisation process is aided by the host cell transmembrane serine protease 2. ACE2 receptors are expressed in various human organs including lung, liver, intestine, kidney, and heart[23,24]. The binding of SARS-CoV-2 to ACE2 receptor impairs ACE2 activity leading to the enhanced effect of angiotensin-2 resulting in an inflammatory and hypercoagulable state. In the liver, ACE2 receptors are more intensely expressed on cholangiocytes (59.7%) than on hepatocytes[24]. Cholangiocytes modify hepatocyte-derived bile acids, and the tight junction between these cells is essential for bile acid accumulation and excretion. Experimental studies using liver ductal organoid culture showed that SARS-CoV-2 can cause dysregulation of genes engaged in tight junction formation and bile acid transportation, thereby resulting in an impaired barrier and defective bile acid transportation. This mechanism of injury has been purported as the cause for direct cholangiocytic injury and consequent bile acid accumulation, resulting in severe and prolonged hepatic damage caused by COVID-19[25].

Ischemia injury, especially to the cholangiocytes has also been implicated in the causality of PCC. ACE2 receptors are expressed on vascular endothelial cells and SARS-CoV-2 can lead to uncontrolled inflammation through the interleukin (IL)-6 signaling pathway. Endothelitis results in hypercoagulability and thrombosis of the peribiliary vascular plexus aggravating biliary ischemia. Shreds of evidence in favor of this hypothesis include endothelial swelling with luminal narrowing of the hepatic arterioles and portal venous endophlebitis reported on histological examination of PCC specimens.

Furthermore, improvement in liver function on treatment with antiplatelets in two of our patients (detailed below) also implicates the role of microvascular events in the pathogenesis of PCC[26]. On the contrary, a few studies noted no significant microvascular thrombi in their patients' livers with PCC[22,27,28].

Due to their similar clinicopathological features, many researchers believe that PCC is a variant of secondary sclerosing cholangitis in critically ill patients (SSC-CIP). SSC-CIP is a rare form of secondary sclerosing cholangitis which occurs in patients with no history of hepatobiliary disease after a long intensive care unit stay for various conditions requiring prolonged mechanical ventilation and high-dose vasopressors. SSC-CIP was first described by Scheppach *et al*[29]. The pathogenesis of SSC-CIP is not fully elucidated, but the main mechanism appears to be bile duct ischemia. Other proposed causes include changes in the composition of the bile and biliary infection[30]. Ischemia leads to necrosis and sloughing of biliary epithelium resulting in biliary cast formation. Ischemia can also damage hepatobiliary transporters involved in the protective barrier mechanism of cholangiocytes from toxic bile salts. Progression to cirrhosis may occur over several months[31,32]. SSC-CIP has a mortality of over 50% in severe cases and up to a fifth of patients require a liver transplant (LT)[33,34]. Damages to extra and intrahepatic biliary ducts, cholangiocyte necrosis and biliary epithelial destruction, ductular reaction, and progressive fibrosis portal tracts are features common to PCC and SSC-CIP. Though PCC is typically described in patients with severe COVID-19 who required prolonged mechanical ventilation, few authors have reported cases of severe cholestasis in patients with mild to moderate COVID-19[17,18]. In contrast to acquired immunodeficiency syndrome cholangiopathy, the opportunistic infection has not been implicated as an etiological factor of PCC.

Some authors attributed PCC to ketamine related hepatobiliary damage, a condition called Ketamine induced cholangiopathy. Ketamine is metabolised in the liver and is used for sedation of patients with respiratory distress. Two recent articles reported patients with severe COVID-19 developed cholestatic liver disease with features of sclerosing cholangitis after exposure to ketamine. Nonetheless, a majority of other reports of PCC do not mention the use of ketamine. Antiviral drugs, particularly remdesivir and immunomodulatory agents like tocilizumab (IL-6 receptor antagonist) used in the management of COVID-19 are known to cause hepatic injury. The use of these agents has not been uniformly reported in any of the published cases of PCC. Moreover, there is insufficient evidence to prove that these medications may cause cholangiopathy.

CLINICAL, BIOCHEMICAL & IMAGING FEATURES

Patients with PCC are predominantly males (80%) and their median age at presentation is over 50 years [13,23,35-37] (Table 1). Patients typically present with jaundice with or without pruritus several weeks or months after the initial admission in intensive care units for severe COVID-19[13,37]. Significantly, these patients have no prior history of liver disease. Diabetes mellitus is the most common comorbid condition reported[37]. LFTs at the time of admission following COVID-19 diagnosis are almost always near-normal. In a cohort of 24 patients with PCC from various German centers, the median serum total bilirubin level at admission was 0.6 mg/dL (N: 0.6-1.2 mg/dL), while at the time of diagnosis of PCC it was 11.9 mg/dL[37]. The highest serum total bilirubin level reported in a patient with PCC was 42.4 mg/dL[16]. Gross elevation of serum alkaline phosphatase (ALP) levels, with peak levels above 1000 U/L (N: 20-140 U/L) have been commonly reported[13,22,27]. Remarkably, these biochemical changes in PCC are similar to that observed in patients with SSC-CIP[37].

In a series of 12 cases reported by Faruqui *et al*[22] mean interval between the initial diagnosis of COVID-19 and the diagnosis of PCC by magnetic resonance cholangiopancreatography (MRCP) was 118 d. All 12 patients in their series, showed some structural changes in the biliary system on MRCP [35]. Intrahepatic bile duct strictures and the beaded appearance of intrahepatic bile ducts were the most commonly noted findings[13,22]. Ghafoor *et al*[35] studied magnetic resonance imaging/MRCP of 17 patients with PCC, and noted that none of the patients had cirrhosis or vascular thrombosis. Strictures in the form of beading of intrahepatic bile ducts were seen in 14 (82.3%) patients and biliary casts were seen in 2 (11.8%) patients. In addition to biliary abnormalities, liver contour irregularities and signal intensity changes in PCC livers can also be ascertained on MRCP.

HISTOPATHOLOGY

On macroscopic examination, the PCC livers are described to have a greenish discoloration[13,38,39] (Figure 1A). Brightfield microscopy may show portal/periportal fibrous expansion with bile ductular proliferation and degenerative cholangiocyte injury accompanied by leucocytes[13,39]. Loss of interlobular bile ducts has been described in PCC (Figure 1B). Ductular bile plugs and bile lakes are reported. Lobular disarray, hepatocanalicular bilirubinostasis with rosetting, and patchy lobular inflammation may be seen. Hilar bile ducts with inflammation and fibrosis have been described. Portal veins may show fibrin thrombi (Figure 1C). A case from the authors' series also showed Mallory Denk bodies

Table 1 A summary of reported cases of post-coronavirus disease 2019 cholangiopathy in the literature

Ref.	Number of patients	Age, median (range)	Sex	Time interval between COVID-19 diagnosis and presentation with features of PCC	Peak bilirubin (mg/dL)	Peak ALP (U/L)	MRCP	Biopsy	Treatment	Outcome reported
Edwards *et al*[21], 2020	1	59	Male	Time to elevation of bilirubin: 15 d. Peak at 79 d	14.6	4000	Beading of intrahepatic ducts	Not reported	ERCP for sludge clearance	Alive (planning biopsy to decide on liver transplantation)
Roth *et al* [13], 2021	3	34 (25-40)	2 males, 1 female	Around 6 mo	Patient 1-7 gm/dL, patient 2-24 and patient 3-15	16 × ULN	Two of three: Hepatomegaly. One of three: Extrahepatic bile ducts dilatation and one of three: Intrahepatic bile ducts strictures and dilatations with beaded aspect or solely dilatation	Two of three: Mild and moderate bile ducts paucity. Three of three moderate ductular reaction, cholangiocytes swelling and regenerative changes with portal tract inflammation, hepatic artery endothelial swelling, hepatic veins endophlebitis and periportal fibrosis	Conservative	Two patients discharged home, one still hospitalized
Faruqui *et al*[22], 2021	12	58 (38-73)	Male: 92%; female: 8%	Mean interval-118 d	Range: 2-35	Range: 965-2544	Eleven of twelve patents showed beaded images of intrahepatic bile ducts, seven of twelve patients showed bile ducts thickening and hyperenhancement, ten of twelve patients showed peribiliary diffusion high signal	Performed in four of twelve pts. Acute or chronic large bile ducts obstruction, mild fibrosis of some portal tracts, Keratin 7 immunostain positivity	UDCA. UDCA slightly improved some lab tests (AST and ALT) but GGT and ALP remained elevated	Four of twelve died for complications consequent to sclerosing cholangiopathy, 2/12 listed for transplantation, 5/12 continuing conservative management
Durazo *et al*[27], 2021	1	47	Male	Around 2 mo	19	1644	Mild intrahepatic bile ducts dilatation with focal strictures and beaded aspect, no dilatation of CBD	Inflammatory mononuclear infiltrates of bile ducts walls with increased collagen deposition, liver abscesses and bile lakes associated with bile duct injury with vacuolization and neutrophilia. Endothelial cell swelling, lumen obliteration of arterial vessels and obliterative portal venopathy	Liver transplantation	Alive with normal LFT at 7 mo after liver transplantation
Tafreshi *et al*[42], 2021	1	38	Male	Cholestasis at a few months after initial hospital admission	9.8	3665	Mild dilatation of intrahepatic bile ducts with beaded aspect, dilatation of CBD and periportal oedema	Cholangiocytes injury, ductular proliferation, canalicular cholestasis, a bile lake and focal bridging fibrosis	Under evaluation for liver transplantation	Under evaluation for liver transplantation

Lee *et al* [38], 2021	1	64	Male	51 d	7.8	1600	Mild intrahepatic biliary ductal dilatation and mild patchy T2 hyperintensity within the right hemiliver, concerning for cholangitis	Explant pathology: Bridging fibrosis, severe bile duct injury, ductular reaction and leucocytes and plasma cells infiltrate	Liver transplantation	Alive at 8 mo and returned to work
Klindt *et al* [43], 2021	1	47	Male	Around 50 d	18	1700	Alterations of medium and small intrahepatic bile ducts	Enlarged portal tracts with phlogistic infiltrate, ductular reaction with degenerative alterations of bile duct epithelium; focal biliary metaplasia of periportal hepatocytes. A few bile infarcts and perivenular canalicular cholestasis	Liver transplantation	Alive
Rojas *et al* [44], 2021	1	29	Female	Around 2 mo	19	6000	Only a cystic lesion in liver segment V	Low periportal phlogistic infiltrate without necrosis but with a severe obstructive cholestatic pattern	UDCA and cholestyramine	Slight improvement at the time of reporting
Bütikofer *et al*[28], 2021	4	59 (54-67)	Male: 3, female: 1	70-153 d	3.81-26.05	(12.85-21.26) × ULN	Diffuse irregularities of the bile ducts with dilatations and strictures	Portal inflammation with pericellular fibrosis	UDCA	2 patients: Deceased. 1 patient: Listed for liver transplantation (MELD-17). 1 patient: Persistently marked increased ALP and GGT at 9 mo of follow up
Rela *et al* [16], 2022	1	50	Male	4 wk	42.4	248	Mild prominence of central intrahepatic, common hepatic, and common bile ducts with minimal beading of the right posterior sectoral and segment 2 ducts	Mild portal tract inflammation with lymphocytes, histiocytes and few eosinophils, with loss of interlobular bile ducts	Auxiliary partial orthotopic liver transplantation	Asymptomatic at 6 mo follow-up with good graft function and recovering function in native liver remnant
Kulkarni *et al*[17], 2022	15	Unvaccinated: 59 (24-67). Vaccinated: 52 (29-67)	Unvaccinated: Male (8/8, 100%). Vaccinated: Male (5/7, 71.4%)	The median time to the development of cholestasis was 35 (19-44) d and in vaccinated group and 39.5 (27-57) in the unvaccinated group	Unvaccinated group: 22.95 (4.2-48.5), vaccinated group 17 (8.3-32.4)	312 (239-517) U/L in the vaccinated group and 571.5 (368-1058) U/L in the unvaccinated group	Normal in all patients	Architectural distortion, fibrosis, cholestasis, and ductular reaction with duct openia in unvaccinated group. Cholestasis and inflammation and no fibrosis in vaccinated group	UDCA. Plasma exchange: 5. Oral steroids: 4	2-died. 2-liver transplantation. 2-listed for liver transplantation. 1-declined liver transplantation. 2-recovered. All 7 in vaccinated group recovered
Mayorquín-Aguilar *et al*[45], 2022	3	46 (45-52)	Male	12-14 wk in two patients and 20 d in another patient	17.32 (5.8-22.7)	1328 (705-1695)	Irregular morphology of intrahepatic and extrahepatic bile ducts. Multiple areas of stenosis in the distal intrahepatic bile ducts	Intracanalicular cholestasis, portal inflammation, ductular reaction, and moderate portal fibrosis	UDCA, cholestyramine, and sertraline	Persisitent cholestasis in one patient and disease progressed to cirrhosis in another patient. Third patient expired due to unrelated cause

Hunyady *et al*[37], 2023	24	57 (19-73)	Out of 24 patients, 20 were male, 4 females	91 d (IQR: 64-154 d)	Peak bilirubin 24.3 mg/dL. Median bilirubin 11.9 mg/dL (6.0-24.3)	Peak ALP 1100 U/L. Median ALP 925 U/L. (555-1100)	Strictures or dilatation of biliary system, rarefication of biliary tree including contrast filling defects or detection of biliary casts	-	UDCA in 16 (66.7%) patients, ERCP with sphincterotomy done in 20 (83.3%) patients. Cast extraction done in 11 (45.8% patients). 3 patients underwent liver transplantation	3 patients underwent liver transplantation. 2 patients had transplant free survival

ULN: Upper limit of normal; UDCA: Ursodeoxycholic acid; COVID-19: Coronavirus disease 2019; ALP: Alkaline phosphatase; PCC: Post-coronavirus disease 2019 cholangiopathy; IQR: Interquartile range; ERCP: Endoscopic retrograde cholangiopancreatography; GGT: Gamma glutamyl transpeptidase; MELD: Model for end-stage liver disease; CBD: Cannabidiol; LFT: Liver function test; MRCP: Magnetic resonance cholangiopancreatography; ALT: Alanine aminotransferase; AST: Aspartate aminotransferase.

along with patchy sinusoidal dilatation and congestion with hepatocyte atrophy (Figure 1D). In late cases, bridging fibrosis and cirrhosis have been reported[13,38]. Immunostaining with CK7 may show biliary metaplasia of hepatocytes (Figure 1E). Pathognomonic findings of PCC on immunohistochemistry include a granular cytoplasmic positivity for SARS-CoV-2 within hepatocytes and sinusoidal macrophages (Figure 1F).

TREATMENT

Given that PCC is a recently described disease arising out of the COVID-19 pandemic, little is known about its natural history. Anecdotal evidence of various treatment modalities is present in the literature, and currently, there is no well-defined treatment algorithm. Though universally used for PCC, medical treatment with ursodeoxycholic acid and cholestyramine does not seem to offer much clinical or biochemical improvement. Antiplatelet medications have serendipitously shown benefits (two patients from the authors' series). However, the exact indication, timing, dose, and duration of this regimen remain unknown. Franzini *et al*[40] recently published a video demonstration of their experience with cholangioscopy (SpyGlass®) to assess bile duct changes and removal of biliary casts. In patients with biliary casts or cholangitis, interventions using endoscopic retrograde cholangiopancreatography may offer transient improvement of the clinical condition, but abnormal liver functions are likely to persist even after an anatomical clearance of the extrahepatic ducts[13,36].

LIVER TRANSPLANTATION FOR PCC

In most patients, the disease causes progressive biliary injury with worsening cholestasis and recurrent infections[16,22]. The first successful LT for PCC was reported by Durazo *et al*[27]. A 47-year-old man with PCC and worsening liver and renal function underwent deceased donor liver transplantation on day 108 from the initial presentation with COVID-19. Histopathology of the explanted liver showed features of severe sclerosing cholangitis with hepatic abscesses. The patient improved well and graft

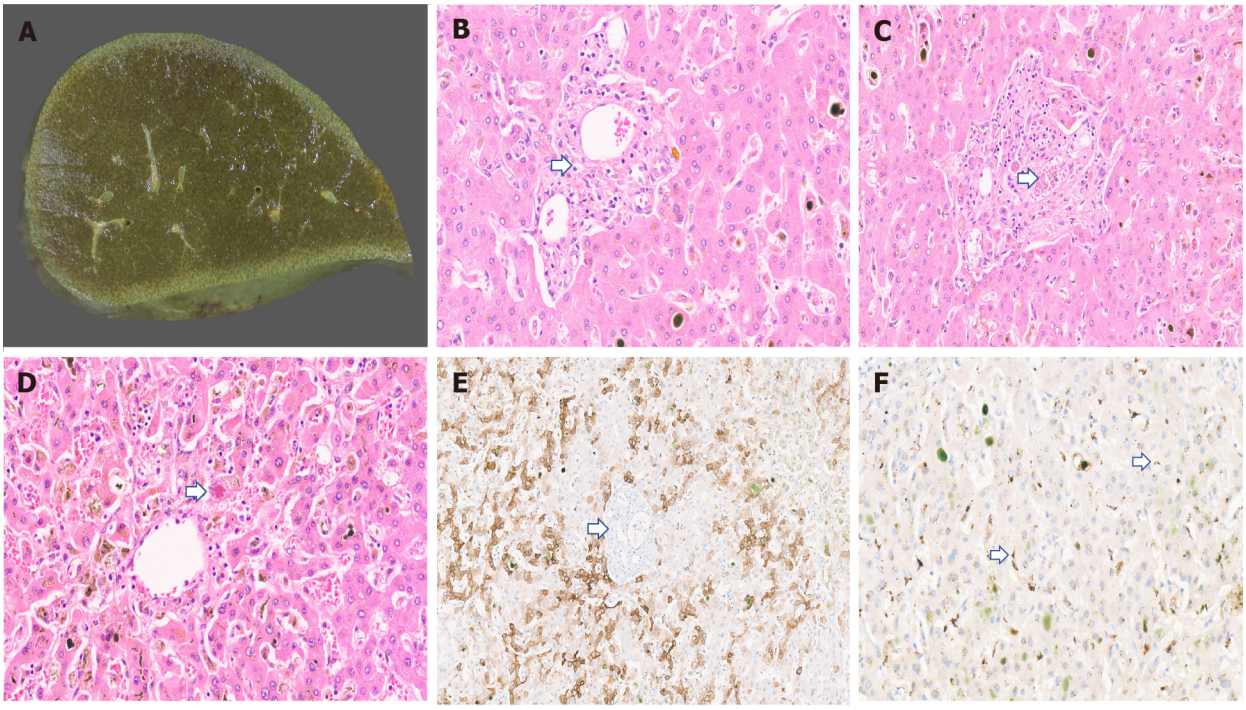

DOI: 10.4240/wjgs.v15.i5.788 **Copyright** ©The Author(s) 2023.

Figure 1 Histopathology imaging. A: Explant liver cut surface with greenish discolouration; B: Explant liver displaying duct loss (arrow) and bilirubinostasis [× 20, hematoxylin and eosin (H&E)]; C: Fibrin thrombi in portal vein (arrow, × 18, H&E); D: Mallory Denk body in a hepatocyte (arrow) and mild lobular inflammation (× 18, H&E); E: CK7 immunostaining with duct loss (arrow) and biliary metaplasia of hepatocytes (× 15); F: Severe acute respiratory syndrome coronavirus 2 immunostaining with granular brown positivity in hepatocytes and macrophages (arrow, × 15).

function was normal at 7 mo after LT. Subsequently, various authors reported their experience with LT for patients with PCC[16,22,38]. Our team reported a living donor auxiliary right lobe LT (APOLT) in a 50-year-old patient at 12 wk after the initial diagnosis of COVID-19. The patient underwent a right trisectionectomy with caudate lobectomy. The right lobe was retrieved robotically from a related donor and implanted orthotopically. Interestingly, hepatobiliary scintigraphy at six months follow-up showed 90% and 10% in the graft and native livers respectively, reflecting some native liver recovery[16]. The authors' premise was that since the natural course of PCC is unknown, there remains the possibility of spontaneous liver recovery. Thus, the allograft in APOLT potentially acts as a bridge till native regeneration occurs, providing the patient with a realistic possibility of becoming immunosuppression-free. While LT is an effective curative option for patients with PCC, it is naïve to offer it to every patient with PCC. It is also sobering to realise that several variables of this management continue to be undefined. These include vital data to define which cohort of patients are likely to recover without an LT. It is likely that these questions will have answers as experience grows with this disease entity.

COVID-19 VACCINATION AND PCC

In the current era of near-universal COVID-19 vaccination, it is important to re-evaluate the natural course of PCC. Vaccination has been shown to reduce the severity of COVID-19 and improve outcomes [41]. Kulkarni *et al*[17] compared 8 unvaccinated patients with 7 vaccinated patients with post-COVID-19 cholestasis and showed that serum ALP and gamma glutamyl transpeptidase (GGT) were significantly lower in the vaccinated group. Furthermore, all patients in the vaccinated group improved with conservative management while a majority in the unvaccinated group required LT. Again, literature in this regard is scarce, but intuitively, COVID-19 vaccination is likely to play a positive role in preventing/attenuating the course of PCC.

OUR EXPERIENCE

Our experience with PCC is limited to four patients. All of them presented with severe cholestatic jaundice following initial recovery from COVID-19 illness[26] (Table 2). All were men in their 5th or 6th decade of life. Unlike other reported series, only half of our patients had a history of mechanical ventilation for their COVID-19 related respiratory illness. Clinical recovery from COVID-19 was

Table 2 A summary of authors' experience with post coronavirus disease 2019 cholangiopathy

Case	Age/sex	ICU admission for COVID	Mechanical ventilation for COVID	Medications received for COVID	LFT at initial admission for COVID	LFT (peak values)	Time interval[1]	MRCP	Biopsy	Treatment	Outcome
1	67/male	Yes (hypoxia-high flow oxygen)	No	Remdesivir, methylprednisolone	Bilirubin 0.84 mg/dL, AST 54 U/L, ALT 32 U/L, ALP 127 U/L, GGT 78 U/L and albumin 4.1 mg/dL	Bilirubin 12.7 mg/dL, AST 322 U/L, ALT 527 U/L, ALP 474 U/L and GGT 1318 U/L, albumin 3.2 g/dL, INR 0.98	4 wk	Normal except for cholelithiasis	Mild portal fibrous expansion with diffuse loss of interlobular bile ducts	Prednisolone, ursodeoxycholic acid	Hyperbilirubinemia continued to worsen. Expired of pneumonia
2	50/male	Yes	Yes	Methylprednisolone, Remdesivir, antibiotics and thromboprophylaxis	Bilirubin 0.5 mg/dL, AST 43 U/L, ALT 57 U/L, ALP 60 U/L, GGT 64 U/L, albumin 2.8 mg/dL	Bilirubin 31.3 mg/dL, ALP 248 U/L, GGT 355 U/L, AST 176 U/L and ALT 200 U/L	6 wk	Mild prominence of central intrahepatic, common hepatic, and common bile ducts with minimal beading of the right posterior sectoral and segment 2 ducts	Mild portal tract inflammation with lymphocytes, histiocytes and few eosinophils, with loss of interlobular bile ducts	Auxiliary partial orthotopic liver transplantation	Asymptomatic at 6 mo follow-up with good graft function and recovering function in native liver remnant
3	58/male	No	No	Doxycycline, ivermectin, methylprednisolone. Remdesivir, paracetamol along with zinc and other vitamin supplements	Bilirubin 1.99 mg/dL, AST 145 U/L, ALT 140 U/L, ALP 70 U/L, GGT 65 U/L and albumin 4.1 g/dL	Bilirubin 10 mg/dL, AST 167 U/L, ALT 181 U/L, ALP 532 U/L and GGT 728 U/L	6 wk	Normal	Bile duct degenerative changes in majority of portal tracts along with prominent centrilobular hepatocanalicular bilirubinostasis	Aspirin, clopidogrel, prednisolone, ursodeoxycholic acid	Improved, LFT at 18 mo of follow up. Bilirubin 1.3 mg/dL, AST 101 U/L, ALT 101 U/L, ALP 309 U/L
4	52/male	Yes	Yes	Amoxycillin, remedesivir, IV methyl prednisolone	Bilirubin 1 mg/dL, albumin 4.2 g/dL, ALT 25 U/L, AST 49 U/L, ALP 110 U/L, GGT 62 U/L	Bilirubin 33.9 mg/dL ALP 390 U/L, ALT 41 U/L, GGT 94 U/L, AST 58 U/L	6 wk	Normal	Bile ducts showed mild injury, lobular bilrubinostasis	Therapeutic plasma exchange, aspirin, clopidogrel, prednisolone, ursodeoxycholic acid	Improved, LFT at 6 mo of follow up. Bilirubin 1.1 mg/dL, ALP 101 U/L, AST 23 U/L, ALT 32 U/L

[1]Time interval between coronavirus disease 2019 (COVID-19) diagnosis and presentation with features of post-COVID-19 cholangiopathy.

COVID: Coronavirus disease; ALP: Alkaline phosphatase; GGT: Gamma glutamyl transpeptidase; MELD: Model for end-stage liver disease; LFT: Liver function test; MRCP: Magnetic resonance cholangiopancreatography; ALT: Alanine aminotransferase; AST: Aspartate aminotransferase; ICU: Intensive care unit; INR: International normalized ratio.

complete and all of them had been discharged between 7 and 21 d. None of them had a history of any underlying liver disease. LFTs were uniformly unremarkable at the time of COVID-19. All these patients were readmitted with fatigue and jaundice four to six weeks following their COVID-19 and a couple of them developed pruritus. Peak enzymes were aspartate aminotransferase 4-8 times upper limit normal (ULN), alanine aminotransferase 3-10 ULN, ALP 4-6 ULN, and GGT 5-15 ULN. Peak bilirubin varied between 15 to 42 mg/dL (N: 0.6-1.2 mg/dL). Interestingly, none of them developed coagulopathy,

ascites, or hepatic encephalopathy. Abdominal imaging in 3 patients was unremarkable. MRCP of one patient demonstrated mild prominence of central intrahepatic, common hepatic, and common bile ducts with minimal beading of the right posterior sectoral and segment 2 ducts. Liver biopsies showed loss of interlobular bile ducts, degenerative features in residual ducts, hepatocanalicular bilirubinostasis, and fibrin thrombi in some vessels.

Of the 4 patients, one died of worsening symptoms and sepsis. The second patient developed progressive jaundice and underwent APOLT (described above)[16]. He remains well on 9 mo follow-up and is due to have a hepatobiliary scintigraphy at 12 mo to reassess native liver regeneration. The third patient remained symptomatic with worsening hyperbilirubinemia and was listed for LT. On evaluation, he was noted to have double-vessel coronary artery disease which required stenting. Following stent placement, he was commenced on aspirin and clopidogrel. Interestingly, there was a significant improvement in LFT within six weeks of initiating antiplatelet therapy. He was discharged home without the need for a LT and his clinical improvement was attributed to anti-platelet drugs. With this experience, the fourth patient was commenced early on antiplatelet therapy and he too had a remarkable improvement in his clinical and biochemical status. Both these patients remain well on 6- and 7-mo' follow-up respectively. This finding underpins the theory of microvascular events in the pathogenesis of PCC.

CONCLUSION

PCC is a recently described entity of severe cholestasis that has been recognized in patients recovering from severe COVID-19 infection. While the exact etiopathogenesis remains unknown, purported theories include SSC-CIP, microthromboses, direct liver injury, and autoimmune etiology among others. Although relatively uncommon at present, it is likely that this disease will be more commonly encountered in the near future. Its natural course remains undefined, but with accumulating evidence several successful management strategies have been proposed. There remains a need for concentrated, multicenter studies to further elucidate this disease which can potentially have high morbidity if not identified and managed appropriately.

FOOTNOTES

Author contributions: Veerankutty FH conceptualized the study; Veerankutty FH, Sengupta K, and Vij M collected the data and contributed to manuscript preparation; Veerankutty FH, Ashwin Rammohan, Jothimani D, Murali A and Rela M drafted and edited the manuscript.

Conflict-of-interest statement: All the authors report no relevant conflicts of interest for this article.

Open-Access: This article is an open-access article that was selected by an in-house editor and fully peer-reviewed by external reviewers. It is distributed in accordance with the Creative Commons Attribution NonCommercial (CC BY-NC 4.0) license, which permits others to distribute, remix, adapt, build upon this work non-commercially, and license their derivative works on different terms, provided the original work is properly cited and the use is non-commercial. See: https://creativecommons.org/Licenses/by-nc/4.0/

Country/Territory of origin: India

ORCID number: Fadl H Veerankutty 0000-0003-3167-0405; Kushan Sengupta 0000-0002-6259-8023; Mukul Vij 0000-0003-0149-0294; Ashwin Rammohan 0000-0001-9528-8892; Dinesh Jothimani 0000-0003-4189-690X; Mohamed Rela 0000-0003-4282-4676.

S-Editor: Wang JJ
L-Editor: A
P-Editor: Wu RR

REFERENCES

1 **Cucinotta D**, Vanelli M. WHO Declares COVID-19 a Pandemic. *Acta Biomed* 2020; **91**: 157-160 [PMID: 32191675 DOI: 10.23750/abm.v91i1.9397]

2 **Yao XH**, Luo T, Shi Y, He ZC, Tang R, Zhang PP, Cai J, Zhou XD, Jiang DP, Fei XC, Huang XQ, Zhao L, Zhang H, Wu HB, Ren Y, Liu ZH, Zhang HR, Chen C, Fu WJ, Li H, Xia XY, Chen R, Wang Y, Liu XD, Yin CL, Yan ZX, Wang J, Jing R, Li TS, Li WQ, Wang CF, Ding YQ, Mao Q, Zhang DY, Zhang SY, Ping YF, Bian XW. A cohort autopsy study defines COVID-19 systemic pathogenesis. *Cell Res* 2021; **31**: 836-846 [PMID: 34135479 DOI: 10.1038/s41422-021-00523-8]

3 **Freund O**, Eviatar T, Bornstein G. Concurrent myopathy and inflammatory cardiac disease in COVID-19 patients: a case

series and literature review. *Rheumatol Int* 2022; **42**: 905-912 [PMID: 35275269 DOI: 10.1007/s00296-022-05106-3]

4 **Jothimani D**, Venugopal R, Abedin MF, Kaliamoorthy I, Rela M. COVID-19 and the liver. *J Hepatol* 2020; **73**: 1231-1240 [PMID: 32553666 DOI: 10.1016/j.jhep.2020.06.006]

5 **Fan Z**, Chen L, Li J, Cheng X, Yang J, Tian C, Zhang Y, Huang S, Liu Z, Cheng J. Clinical Features of COVID-19-Related Liver Functional Abnormality. *Clin Gastroenterol Hepatol* 2020; **18**: 1561-1566 [PMID: 32283325 DOI: 10.1016/j.cgh.2020.04.002]

6 **Xu L**, Liu J, Lu M, Yang D, Zheng X. Liver injury during highly pathogenic human coronavirus infections. *Liver Int* 2020; **40**: 998-1004 [PMID: 32170806 DOI: 10.1111/liv.14435]

7 **Zhang C**, Shi L, Wang FS. Liver injury in COVID-19: management and challenges. *Lancet Gastroenterol Hepatol* 2020; **5**: 428-430 [PMID: 32145190 DOI: 10.1016/S2468-1253(20)30057-1]

8 **Phipps MM**, Barraza LH, LaSota ED, Sobieszczyk ME, Pereira MR, Zheng EX, Fox AN, Zucker J, Verna EC. Acute Liver Injury in COVID-19: Prevalence and Association with Clinical Outcomes in a Large U.S. Cohort. *Hepatology* 2020; **72**: 807-817 [PMID: 32473607 DOI: 10.1002/hep.31404]

9 **Sharma A**, Jaiswal P, Kerakhan Y, Saravanan L, Murtaza Z, Zergham A, Honganur NS, Akbar A, Deol A, Francis B, Patel S, Mehta D, Jaiswal R, Singh J, Patel U, Malik P. Liver disease and outcomes among COVID-19 hospitalized patients - A systematic review and meta-analysis. *Ann Hepatol* 2021; **21**: 100273 [PMID: 33075578 DOI: 10.1016/j.aohep.2020.10.001]

10 **Hundt MA**, Deng Y, Ciarleglio MM, Nathanson MH, Lim JK. Abnormal Liver Tests in COVID-19: A Retrospective Observational Cohort Study of 1,827 Patients in a Major U.S. Hospital Network. *Hepatology* 2020; **72**: 1169-1176 [PMID: 32725890 DOI: 10.1002/hep.31487]

11 **Rela M**, Jothimani D, Vij M, Rajakumar A, Rammohan A. Auto-immune hepatitis following COVID vaccination. *J Autoimmun* 2021; **123**: 102688 [PMID: 34225251 DOI: 10.1016/j.jaut.2021.102688]

12 **McConnell MJ**, Kondo R, Kawaguchi N, Iwakiri Y. Covid-19 and Liver Injury: Role of Inflammatory Endotheliopathy, Platelet Dysfunction, and Thrombosis. *Hepatol Commun* 2022; **6**: 255-269 [PMID: 34658172 DOI: 10.1002/hep4.1843]

13 **Roth NC**, Kim A, Vitkovski T, Xia J, Ramirez G, Bernstein D, Crawford JM. Post-COVID-19 Cholangiopathy: A Novel Entity. *Am J Gastroenterol* 2021; **116**: 1077-1082 [PMID: 33464757 DOI: 10.14309/ajg.0000000000001154]

14 **Schmidt C**. COVID-19 long haulers. *Nat Biotechnol* 2021; **39**: 908-913 [PMID: 34257426 DOI: 10.1038/s41587-021-00984-7]

15 **Mehandru S**, Merad M. Pathological sequelae of long-haul COVID. *Nat Immunol* 2022; **23**: 194-202 [PMID: 35105985 DOI: 10.1038/s41590-021-01104-y]

16 **Rela M**, Rajakannu M, Veerankutty FH, Vij M, Rammohan A. First report of auxiliary liver transplantation for severe cholangiopathy after SARS-CoV-2 respiratory infection. *Am J Transplant* 2022; **22**: 3143-3145 [PMID: 35929565 DOI: 10.1111/ajt.17165]

17 **Kulkarni AV**, Khelgi A, Sekaran A, Reddy R, Sharma M, Tirumalle S, Gora BA, Somireddy A, Reddy J, Menon B, Reddy DN, Rao NP. Post-COVID-19 Cholestasis: A Case Series and Review of Literature. *J Clin Exp Hepatol* 2022; **12**: 1580-1590 [PMID: 35719861 DOI: 10.1016/j.jceh.2022.06.004]

18 **Jothimani D**, Vij M, Sanglodkar U, Patil V, Sachan D, Narasimhan G, Kaliamoorthy I, Rela M. Severe Jaundice in a COVID-19 Patient-Virus or Drug? *J Clin Exp Hepatol* 2021; **11**: 407-408 [PMID: 33654344 DOI: 10.1016/j.jceh.2021.02.006]

19 **Lindholm CR**, Zhang X, Spengler EK, Daniel KE. Severe Cholestatic Hepatitis Secondary to SARS-CoV-2. *ACG Case Rep J* 2022; **9**: e00753 [PMID: 35359752 DOI: 10.14309/crj.0000000000000753]

20 **Faruqui S**, Shanbhogue K, Jacobson IM. Biliary Tract Injury in Patients With COVID-19: A Review of the Current Literature. *Gastroenterol Hepatol (N Y)* 2022; **18**: 380-387 [PMID: 36397771]

21 **Edwards K**, Allison M, Ghuman S. Secondary sclerosing cholangitis in critically ill patients: a rare disease precipitated by severe SARS-CoV-2 infection. *BMJ Case Rep* 2020; **13** [PMID: 33168538 DOI: 10.1136/bcr-2020-237984]

22 **Faruqui S**, Okoli FC, Olsen SK, Feldman DM, Kalia HS, Park JS, Stanca CM, Figueroa Diaz V, Yuan S, Dagher NN, Sarkar SA, Theise ND, Kim S, Shanbhogue K, Jacobson IM. Cholangiopathy After Severe COVID-19: Clinical Features and Prognostic Implications. *Am J Gastroenterol* 2021; **116**: 1414-1425 [PMID: 33993134 DOI: 10.14309/ajg.0000000000001264]

23 **Zou X**, Chen K, Zou J, Han P, Hao J, Han Z. Single-cell RNA-seq data analysis on the receptor ACE2 expression reveals the potential risk of different human organs vulnerable to 2019-nCoV infection. *Front Med* 2020; **14**: 185-192 [PMID: 32170560 DOI: 10.1007/s11684-020-0754-0]

24 **Qi F**, Qian S, Zhang S, Zhang Z. Single cell RNA sequencing of 13 human tissues identify cell types and receptors of human coronaviruses. *Biochem Biophys Res Commun* 2020; **526**: 135-140 [PMID: 32199615 DOI: 10.1016/j.bbrc.2020.03.044]

25 **Zhao B**, Ni C, Gao R, Wang Y, Yang L, Wei J, Lv T, Liang J, Zhang Q, Xu W, Xie Y, Wang X, Yuan Z, Zhang R, Lin X. Recapitulation of SARS-CoV-2 infection and cholangiocyte damage with human liver ductal organoids. *Protein Cell* 2020; **11**: 771-775 [PMID: 32303993 DOI: 10.1007/s13238-020-00718-6]

26 ILTS 2022 Joint International Congress of ILTS, ELITA & LICAGE, May 4-7, 2022. *Transplantation* 2022; **106**: 1-214 [PMID: 36735273 DOI: 10.1097/01.tp.0000872804.80721.17]

27 **Durazo FA**, Nicholas AA, Mahaffey JJ, Sova S, Evans JJ, Trivella JP, Loy V, Kim J, Zimmerman MA, Hong JC. Post-Covid-19 Cholangiopathy-A New Indication for Liver Transplantation: A Case Report. *Transplant Proc* 2021; **53**: 1132-1137 [PMID: 33846012 DOI: 10.1016/j.transproceed.2021.03.007]

28 **Bütikofer S**, Lenggenhager D, Wendel Garcia PD, Maggio EM, Haberecker M, Reiner CS, Brüllmann G, Buehler PK, Gubler C, Müllhaupt B, Jüngst C, Morell B. Secondary sclerosing cholangitis as cause of persistent jaundice in patients with severe COVID-19. *Liver Int* 2021; **41**: 2404-2417 [PMID: 34018314 DOI: 10.1111/liv.14971]

29 **Scheppach W**, Druge G, Wittenberg G, Mueller JG, Gassel AM, Gassel HJ, Richter F. Sclerosing cholangitis and liver cirrhosis after extrabiliary infections: report on three cases. *Crit Care Med* 2001; **29**: 438-441 [PMID: 11246328 DOI: 10.1097/00003246-200102000-00042]

30 **Leonhardt S**, Veltzke-Schlieker W, Adler A, Schott E, Hetzer R, Schaffartzik W, Tryba M, Neuhaus P, Seehofer D. Trigger mechanisms of secondary sclerosing cholangitis in critically ill patients. *Crit Care* 2015; **19**: 131 [PMID: 25886728 DOI: 10.1186/s13054-015-0861-5]

31 **Kirchner GI**, Scherer MN, Obed A, Ruemmele P, Wiest R, Froh M, Loss M, Schlitt HJ, Schölmerich J, Gelbmann CM. Outcome of patients with ischemic-like cholangiopathy with secondary sclerosing cholangitis after liver transplantation. *Scand J Gastroenterol* 2011; **46**: 471-478 [PMID: 21114429 DOI: 10.3109/00365521.2010.537683]

32 **Leonhardt S**, Veltzke-Schlieker W, Adler A, Schott E, Eurich D, Faber W, Neuhaus P, Seehofer D. Secondary Sclerosing Cholangitis in Critically Ill Patients: Clinical Presentation, Cholangiographic Features, Natural History, and Outcome: A Series of 16 Cases. *Medicine (Baltimore)* 2015; **94**: e2188 [PMID: 26656347 DOI: 10.1097/MD.0000000000002188]

33 **Voigtländer T**, Negm AA, Schneider AS, Strassburg CP, Manns MP, Wedemeyer J, Lankisch TO. Secondary sclerosing cholangitis in critically ill patients: model of end-stage liver disease score and renal function predict outcome. *Endoscopy* 2012; **44**: 1055-1058 [PMID: 23108773 DOI: 10.1055/s-0032-1325733]

34 **Lin T**, Qu K, Xu X, Tian M, Gao J, Zhang C, Di Y, Zhang Y, Liu C. Sclerosing cholangitis in critically ill patients: an important and easily ignored problem based on a German experience. *Front Med* 2014; **8**: 118-126 [PMID: 24415157 DOI: 10.1007/s11684-014-0306-6]

35 **Ghafoor S**, Germann M, Jüngst C, Müllhaupt B, Reiner CS, Stocker D. Imaging features of COVID-19-associated secondary sclerosing cholangitis on magnetic resonance cholangiopancreatography: a retrospective analysis. *Insights Imaging* 2022; **13**: 128 [PMID: 35939241 DOI: 10.1186/s13244-022-01266-9]

36 **Saleem N**, Li BH, Vuppalanchi R, Gawrieh S, Gromski MA. Critical Illness Cholangiopathy in COVID-19 Long-haulers. *Tech Innov Gastrointest Endosc* 2022; **24**: 351-353 [PMID: 35615695 DOI: 10.1016/j.tige.2022.05.006]

37 **Hunyady P**, Streller L, Rüther DF, Groba SR, Bettinger D, Fitting D, Hamesch K, Marquardt JU, Mücke VT, Finkelmeier F, Sekandarzad A, Wengenmayer T, Bounidane A, Weiss F, Peiffer KH, Schlevogt B, Zeuzem S, Waidmann O, Hollenbach M, Kirstein MM, Kluwe J, Kütting F, Mücke MM. Secondary Sclerosing Cholangitis Following Coronavirus Disease 2019 (COVID-19): A Multicenter Retrospective Study. *Clin Infect Dis* 2023; **76**: e179-e187 [PMID: 35809032 DOI: 10.1093/cid/ciac565]

38 **Lee A**, Wein AN, Doyle MBM, Chapman WC. Liver transplantation for post-COVID-19 sclerosing cholangitis. *BMJ Case Rep* 2021; **14** [PMID: 34446515 DOI: 10.1136/bcr-2021-244168]

39 **Cesar Machado MC**, Filho RK, El Bacha IAH, de Oliveira IS, Ribeiro CMF, de Souza HP, Parise ER. Post-COVID-19 Secondary Sclerosing Cholangitis: A Rare but Severe Condition with no Treatment Besides Liver Transplantation. *Am J Case Rep* 2022; **23**: e936250 [PMID: 35978523 DOI: 10.12659/AJCR.936250]

40 **Franzini TAP**, Guedes MMF, Rocha HLOG, Fleury CA, Bestetti AM, Moura EGH. CHOLANGIOSCOPY IN A POST-COVID-19 CHOLANGIOPATHY PATIENT. *Arq Gastroenterol* 2022; **59**: 321-323 [PMID: 35830050 DOI: 10.1590/S0004-2803.202202000-58]

41 **Freund O**, Tau L, Weiss TE, Zornitzki L, Frydman S, Jacob G, Bornstein G. Associations of vaccine status with characteristics and outcomes of hospitalized severe COVID-19 patients in the booster era. *PLoS One* 2022; **17**: e0268050 [PMID: 35536849 DOI: 10.1371/journal.pone.0268050]

42 **Tafreshi S**, Whiteside I, Levine I, D'Agostino C. A case of secondary sclerosing cholangitis due to COVID-19. *Clin Imaging* 2021; **80**: 239-242 [PMID: 34364072 DOI: 10.1016/j.clinimag.2021.07.017]

43 **Klindt C**, Jensen BE, Brandenburger T, Feldt T, Killer A, Schimmöller L, Antoch G, Senff T, Hauka S, Timm J, Bahners BH, Seidl M, Esposito I, Luedde T, Bode JG, Keitel V. Secondary sclerosing cholangitis as a complication of severe COVID-19: A case report and review of the literature. *Clin Case Rep* 2021; **9**: e04068 [PMID: 34084492 DOI: 10.1002/ccr3.4068]

44 **Rojas M**, Rodríguez Y, Zapata E, Hernández JC, Anaya JM. Cholangiopathy as part of post-COVID syndrome. *J Transl Autoimmun* 2021; **4**: 100116 [PMID: 34485887 DOI: 10.1016/j.jtauto.2021.100116]

45 **Mayorquín-Aguilar JM**, Lara-Reyes A, Revuelta-Rodríguez LA, Flores-García NC, Ruiz-Margáin A, Jiménez-Ferreira MA, Macías-Rodríguez RU. Secondary sclerosing cholangitis after critical COVID-19: Three case reports. *World J Hepatol* 2022; **14**: 1678-1686 [PMID: 36157873 DOI: 10.4254/wjh.v14.i8.1678]

Published by **Baishideng Publishing Group Inc**
7041 Koll Center Parkway, Suite 160, Pleasanton, CA 94566, USA
Telephone: +1-925-3991568
E-mail: bpgoffice@wjgnet.com
Help Desk: https://www.f6publishing.com/helpdesk
https://www.wjgnet.com

© 2023 Baishideng Publishing Group Inc. All rights reserved.