

# Comparison between chemoembolization combined with radiotherapy and chemoembolization alone for large hepatocellular carcinoma

Wei-Jian Guo, Er-Xin Yu, Lu-Ming Liu, Jie Li, Zhen Chen, Jun-Hua Lin, Zhi-Qiang Meng, Yi Feng

**Wei-Jian Guo, Jie Li, Yi Feng**, Department of Oncology, Xinhua Hospital of Shanghai Second Medical University, 1665 Kongjiang Road, Shanghai 200092, China

**Er-Xin Yu, Lu-Ming Liu, Zhen Chen, Jun-Hua Lin, Zhi-Qiang Meng**, Cancer Hospital of Fudan University, Shanghai 200032, China  
**Correspondence to:** Wei-Jian Guo, MD, Department of Oncology, Xinhua Hospital of Shanghai Second Medical University, 1665 Kongjiang Road, Shanghai 200092, China. guoweijian1@sohu.com  
**Received:** 2003-04-02 **Accepted:** 2003-05-19

## Abstract

**AIM:** To investigate the efficacy of transcatheter arterial chemoembolization (TACE) combined with radiotherapy for unresectable large hepatocellular carcinoma (HCC).

**METHODS:** From June 1994 to June 1999, a total of 76 patients with large unresectable HCC were treated with TACE followed by external-beam irradiation. 89 patients with large HCC, who underwent TACE alone during the same period, served as the control group. Clinical features, therapeutic modalities, acute effects and survival rates were analyzed and compared between TACE plus irradiation group and TACE alone group. A multivariate analysis of nine clinical variables and one treatment variable (irradiation) was performed by the Cox proportional hazards model.

**RESULTS:** The clinical features and therapeutic modalities except irradiation between the two groups were comparable ( $P>0.05$ ). The objective response rate (RR) in TACE plus irradiation group was higher than that in TACE alone group (47.4 % vs 28.1 %,  $P<0.05$ ). The overall survival rates in TACE plus irradiation group (64.0 %, 28.6 %, and 19.3 % at 1, 3, 5 years, respectively) were significantly higher than those in TACE alone group (39.9 %, 9.5 %, and 7.2 %, respectively,  $P=0.0001$ ). Cox proportional hazards model analysis showed that tumor extension and Child grade were significant and were independent negative predictors of survival, while irradiation was an independent positive predictor of survival.

**CONCLUSION:** TACE combined with radiotherapy is more effective than TACE alone, and is a promising treatment for unresectable large HCC.

Guo WJ, Yu EX, Liu LM, Li J, Chen Z, Lin JH, Meng ZQ, Feng Y. Comparison between chemoembolization combined with radiotherapy and chemoembolization alone for large hepatocellular carcinoma. *World J Gastroenterol* 2003; 9(8): 1697-1701  
<http://www.wjgnet.com/1007-9327/9/1697.asp>

## INTRODUCTION

Hepatocellular carcinoma (HCC) is a common cancer in Asia. In China, there has been an increasing trend in the incidence

and mortality of HCC during the past two decades. The age-adjusted rate of death per 100 000/year was 20.37 in 1990's. Patients with HCC usually have a poor prognosis. Surgery is the only potential cure, and there has been a great progress in surgery over the past decades<sup>[1]</sup>. However, the overall 5-year survival rates are still not above 5 % as the number of resected cases is limited due to advanced lesions or associated liver disease<sup>[2-4]</sup>. Most of the patients with HCC are subjected to various forms of non-surgical therapy. Transcatheter arterial chemoembolization (TACE) has become one of the most popular forms of nonsurgical treatment in Asia. TACE application to HCC has demonstrated good results in reducing the size of tumor and improving survival<sup>[5-10]</sup>. However, within or around the capsule, which is supplied by both arterial and portal blood, tumor cells remain viable, which are often responsible for later recurrence<sup>[11]</sup>. Even in several prospective randomized trials, TAE failed to improve significantly the survival of patients with HCC<sup>[12,13]</sup>. Further treatment was needed to eradicate the residual tumor cells. We have found in a clinical trial that TACE combined with irradiation may be a good method for large unresectable HCC<sup>[14]</sup>. In the present study, we compared the effects of TACE plus irradiation with that of TACE alone for the treatment of large unresectable HCC.

## MATERIALS AND METHODS

### Patients

During the past decade, patients with unresectable HCC underwent TACE therapy as the first line treatment at the Cancer Hospital of Fudan University, but parts of patients underwent TACE combined with radiotherapy or were given percutaneous ethanol injection (PEI) in clinical trials by some doctors. Included in the present study were 76 patients with unresectable large HCC who underwent TACE combined with radiotherapy between June 1994 and June 1999. The criteria for entry into this study were as follows: (1) The tumor / liver volume ratio was not above 0.7:1. (2) The lesion was detectable by ultrasound (US) and computed tomography (CT). (3) The level of serum transaminase was under 80 IU/L. (4) There was no evidence of extrahepatic metastasis, or ascites, or severe cirrhosis (class C according to Child's classification). (5) Karnofsky performance score  $\geq 70$ . During the same period, a total of 127 patients underwent TACE alone as a routine therapy. 89 patients who complied with the above criteria served as the control group. In 61 (80.0 %) patients in TACE plus irradiation group and 73 patients (82.0 %) in control group, the diagnosis of HCC was confirmed by cytological examination. Diagnosis in the remaining patients was made on the basis of characteristic findings by ultrasound, CT and angiography, and high serum  $\alpha$ -fetoprotein (AFP) levels. None of the patients underwent surgical resection owing to advanced tumor stage and/or location of the lesion, or because of refusal of surgery. Informed consent was obtained from all patients and their relatives.

### Treatments

TACE procedure was performed as follows. The tip of a catheter

was introduced into the appropriate hepatic artery, and 5-fluorouracil (1.0 g, 5-Fu, Xudong Haipu Pharmaceutical Inc., Shanghai, China) and cisplatin (40-60 mg, CDDP, Qilu Pharmaceutical Factory, Jinan, China) or doxorubicin hydrochloride (30-50 mg, Adriamycin, Main Luck Pharmaceutical Inc., Shenzhen, China) were injected, followed by a mixture of iodized oil (5-20 ml, Lipiodol, Huaihai Pharmaceutical Factory, Shanghai, China) and mitomycin C (10-20 mg, MMC, Kyowa Hakko Kogyo Co., LTD, Tokyo, Japan) was injected slowly under fluoroscopic control. In some patients embolization with a gelatin sponge (1×1×10 mm, Gelfoam, the 3rd Pharmaceutical Factory of Nanjing, Nanjing, China) was performed at the same time. TACE procedures were performed at 4 to 10 week intervals, and patients received 1 to 4 times of TACE.

In the TACE plus irradiation group, radiotherapy was started 4 to 8 weeks after TACE. Twenty-six patients with a solitary tumor within a 9 cm diameter received limited-field radiotherapy. Radiation was delivered through a pair of opposed anterior-posterior fields using a 6 MV or 18 MV linear accelerator. Field sizes ranged from 64 cm<sup>2</sup> to 144 cm<sup>2</sup>. The fractions were 1.8 to 2.0 Gy daily, given five times a week. The total dose ranged from 30 Gy to 50 Gy, depending on the proportion of normal liver excluded from the high-dose volume and the Child's grade. For 50 patients with a solitary tumor of more than 9 cm diameter or with multinodular or diffuse lesions, whole or partial liver irradiation with a moving strip technique<sup>[14]</sup> was performed. The total midline dose ranged from 19.5 to 30 Gy. Ten patients whose tumor reduced to 9 cm or smaller after whole or partial liver irradiation had a boost to residual disease to a total dose of 36 to 42 Gy.

#### Effects evaluation

The effects on the tumor were assessed by US and CT, together with AFP levels in cases with increased baseline values. Changes in tumor size were assessed in terms of percent regressing on CT and US, using World Health Organization criteria. Cumulative survival was determined by the Kaplan-Meier method from the first day of treatment.

#### Statistical analysis

The difference of clinical features, therapeutic modalities, response rate (RR) and AFP decreasing rate between the 2 groups were analyzed by chi-square test. The difference of survival was assessed by log-rank test. *P* value <0.05 was considered significant.

To assess the relatively prognostic importance of factors in predicting survival, a multivariate analysis of nine clinical variables, including sex, age, AFP level, number of lesions, tumor size, tumor extension, portal thrombosis, Child grade, and Okuda stage, and one treatment variable (irradiation), was performed by Cox proportional hazards model.

## RESULTS

### Clinical features and therapeutic modalities

The nine clinical features before treatment in the two groups are shown in Table 1. Only the rate of two lobes invasion in TACE plus irradiation group was slightly, but not significantly higher than that in control group. The other features in two groups were similar (*P*>0.05). There was no significant difference of TACE times and spongostan use between two groups (Table 1). Thus, the clinical features and therapeutic modalities, except irradiation, were comparable between these two groups.

### Effects on tumor

In the TACE plus irradiation group, 5 patients (6.6 %) showed

a complete response (CR), and 31 patients (40.8 %) showed a partial response (PR). Tumor size was unchanged in 30 cases (39.5 %), and increased in 10 cases (13.2 %). The objective response rate (RR) was 47.4 %. 48 patients had increased AFP values (>20 ng/ml) before treatment. In 23 of these cases (47.9 %), AFP level reduced by more than 50 %. In the control group, CR was observed in 2 patients (2.3 %) and PR was observed in 23 patients (25.8 %). Tumor size was unchanged in 44 cases (49.4 %) and increased in 20 cases (22.5 %). The RR was 28.1 %. The rate of AFP level, reducing by more than 50 %, was 29.0 % (20/69). The RR and AFP reduction rate in the TACE plus irradiation group increased significantly compared with that in the control group (*P*<0.05).

**Table 1** Clinical features and therapeutic modalities in two groups

		TACE group cases (%)	TACE plus irradiation group cases (%)	<i>P</i> value
Sex	Male	75 (84.3)	68 (89.5)	0.327
	Female	14 (15.7)	8 (10.5)	
Age	<60 years	66 (74.2)	57 (75.0)	0.901
	≥60 years	23 (25.8)	19 (25.0)	
AFP	<400 ng/ml	45 (50.6)	42 (55.3)	0.547
	≥400 ng/ml	44 (49.4)	34 (44.7)	
No. of lesions	Solitary	59 (66.3)	51 (67.1)	0.912
	Multiple	30 (33.7)	25 (32.9)	
Tumor extension <sup>a</sup>	1 lobe	72 (81.9)	52 (68.4)	0.064
	2 lobe	17 (19.1)	24 (31.6)	
Tumor size	5-10 cm	51 (57.3)	47 (61.8)	0.554
	>10 cm	38 (42.7)	29 (38.2)	
Portal thrombosis	Absent	67 (75.3)	62 (81.6)	0.329
	Present	22 (24.7)	14 (18.4)	
Child grade	A	74 (83.2)	63 (82.9)	0.996
	B	15 (16.8)	13 (17.1)	
Okuda stage	I	24 (27.0)	29 (38.2)	0.155
	II	65 (73.0)	46 (60.5)	
	III		1 (1.3)	
TACE times	1	27 (30.3)	27 (35.5)	0.253
	2	42 (47.2)	28 (36.8)	
	3	15 (16.9)	11 (14.5)	
	4	5 (5.6)	10 (13.2)	
Spongostan use	No	48 (53.9)	44 (57.9)	0.610
	Yes	41 (46.1)	32 (42.1)	

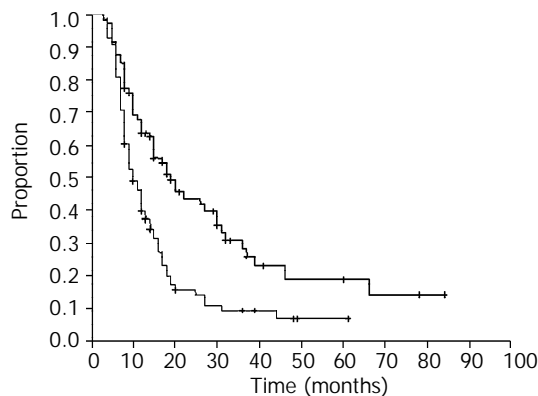
<sup>a</sup>Hepatic lobes were classified as two lobes: right lobe and left lobe.

### Survival and Cox model analysis

In the TACE plus irradiation group, the median follow-up time was 26 months (ranged from 10 to 84 months). Fifty-two patients died, 21 patients were still alive, and the remaining 3 patients were lost to follow-up. In the control group, the median follow-up time was 24 months (ranged from 10 to 70 months). Seventy-five patients died, 9 patients were still alive, and 5 patients were lost to follow-up. The data were obtained and analyzed in January 2001.

The survival curve for patients from the two groups is shown in Figure 1. The overall survival rates at 1, 3, and 5 years from the TACE plus irradiation group were 64.0 %, 28.6 %, and 19.3 %, respectively (median survival, 19 months), and 39.9 %, 9.5 %, and 7.2 %, respectively from the control group (median survival, 10 months). The survival rates in TACE plus irradiation group were significantly higher than those in control group (*P*=0.0001).

Multivariate analysis using the Cox proportional hazards model showed that both tumor extension and Child grade were significant and independent negative predictors of survival, while irradiation was an independent positive predictor of survival (Table 2).



**Figure 1** Cumulative survival curves for patients in two groups. The patients in TACE plus irradiation group survived significantly longer than did those in TACE alone group ( $P=0.0001$ ).

**Table 2** Multivariate analysis of major prognostic factors by the Cox proportional hazards model

Variabes	Regression coefficient	Hazard ratio	P value
Tumor extension	0.8708	2.3888	0.0016
Child grade	0.5685	1.7655	0.0200
Irradiation or not	-0.7256	0.4840	0.0002

## DISCUSSION

TACE is a combination of target chemotherapy and arterial embolization that has both selective ischemic and chemotherapeutic effects on HCC. TACE is an excellent debulking procedure. Surgically resected specimens showed that TACE effectively destroyed malignant cells, not only in the main tumors, but also in daughter tumors, extracapsular invasion, and intraportal neoplastic thrombi. TACE was proved to be effective in treating HCC, and has been widely used for patients with unresectable HCC in Asia<sup>[5-10]</sup>. It was even found that the effects of TACE was comparable to that of resection in some subpopulations of patients with operable HCC<sup>[15]</sup>. However, TACE is not a curative method. Tumor cells remain viable, especially in and around the capsule, and tumors may recur by the blood supply from the collateral circulation or portal vein<sup>[11]</sup>. The long-term efficacy of TACE was disappointing. 1, 3, and 5 year survival rates were around 50 %, 20 %, and 6 %, respectively<sup>[5-10]</sup>. In the present study, the RR and 5 year survival rate in the TACE control group were 28.1 % and 7.2 %, respectively, which were approximate to the results in the literature. Nevertheless, in some prospective randomized trials, TACE therapy failed to improve the survival of patients significantly<sup>[12,13]</sup>. Segmental TACE has been shown to yield 5 year survival rate (30 %) for patients with lesions less than 5 cm, but it is suitable only for small tumors. Thus, multimodality treatments are necessary, especially for large HCC.

Radiotherapy has not played a significant role in treating HCC because of the poor tolerance of the liver. The benefit of radiotherapy is still uncertain. Whole liver irradiation at or above 35Gy in a 3-4 week period is known to cause a high incidence of radiation hepatitis, yet this dose level is not enough to control the tumor. In contrast to whole liver irradiation, small portions of the liver can be irradiated up to 50-60 Gy in 5-6 weeks without significant long-term morbidity.

Limited-field high dose irradiation (40-60Gy) and three-dimension conformal radiotherapy have been found to be effective for relatively small unresectable HCC, even with portal vein thrombosis<sup>[16-20]</sup>.

The combination of TACE with radiotherapy may remedy the limitation of each alone and have synergistic effects. Tumor shrinkage after TACE allows the use of smaller irradiation fields, which permits higher tumor doses and improves the normal liver tolerance. Combination therapy also serves the purpose of eliminating residual cancer cells after TACE. Furthermore, the anticancer drug retained in the tumor may have a radiosensitizing effect<sup>[21]</sup>. The anticancer drug, when it is mixed with lipiodol, has been reported to maintain relatively high concentrations in tumors as long as 27 days and decrease to a trace level after 47 days<sup>[22]</sup>. In 1990, Yoshikawa *et al.*<sup>[23]</sup> reported that the combination therapy was more effective than TACE or radiotherapy alone in a preliminary study encompassing a small number of cases. From then on, this combination regimen was carried out to treat HCC by more investigators, and was found to be an effective method for HCC<sup>[24-29]</sup>. Seong *et al.*<sup>[26]</sup> reported that 30 patients with HCC who were treated by TACE combined with radiotherapy had 3 year survival rate of 22.2 %, and a median survival of 17 months. The results of our study also suggested that TACE followed by irradiation was a promising approach for large HCC. The RR and 5 year survival rate were 47.4 % and 19.3 %, respectively, in 76 patients with very large tumors ( $\geq 5$  cm in all cases,  $>10$  cm in 38.2 % of the cases, while two hepatic lobes were involved in 31.6 % of the cases). In addition, the results of the Cox proportional hazards model analysis showed that irradiation was an independent positive predictor of survival, and further confirmed that TACE combined with radiotherapy was more effective than TACE alone.

The results of combination therapy in the present study appeared to be comparable to those in other reports of multimodality therapy. Second-look resection after TACE yielded the highest 5 year survival rate (56 %) <sup>[30,31]</sup>, but only a few patients had the opportunity of resection following TACE. PEI after TACE yielded higher survival rates at 1, 2, and 3 years than TACE alone did<sup>[32-37]</sup>, but the survival rates after 4 years dropped, and it was suitable only for tumors  $<8$  cm. Tanaka *et al.*<sup>[37]</sup> reported that 83 patients with HCC who were treated by TACE-PEI had 5 and 7 year survival rates of 35 % and 14 %, respectively, but most of the patients (71.1 %) in their study had tumors of less than 5 cm in diameter. The results of our study showed that TACE combined with radiotherapy was effective even for very large tumors.

The optimal radiation dose in the combined therapy is unclear. It is well known that the inhibiting effect of radiotherapy on most tumors depends on the irradiation dose. It has been found that the radiation dose is a significant factor for predicting the objective response and the survival in treating HCC<sup>[14,19]</sup>, but liver tolerance should be considered at the same time. Recently, conformal radiotherapy has been introduced for the treatment of intrahepatic malignancies and dose-volume histogram analysis was used to quantify the tolerance of the liver by some investigators<sup>[20,38-40]</sup>. They suggested the irradiation dose level by normal liver volume to be radiated depended on the percentage of normal liver receiving more than 50 % of the prescribed isocenter dose, 66Gy for less than 33 %, 48Gy for 33-66 %, and 24Gy (whole liver) for more than 66 % in 1.5Gy twice a day fractionation with concurrent bromodeoxyuridine<sup>[38,39]</sup>. Introduction of conformal radiotherapy and dose-volume histogram analysis into the study of the combined therapy will help to give an optimal and tangible dose.

The Cox proportional hazards model showed that tumor extension was a significant and independent negative predictor

of survival. The prognosis of patients with invasion in two hepatic lobes was worse than that of patients with one hepatic lobe invasion. This may be because the tumor was barely controlled by combined therapy or TACE alone treatment plus the chance of metastases rose when there was invasion in two lobes. The degree of cirrhosis (classified by Child grade) is also an independent negative predictor of survival. This is in agreement with previous studies<sup>[35, 36]</sup>.

In summary, our results demonstrate that TACE combined with radiotherapy is a promising treatment for large HCC. Prospectively randomized, controlled multi-center clinical trials are needed to confirm the advantageous effects of combined therapy over TACE or radiotherapy alone. In addition, further clarification about an optimal radiation dose and the optimal interval between TACE and radiotherapy are also needed.

## ACKNOWLEDGEMENTS

We would like to thank Mrs. Margaret-Hiatt Rosen, Director of Admission, the Mead School, Stanford, US, for her correction of the English translation of the paper.

## REFERENCES

- Zhou XD**, Tang ZY, Yang BH, Lin ZY, Ma ZC, Ye SL, Wu ZQ, Fan J, Qin LX, Zheng BH. Experience of 1000 patients who underwent hepatectomy for small hepatocellular carcinoma. *Cancer* 2001; **91**: 1479-1486
- Faivre J**, Forman D, Esteve J, Obradovic M, Sant M. Survival of patients with primary liver cancer, pancreatic cancer and biliary tract cancer in Europe. *Eur J Cancer* 1998; **34**: 2184-2190
- El-Serag HB**, Mason AC, Key C. Trends in survival of patients with hepatocellular carcinoma between 1977 and 1996 in the United States. *Hepatology* 2001; **33**: 62-65
- El-Serag HB**. Hepatocellular carcinoma: an epidemiologic view. *J Clin Gastroenterol* 2002; **35**(5 Suppl 2): S72-78
- Poon RT**, Ngan H, Lo CM, Liu CL, Fan ST, Wong J. Transarterial chemoembolization for inoperable hepatocellular carcinoma and postresection intrahepatic recurrence. *J Surg Oncol* 2000; **73**: 109-114
- Lo CM**, Ngan H, Tso WK, Liu CL, Lam CM, Poon RT, Fan ST, Wong J. Randomized controlled trial of transarterial lipiodol chemoembolization for unresectable hepatocellular carcinoma. *Hepatology* 2002; **35**: 1164-1171
- Savastano S**, Miotto D, Casarrubea G, Teso S, Chiesura-Corona M, Feltrin GP. Transcatheter arterial chemoembolization for hepatocellular carcinoma in patients with Child's grade A or B cirrhosis: a multivariate analysis of prognostic factors. *J Clin Gastroenterol* 1999; **28**: 334-340
- Sithinamsuwan P**, Piratvisuth T, Tanomkiat W, Apakupakul N, Tongyoo S. Review of 336 patients with hepatocellular carcinoma at Songklanagarind Hospital. *World J Gastroenterol* 2000; **6**: 339-343
- Levy I**, Verstandig A, Sasson T, Wolf D, Krichon I, Libson E, Levensart P, Papo O, Yurim O, Id A, Shouval D. Transarterial oil chemoembolization for hepatocellular carcinoma, in 100 cases. *Harefuah* 2000; **138**: 89-93
- Ueno K**, Miyazono N, Inoue H, Nishida H, Kanetsuki I, Nakajo M. Transcatheter arterial chemoembolization therapy using iodized oil for patients with unresectable hepatocellular carcinoma: evaluation of three kinds of regimens and analysis of prognostic factors. *Cancer* 2000; **88**: 1574-1581
- Tang ZY**, Yu YQ, Zhou XD, Yang BH, Lin ZY, Lu JZ, Ma ZC, Ye SL, Liu KD. Three decades' experience in surgery of hepatocellular carcinoma. *Gan To Kagaku Ryoho* 1997; **24**(Suppl): 126-133
- Pelletier G**, Ducreux M, Gay F, Luboinski M, Hagege H, Dao T, Van Steenberghe W, Buffet C, Rougier P, Adler M, Pignon JP, Roche A. Treatment of unresectable hepatocellular carcinoma with lipiodol chemoembolization: a multicenter randomized trial. *Groupe CHC. J Hepatol* 1998; **29**: 129-134
- Bruix J**, Llovet JM, Castells A, Montana X, Bru C, Ayuso MC, Vilana R, Rodes J. Transarterial embolization versus symptomatic treatment in patients with advanced hepatocellular carcinoma: results of a randomized, controlled trial in a single institution. *Hepatology* 1998; **27**: 1578-1583
- Guo WJ**, Yu EX. Evaluation of combined therapy with chemoembolization and irradiation for large hepatocellular carcinoma. *Br J Radiol* 2000; **73**: 1901-1907
- Lee HS**, Kim KM, Yoon JH, Lee TR, Suh KS, Lee KU, Chung JW, Park JH, Kim CY. Therapeutic efficacy of transcatheter arterial chemoembolization as compared with hepatic resection in hepatocellular carcinoma patients with compensated liver function in a hepatitis B virus-endemic area: a prospective cohort study. *J Clin Oncol* 2002; **20**: 4459-4465
- Seong J**, Park HC, Han KH, Chon CY. Clinical results and prognostic factors in radiotherapy for unresectable hepatocellular carcinoma: a retrospective study of 158 patients. *Int J Radiat Oncol Biol Phys* 2003; **55**: 329-336
- Tokuuye K**, Sumi M, Kagami Y, Murayama S, Kawashima M, Ikeda H, Ueno H, Okusaka T, Okada S. Radiotherapy for hepatocellular carcinoma. *Strahlenther Onkol* 2000; **176**: 406-410
- Seong J**, Park HC, Han KH, Lee DY, Lee JT, Chon CY, Moon YM, Suh CO. Local radiotherapy for unresectable hepatocellular carcinoma patients who failed with transcatheter arterial chemoembolization. *Int J Radiat Oncol Biol Phys* 2000; **47**: 1331-1335
- Park HC**, Seong J, Han KH, Chon CY, Moon YM, Suh CO. Dose-response relationship in local radiotherapy for hepatocellular carcinoma. *Int J Radiat Oncol Biol Phys* 2002; **54**: 150-155
- Cheng SH**, Lin YM, Chuang VP, Yang PS, Cheng JC, Huang AT, Sung JL. A pilot study of three-dimensional conformal radiotherapy in unresectable hepatocellular carcinoma. *J Gastroenterol Hepatol* 1999; **14**: 1025-1033
- Seong J**, Kim SH, Suh CO. Enhancement of tumor radioresponse by combined chemotherapy in murine hepatocarcinoma. *J Gastroenterol Hepatol* 2001; **16**: 883-889
- Raoul JL**, Heresbach D, Bretagne JF, Ferrer DB, Duvauferrier R, Bourguet P, Messner M, Gosselin M. Chemoembolization of hepatocellular carcinoma. A study of the biodistribution and pharmacokinetics of doxorubicin. *Cancer* 1992; **70**: 585-590
- Yoshikawa M**, Ebara M, Ohto M, Miyoshi T. A combination treatment of transcatheter arterial embolization (TAE) and irradiation for hepatocellular carcinoma (HCC): evaluation for therapeutic efficacy in comparison with TAE or irradiation alone. *Nippon Shokakubyo Gakkai Zasshi* 1990; **87**: 225-234
- Yamada K**, Soejima T, Sugimoto K, Mayahara H, Izaki K, Sasaki R, Maruta T, Matsumoto S, Hirota S, Sugimura K. Pilot study of local radiotherapy for portal vein tumor thrombus in patients with unresectable hepatocellular carcinoma. *Jpn J Clin Oncol* 2001; **31**: 147-152
- Guo WJ**, Song MZ, Yu EX. Transcatheter arterial chemoembolization combined with external radiation for primary liver cancer. *Zhonghua Zhongliu Zazhi* 1999; **21**: 25-28
- Seong J**, Keum KC, Han KH, Lee DY, Lee JT, Chon CY, Moon YM, Suh CO, Kim GE. Combined transcatheter arterial chemoembolization and local radiotherapy of unresectable hepatocellular carcinoma. *Int J Radiat Oncol Biol Phys* 1999; **43**: 393-397
- Chia-Hsien Cheng J**, Chuang VP, Cheng SH, Lin YM, Cheng TI, Yang PS, Jian JJ, You DL, Horng CF, Huang AT. Unresectable hepatocellular carcinoma treated with radiotherapy and/or chemoembolization. *Int J Cancer* 2001; **96**: 243-252
- Guo WJ**, Yu EX, Yi C, Wu WY, Lin JH. Prognostic factors influencing survival in patients with large hepatocellular carcinoma receiving combined transcatheter arterial chemoembolization and radiotherapy. *Zhonghua Ganzhangbing Zazhi* 2002; **10**: 167-169
- Zeng ZC**, Tang ZY, Wu ZQ, Ma ZC, Fan J, Qin LX, Zhou J, Wang JH, Wang BL, Zhong CS. Phase I clinical trial of oral furtulon and combined hepatic arterial chemoembolization and radiotherapy in unresectable primary liver cancers, including clinicopathologic study. *Am J Clin Oncol* 2000; **23**: 449-454
- Fan J**, Tang ZY, Yu YQ, Wu ZQ, Ma ZC, Zhou XD, Zhou J, Qiu SJ, Lu JZ. Improved survival with resection after transcatheter arterial chemoembolization (TACE) for unresectable hepatocellular carcinoma. *Dig Surg* 1998; **15**: 674-678
- Tang ZY**. Hepatocellular carcinoma. *J Gastroenterol Hepatol*

- 2000; **15**(Suppl): G1-7
- 32 **Kamada K**, Kitamoto M, Aikata H, Kawakami Y, Kono H, Imamura M, Nakanishi T, Chayama K. Combination of transcatheter arterial chemoembolization using cisplatin-lipiodol suspension and percutaneous ethanol injection for treatment of advanced small hepatocellular carcinoma. *Am J Surg* 2002; **184**: 284-290
- 33 **Li C**, Shi Z, Hao Y. Combined percutaneous ethanol injection through liver puncture and transcatheter hepatic arterial chemoembolization for hepatocellular carcinoma. *Zhonghua Zhongliu Zazhi* 2001; **23**: 490-492
- 34 **Koda M**, Murawaki Y, Mitsuda A, Oyama K, Okamoto K, Idobe Y, Suou T, Kawasaki H. Combination therapy with transcatheter arterial chemoembolization and percutaneous ethanol injection compared with percutaneous ethanol injection alone for patients with small hepatocellular carcinoma: a randomized control study. *Cancer* 2001; **92**: 1516-1124
- 35 **Allgaier HP**, Deibert P, Olschewski M, Spamer C, Blum U, Gerok W, Blum HE. Survival benefit of patients with inoperable hepatocellular carcinoma treated by a combination of transarterial chemoembolization and percutaneous ethanol injection-a single-center analysis including 132 patients. *Int J Cancer* 1998; **79**: 601-605
- 36 **Lencioni R**, Paolicchi A, Moretti M, Pinto F, Armillotta N, Di Giulio M, Cicorelli A, Donati F, Cioni D, Bartolozzi C. Combined transcatheter arterial chemoembolization and percutaneous ethanol injection for the treatment of large hepatocellular carcinoma: local therapeutic effect and long-term survival rate. *Eur Radiol* 1998; **8**: 439-444
- 37 **Tanaka K**, Nakamura S, Numata K, Kondo M, Morita K, Kitamura T, Saito S, Kiba T, Okazaki H, Sekihara H. The long term efficacy of combined transcatheter arterial embolization and percutaneous ethanol injection in the treatment of patients with large hepatocellular carcinoma and cirrhosis. *Cancer* 1998; **82**: 78-85
- 38 **Dawson LA**, Normolle D, Balter JM, McGinn CJ, Lawrence TS, Ten Haken RK. Analysis of radiation-induced liver disease using the Lyman NTCP model. *Int J Radiat Oncol Biol Phys* 2002; **53**: 810-821
- 39 **Robertson JM**, McGinn CJ, Walker S, Marx MV, Kessler ML, Ensminger WD, Lawrence TS. A phase I trial of hepatic arterial bromodeoxyuridine and conformal radiation therapy for patients with primary hepatobiliary cancers or colorectal liver metastases. *Int J Radiat Oncol Biol Phys* 1997; **39**: 1087-1092
- 40 **Cheng JC**, Wu JK, Huang CM, Liu HS, Huang DY, Cheng SH, Tsai SY, Jian JJ, Lin YM, Cheng TI, Horng CF, Huang AT. Radiation-induced liver disease after three-dimensional conformal radiotherapy for patients with hepatocellular carcinoma: dosimetric analysis and implication. *Int J Radiat Oncol Biol Phys* 2002; **54**: 156-162

Edited by Zhang JZ