


World Journal of *Gastroenterology*

World J Gastroenterol 2020 January 7; 26(1): 1-108



**OPINION REVIEW**

- 1 Diagnosing coeliac disease: Out with the old and in with the new?
Charlesworth RP

MINIREVIEWS

- 11 Hepatic hemangioma: What internists need to know
Leon M, Chavez L, Surani S

ORIGINAL ARTICLE**Basic Study**

- 21 Feedback regulation between phosphatidylinositol-3,4,5-trisphosphate dependent Rac exchange factor 1 and transforming growth factor β 1 and prognostic value in gastric cancer
Shao Q, Chen ZM
- 35 Abdominal paracentesis drainage ameliorates myocardial injury in severe experimental pancreatitis rats through suppressing oxidative stress
Wen Y, Sun HY, Tan Z, Liu RH, Huang SQ, Chen GY, Qi H, Tang LJ
- 55 Synergistic protection of astragalus polysaccharides and matrine against ulcerative colitis and associated lung injury in rats
Yan X, Lu QG, Zeng L, Li XH, Liu Y, Du XF, Bai GM

Retrospective Cohort Study

- 70 Risk of gastrointestinal cancer in a symptomatic cohort after a complete colonoscopy: Role of faecal immunochemical test
Pin-Vieito N, Iglesias MJ, Remedios D, Rodríguez-Alonso L, Rodríguez-Moranta F, Álvarez-Sánchez V, Fernández-Bañares F, Boadas J, Martínez-Bauer E, Campo R, Bujanda L, Ferrandez Á, Piñol V, Rodríguez-Alcalde D, Guardiola J, Cubiella J, on behalf of the COLONPREDICT study investigators

Retrospective Study

- 86 Prognostic value of serum microRNA-122 in hepatocellular carcinoma is dependent on coexisting clinical and laboratory factors
Franck M, Schütte K, Malfertheiner P, Link A
- 97 Usefulness of autotaxin for the complications of liver cirrhosis
Shao X, Uojima H, Setsu T, Okubo T, Atsukawa M, Furuichi Y, Arase Y, Hidaka H, Tanaka Y, Nakazawa T, Kako M, Kagawa T, Iwakiri K, Terai S, Koizumi W

ABOUT COVER

Editor-in-Chief of *World Journal of Gastroenterology*, Andrzej S Tarnawski, MD, PhD, DSc (med), FACC, AGAF, AAP, Professor of Medicine, University of California-Irvine, United States, Hon. Professor Chinese University of Hong Kong, Notable Veterans Administration R&D Investigator, Honorary Member of 6 GI International Societies. Gastroenterology Research Department, University of California Irvine and the Veterans Administration Long Beach Healthcare System, Long Beach, CA 90822, United States

AIMS AND SCOPE

The primary aim of *World Journal of Gastroenterology* (*WJG*, *World J Gastroenterol*) is to provide scholars and readers from various fields of gastroenterology and hepatology with a platform to publish high-quality basic and clinical research articles and communicate their research findings online.

WJG mainly publishes articles reporting research results and findings obtained in the field of gastroenterology and hepatology and covering a wide range of topics including gastroenterology, hepatology, gastrointestinal endoscopy, gastrointestinal surgery, gastrointestinal oncology, and pediatric gastroenterology.

INDEXING/ABSTRACTING

The *WJG* is now indexed in Current Contents®/Clinical Medicine, Science Citation Index Expanded (also known as SciSearch®), Journal Citation Reports®, Index Medicus, MEDLINE, PubMed, PubMed Central, and Scopus. The 2019 edition of Journal Citation Report® cites the 2018 impact factor for *WJG* as 3.411 (5-year impact factor: 3.579), ranking *WJG* as 35th among 84 journals in gastroenterology and hepatology (quartile in category Q2). CiteScore (2018): 3.43.

RESPONSIBLE EDITORS FOR THIS ISSUE

Responsible Electronic Editor: Yun-Jie Ma
Proofing Production Department Director: Yun-Xiaojuan Wu

NAME OF JOURNAL

World Journal of Gastroenterology

ISSN

ISSN 1007-9327 (print) ISSN 2219-2840 (online)

LAUNCH DATE

October 1, 1995

FREQUENCY

Weekly

EDITORS-IN-CHIEF

Subrata Ghosh, Andrzej S Tarnawski

EDITORIAL BOARD MEMBERS

<http://www.wjgnet.com/1007-9327/editorialboard.htm>

EDITORIAL OFFICE

Ze-Mao Gong, Director

PUBLICATION DATE

January 7, 2020

COPYRIGHT

© 2020 Baishideng Publishing Group Inc

INSTRUCTIONS TO AUTHORS

<https://www.wjgnet.com/bpg/gerinfo/204>

GUIDELINES FOR ETHICS DOCUMENTS

<https://www.wjgnet.com/bpg/GerInfo/287>

GUIDELINES FOR NON-NATIVE SPEAKERS OF ENGLISH

<https://www.wjgnet.com/bpg/gerinfo/240>

PUBLICATION MISCONDUCT

<https://www.wjgnet.com/bpg/gerinfo/208>

ARTICLE PROCESSING CHARGE

<https://www.wjgnet.com/bpg/gerinfo/242>

STEPS FOR SUBMITTING MANUSCRIPTS

<https://www.wjgnet.com/bpg/GerInfo/239>

ONLINE SUBMISSION

<https://www.f6publishing.com>



Hepatic hemangioma: What internists need to know

Monica Leon, Luis Chavez, Salim Surani

ORCID number: Monica Leon (0000-0001-8652-0725); Luis Chavez (0000-0002-1920-6354); Salim Surani (0000-0001-7105-4266).

Author contributions: All authors have contributed in preparation and review of the manuscript.

Conflict-of-interest statement: All authors declare no conflict of interest related to this publication.

Open-Access: This article is an open-access article which was selected by an in-house editor and fully peer-reviewed by external reviewers. It is distributed in accordance with the Creative Commons Attribution Non Commercial (CC BY-NC 4.0) license, which permits others to distribute, remix, adapt, build upon this work non-commercially, and license their derivative works on different terms, provided the original work is properly cited and the use is non-commercial. See: <http://creativecommons.org/licenses/by-nc/4.0/>

Manuscript source: Unsolicited manuscript

Received: October 30, 2019

Peer-review started: October 30, 2019

First decision: November 22, 2019

Revised: November 26, 2019

Accepted: December 22, 2019

Article in press: December 22, 2019

Published online: January 7, 2020

P-Reviewer: Boteon YL, Coelho J, Li W, Sawada K

S-Editor: Tang JZ

L-Editor: A

E-Editor: Ma YJ

Monica Leon, Centro Medico ABC, Ciudad de Mexico, CDMX 01120, Mexico

Luis Chavez, Department of Internal Medicine, Texas Tech University Health Sciences Center, El Paso, TX 79905, United States

Salim Surani, Texas A&M University, Corpus Christi, TX 78405, United States

Corresponding author: Salim Surani, BSc, FACC, FACP, FCCP, MD, Professor, Texas A&M University, 701 Ayers Street, Corpus Christi, TX 78405, United States. srsurani@hotmail.com

Abstract

Hepatic hemangioma (HH) is the most common benign liver tumor and it is usually found incidentally during radiological studies. This tumor arises from a vascular malformation; however, the pathophysiology has not been clearly elucidated. Symptoms usually correlate with the size and location of the tumor. Less commonly the presence of a large HH may cause life-threatening conditions. The diagnosis can be established by the identification of HH hallmarks in several imaging studies. In patients that present with abdominal symptoms other etiologies should be excluded first before attributing HH as the cause. In asymptomatic patient's treatment is not required and follow up is usually reserved for HH of more than 5 cm. Symptomatic patients can be managed surgically or with other non-surgical modalities such as transcatheter arterial embolization or radiofrequency ablation. Enucleation surgery has shown to have fewer complications as compared to hepatectomy or other surgical techniques. Progression of the tumor is seen in less than 40%. Hormone stimulation may play a role in HH growth; however, there are no contraindications for hormonal therapy in patients with HH due to the lack of concrete evidence. When clinicians encounter this condition, they should discern between observation and surgical or non-surgical management based on the clinical presentation.

Key words: Hepatic hemangioma; Liver masses; Liver; Vascular lesion

©The Author(s) 2020. Published by Baishideng Publishing Group Inc. All rights reserved.

Core tip: Hepatic hemangioma is the most common benign liver tumor and it is usually found incidentally during radiological studies. This tumor arises from a vascular malformation. Symptoms usually correlate with the size and location of the tumor. Symptomatic patients can be managed surgically or with other non-surgical modalities.

Citation: Leon M, Chavez L, Surani S. Hepatic hemangioma: What internists need to know.



World J Gastroenterol 2020; 26(1): 11-20

URL: <https://www.wjgnet.com/1007-9327/full/v26/i1/11.htm>

DOI: <https://dx.doi.org/10.3748/wjg.v26.i1.11>

INTRODUCTION

Hepatic hemangioma (HH) is a mesoderm-derived tumor consisting of a blood-filled space, fed by hepatic arterial circulation and lined by a single layer of flat endothelial cells^[1]. It is the most common benign liver tumor, presenting as a well- circumscribed hypervascular lesion, more commonly found in women with a prevalence that ranges from 0.4% to 7.3% (based on autopsy findings) and an incidence of 0.4%-20% in the general population^[1-5].

HH presents commonly as an incidental finding during radiological imaging and are describe as solitary or multiple lesions. They may be confined to one lobe (more in the right hepatic lobe) or extend throughout the entire liver. According to their dimension they can be small or giant (> 5 cm) and may range from 1 mm up to 50 cm^[2,6]. HH are classified by their nature as cavernous, capillary and sclerosing hemangioma; the latter is characterized by degeneration and fibrous replacement and can be misdiagnosed as a malignant tumor^[7,8].

PATHOGENESIS

The pathophysiology of HH is not completely understood, and in some cases, a genetic predisposition has been described^[9]. HH arises from a vascular malformation with a growing pattern secondary to dilation rather than hypertrophy or hyperplasia.

One hypothesis suggest HH results from abnormal angiogenesis and an increase in pro-angiogenic factors^[10].

Vascular endothelial growth factor (VEGF) is an important pro-angiogenic factor for endothelial cells. Mammalian target of rapamycin (mTOR) stimulates an autocrine loop of VEGF signaling and increase cell proliferation in vascular endothelial cells. TOR proteins are a group of serine/threonine kinases involved in ribosomal biogenesis, mRNA translation and cell mass growth and proliferation^[11]. Zhang *et al*^[12] found an increased expression of VEGF-A, pro-matrix metalloproteinase 2, and activated metalloproteinase 2 in HH cells compared to normal human liver endothelial cells.

Rapamycin inhibits mTOR and has been studied in mouse models and mouse cells as a possible treatment for vascular cell growths (mainly malignancies)^[11].

Rapamycin is currently used as an antifungal, antineoplastic and antibacterial macrolide drug, but no human studies aimed to HH have been done.

Hormones such as estrogens play a role in HH growth, as they are seen more frequently among women and their size increase after hormone replacement therapy (HRT), oral contraceptive pills (OCPs), and pregnancy^[13,14]. The direct mechanisms of hormone effects are unknown, as HH are negative for estrogen and progesterone receptors and current evidence does not support a contraindication of OCPs/HRT/anabolic steroids in patients with HH^[15-18].

SYMPTOMS

HH are usually asymptomatic, however symptoms may present when a HH is larger than > 5 cm^[19]. Symptoms are nonspecific, patients usually describe abdominal pain, discomfort and fullness in the right upper quadrant, secondary to stretching and inflammation of the Glisson's capsule. Tumors > 10 cm present with abdominal distention^[19,20]. The location of the liver mass may cause pressure and compression of adjacent structures causing other symptoms such as nausea, early satiety, and postprandial bloating. Less commonly associated symptoms include fever, jaundice, dyspnea, high-output cardiac failure, and haemobilia^[21-24].

Giant HH may cause a life-threatening coagulation disorder known as Kasabach-Merrit syndrome (thrombocytopenia, disseminated intravascular coagulation, and systemic bleeding) presenting with coagulopathy secondary to thrombocytopenia, anemia, hypofibrinogenemia, a decrease in prothrombin time, and increase in D-dimer. This syndrome has been reported with an incidence ranging from 0.3% of all

HH to 26% in tumors > 15 cm^[19,25].

Another serious complication is bleeding from spontaneous or traumatic rupture (in peripherally located and exophytic giant lesions), however the risk is extremely low (0.47%)^[26].

GROWTH PATTERN

The natural progression of HH varies, previously these lesions were considered to remain stable. However, multiple studies have shown progression and increase in size when followed throughout the years^[27,28]. In a study of 236 patients with a median follow up of 48 mo (3-26), 61% experienced HH size increase with a peak growth rate when HH was 8-10 cm (0.80 ± 0.62 cm/year) and in patients less than 30 years of age^[29].

In another study with 123 patients (163 HH) a 50.9% grew by any amount in absolute mean linear dimension with an annual growth rate of 0.03 cm for all lesions and 0.19 cm for those that grew > 5%. This study also found a correlation with increased annual growth in HH of 5 cm or more at initial size. They predicted an annual growth rate for all HH of 0.34 mm^[5].

DIAGNOSIS

HH unique features by imaging are the presence of peripheral nodular enhancement and a progressive centripetal fill-in. Ultrasound (US), computed tomography (CT), and magnetic resonance imaging (MRI) are the most common imaging tests. Atypical lesions may require more than one imaging test.

US is usually the first diagnostic imaging test due to its availability. HH appears as a well-defined, homogeneously hyper echoic mass with posterior acoustic enhancement (Figure 1). Color-Doppler US does not improve accuracy in diagnosis as it only shows blood flow in HH with an intra arterio-portal shunt^[30,31].

US has a sensitivity of 96.9% and a specificity of 60.3%^[32]. Some malignant hepatic lesions (Hepatocellular carcinoma and hepatic metastases) may produce similar acoustic patterns and other imaging modality must be used to confirm diagnosis.

Contrast-enhanced US (CEUS) uses gas-filled micro bubbles that delineate the signal produced by blood flow. HH shows a peripheral nodular contrast enhancement in the early phase (arterial) with centripetal filling in later phases.

Some studies have proven CEUS improves characterization and specificity for HH diagnosis^[33,34].

CT has a sensitivity of 98.3% and a specificity of 55%^[32]. HH are described as well-demarcated hypodense masses (Figure 2). When contrast is used, a peripheral nodular enhancement with centripetal homogeneous filling is expected, however small lesions and HH with cystic areas, fibrosis or thrombosis may show an atypical pattern^[35].

MRI shows a well-defined, smooth, homogenous lesion, hypointense on T1 and hyperintense on T2 weighted images (Figure 3). Some malignant lesions may show a similar hyperintensity on T2, to differentiate HH from solid neoplastic liver lesions the echo time is increased which causes signal from malignant lesions to decrease and signal from HH to increase. Gadolinium administration shows a peripheral enhancement on arterial phase and contrast retention on delayed phases, which allows differentiating from hypervascular tumors that usually have a contrast washout on delayed phase. MRI has been considered the best imaging method for HH with a sensitivity of 90%-100% and a specificity of 91%-99%^[32,36].

Angiography is the best option for atypical HH that are difficult to diagnose with other imaging test. HH appears as a "snowy-tree" or "cotton wool" with a large feeding vessel and diffuse pooling of contrast that continues during delayed phase. Technetium-99m pertechnetate-labeled red blood cell pool scintigraphy, single photon emission computed tomography and positron emission tomography/CT are other imaging modalities available to diagnose HH in patients with atypical tumors, history of chronic liver disease or malignancy^[37,38].

Needle aspiration biopsy is not recommended because of the high risk of hemorrhage and a low diagnostic yield^[39-41].

MANAGEMENT

Small, asymptomatic HH do not require treatment or follow up. Some authors suggest to follow-up in HH > 5 cm at 6-12 mo to assess for rapid growth with the same

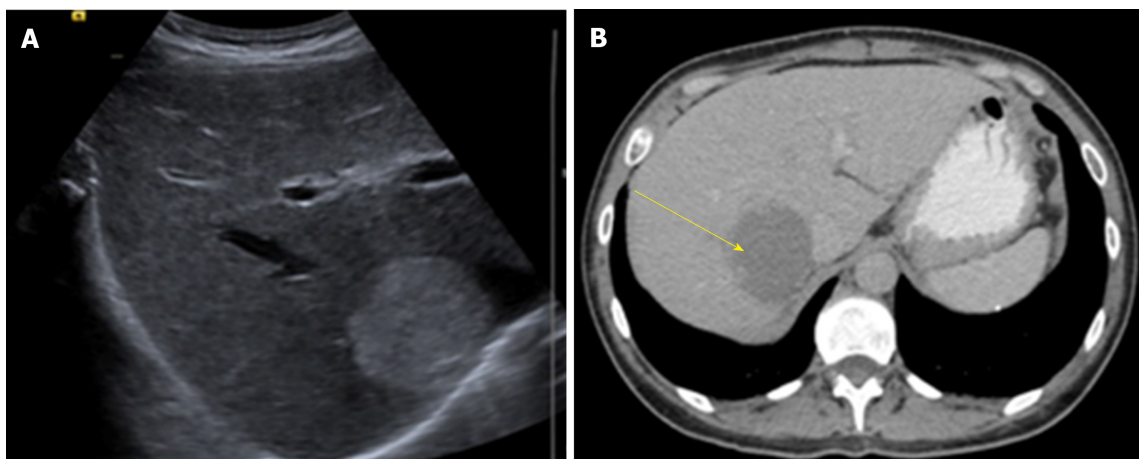


Figure 1 Liver ultrasound and computed tomography abdomen with contrast of a patient with hepatic hemangioma (55 mm × 46 mm). A: Image of ultrasound; B: Image of computed tomography.

imaging test used at diagnosis^[42].

Treatment should be restricted to symptomatic patients, with continuous mass growth, compression of adjacent organs (gastric outlet obstruction, Budd-Chiari syndrome) or complications such as rupture with intraperitoneal bleeding or Kasabach-Merritt syndrome.

Abdominal pain should be carefully evaluated in patients with HH and other possible causes should be kept in mind before definitive treatment is decided. Farges *et al*^[43] diagnosed 87 patients with abdominal pain and HH, from these, 54% were found to have other condition responsible from the abdominal pain. Specific treatment for abdominal pain and HH was required in 14 patients and half of them remained symptomatic after treatment, suggesting another etiology causing the pain. In another study, the majority of patients with abdominal pain and HH were found to have symptoms attributable to different gastrointestinal diseases (Irritable bowel syndrome, gastroesophageal reflux disease, hepatitis, peptic ulcer, gallbladder disease) and in only 21.7% of symptomatic patients, abdominal pain was attributable to HH^[44].

Surgery

Surgery continues to be the most common treatment for HH. Surgical management includes liver resection, enucleation, hepatic artery ligation and liver transplantation. The most common procedures worldwide are liver resection and enucleation (open surgery, laparoscopy or robot)^[45-48].

The first hepatic resection for HH was done in 1987 by Schwartz *et al*^[49] and in 1988 Alper *et al*^[50] reported the first nine patients treated with enucleation.

The choice of procedure depends on the size, number of lesions, location, surgeon experience, and institutional resources. Both techniques carry minimal postoperative morbidity.

In the last years several studies have evaluated enucleation vs hepatectomy and most have concluded that enucleation is associated with lower morbidity, shorter operation time, less blood loss and fewer complications^[47,48,51]. However, when HH is larger than 10 cm, Zhang *et al*^[52] found no difference in operation time, blood loss, complications or hospital stay between enucleation and resection.

Enucleation is technically easier in peripherally located HH, when done in centrally located HH the procedure causes a longer vascular inflow occlusion time, longer operating time and more blood loss^[53]. Centrally located HH (Segments I, IV, V and VIII) are treated with extended right and left hepatectomy. This therapy may remove 60% to 80% of liver parenchyma, which convey a higher risk of postsurgical liver failure. Some lesions are suitable for a wedge resection^[53].

Improvement in laparoscopic surgery has increased the cases treated with minimally invasive surgery for either resection or enucleation. Laparoscopic liver surgery is preferred in small, left lateral lesions with minor resections^[32,54].

A recent retrospective study compared open versus laparoscopic liver surgery for HH; results favored laparoscopic therapy with less blood loss, lower complication rates, and a shorter postoperative hospital stay. However, baseline patient characteristics between the two groups were not equal as surgeons decided open or laparoscopic surgery based on tumor characteristics^[54].

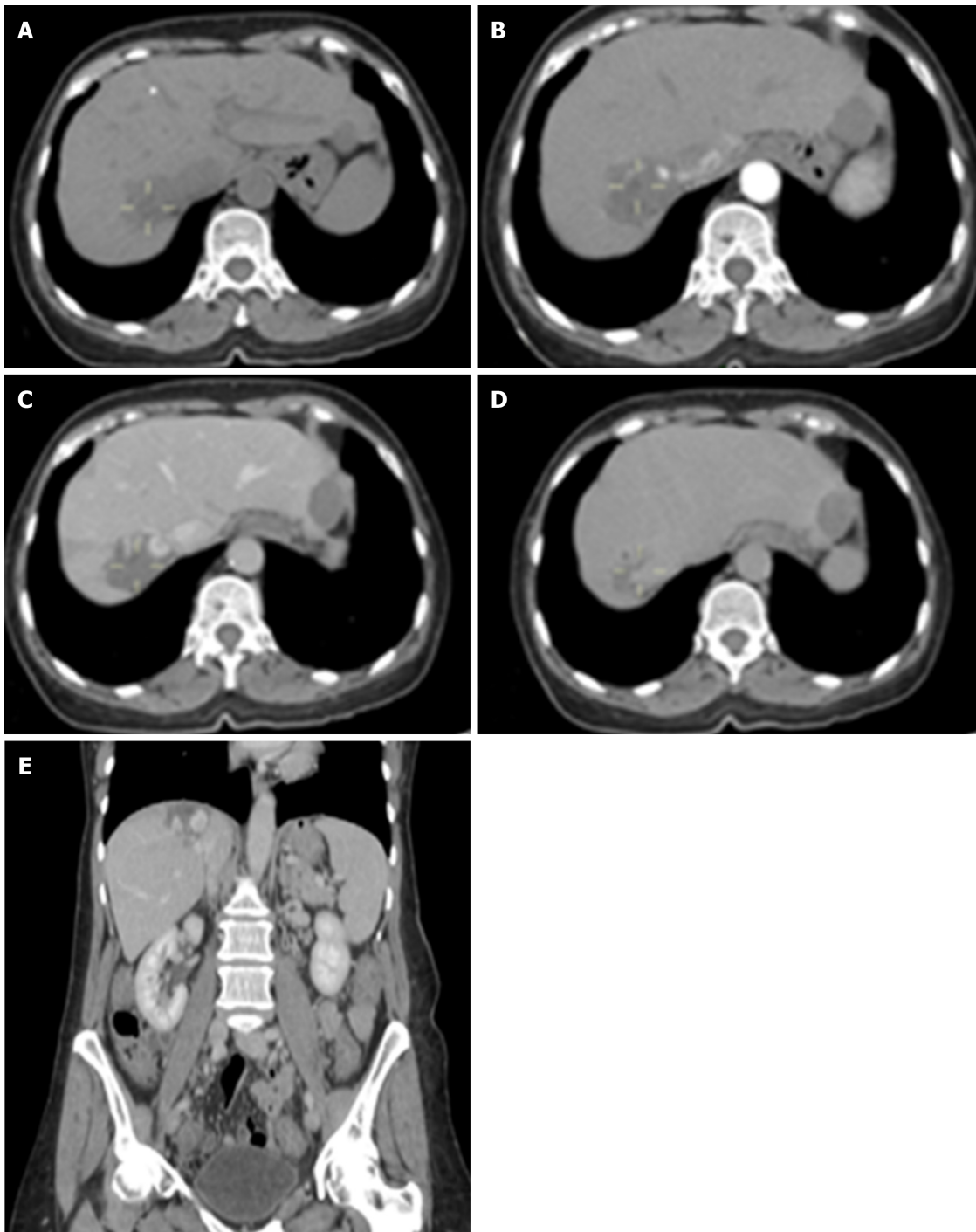


Figure 2 Hepatic hemangioma of 49 mm × 30 mm. A: Non-contrast phase; B: Arterial phase; C: Venous phase; D: Delayed phase; E: Coronal view of computed tomography scan (venous phase).

Liver transplantation for benign solid tumors is not considered a first line treatment due to morbidity and organ shortage. A study published in 2015 analyzed data from the United Network of Organ Sharing from 1988 to 2013 and found 147 (0.17%) liver transplants in US patients were performed for benign tumors of the liver, including 25 for HH^[55].

Liver transplantation is reserved for unresectable giants HH causing severe symptoms (respiratory distress, abdominal pain), failure of previous interventions or life-threatening complications such as Kasabach Merrit syndrome^[56,57].

Non-surgical management

Transcatheter arterial embolization (TAE) is used to control acute bleeding or shrink HH prior to surgery with metallic coils, gelform particles, polyvinyl alcohol and liquid agents such as N-butyl-2-cyanoacrylate, bleomycin-lipiodol^[58-61]. However, TAE

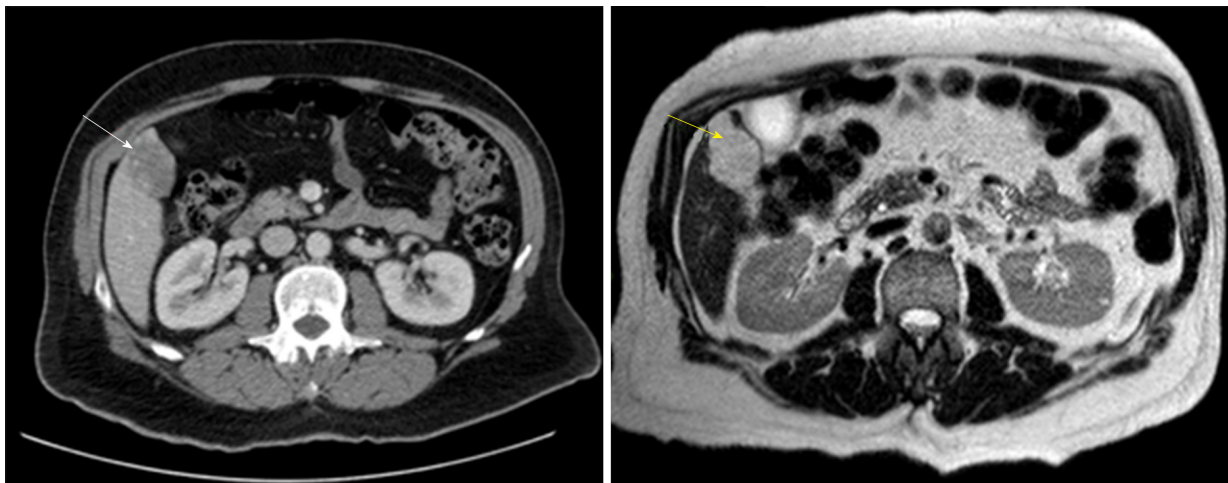


Figure 3 Computed tomography abdomen with contrast (white arrow) and magnetic resonance imaging T2-weighted scan (yellow arrow) with hepatic hemangioma 45 mm × 30 mm.

as also been used as single treatment with acceptable results^[62,63].

A mix of pingyangmycin/lipiodol was first studied as a single treatment for HH. Two studies reported good results with significant reduction of HH volume and relief of symptoms^[64,65]. Pingyangmycin is only available in China, similar studies have been carried in other places with bleomycin as substitute for pingyangmycin^[62,63].

A study with 23 patients (29 HH) managed with TAE with bleomycin-lipiodol concluded 73.9% of patients had > 50% volume regression of HH^[62]. Bleomycin administration results in micro-thrombi formation, which leads to atrophy and fibrosis of the tumor. It also induces a non-specific inflammatory process around the HH and in the portal area. Acute liver failure, liver infarction, abscess, intrahepatic biloma, cholecystitis, splenic infarction, hepatic artery perforation, and sclerosing cholangitis have been reported as associated complications of TAE with Bleomycin^[66].

Radiofrequency ablation (RFA) can be used percutaneously, laparoscopically or by open surgery. RFA induces a thermal damage to endothelial vascular structures and promotes thrombosis. RFA is usually performed under US guidance; CT guidance for percutaneous RFA is suitable for HH located deeply in liver parenchyma^[67].

Laparoscopic RFA with US guidance is preferred for subcapsular HH^[68]. Laparoscopic RFA compared with open resection is associated with shorter operative time, less pain, shorter hospital stay and the lower hospital cost^[69,70].

Lengthy RFA is prone to cause hemolysis, hemoglobinuria and acute kidney injury, thus is not suitable for large HH^[71]. Other complications of RFA include bleeding at the electrode entry site, rupture of HH and injury to adjacent organs by puncture or thermal injury.

The established indications for RFA in this population are maximum diameter of HH > 5 cm, tumor gaining enlargement > 1 cm within 2 years, persistent HH related abdominal pain with exclusion of other GI diseases. Contraindications include patients with severe bleeding tendency, malignant tumors, Kasabach-Merritt syndrome, infection (biliary system inflammation), low immune function, and severe organ failure^[67].

The use of anti-VEGF such as sorafenib and bevacizumab have been reported in case reports to incidentally reduce HH size^[72,73]. A retrospective study aimed to study HH size reduction with anti VEGF (bevacizumab or sunitinib) showed no significant volume reduction^[10]. Metformin has also been reported in a case report to incidentally reduce HH size^[74].

Liver transplant with liver resection graft of HH

In the last years, the donor's criteria for liver transplant has expanded to overcome organ shortage. Liver donors with the discarded partial liver resection from HH have proved to be a viable source for liver transplant with acceptable receptor outcomes and no growth of HH^[75-77].

CONCLUSION

Most HH are diagnosed incidentally on imaging tests since most patients remain

asymptomatic throughout their life. Patients who present with symptoms are usually due to larger lesions.

Since the natural history of HH is benign and an increase in size progression occurs in less than 40%, most patients can be reassured and only observed. When a patient is symptomatic, the first step is to exclude other causes of their symptoms. Once excluding other etiologies and HH is considered the cause of symptoms, treatment modalities are decided based on size, anatomy and comorbidities of the patient.

Over the last years, non-surgical minimal invasive procedures for tumor reduction and laparoscopic surgery have proven good results in selected patients.

Rarely HH present with life-threatening conditions such as an acute traumatic rupture or coagulation disorders. Only in these instances, emergent surgical management is warranted.

Clinicians should discern between observation and the best optimal management based on the clinical presentation. If treatment is needed, a minimal invasive approach should be pursued. Future research will help clinicians understand HH pathogenesis and guide management.

REFERENCES

- Ishak KG, Rabin L. Benign tumors of the liver. *Med Clin North Am* 1975; **59**: 995-1013 [PMID: 167242 DOI: 10.1016/s0025-7125(16)31998-8]
- Yang Z, Tan H, Liu X, Sun Y. Extremely Giant Liver Hemangioma (50 cm) with Kasabach-Merritt Syndrome. *J Gastrointest Surg* 2017; **21**: 1748-1749 [PMID: 28424986 DOI: 10.1007/s11605-017-3429-7]
- Schumacker HB. Hemangioma of the liver: discussion of symptomatology and report of patient treated by operation. *Surgery* 1942; **11**: 209-222
- Reddy KR, Kligerman S, Levi J, Livingstone A, Molina E, Franceschi D, Badalamenti S, Jeffers L, Tzakis A, Schiff ER. Benign and solid tumors of the liver: relationship to sex, age, size of tumors, and outcome. *Am Surg* 2001; **67**: 173-178 [PMID: 11243545]
- Hasan HY, Hinshaw JL, Borman EJ, Gegios A, Levenson G, Winslow ER. Assessing normal growth of hepatic hemangiomas during long-term follow-up. *JAMA Surg* 2014; **149**: 1266-1271 [PMID: 25321079 DOI: 10.1001/jamasurg.2014.477]
- Adam YG, Huvois AG, Fortner JG. Giant hemangiomas of the liver. *Ann Surg* 1970; **172**: 239-245 [PMID: 5433290 DOI: 10.1097/0000658-197008000-00010]
- Mori H, Ikegami T, Imura S, Shimada M, Morine Y, Kanemura H, Arakawa Y, Kanamoto M, Hanaoka J, Sugimoto K, Tokunaga T. Sclerosed hemangioma of the liver: Report of a case and review of the literature. *Hepatol Res* 2008; **38**: 529-533 [PMID: 18067557 DOI: 10.1111/j.1872-034X.2007.00306.x]
- European Association for the Study of the Liver (EASL). EASL Clinical Practice Guidelines on the management of benign liver tumours. *J Hepatol* 2016; **65**: 386-398 [PMID: 27085809 DOI: 10.1016/j.jhep.2016.04.001]
- Moser C, Hany A, Spiegel R. Familial giant hemangiomas of the liver. Study of a family and review of the literature. *Praxis (Bern 1994)* 1998; **87**: 461-468 [PMID: 9587222]
- Lee M, Choi JY, Lim JS, Park MS, Kim MJ, Kim H. Lack of anti-tumor activity by anti-VEGF treatments in hepatic hemangiomas. *Angiogenesis* 2016; **19**: 147-153 [PMID: 26816001 DOI: 10.1007/s10456-016-9494-9]
- Zheng N, Ding X, Jahan R. Low concentration of rapamycin inhibits hemangioma endothelial cell proliferation, migration, and vascular tumor formation in mice. *Curr Ther Res Clin Exp* 2014; **11**: 99-103 [PMID: 25408787 DOI: 10.1016/j.curtheres.2014.09.004]
- Zhang WJ, Ye LY, Wu LQ, Xin YL, Gu F, Niu JX, Yang ZH, Zhu GJ, Grau GE, Lou JN. Morphologic, phenotypic and functional characteristics of endothelial cells derived from human hepatic cavernous hemangioma. *J Vasc Res* 2006; **43**: 522-532 [PMID: 17008795 DOI: 10.1159/000095965]
- Glinkova V, Shevah O, Boaz M, Levine A, Shirin H. Hepatic haemangiomas: possible association with female sex hormones. *Gut* 2004; **53**: 1352-1355 [PMID: 15306599 DOI: 10.1136/gut.2003.038646]
- Ozakyol A, Kebapci M. Enhanced growth of hepatic hemangiomatosis in two adults after postmenopausal estrogen replacement therapy. *Tohoku J Exp Med* 2006; **210**: 257-261 [PMID: 17077603 DOI: 10.1620/tjem.210.257]
- Gemer O, Moscovici O, Ben-Horin CL, Linov L, Peled R, Segal S. Oral contraceptives and liver hemangioma: a case-control study. *Acta Obstet Gynecol Scand* 2004; **83**: 1199-1201 [PMID: 15548156 DOI: 10.1111/j.0001-6349.2004.00551.x]
- Kim GE, Thung SN, Tsui WM, Ferrell LD. Hepatic cavernous hemangioma: underrecognized associated histologic features. *Liver Int* 2006; **26**: 334-338 [PMID: 16584396 DOI: 10.1111/j.1478-3231.2005.01226.x]
- Saegusa T, Ito K, Oba N, Matsuda M, Kojima K, Tohyama K, Matsumoto M, Miura K, Suzuki H. Enlargement of multiple cavernous hemangioma of the liver in association with pregnancy. *Intern Med* 1995; **34**: 207-211 [PMID: 7787330 DOI: 10.2169/internalmedicine.34.207]
- Marrero JA, Ahn J, Rajender Reddy K; Americal College of Gastroenterology. ACG clinical guideline: the diagnosis and management of focal liver lesions. *Am J Gastroenterol* 2014; **109**: 1328-47; quiz 1348 [PMID: 25135008 DOI: 10.1038/ajg.2014.213]
- Sakamoto Y, Kokudo N, Watadani T, Shibahara J, Yamamoto M, Yamaue H; Japanese Society of Hepato-Biliary-Pancreatic Surgery. Proposal of size-based surgical indication criteria for liver hemangioma based on a nationwide survey in Japan. *J Hepatobiliary Pancreat Sci* 2017; **24**: 417-425 [PMID: 28516570 DOI: 10.1002/jhbp.464]
- Luks FI, Yazbeck S, Brandt ML, Bensoussan AL, Brochu P, Blanchard H. Benign liver tumors in children: a 25-year experience. *J Pediatr Surg* 1991; **26**: 1326-1330 [PMID: 1812268 DOI: 10.1016/0022-3468(91)90612-w]
- Liu X, Yang Z, Tan H, Zhou W, Su Y. Fever of Unknown Origin Caused by Giant Hepatic Hemangioma. *J Gastrointest Surg* 2018; **22**: 366-367 [PMID: 28785931 DOI: 10.1007/s11605-017-3522-y]

- 22 **Smith AA**, Nelson M. High-Output Heart Failure from a Hepatic Hemangioma With Exertion-Induced Hypoxia. *Am J Cardiol* 2016; **117**: 157-158 [PMID: [26525213](#) DOI: [10.1016/j.amjcard.2015.10.019](#)]
- 23 **Mikami T**, Hirata K, Oikawa I, Kimura M, Kimura H. Hemobilia caused by a giant benign hemangioma of the liver: report of a case. *Surg Today* 1998; **28**: 948-952 [PMID: [9744407](#) DOI: [10.1007/s005950050259](#)]
- 24 **Huang SA**, Tu HM, Harney JW, Venihaki M, Butte AJ, Kozakewich HP, Fishman SJ, Larsen PR. Severe hypothyroidism caused by type 3 iodothyronine deiodinase in infantile hemangiomas. *N Engl J Med* 2000; **343**: 185-189 [PMID: [10900278](#) DOI: [10.1056/NEJM200007203430305](#)]
- 25 **Miura JT**, Amini A, Schmocker R, Nichols S, Sukato D, Winslow ER, Spolverato G, Ejaz A, Squires MH, Kooby DA, Maithel SK, Li A, Wu MC, Sarmiento JM, Bloomston M, Christians KK, Johnston FM, Tsai S, Turaga KK, Tsung A, Pawlik TM, Gamblin TC. Surgical management of hepatic hemangiomas: a multi-institutional experience. *HPB (Oxford)* 2014; **16**: 924-928 [PMID: [24946109](#) DOI: [10.1111/hpb.12291](#)]
- 26 **Mocchegiani F**, Vincenzi P, Coletta M, Agostini A, Marziani M, Baroni GS, Giovagnoni A, Guerrieri M, Marmorale C, Risaliti A, Vivarelli M. Prevalence and clinical outcome of hepatic haemangioma with specific reference to the risk of rupture: A large retrospective cross-sectional study. *Dig Liver Dis* 2016; **48**: 309-314 [PMID: [26514738](#) DOI: [10.1016/j.dld.2015.09.016](#)]
- 27 **Gibney RG**, Hendin AP, Cooperberg PL. Sonographically detected hepatic hemangiomas: absence of change over time. *AJR Am J Roentgenol* 1987; **149**: 953-957 [PMID: [3314430](#) DOI: [10.2214/ajr.149.5.953](#)]
- 28 **Tait N**, Richardson AJ, Muguti G, Little JM. Hepatic cavernous haemangioma: a 10 year review. *Aust N Z J Surg* 1992; **62**: 521-524 [PMID: [1610320](#) DOI: [10.1111/j.1445-2197.1992.tb07043.x](#)]
- 29 **Jing L**, Liang H, Caifeng L, Jianjun Y, Feng X, Mengchao W, Yiqun Y. New recognition of the natural history and growth pattern of hepatic hemangioma in adults. *Hepatol Res* 2016; **46**: 727-733 [PMID: [26492419](#) DOI: [10.1111/hepr.12610](#)]
- 30 **Perkins AB**, Imam K, Smith WJ, Cronan JJ. Color and power Doppler sonography of liver hemangiomas: a dream unfulfilled? *J Clin Ultrasound* 2000; **28**: 159-165 [PMID: [10751735](#) DOI: [10.1002/\(sici\)1097-0096\(200005\)28:4<159::aid-jcu1>3.0.co;2-b](#)]
- 31 **Lim KJ**, Kim KW, Jeong WK, Kim SY, Jang YJ, Yang S, Lee JJ. Colour Doppler sonography of hepatic haemangiomas with arterioportal shunts. *Br J Radiol* 2012; **85**: 142-146 [PMID: [21385916](#) DOI: [10.1259/bjr/96605786](#)]
- 32 **Toro A**, Mahfouz AE, Ardiri A, Malaguarnera M, Malaguarnera G, Loria F, Bertino G, Di Carlo I. What is changing in indications and treatment of hepatic hemangiomas. A review. *Ann Hepatol* 2014; **13**: 327-339 [PMID: [24927603](#) DOI: [10.1016/S1665-2681\(19\)30839-7](#)]
- 33 **Dietrich CF**, Mertens JC, Braden B, Schuessler G, Ott M, Ignee A. Contrast-enhanced ultrasound of histologically proven liver hemangiomas. *Hepatology* 2007; **45**: 1139-1145 [PMID: [17464990](#) DOI: [10.1002/hep.21615](#)]
- 34 **Quaia E**, Calliada F, Bertolotto M, Rossi S, Garioni L, Rosa L, Pozzi-Mucelli R. Characterization of focal liver lesions with contrast-specific US modes and a sulfur hexafluoride-filled microbubble contrast agent: diagnostic performance and confidence. *Radiology* 2004; **232**: 420-430 [PMID: [15286314](#) DOI: [10.1148/radiol.2322031401](#)]
- 35 **Yamashita Y**, Ogata I, Urata J, Takahashi M. Cavernous hemangioma of the liver: pathologic correlation with dynamic CT findings. *Radiology* 1997; **203**: 121-125 [PMID: [9122378](#) DOI: [10.1148/radiology.203.1.9122378](#)]
- 36 **McFarland EG**, Mayo-Smith WW, Saini S, Hahn PF, Goldberg MA, Lee MJ. Hepatic hemangiomas and malignant tumors: improved differentiation with heavily T2-weighted conventional spin-echo MR imaging. *Radiology* 1994; **193**: 43-47 [PMID: [8090920](#) DOI: [10.1148/radiology.193.1.8090920](#)]
- 37 **Caturelli E**, Pompili M, Bartolucci F, Siena DA, Sperandeo M, Andriulli A, Bisceglia M. Hemangioma-like lesions in chronic liver disease: diagnostic evaluation in patients. *Radiology* 2001; **220**: 337-342 [PMID: [11477234](#) DOI: [10.1148/radiology.220.2.r01au14337](#)]
- 38 **Imperiale A**, Greget M, Chabrier G, Keomany J, Rust E, Detour J, Pessaux P, Goichot B. Solitary hepatic metastasis from medullary thyroid carcinoma mimicking atypical hemangioma: insights from multimodality diagnostic approach by MRI, F-18 FDG and F-18 FDOPA PET/CT. *Clin Nucl Med* 2010; **35**: 434-437 [PMID: [20479594](#) DOI: [10.1097/RLU.0b013e3181db4e45](#)]
- 39 **Terriff BA**, Gibney RG, Scudamore CH. Fatality from fine-needle aspiration biopsy of a hepatic hemangioma. *AJR Am J Roentgenol* 1990; **154**: 203-204 [PMID: [2104717](#) DOI: [10.2214/ajr.154.1.2104717](#)]
- 40 **Davies R**. Haemorrhage after fine-needle aspiration biopsy of an hepatic haemangioma. *Med J Aust* 1993; **158**: 364 [PMID: [8474396](#) DOI: [10.5694/j.1326-5377.1993.tb121823.x](#)]
- 41 **Taavitsainen M**, Airaksinen T, Kreula J, Päivänsalo M. Fine-needle aspiration biopsy of liver hemangioma. *Acta Radiol* 1990; **31**: 69-71 [PMID: [2187514](#) DOI: [10.3109/02841859009173055](#)]
- 42 **Bajenaru N**, Balaban V, Săvulescu F, Campeanu I, Patrascu T. Hepatic hemangioma -review-. *J Med Life* 2015; **8**: 4-11 [PMID: [26361504](#)]
- 43 **Farges O**, Daradkeh S, Bismuth H. Cavernous hemangiomas of the liver: are there any indications for resection? *World J Surg* 1995; **19**: 19-24 [PMID: [7740805](#) DOI: [10.1007/bf00316974](#)]
- 44 **Etemadi A**, Golozar A, Ghassabian A, Zarei M, Hashemi Taheri AP, Dawsey SM, Malekzadeh R. Cavernous hemangioma of the liver: factors affecting disease progression in general hepatology practice. *Eur J Gastroenterol Hepatol* 2011; **23**: 354-358 [PMID: [21383624](#) DOI: [10.1097/MEG.0b013e3283451e7d](#)]
- 45 **Ozden I**, Emre A, Alper A, Tunaci M, Acarli K, Bilge O, Tekant Y, Ariogul O. Long-term results of surgery for liver hemangiomas. *Arch Surg* 2000; **135**: 978-981 [PMID: [10922262](#) DOI: [10.1001/archsurg.135.8.978](#)]
- 46 **Efthimiadis C**, Ioannidis A, Grigoriou M, Kofina K, Lazaridis M, Kosmidis C. Robotic right segmental hepatectomy for the treatment of a giant hepatic hemangioma-a case report. *J Surg Case Rep* 2017; **2017**: rjx118 [PMID: [28698794](#) DOI: [10.1093/jscr/rjx118](#)]
- 47 **Liu Y**, Wei X, Wang K, Shan Q, Dai H, Xie H, Zhou L, Xu X, Zheng S. Enucleation versus Anatomic Resection for Giant Hepatic Hemangioma: A Meta-Analysis. *Gastrointest Tumors* 2017; **3**: 153-162 [PMID: [28611982](#) DOI: [10.1159/000455846](#)]
- 48 **Cheng WL**, Qi YQ, Wang B, Tian L, Huang W, Chen Y. Enucleation versus hepatectomy for giant hepatic haemangiomas: a meta-analysis. *Ann R Coll Surg Engl* 2017; **99**: 237-241 [PMID: [27869486](#) DOI: [10.1308/rcsann.2016.0349](#)]

- 49 **Schwartz SI**, Husser WC. Cavernous hemangioma of the liver. A single institution report of 16 resections. *Ann Surg* 1987; **205**: 456-465 [PMID: 3555360 DOI: 10.1097/0000658-198705000-00003]
- 50 **Alper A**, Ariogul O, Emre A, Uras A, Okten A. Treatment of liver hemangiomas by enucleation. *Arch Surg* 1988; **123**: 660-661 [PMID: 3358693 DOI: 10.1001/archsurg.1988.01400290146027]
- 51 **Giuliente F**, Ardito F, Vellone M, Giordano M, Ranucci G, Piccoli M, Giovannini I, Chiarla C, Nuzzo G. Reappraisal of surgical indications and approach for liver hemangioma: single-center experience on 74 patients. *Am J Surg* 2011; **201**: 741-748 [PMID: 20937504 DOI: 10.1016/j.amjsurg.2010.03.007]
- 52 **Zhang W**, Huang ZY, Ke CS, Wu C, Zhang ZW, Zhang BX, Chen YF, Zhang WG, Zhu P, Chen XP. Surgical Treatment of Giant Liver Hemangioma Larger Than 10cm: A Single Center's Experience With 86 Patients. *Medicine (Baltimore)* 2015; **94**: e1420 [PMID: 26313792 DOI: 10.1097/MD.0000000000001420]
- 53 **Fu XH**, Lai EC, Yao XP, Chu KJ, Cheng SQ, Shen F, Wu MC, Lau WY. Enucleation of liver hemangiomas: is there a difference in surgical outcomes for centrally or peripherally located lesions? *Am J Surg* 2009; **198**: 184-187 [PMID: 19324327 DOI: 10.1016/j.amjsurg.2008.09.029]
- 54 **Liu Q**, Liu F, Ding J, Wei Y, Li B. Surgical outcomes and quality of life between laparoscopic and open approach for hepatic hemangioma: A propensity score matching analysis. *Medicine (Baltimore)* 2019; **98**: e14485 [PMID: 30732219 DOI: 10.1097/MD.00000000000014485]
- 55 **Sundar Alagusundaramoorthy S**, Vilchez V, Zanni A, Sourianarayanan A, Maynard E, Shah M, Daily MF, Pena LR, Gedaly R. Role of transplantation in the treatment of benign solid tumors of the liver: a review of the United Network of Organ Sharing data set. *JAMA Surg* 2015; **150**: 337-342 [PMID: 25714928 DOI: 10.1001/jamasurg.2014.3166]
- 56 **Prodromidou A**, Machairas N, Garoufalia Z, Kostakis ID, Tsaparas P, Paspala A, Stamopoulos P, Sotiropoulos GC. Liver Transplantation for Giant Hepatic Hemangioma: A Systematic Review. *Transplant Proc* 2019; **51**: 440-442 [PMID: 30879561 DOI: 10.1016/j.transproceed.2019.01.018]
- 57 **Longeville JH**, de la Hall P, Dolan P, Holt AW, Lillie PE, Williams JA, Padbury RT. Treatment of a giant haemangioma of the liver with Kasabach-Merritt syndrome by orthotopic liver transplant a case report. *HPB Surg* 1997; **10**: 159-162 [PMID: 9174860 DOI: 10.1155/1997/10136]
- 58 **Jain V**, Ramachandran V, Garg R, Pal S, Gamanagatti SR, Srivastava DN. Spontaneous rupture of a giant hepatic hemangioma - sequential management with transcatheter arterial embolization and resection. *Saudi J Gastroenterol* 2010; **16**: 116-119 [PMID: 20339183 DOI: 10.4103/1319-3767.61240]
- 59 **Bailey J**, Di Carlo S, Blackwell J, Gomez D. Same day arterial embolisation followed by hepatic resection for treatment of giant haemangioma. *BMJ Case Rep* 2016; **2016** [PMID: 26917792 DOI: 10.1136/bcr-2015-213259]
- 60 **Zhou JX**, Huang JW, Wu H, Zeng Y. Successful liver resection in a giant hemangioma with intestinal obstruction after embolization. *World J Gastroenterol* 2013; **19**: 2974-2978 [PMID: 23704832 DOI: 10.3748/wjg.v19.i19.2974]
- 61 **Igarashi G**, Mikami K, Sawada N, Endo T, Sueyoshi N, Sato K, Tsushima F, Kakehata S, Ono S, Aoki M, Kurose A, Iwamura H, Fukuda S. Interventional Treatment for Giant Hepatic Hemangioma Accompanied by Arterio-portal Shunt with Ascites. *Intern Med* 2018; **57**: 2847-2851 [PMID: 29709944 DOI: 10.2169/internalmedicine.0655-17]
- 62 **Akhlaghpour S**, Torkian P, Golzarian J. Transarterial Bleomycin-Lipiodol Embolization (B/LE) for Symptomatic Giant Hepatic Hemangioma. *Cardiovasc Intervent Radiol* 2018; **41**: 1674-1682 [PMID: 29922860 DOI: 10.1007/s00270-018-2010-4]
- 63 **Özden İ**, Poyanlı A, Önal Y, Demir AA, Hoş G, Acunaş B. Superselective Transarterial Chemoembolization as an Alternative to Surgery in Symptomatic/Enlarging Liver Hemangiomas. *World J Surg* 2017; **41**: 2796-2803 [PMID: 28634838 DOI: 10.1007/s00268-017-4069-5]
- 64 **Li Y**, Jia Y, Li S, Wang W, Wang Z, Wang Y, Liu B, Wang W, Chang H, Li Z. Transarterial Chemoembolization of Giant Liver Haemangioma: A Multi-center Study with 836 Cases. *Cell Biochem Biophys* 2015; **73**: 469-472 [PMID: 27352340 DOI: 10.1007/s12013-015-0680-y]
- 65 **Sun JH**, Nie CH, Zhang YL, Zhou GH, Ai J, Zhou TY, Zhu TY, Zhang AB, Wang WL, Zheng SS. Transcatheter Arterial Embolization Alone for Giant Hepatic Hemangioma. *PLoS One* 2015; **10**: e0135158 [PMID: 26287964 DOI: 10.1371/journal.pone.0135158]
- 66 **Jin S**, Shi XJ, Sun XD, Wang SY, Wang GY. Sclerosing cholangitis secondary to bleomycin-iodinated embolization for liver hemangioma. *World J Gastroenterol* 2014; **20**: 17680-17685 [PMID: 25516686 DOI: 10.3748/wjg.v20.i46.17680]
- 67 **Gao J**, Fan RF, Yang JY, Cui Y, Ji JS, Ma KS, Li XL, Zhang L, Xu CL, Kong XL, Ke S, Ding XM, Wang SH, Yang MM, Song JJ, Zhai B, Nin CM, Guo SG, Xin ZH, Lu J, Dong YH, Zhu HQ, Sun WB. Radiofrequency ablation for hepatic hemangiomas: A consensus from a Chinese panel of experts. *World J Gastroenterol* 2017; **23**: 7077-7086 [PMID: 29093616 DOI: 10.3748/wjg.v23.i39.7077]
- 68 **Gao J**, Ji JS, Ding XM, Ke S, Xin ZH, Ning CM, Guo SG, Li XL, Dong YH, Sun WB. Laparoscopic Radiofrequency Ablation for Large Subcapsular Hepatic Hemangiomas: Technical and Clinical Outcomes. *PLoS One* 2016; **11**: e0149755 [PMID: 26901132 DOI: 10.1371/journal.pone.0149755]
- 69 **Zhang X**, Yan L, Li B, Wen T, Wang W, Xu M, Wei Y, Yang J. Comparison of laparoscopic radiofrequency ablation versus open resection in the treatment of symptomatic-enlarging hepatic hemangiomas: a prospective study. *Surg Endosc* 2016; **30**: 756-763 [PMID: 26123327 DOI: 10.1007/s00464-015-4274-y]
- 70 **Chen L**, Zhang L, Tian M, Hu Q, Zhao L, Xiong J. Safety and effective of laparoscopic microwave ablation for giant hepatic hemangioma: A retrospective cohort study. *Ann Med Surg (Lond)* 2019; **39**: 29-35 [PMID: 30899458 DOI: 10.1016/j.amsu.2019.02.001]
- 71 **van Tilborg AAJM**, Dresselaars HF, Scheffer HJ, Nielsen K, Sietses C, van den Tol PM, Meijerink MR. RF Ablation of Giant Hemangiomas Inducing Acute Renal Failure: A Report of Two Cases. *Cardiovasc Intervent Radiol* 2016; **39**: 1644-1648 [PMID: 27387187 DOI: 10.1007/s00270-016-1415-1]
- 72 **Yamashita S**, Okita K, Harada K, Hirano A, Kimura T, Kato A, Okita K. Giant cavernous hepatic hemangioma shrunk by use of sorafenib. *Clin J Gastroenterol* 2013; **6**: 55-62 [PMID: 23396631 DOI: 10.1007/s12328-012-0343-0]
- 73 **Mahajan D**, Miller C, Hirose K, McCullough A, Yerian L. Incidental reduction in the size of liver hemangioma following use of VEGF inhibitor bevacizumab. *J Hepatol* 2008; **49**: 867-870 [PMID: 18814928 DOI: 10.1016/j.jhep.2008.06.028]
- 74 **Ono M**, Sawada K, Okumura T. A case of liver hemangioma with markedly reduced tumor size after metformin treatment: a case report. *Clin J Gastroenterol* 2017; **10**: 63-67 [PMID: 27995469 DOI: 10.1007/s12328-016-0705-0]
- 75 **Onishi Y**, Kamei H, Imai H, Kurata N, Hori T, Ogura Y. Successful adult-to-adult living donor liver

- transplantation using liver allograft after the resection of hemangioma: A suggestive case for a further expansion of living donor pool. *Int J Surg Case Rep* 2015; **16**: 166-170 [PMID: [26476494](#) DOI: [10.1016/j.ijscr.2015.09.043](#)]
- 76 **Li G**, Mu X, Huang X, Qian X, Qin J, Tan Z, Zhang W, Xu X, Tan S, Zhu Z, Li W, Wang X, Wang X, Sun B. Liver transplantation using the otherwise-discarded partial liver resection graft with hepatic benign tumor: Analysis of a preliminary experience on 15 consecutive cases. *Medicine (Baltimore)* 2017; **96**: e7295 [PMID: [28723742](#) DOI: [10.1097/MD.00000000000007295](#)]
- 77 **Sun B**, Mu X, Wang X. Successful adult-to-adult liver transplantation of an otherwise discarded partial liver allograft with a cavernous hemangioma: new strategy for expanding liver donor pool. *Transpl Int* 2013; **26**: e79-e80 [PMID: [23721088](#) DOI: [10.1111/tri.12119](#)]



Published By Baishideng Publishing Group Inc
7041 Koll Center Parkway, Suite 160, Pleasanton, CA 94566, USA
Telephone: +1-925-2238242
E-mail: bpgoffice@wjgnet.com
Help Desk: <http://www.f6publishing.com/helpdesk>
<http://www.wjgnet.com>

