

New endoscopic ultrasound techniques for digestive tract diseases: A comprehensive review

Fan-Sheng Meng, Zhao-Hong Zhang, Feng Ji

Fan-Sheng Meng, Feng Ji, Department of Gastroenterology, the First Affiliated Hospital, Zhejiang University, Hangzhou 310000, Zhejiang Province, China

Zhao-Hong Zhang, Department of Hematology, People's Hospital of Linyi, Linyi 276300, Shandong Province, China

Author contributions: Meng FS and Zhang ZH searched the literature and wrote the manuscript; Ji F critically revised the manuscript; Meng FS and Zhang ZH contributed equally to this manuscript.

Conflict-of-interest: The authors declare no conflicts of interest.

Open-Access: This article is an open-access article which was selected by an in-house editor and fully peer-reviewed by external reviewers. It is distributed in accordance with the Creative Commons Attribution Non Commercial (CC BY-NC 4.0) license, which permits others to distribute, remix, adapt, build upon this work non-commercially, and license their derivative works on different terms, provided the original work is properly cited and the use is non-commercial. See: <http://creativecommons.org/licenses/by-nc/4.0/>

Correspondence to: Feng Ji, MD, Department of Gastroenterology, the First Affiliated Hospital, Zhejiang University, 79 Qingchun Road, Hangzhou 310000, Zhejiang Province,

China. jifeng1126@sina.com

Telephone: +86-571-87236586

Fax: +86-571-87236611

Received: October 22, 2014

Peer-review started: October 27, 2014

First decision: December 11, 2014

Revised: January 14, 2015

Accepted: March 12, 2015

Article in press: March 12, 2015

Published online: April 28, 2015

masses and lymphadenopathy. EUS-elastography evaluates tissue elasticity and therefore, can be used to differentiate various lesions. Contrast-enhanced EUS can distinguish benign from malignant pancreatic lesions and lymphadenopathy using the intravenous injection of contrast agents. This review discusses the principles and types of these new techniques, as well as their clinical applications and limitations.

Key words: Endoscopic ultrasound; Elastography; Contrast-enhanced; New techniques; Digestive tract diseases

© **The Author(s) 2015.** Published by Baishideng Publishing Group Inc. All rights reserved.

Core tip: This article primarily focuses on emerging techniques such as elastography and contrast-enhanced endoscopic ultrasound. Principles, types and clinical applications are discussed. These emerging techniques have high accuracy, sensitivity and specificity in differential diagnosis between benign and malignant lesions.

Meng FS, Zhang ZH, Ji F. New endoscopic ultrasound techniques for digestive tract diseases: A comprehensive review. *World J Gastroenterol* 2015; 21(16): 4809-4816 Available from: URL: <http://www.wjgnet.com/1007-9327/full/v21/i16/4809.htm> DOI: <http://dx.doi.org/10.3748/wjg.v21.i16.4809>

Abstract

Endoscopic ultrasound (EUS) is one of the most important modalities for the diagnosis of digestive tract diseases. EUS has been evolving ever since it was introduced. New techniques such as elastography and contrast enhancement have emerged, increasing the accuracy, sensitivity and specificity of EUS for the diagnosis of digestive tract diseases including pancreatic

INTRODUCTION

Endoscopic ultrasound (EUS) has continuously evolved since its initial introduction. With the development of accessories and technologies, EUS-guided fine-needle aspiration (FNA) has emerged as the gold standard for the diagnosis of gastrointestinal lesions. However, EUS-FNA is technically demanding and is associated

with a low (but not negligible) risk of complications. EUS-elastography and contrast-enhanced EUS have emerged as non-invasive techniques in diagnosis of digestive disorders. Recently, 3-D EUS technology and EUS-guided interventions such as biliary and pancreatic fluid collection drainage and fine-needle injections have been introduced and are rapidly gaining in popularity. EUS-guided interventions will be discussed elsewhere.

Recently, many studies have demonstrated that elastography and contrast-enhanced EUS have high accuracy, sensitivity and specificity in discriminating between benign and malignant lesions (Table 1).

EUS-ELASTOGRAPHY

Principle

Elasticity varies in different types of tissues and in the same tissue affected by different pathologic states^[1]. Elastography can evaluate the hardness of tissue by measuring its elasticity^[2]. The principle of elastography is that tissue compression produces strain; alterations in strain can be detected and displayed in real time alongside conventional B-mode images with special software^[3,4]. Elastography was developed in order to complement conventional EUS for the assessment of previously hard-to-reach tumors near the gastrointestinal tract, such as pancreatic masses^[5,6] and lymph nodes^[1,7].

Categories

Qualitative elastography: Less tissue deformation is caused by compression of hard tissue than of soft tissue^[4]. The degree of deformation is represented by different colors^[4,8]. Hard tissue is blue and soft tissue is red; tissues with an intermediate elasticity are in the green-yellow spectrum^[6,9].

Quantitative elastography

Hue/SH analysis: A histogram is used to represent the digital color distribution. Specialized software (Image J or SH) analyzes the color of the pixels inside the target lesions and each pixel color is represented by a value from 0 to 255 (soft to hard)^[4,8]. Histograms produce an average value that represents the overall elasticity of tissues^[6].

Strain ratio: Strain ratio (SR) is based on a different principle from histograms. The elasticity of the target tissue is expressed not as an absolute value, but as a relative ratio compared to the reference value provided by these tissues^[2]. Two non-overlapping areas inside the region of interest (ROI) are selected: The lesion (area A) and the reference zone (area B). The B/A quotient yields the SR^[10,11].

Elastography has been used to evaluate several organs including the breast, thyroid, prostate, cervix, liver and others^[12,13]. Studies have demonstrated that

primarily blue masses are malignant, whereas red and green masses are considered to be benign.

CONTRAST-ENHANCED EUS

Principle

The contrast agents used in this new technique are gas-containing microbubbles that are covered by a protective shell^[14]. The principles of contrast-enhanced EUS are as follows: when subjected to an ultrasonic signal, the microbubbles oscillate or break and generate components that can be detected and reconstructed on an ultrasound image^[15,16], and components of a higher frequency are required for EUS enhancement^[17].

Two generations of contrast agents have been developed. The first-generation agent was Levovist, which is composed of microbubbles of air covered by galactose and palmitic acid^[18]. However, Levovist requires high acoustic power to oscillate the microbubbles. Second-generation contrast agents, such as Sonovue, Sonazoid and Definity, can be oscillated or broken by lower acoustic power^[19,20]. The development of these contrast agents promoted the use of harmonic imaging in EUS^[21].

The contrast microbubbles are restricted to the vascular system and do not lead to enhancement of the entire circulatory system^[21]. They are generally safe, and adverse events have rarely been observed.

Categories

Contrast-enhanced color and power Doppler sonography (CD-EUS): CD-EUS allows the detection of intra-tumoral vasculature through the enhancement of tumor vessels^[22,23]; it increases the sensitivity to signals from vessels by producing pseudo-Doppler signals from microbubbles^[24]. However, CD-EUS technique has a limited ability to detect slow blood flow and it suffers from Doppler-related artifacts such as motion and blooming^[14,25].

Contrast-enhanced harmonic EUS (CH-EUS): CH-EUS has been developed to overcome the limitations of CD-EUS. This technique allows microvessels and parenchymal perfusion to be visualized^[26]. Moreover, by measuring the time-course of changes in the intensity of echogenicity (time-intensity curve), vascularity can be quantitatively analyzed^[27,28].

EUS-GUIDED CONFOCAL MICROSCOPY

Confocal endomicroscopy is an emerging technique and allows real-time optical biopsies to be performed in the gastrointestinal tract. The technique uses a EUS puncture needle in which the stylet is replaced by a confocal mini-probe. The mini-probe, which is preloaded into the EUS needle, is guided

Table 1 Summary of studies with new endoscopic ultrasound techniques

Ref.	No. of cases	Target lesions	Techniques	Accuracy	Specificity	Sensitivity
König <i>et al</i> ^[13]	151	Prostatic lesions	RTE	84.10%	N/A	N/A
Kanamori <i>et al</i> ^[48]	46	LN lesions	CE	82.10%	77.30%	88.20%
Alam <i>et al</i> ^[12]	85	LN lesions	RTE	84%	59%	98%
Kamoi <i>et al</i> ^[54]	107	Prostatic Lesions	RTE	76%	81%	68%
Ohno <i>et al</i> ^[44]	87	IPMNs	CE	75.90%	92.90%	60%
Giovannini <i>et al</i> ^[33]	222	LN and PLs	RTE	N/A	82.5% (LN) 80.0% (PL)	91.8% (LN) 92.3% (PL)
Săftoiu <i>et al</i> ^[22]	54	Pancreatic masses	CE and RTE	83.30%	95.20%	75.80%
Napoleon <i>et al</i> ^[42]	35	Pancreatic masses	CE	86%	88%	89%
Xia <i>et al</i> ^[49]	43	Intra-abdominal lesions	CE	97.60%	100%	96.30%
Săftoiu <i>et al</i> ^[6]	258	Pancreatic masses	RTE	85.40%	66%	93.40%
Xu <i>et al</i> ^[7]	368	LN lesions	RTE	N/A	91%	85%
Sakamoto <i>et al</i> ^[51]	76	GISTs	CH	83%	63%	100%
Kapoor <i>et al</i> ^[55]	50	Prostatic lesions	RTE	N/A	86.80%	91.70%
Waage <i>et al</i> ^[56]	69	Rectal lesions	RTE	94%	96%	93%
Hocke <i>et al</i> ^[5]	58	Pancreatic lesions	RTE	N/A	94.7%(RTE) 89.5%(CE)	33.4%(RTE) 92.3%(CE)
Dawwas <i>et al</i> ^[31]	104	Pancreatic masses	RTE	86.50%	16.70%	100%
Kitano <i>et al</i> ^[39]	277	Pancreatic lesions	CH	N/A	94.40%	91.20%
Gong <i>et al</i> ^[41]	1139	Pancreatic masses	CE	N/A	93%	93%
Knabe <i>et al</i> ^[3]	40	LN lesions	RTE	51.5	86.70%	88.90%
Lee <i>et al</i> ^[43]	37	Pancreatic lesions	CH	92%	N/A	93%
Havre <i>et al</i> ^[34]	39	Pancreatic lesions	RTE	N/A	71%	67%
Imazu <i>et al</i> ^[59]	36	GB lesions	CH	94.40%	98%	89.60%

LN: Lymph node; PL: Pancreatic lesion; RTE: Real-time elastography; CE: Contrast-enhanced; CH: Contrast-enhanced harmonic; IPMN: Intraductal papillary mucinous neoplasm; GIST: Gastrointestinal stromal tumor; GB: Gallbladder; N/A: Not available.

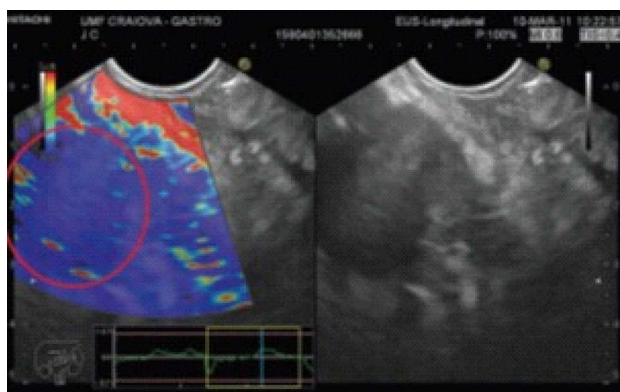


Figure 1 A patient with a malignant pancreatic tumor. The elastography image in the left panel shows a homogeneous blue mass (red circle). The B-mode reference image is shown in the right panel (Popescu *et al*^[4]).

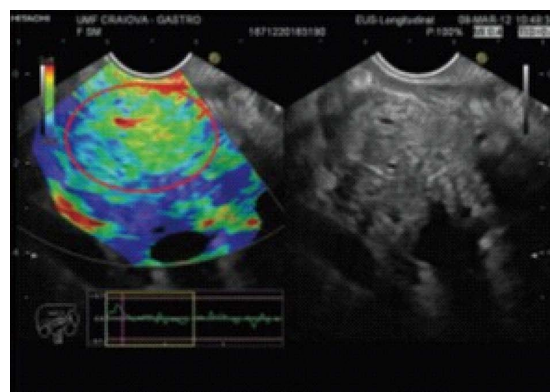


Figure 2 A patient with chronic pancreatitis. The elastography image in the left panel shows a heterogeneous green mass (red circle). The B-mode reference image is shown in the right panel (Popescu *et al*^[4]).

endosonographically into the target lesion. The intratumoral CM examination begins after the injection of fluorescein^[29,30].

CLINICAL APPLICATIONS

EUS-elastography and CH-EUS for solid pancreatic lesions

Many published studies have reported that a EUS-elastography finding of a blue (*i.e.*, hard) pancreatic lesion is highly sensitive and specific for adenocarcinoma (Figure 1). Chronic pancreatitis is an intermediately soft (green) mass (Figure 2), and normal pancreatic tissue

is homogeneously soft on EUS-elastography.

A prospective study conducted by Dawwas *et al*^[31] which used elastography to differentiate pancreatic masses revealed that quantitative and qualitative EUS elastography techniques had a sensitivity of 100.0% and 95.7%, a specificity of 16.7% and 22.2%, a positive predictive value (PPV) of 86.1% and 86.4%, a negative predictive value (NPV) of 100.0% and 50.0%, and an overall accuracy of 86.5% and 83.8%, respectively. A recent meta-analysis that reviewed six studies showed that using the qualitative color pattern as the diagnostic standard, the pooled sensitivity was 99% (95%CI: 98%-100%) and the specificity was

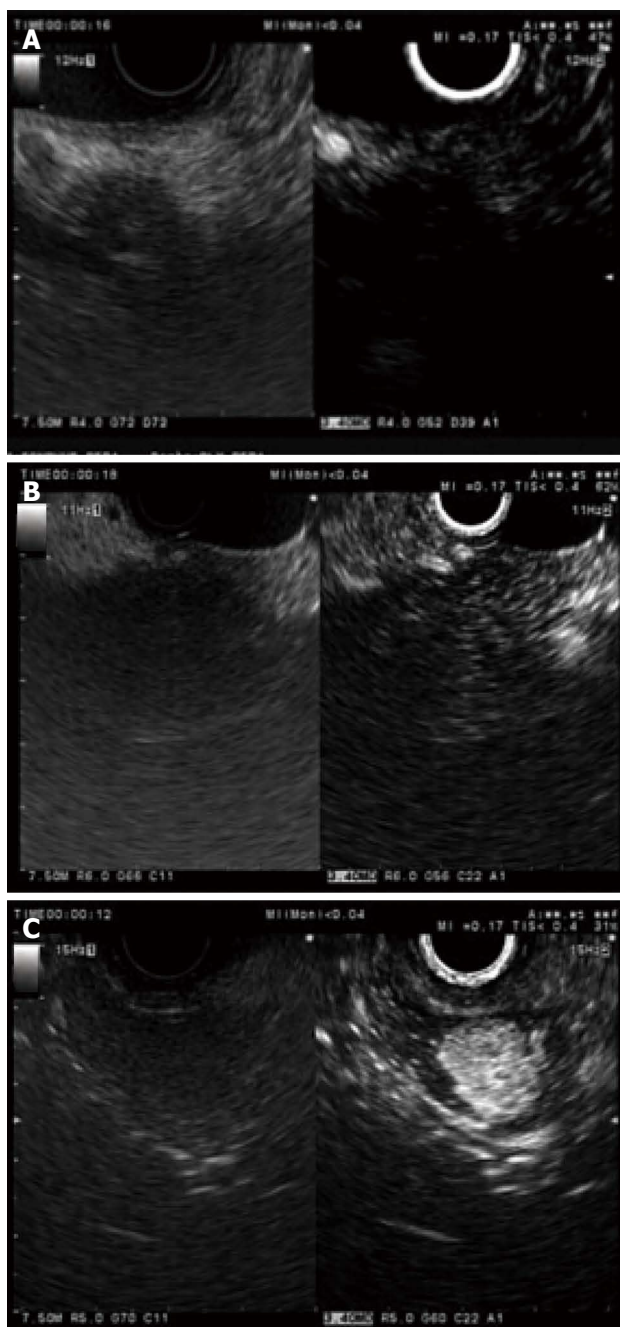


Figure 3 Typical contrast-enhanced harmonic endoscopic ultrasound images of pancreatic tumors. A: Pancreatic carcinoma with hypoenhancement. Conventional EUS (left) shows a hypoechoic mass at the pancreas tail. Contrast-enhanced harmonic endoscopic ultrasound (CH-EUS) (right) indicates that the mass has hypoenhancement compared with the surrounding tissue; B: Chronic pancreatitis with isoenhancement. Conventional EUS (left) shows a hypoechoic mass at the pancreas body. CH-EUS (right) indicates homogeneous enhancement mass similar to the surrounding tissue; a margin is not observed; C: Neuroendocrine tumor with hyperenhancement. Conventional EUS (left) shows a hypoechoic mass at the pancreas body. CH-EUS (right) indicates that enhancement in the mass is higher than in the surrounding tissue (Kwek *et al.*^[65]).

74% (95%CI: 65%-82%)^[32].

More recent studies have focused on quantitative elastography. A European multicenter study conducted by Săftoiu *et al.*^[6] demonstrated that Hue histogram elastography using 175 as the cut-off value had a

sensitivity of 93.4%, a specificity of 66.0%, a PPV of 92.5%, an NPV of 68.9%, and an overall accuracy of 85.4%. Another multicenter study conducted by Giovannini *et al.*^[33] yielded similar results. A study conducted by Havre *et al.*^[34] showed that the median SR in malignant lesions was 7.05 (3.02-27.57) and was 1.56 (0.07-35.55) ($P < 0.001$) in benign lesions. Iglesias-Garcia *et al.*^[8] reported that the SR was significantly higher among patients with pancreatic cancers than in those with inflammatory masses. An earlier study conducted by Săftoiu *et al.*^[35] in 2008 investigated the ability of quantitative EUS elastography to differentiate between benign and malignant pancreatic masses, and its sensitivity, specificity, PPV, NPV and accuracy were 91.4%, 87.9%, 88.9%, 90.6%, and 89.7%, respectively.

Ying *et al.*^[36] analyzed 10 studies including 893 pancreatic masses and found that the pooled sensitivity and specificity for the diagnosis of malignant pancreatic masses were 0.98 (95%CI: 0.93-1.00) and 0.69 (95%CI: 0.52-0.82) for qualitative EUS elastography, and 0.96 (95%CI: 0.86-0.99) and 0.76 (95%CI: 0.58-0.87) for quantitative EUS elastography, respectively. Another meta-analysis conducted by Li *et al.*^[37] yielded similar conclusions.

However, other elastography studies have reported less promising results. One study found overly similar color patterns between cancerous masses and pancreatitis^[38]. One recently published large single-center study reported that quantitative elastography was not as accurate as was described in previous studies and meta-analyses^[31].

There are four types of enhancement patterns in CH-EUS: non-enhancement, hypo-enhancement, iso-enhancement and hyper-enhancement^[39]. A hypo-enhancing pattern has been considered to be one of the most common distinguishing characteristics of pancreatic adenocarcinoma (Figure 3), and is more diagnostically accurate than the finding of a hypoechoic lesion on conventional EUS ($P < 0.001$)^[40]. A recent meta-analysis of CE-EUS showed that this method can identify pancreatic adenocarcinomas with a pooled sensitivity and specificity of 94% and 89%, respectively^[41]. Hypo-vascularity which is a sign of ductal carcinomas in CH-EUS yielded a sensitivity of 89%-95% and a specificity of 64%-89%^[36,40,42]. In particular, CH-EUS was significantly more accurate than CT in diagnosing small ductal carcinomas ≤ 2 cm ($P < 0.034$)^[39].

Lee *et al.*^[43] demonstrated that pancreatic carcinomas and pancreatic neuroendocrine tumors showed different enhancement patterns on CE-EUS, suggesting that the enhancement pattern may be an important characteristic for diagnosis.

CH-EUS for cystic pancreatic lesions

Differentiating between benign and malignant intraductal papillary mucinous neoplasms of the pancreas is challenging. Mural nodules have been

identified as one of the most important signs predicting for malignancy. An earlier study conducted by Ohno *et al*^[44] analyzed the enhancement pattern of mural nodules and found that papillary and invasive nodular patterns were more frequently related to invasive cancer. A recent study of CE-EUS in the differentiation of pancreatic cystic lesions showed that CE-EUS considerably increases the sensitivity of displaying cystic wall vascularization^[45].

EUS-elastography and CH-EUS for lymph nodes

At present, the established standards indicating malignant involvement of lymph nodes (LN) include the following: round shape, hypo-echogenicity, diameter > 1 cm and distinguishing margin. However, all four features of malignant involvement are present in only one-fourth of malignant LNs^[46] and the specificity of these findings is poor^[8].

A recent meta-analysis conducted by Xu *et al*^[7] found that EUS elastography demonstrated a pooled sensitivity of 88% and specificity of 85% for differentiating between benign and malignant LNs. A study conducted by Okasha *et al*^[1] reached similar conclusions. However, a recent study by Larsen *et al*^[47] delivered a disappointing result. The investigators concluded that EUS-elastography was not better than conventional EUS in differentiating between malignant and benign LNs.

On CD-EUS, the presence of a filling defect is a typical characteristic of malignant lymphadenopathy, with a sensitivity of 100% and a specificity of 86.4%^[48]. In a study conducted by Xia *et al*^[49], the sensitivity, specificity and accuracy rates of CD-EUS in diagnosing LN lesions with unknown origin were 96.3%, 100% and 97.6%, respectively.

EUS-elastography and CH-EUS for gastrointestinal submucosal lesions

The risk classifications for GISTs are based on size and the number of mitoses/50 high power fields. Immunohistochemical analysis should also be performed. Therefore, elastographic evaluation of malignancy in such lesions may be difficult.

A recent study conducted by Kannengiesser *et al*^[50] demonstrated that the enhancement pattern of CH-EUS was able to distinguish between GISTs and other benign submucosal tumors such as leiomyoma or lipoma by the enhancement pattern. All histologically proven GISTs showed hyper-enhancement, while lipoma and leiomyoma both showed hypo-enhancement. A study conducted by Sakamoto *et al*^[51] demonstrated that the overall sensitivity, specificity and accuracy of CH-EUS in prediction of malignant GISTs were 100%, 63% and 83%, respectively.

EUS-elastography and CH-EUS guided FNA

Elastography can help the user to select a site where FNA can be performed with improved diagnostic yield, particularly in patients with either necrotic tumors or

possible cancers within diffuse inflammatory lesions.

CH-EUS clearly depicts subtle lesions that conventional EUS is unable to identify and, can be used to select targets for EUS-FNA^[52]. Real-time CH-EUS-FNA can identify and avoid an avascular site, helping to prevent sampling of necrotic areas and allowing the selection of more suitable sites for biopsy^[53].

OTHER CLINICAL APPLICATIONS

The use of EUS-elastography has been investigated for the diagnosis and evaluation of prostate cancer, rectal cancer, and inflammatory bowel disease. In prostate cancer, EUS-elastography has been demonstrated to be better than conventional EUS^[54], and it increases the specificity of prostate biopsies by highlighting areas that are highly suspicious for malignancy^[55]. A study of transrectal elastography conducted by Waage *et al*^[56] showed that the sensitivity, specificity and accuracy rates of SR were 93%, 96% and 94%, respectively. Dietrich *et al*^[57] reported that left hepatic tumors can be differentiated by EUS-elastography.

Elastography of the hepatobiliary system is particularly useful for evaluation of the papilla of Vater and staging papillary carcinoma and papillomatosis^[58].

A recent study of CH-EUS for the differential diagnosis of gallbladder wall thickening, which was conducted by Imazu *et al*^[59], reported that the overall sensitivity, specificity and accuracy rates of CH-EUS for diagnosing malignant GB wall thickening were 89.6%, 98% and 94.4%, respectively.

CE-EUS has also been used in other gastrointestinal diseases, such as inflammatory bowel disease. A study published in 2012 showed that CE-EUS had excellent sensitivity and specificity for the diagnosis of postoperative recurrence in Crohn's disease^[60].

EUS-confocal microscopy for pancreatic cystic lesions

Studies of EUS-confocal microscopy are rare. A recent study conducted by Giovannini *et al*^[61] demonstrated that EUS-confocal microscopy can effectively distinguish different pancreatic cystic lesions.

LIMITATIONS AND FUTURE DEVELOPMENT

EUS-elastography is an operator-dependent technique, with a high image selection bias and, in some cases, a lack of reproducibility. Excessive compression of the tissue can artificially cause more deformation. The presence of certain tissues (*e.g.*, vessels, cysts, and bone) in the ROI significantly influences elasticity measurements. Furthermore, the appropriate cut-off values for quantitative elastography remain controversial. Some authors have reported promising findings, while others noted disappointing results. Consequently, most authors have indicated that elastography is not ready to replace EUS-FNA, but

may be a supplementary procedure in patients with negative or inconclusive EUS-FNA findings, if a strong suspicion of malignancy still exists^[4].

CE-EUS has been criticized for its qualitative nature, and quantitative methods have been proposed to improve its reliability^[62].

The therapeutic potential of CE-EUS is to selectively deliver medications and reduce side-effects using contrast microbubbles as carriers^[63,64].

CONCLUSION

EUS-elastography and CH-EUS are emerging techniques. These techniques are simple and easy to perform (using a touch of a button for elastography), do not require extensive training and costly devices, have a low cost and low complication rate, do not add extra time to EUS procedures, and can provide valuable information regarding the characteristics of focal masses. Therefore, both are effective supplemental techniques in EUS-FNA and should be implemented in clinical practice. A combination of these emerging techniques can further increase the ability of EUS to diagnose pancreatic masses. However, these techniques should be performed in tertiary centers by experienced operators with expertise in EUS and EUS-FNA.

REFERENCES

- 1 **Okasha HH**, Mansour M, Attia KA, Khatib HM, Sakr AY, Naguib M, Aref W, Al-Naggar AA, Ezzat R. Role of high resolution ultrasound/endosonography and elastography in predicting lymph node malignancy. *Endosc Ultrasound* 2014; **3**: 58-62 [PMID: 24949412 DOI: 10.4103/2303-9027.121252]
- 2 **Dietrich CF**, Săftoiu A, Jenssen C. Real time elastography endoscopic ultrasound (RTE-EUS), a comprehensive review. *Eur J Radiol* 2014; **83**: 405-414 [PMID: 23643030 DOI: 10.1016/j.ejrad.2013.03.023]
- 3 **Knabe M**, Günter E, Ell C, Pech O. Can EUS elastography improve lymph node staging in esophageal cancer? *Surg Endosc* 2013; **27**: 1196-1202 [PMID: 23093233 DOI: 10.1007/s00464-012-2575-y]
- 4 **Popescu A**, Săftoiu A. Can elastography replace fine needle aspiration? *Endosc Ultrasound* 2014; **3**: 109-117 [PMID: 24955340 DOI: 10.4103/2303-9027.123009]
- 5 **Hocke M**, Ignee A, Dietrich CF. Advanced endosonographic diagnostic tools for discrimination of focal chronic pancreatitis and pancreatic carcinoma--elastography, contrast enhanced high mechanical index (CEHMI) and low mechanical index (CELM) endosonography in direct comparison. *Z Gastroenterol* 2012; **50**: 199-203 [PMID: 22298098 DOI: 10.1055/s-0031-1281824]
- 6 **Săftoiu A**, Vilmann P, Gorunescu F, Janssen J, Hocke M, Larsen M, Iglesias-Garcia J, Arcidiacono P, Will U, Giovannini M, Dietrich C, Havre R, Gheorge C, McKay C, Gheonea DI, Ciurea T. Accuracy of endoscopic ultrasound elastography used for differential diagnosis of focal pancreatic masses: a multicenter study. *Endoscopy* 2011; **43**: 596-603 [PMID: 21437851 DOI: 10.1055/s-0030-1256314]
- 7 **Xu W**, Shi J, Zeng X, Li X, Xie WF, Guo J, Lin Y. EUS elastography for the differentiation of benign and malignant lymph nodes: a meta-analysis. *Gastrointest Endosc* 2011; **74**: 1001-109; quiz 1001-109; [PMID: 22032315 DOI: 10.1016/j.gie.2011.07.026]
- 8 **Iglesias-Garcia J**, Lindkvist B, Lariño-Noia J, Dominguez-Muñoz JE. Endoscopic ultrasound elastography. *Endosc Ultrasound* 2012; **1**: 8-16 [PMID: 24949330 DOI: 10.7178/eus.01.003]
- 9 **Gheonea DI**, Săftoiu A. Beyond conventional endoscopic ultrasound: elastography, contrast enhancement and hybrid techniques. *Curr Opin Gastroenterol* 2011; **27**: 423-429 [PMID: 21844751 DOI: 10.1097/Mog.0b013e328349cfab]
- 10 **Iglesias-Garcia J**, Larino-Noia J, Abdulkader I, Forteza J, Dominguez-Munoz JE. Quantitative endoscopic ultrasound elastography: an accurate method for the differentiation of solid pancreatic masses. *Gastroenterology* 2010; **139**: 1172-1180 [PMID: 20600020 DOI: 10.1053/j.gastro.2010.06.059]
- 11 **Itokawa F**, Itoi T, Sofuni A, Kurihara T, Tsuchiya T, Ishii K, Tsuji S, Ikeuchi N, Umeda J, Tanaka R, Yokoyama N, Moriyasu F, Kasuya K, Nagao T, Kamisawa T, Tsuchida A. EUS elastography combined with the strain ratio of tissue elasticity for diagnosis of solid pancreatic masses. *J Gastroenterol* 2011; **46**: 843-853 [PMID: 21505859 DOI: 10.1007/s00535-011-0399-5]
- 12 **Alam F**, Naito K, Horiguchi J, Fukuda H, Tachikake T, Ito K. Accuracy of sonographic elastography in the differential diagnosis of enlarged cervical lymph nodes: comparison with conventional B-mode sonography. *AJR Am J Roentgenol* 2008; **191**: 604-610 [PMID: 18647939 DOI: 10.2214/Ajr.07.3401]
- 13 **König K**, Scheipers U, Pesavento A, Lorenz A, Ermert H, Senge T. Initial experiences with real-time elastography guided biopsies of the prostate. *J Urol* 2005; **174**: 115-117 [PMID: 15947593 DOI: 10.1097/01.ju.0000162043.72294.4a]
- 14 **Reddy NK**, Ionciă AM, Săftoiu A, Vilmann P, Bhutani MS. Contrast-enhanced endoscopic ultrasonography. *World J Gastroenterol* 2011; **17**: 42-48 [PMID: 21218082 DOI: 10.3748/wjg.v17.i1.42]
- 15 **Kaufmann BA**, Lindner JR. Molecular imaging with targeted contrast ultrasound. *Curr Opin Biotechnol* 2007; **18**: 11-16 [PMID: 17241779 DOI: 10.1016/j.copbio.2007.01.004]
- 16 **Serrani M**, Caletti G, Fusaroli P. Contrast enhancement and elastography in endoscopic ultrasound: an overview of clinical applications in pancreatic diseases. *Minerva Med* 2014; **105**: 353-361 [PMID: 25028864]
- 17 **Yip HC**, Teoh AY, Chong CC, Lau JY. Current status and future applications of contrast-enhanced endoscopic ultrasonography. *World J Gastrointest Endosc* 2014; **6**: 121-127 [PMID: 24748919 DOI: 10.4253/wjge.v6.i4.121]
- 18 **Kitano M**, Sakamoto H, Kudo M. Contrast-enhanced endoscopic ultrasound. *Dig Endosc* 2014; **26** Suppl 1: 79-85 [PMID: 24118242 DOI: 10.1111/Den.12179]
- 19 **Sanchez MV**, Varadarajulu S, Napoleon B. EUS contrast agents: what is available, how do they work, and are they effective? *Gastrointest Endosc* 2009; **69**: S71-S77 [PMID: 19179175 DOI: 10.1016/j.gie.2008.12.004]
- 20 **Kitano M**, Kudo M, Sakamoto H, Nakatani T, Maekawa K, Mizuguchi N, Ito Y, Miki M, Matsui U, Von Schrenck T. Preliminary study of contrast-enhanced harmonic endosonography with second-generation contrast agents. *J Med Ultra* 2008; **35**: 11-18 [DOI: 10.1007/s10396-007-0167-6]
- 21 **Săftoiu A**, Dietrich CF, Vilmann P. Contrast-enhanced harmonic endoscopic ultrasound. *Endoscopy* 2012; **44**: 612-617 [PMID: 22528674 DOI: 10.1055/s-0032-1308909]
- 22 **Săftoiu A**, Iordache SA, Gheonea DI, Popescu C, Maloş A, Gorunescu F, Ciurea T, Iordache A, Popescu GL, Manea CT. Combined contrast-enhanced power Doppler and real-time sonoelastography performed during EUS, used in the differential diagnosis of focal pancreatic masses (with videos). *Gastrointest Endosc* 2010; **72**: 739-747 [PMID: 20674916 DOI: 10.1016/j.gie.2010.02.056]
- 23 **Ishikawa T**, Itoh A, Kawashima H, Ohno E, Matsubara H, Itoh Y, Nakamura Y, Nakamura M, Miyahara R, Hayashi K, Ishigami M, Katano Y, Ohmiya N, Goto H, Hirooka Y. Usefulness of EUS combined with contrast-enhancement in the differential diagnosis of malignant versus benign and preoperative localization of pancreatic endocrine tumors. *Gastrointest Endosc* 2010; **71**: 951-959 [PMID: 20438884 DOI: 10.1016/j.gie.2009.12.023]

- 24 **Iglesias-Garcia J**, Lindkvist B, Cruz-Soares JB, Larino-Noia J, Dominguez-Munoz E. Does Contrast Enhancement Play a Role as an Adjunct to Endoscopic Ultrasound for the Diagnosis of Chronic Pancreatitis? a Pilot Study. *Gastroenterology* 2012; **142**: S243-S244
- 25 **Kitano M**, Sakamoto H, Komaki T, Kudo M. New techniques and future perspective of EUS for the differential diagnosis of pancreatic malignancies: contrast harmonic imaging. *Dig Endosc* 2011; **23** Suppl 1: 46-50 [PMID: 21535201 DOI: 10.1111/j.1443-1661.2011.01146.x]
- 26 **Kitano M**, Sakamoto H, Matsui U, Ito Y, Maekawa K, von Schrenck T, Kudo M. A novel perfusion imaging technique of the pancreas: contrast-enhanced harmonic EUS (with video). *Gastrointest Endosc* 2008; **67**: 141-150 [PMID: 18155437 DOI: 10.1016/j.gie.2007.07.045]
- 27 **Hirooka Y**, Itoh A, Kawashima H, Ohno E, Itoh Y, Nakamura Y, Hiramatsu T, Sugimoto H, Sumi H, Hayashi D, Ohmiya N, Miyahara R, Nakamura M, Funasaka K, Ishigami M, Katano Y, Goto H. Contrast-enhanced endoscopic ultrasonography in digestive diseases. *J Gastroenterol* 2012; **47**: 1063-1072 [PMID: 23001249 DOI: 10.1007/s00535-012-0662-4]
- 28 **Fusaroli P**, Saftoiu A, Mancino MG, Caletti G, Eloubeidi MA. Techniques of image enhancement in EUS (with videos). *Gastrointest Endosc* 2011; **74**: 645-655 [PMID: 21679945 DOI: 10.1016/j.gie.2011.03.1246]
- 29 **Dunbar K**, Canto M. Confocal endomicroscopy. *Curr Opin Gastroenterol* 2008; **24**: 631-637 [PMID: 19122507 DOI: 10.1097/MOG.0b013e32830c91c7]
- 30 **Konda VJ**, Aslanian HR, Wallace MB, Siddiqui UD, Hart J, Waxman I. First assessment of needle-based confocal laser endomicroscopy during EUS-FNA procedures of the pancreas (with videos). *Gastrointest Endosc* 2011; **74**: 1049-1060 [PMID: 21924718 DOI: 10.1016/j.gie.2011.07.018]
- 31 **Dawwas MF**, Taha H, Leeds JS, Nayar MK, Opong KW. Diagnostic accuracy of quantitative EUS elastography for discriminating malignant from benign solid pancreatic masses: a prospective, single-center study. *Gastrointest Endosc* 2012; **76**: 953-961 [PMID: 22854060 DOI: 10.1016/j.gie.2012.05.034]
- 32 **Xu W**, Shi J, Li X, Zeng X, Lin Y. Endoscopic ultrasound elastography for differentiation of benign and malignant pancreatic masses: a systemic review and meta-analysis. *Eur J Gastroenterol Hepatol* 2013; **25**: 218-224 [PMID: 23169307 DOI: 10.1097/Meg.0b013e32835a7f7c]
- 33 **Giovannini M**, Thomas B, Erwan B, Christian P, Fabrice C, Benjamin E, Geneviève M, Paolo A, Pierre D, Robert Y, Walter S, Hanz S, Carl S, Christoph D, Pierre E, Jean-Luc VL, Jacques D, Peter V, Andrian S. Endoscopic ultrasound elastography for evaluation of lymph nodes and pancreatic masses: a multicenter study. *World J Gastroenterol* 2009; **15**: 1587-1593 [PMID: 19340900 DOI: 10.3748/wjg.15.1587]
- 34 **Havre RF**, Ødegaard S, Gilja OH, Nesje LB. Characterization of solid focal pancreatic lesions using endoscopic ultrasonography with real-time elastography. *Scand J Gastroenterol* 2014; **49**: 742-751 [PMID: 24713038 DOI: 10.3109/00365521.2014.905627]
- 35 **Săftoiu A**, Vilman P, Gorunescu F, Gheonea DI, Gorunescu M, Ciurea T, Popescu GL, Iordache A, Hassan H, Iordache S. Neural network analysis of dynamic sequences of EUS elastography used for the differential diagnosis of chronic pancreatitis and pancreatic cancer. *Gastrointest Endosc* 2008; **68**: 1086-1094 [PMID: 18656186 DOI: 10.1016/j.gie.2008.04.031]
- 36 **Ying L**, Lin X, Xie ZL, Hu YP, Tang KF, Shi KQ. Clinical utility of endoscopic ultrasound elastography for identification of malignant pancreatic masses: a meta-analysis. *J Gastroenterol Hepatol* 2013; **28**: 1434-1443 [PMID: 23731128 DOI: 10.1111/Jgh.12292]
- 37 **Li X**, Xu W, Shi J, Lin Y, Zeng X. Endoscopic ultrasound elastography for differentiating between pancreatic adenocarcinoma and inflammatory masses: a meta-analysis. *World J Gastroenterol* 2013; **19**: 6284-6291 [PMID: 24115828 DOI: 10.3748/wjg.v19.i37.6284]
- 38 **Janssen J**, Schlörer E, Greiner L. EUS elastography of the pancreas: feasibility and pattern description of the normal pancreas, chronic pancreatitis, and focal pancreatic lesions. *Gastrointest Endosc* 2007; **65**: 971-978 [PMID: 17531630 DOI: 10.1016/j.gie.2006.12.057]
- 39 **Kitano M**, Kudo M, Yamao K, Takagi T, Sakamoto H, Komaki T, Kamata K, Imai H, Chiba Y, Okada M, Murakami T, Takeyama Y. Characterization of small solid tumors in the pancreas: the value of contrast-enhanced harmonic endoscopic ultrasonography. *Am J Gastroenterol* 2012; **107**: 303-310 [PMID: 22008892 DOI: 10.1038/ajg.2011.354]
- 40 **Fusaroli P**, Spada A, Mancino MG, Caletti G. Contrast harmonic echo-endoscopic ultrasound improves accuracy in diagnosis of solid pancreatic masses. *Clin Gastroenterol Hepatol* 2010; **8**: 629-34.e1-2 [PMID: 20417721 DOI: 10.1016/j.cgh.2010.04.012]
- 41 **Gong TT**, Hu DM, Zhu Q. Contrast-enhanced EUS for differential diagnosis of pancreatic mass lesions: a meta-analysis. *Gastrointest Endosc* 2012; **76**: 301-309 [PMID: 22703697 DOI: 10.1016/j.gie.2012.02.051]
- 42 **Napoleon B**, Alvarez-Sanchez MV, Gincoul R, Pujol B, Lefort C, Lepilliez V, Labadie M, Souquet JC, Queneau PE, Scoazec JY, Chayvialle JA, Ponchon T. Contrast-enhanced harmonic endoscopic ultrasound in solid lesions of the pancreas: results of a pilot study. *Endoscopy* 2010; **42**: 564-570 [PMID: 20593334 DOI: 10.1055/s-0030-1255537]
- 43 **Lee TY**, Cheon YK, Shim CS. Clinical role of contrast-enhanced harmonic endoscopic ultrasound in differentiating solid lesions of the pancreas: a single-center experience in Korea. *Gut Liver* 2013; **7**: 599-604 [PMID: 24073319 DOI: 10.5009/gnl.2013.7.5.599]
- 44 **Ohno E**, Hirooka Y, Itoh A, Ishigami M, Katano Y, Ohmiya N, Niwa Y, Goto H. Intraductal papillary mucinous neoplasms of the pancreas: differentiation of malignant and benign tumors by endoscopic ultrasound findings of mural nodules. *Ann Surg* 2009; **249**: 628-634 [PMID: 19300203 DOI: 10.1097/SLA.0b013e3181a189a8]
- 45 **Hocke M**, Cui XW, Domagk D, Ignee A, Dietrich CF. Pancreatic cystic lesions: The value of contrast-enhanced endoscopic ultrasound to influence the clinical pathway. *Endosc Ultrasound* 2014; **3**: 123-130 [PMID: 24955342 DOI: 10.4103/2303-9027.131040]
- 46 **Strongin A**, Singh H, Eloubeidi MA, Siddiqui AA. Role of endoscopic ultrasonography in the evaluation of extrahepatic cholangiocarcinoma. *Endosc Ultrasound* 2013; **2**: 71-76 [PMID: 24949368 DOI: 10.7178/Eus.05.003]
- 47 **Larsen MH**, Frstrup C, Hansen TP, Hovendal CP, Mortensen MB. Endoscopic ultrasound, endoscopic sonoelastography, and strain ratio evaluation of lymph nodes with histology as gold standard. *Endoscopy* 2012; **44**: 759-766 [PMID: 22752891 DOI: 10.1055/s-0032-1309817]
- 48 **Kanamori A**, Hirooka Y, Itoh A, Hashimoto S, Kawashima H, Hara K, Uchida H, Goto J, Ohmiya N, Niwa Y, Goto H. Usefulness of contrast-enhanced endoscopic ultrasonography in the differentiation between malignant and benign lymphadenopathy. *Am J Gastroenterol* 2006; **101**: 45-51 [PMID: 16405532 DOI: 10.1111/j.1572-0241.2006.00394.x]
- 49 **Xia Y**, Kitano M, Kudo M, Imai H, Kamata K, Sakamoto H, Komaki T. Characterization of intra-abdominal lesions of undetermined origin by contrast-enhanced harmonic EUS (with videos). *Gastrointest Endosc* 2010; **72**: 637-642 [PMID: 20646696 DOI: 10.1016/j.gie.2010.04.013]
- 50 **Kannengiesser K**, Mahlke R, Petersen F, Peters A, Ross M, Kucharzik T, Maaser C. Contrast-enhanced harmonic endoscopic ultrasound is able to discriminate benign submucosal lesions from gastrointestinal stromal tumors. *Scand J Gastroenterol* 2012; **47**: 1515-1520 [DOI: 10.3109/00365521.2012.729082]
- 51 **Sakamoto H**, Kitano M, Matsui S, Kamata K, Komaki T, Imai H, Dote K, Kudo M. Estimation of malignant potential of GI stromal tumors by contrast-enhanced harmonic EUS (with videos). *Gastrointest Endosc* 2011; **73**: 227-237 [PMID: 21295636 DOI: 10.1016/j.gie.2010.10.011]
- 52 **Romagnuolo J**, Hoffman B, Vela S, Hawes R, Vignesh S.

- Accuracy of contrast-enhanced harmonic EUS with a second-generation perflutren lipid microsphere contrast agent (with video). *Gastrointest Endosc* 2011; **73**: 52-63 [PMID: 21184870 DOI: 10.1016/j.gie.2010.09.014]
- 53 **Kitano M**, Sakamoto H, Komaki T, Kudo M. FNA Guided By Contrast-Enhanced Harmonic EUS in Pancreatic Tumors. *Gastrointestinal Endosc* 2009; **69**: Ab328-Ab329
- 54 **Kamoi K**, Okihara K, Ochiai A, Ukimura O, Mizutani Y, Kawauchi A, Miki T. The utility of transrectal real-time elastography in the diagnosis of prostate cancer. *Ultrasound Med Biol* 2008; **34**: 1025-1032 [PMID: 18255215 DOI: 10.1016/j.ultrasmedbio.2007.12.002]
- 55 **Kapoor A**, Kapoor A, Mahajan G, Sidhu BS. Real-time elastography in the detection of prostate cancer in patients with raised PSA level. *Ultrasound Med Biol* 2011; **37**: 1374-1381 [PMID: 21816287 DOI: 10.1016/j.ultrasmedbio.2011.05.014]
- 56 **Waage JE**, Havre RF, Odegaard S, Leh S, Eide GE, Baatrup G. Endorectal elastography in the evaluation of rectal tumours. *Colorectal Dis* 2011; **13**: 1130-1137 [PMID: 21040360 DOI: 10.1111/j.1463-1318.2010.02440.x]
- 57 **Dietrich CF**. Real Time Elastography Indications Not Only in the Gastrointestinal Tract. *Endoskopie Heute* 2010; **23**: 177-212 [DOI: 10.1055/s-0030-1262579]
- 58 **Cui XW**, Ignee A, Braden B, Woenckhaus M, Dietrich CF. Biliary papillomatosis and new ultrasound imaging modalities. *Z Gastroenterol* 2012; **50**: 226-231 [PMID: 22298103 DOI: 10.1055/s-0031-1281967]
- 59 **Imazu H**, Mori N, Kanazawa K, Chiba M, Toyozumi H, Torisu Y, Koyama S, Hino S, Ang TL, Tajiri H. Contrast-enhanced harmonic endoscopic ultrasonography in the differential diagnosis of gallbladder wall thickening. *Dig Dis Sci* 2014; **59**: 1909-1916 [PMID: 24664415 DOI: 10.1007/s10620-014-3115-5]
- 60 **Paredes JM**, Ripollés T, Cortés X, Moreno N, Martínez MJ, Bustamante-Balén M, Delgado F, Moreno-Osset E. Contrast-enhanced ultrasonography: usefulness in the assessment of postoperative recurrence of Crohn's disease. *J Crohns Colitis* 2013; **7**: 192-201 [PMID: 22542055 DOI: 10.1016/j.crohns.2012.03.017]
- 61 **Giovannini M**, Caillol F, Lemaistre A, Monges G, Napoleon B, Pujol B. Endoscopic ultrasound guided confocal microscopy: Atlas of cystic pancreatic lesions. *Endosc Ultra* 2014; **3**: S19-S21
- 62 **Fusaroli P**, Kypraios D, Mancino MG, Spada A, Benini MC, Bianchi M, Bocus P, De Angelis C, De Luca L, Fabbri C, Grillo A, Marzioni M, Reggio D, Togliani T, Zanmarini S, Caletti G. Interobserver agreement in contrast harmonic endoscopic ultrasound. *J Gastroenterol Hepatol* 2012; **27**: 1063-1069 [PMID: 22414180 DOI: 10.1111/j.1440-1746.2012.07115.x]
- 63 **Hernot S**, Klibanov AL. Microbubbles in ultrasound-triggered drug and gene delivery. *Adv Drug Deliv Rev* 2008; **60**: 1153-1166 [PMID: 18486268 DOI: 10.1016/j.addr.2008.03.005]
- 64 **Kitano M**, Sakamoto H, Kudo M. Endoscopic ultrasound: contrast enhancement. *Gastrointest Endosc Clin N Am* 2012; **22**: 349-58, xi [PMID: 22632956 DOI: 10.1016/j.giec.2012.04.013]
- 65 **Kwek BE**, Ang TL, Seo DW, Imazu H. Contrast-enhanced harmonic endoscopic ultrasonography of solid pancreatic lesions. *Endosc Ultrasound* 2013; **2**: 142-147 [PMID: 24949382 DOI: 10.7178/eus.06.005]

P- Reviewer: Amorniyotin S, Figueiredo PN, Sureka B **S- Editor:** Qi Y
L- Editor: Wang TQ **E- Editor:** Zhang DN



